










RESEARCH ARTICLE

The Assessment of White Blood Corpuscles by Geometric-Morphometric Analysis After the Application of Calcium Aluminate and Calcium Silicate Dental Cements in Wistar Rats^[1]

Muhamed KATICA^{1 (*)}  Zurifa AJANOVIĆ^{2 (v)}  Aida BEŠIĆ¹  Ognjenka JANKOVIĆ³ 
Emina DERVIŠEVIĆ⁴  Nedžad HADŽIOMEROVIĆ⁵  Faruk TANDIR⁵  Smiljana PARAŠ⁶ 
Amina LUČKIN⁷  Vukoman JOKANOVIĆ^{8,9} 

^v Muhamed Katica and Zurifa Ajanović equally contributed to the study

^[1] The part of the results of our study was presented on 9th International Congress on Advances in Veterinary Sciences & Technics in Aksaray/ Türkiye 21-27 September 2024.

¹ University of Sarajevo, Veterinary Faculty, Department of Clinical Sciences of Veterinary Medicine, 71000 Sarajevo, BOSNIA AND HERZEGOVINA

² University of Sarajevo, Faculty of Medicine, Department of Anatomy, 71000 Sarajevo, BOSNIA AND HERZEGOVINA

³ University of Banja Luka, Faculty of Medicine, Department of Restorative Dentistry and Endodontics, 78000 Banja Luka, BOSNIA AND HERZEGOVINA

⁴ University of Sarajevo, Faculty of Medicine, Department of Forensic Medicine, 71000 Sarajevo, BOSNIA AND HERZEGOVINA

⁵ University of Sarajevo, Veterinary Faculty, Department of Basic Sciences of Veterinary Medicine, 71000 Sarajevo, BOSNIA AND HERZEGOVINA

⁶ University of Banja Luka, Faculty of Science and Mathematics, Department of Zoology, 78 000 Banja Luka, BOSNIA AND HERZEGOVINA

⁷ University of Sarajevo, Clinic for Orthopedics and Traumatology, Clinical Center University of Sarajevo, 71 000 Sarajevo, BOSNIA AND HERZEGOVINA

⁸ Inovative Company ALBOS doo, 11 000 Belgrade, SERBIA

⁹ University of Belgrade, Vinča Institute of Nuclear Sciences, 11 000 Belgrade, SERBIA



(*) Corresponding authors:

Muhamed KATICA

Phone: +387 61 224 234

Cellular phone: +387 33 729 155

Fax: +387 33 617 850

E-mail: muhamed.katica@vfs.unsa.ba

How to cite this article?

Katica M, Ajanović Z, Bešić A, Janković O, Dervišević E, Hadžiomerović N, Tandir F, Paraš S, Lučkin A, Jokanović V: The assessment of white blood corpuscles by geometric-morphometric analysis after the application of calcium aluminate and calcium silicate dental cements in wistar rats. *Kafkas Univ Vet Fak Derg*, 31 (1): 111-117, 2025. DOI: 10.9775/kvfd.2024.32947

Article ID: KVFD-2024-32947

Received: 08.09.2024

Accepted: 11.11.2024

Published Online: 12.11.2024

Abstract

The aim of the research was to determine possible changes in the morphology of cells of the leukocyte order of peripheral blood, using geometric morphometric tests, after the application of calcium-aluminate and calcium-silicate cements to the dental pulp in rats. The study included 27 Wistar rats, divided into an experimental group (n=18) and a control group (n=9). Trepanation of the tip of the pulp cavity was performed, and placement of calcium-aluminate and calcium-silicate dental cements directly on the pulp. Peripheral blood samples were collected by vena caudalis puncture, with the aim of making blood smears. In the tpsUtil program, two-dimensional models of the examined leukocytes were created and they were converted into tps files, on which sixteen specific points were marked in the tpsDig program. We analyzed their shape in the MorphoJ program. The results of discriminant functional analysis determined that there was a statistically significant difference in the shape of the lymphocytes between the experimental animals, to which dental cements were applied, compared to the lymphocytes from the control group. Morphological differences were determined between the lymphocytes to which calcium aluminate and calcium silicate were applied. The results indicate that there were statistically significant morphological differences between these two groups of lymphocytes (P=0.02). The results obtained indicate the possibly unfavorable influence of the tested dental cements, especially calcium silicate, on leukocytic cells.

Keywords: Biomaterials, Leukocyte cells, Dentin, Rat



INTRODUCTION

More detailed research began to be carried out into the potential biomedical application of calcium aluminate and silicate cements at the beginning of the twenty-first century^[1]. There are reports that these biomaterials would be a suitable alternative to the existing dental cements, and overcome their evident shortcomings. The failings of commonly used dental cements are generally known, namely their undesirable granular consistency of the fused material, and the prolonged period of attachment^[2]. On the other hand, research by Janković et al.^[1] produced results clearly illustrating the good tolerance of nanostructured calcium aluminate biomaterials, as well as comparable nanostructured calcium silicate ALBO-CSHA and commercial calcium-silicate cement (MTA). Definitely, calcium-aluminate and silicate cements have been identified as good materials for dentistry, especially for dental procedures that come into contact with the dental pulp. In addition, calcium-silicate and calcium-aluminate cements also cause biomineralization, i.e. deposition of hydroxyapatite (HA), and in this way additionally protect the dental tissue^[3]. Moreover, according to Fu et al.^[4] calcium aluminate cements have excellent resistance to high temperatures, better mechanical resistance to wear compared to other dental cements, and improved resistance to aggressive environments.

The most commonly used rodents for experimental studies in the application of dental cements are laboratory rats. Adult rats are the animal model of choice for these types of studies due to their extremely strong dentine that closely resembles human dentin^[5,6].

Interpretation of white blood cell (WBC) changes provides valuable information to guide human and veterinary doctors in establishing diagnoses for a wide range of diseases. Changes in WBC, in a quantitative sense, as well as, for example, the presence of inclusions and/or degenerative changes within the WBC cytoplasm, determined by microscopic examination of blood corpuscles, are additional indicators when establishing a more precise diagnosis^[7,8]. However, successful control and therapeutic success in the treatment of the patient largely depend on identification of the primary, or qualitative state of the observed WBCs.

Geometric analysis greatly helps in this, since the same type of morphometric analysis is performed on a 2- or 3-dimensional plane, and the process of geometric morphometric analysis excludes factors such as position and size, where only shape-related differences are detected^[9,10].

In research by Katica et al.^[2] calcium-silicate and calcium-aluminate cements were used, and no occurrence of

inflammatory processes was determined after analysis of the leukogram and the total WBC count. In that study, all the corpuscles of the leukocytic order were within the reference limits in all experimental groups, without degenerative changes, with the exception of lymphocytes, which had slightly lower values than the reference values.

According to the literature available, that Ajanović et al.^[11] analyzed the effects of hyperthermia on WBC in rats using geometric morphometric methods on leukocyte cells.

The aim of the research was to determine possible changes in the morphology of cells of the leukocyte order of peripheral blood, using geometric morphometric tests, after the application of calcium-aluminate and calcium-silicate cements to dental pulp in adult rats.

MATERIAL AND METHODS

Ethics Committee Approval

This study was approved by the Ethics Committee of the University of Sarajevo-Veterinary Faculty under registration number 07-03-535-3/22, Bosnia and Herzegovina.

Animals

In the experiment, 27 adult albino Wistar rats of both sexes were used, aged 70-77 days, with a body weight of 265-280 g. All animals were kept in the same laboratory conditions (accommodated in standard plastic cages with a sawdust mat) and lived according to the standards for adequate environmental air temperature (20 and 23°C), with 60%±10% air humidity, and a 12-h light/darkness schedule. The rats were regularly visited, and had free access to food and water (*ad libitum*)^[2].

Testing Materials

The materials used for testing are calcium aluminate systems: a $\text{CaO} \cdot \text{Al}_2\text{O}_3 + \text{CaCO}_3 + \text{Bi}_2\text{O}_3$, a mixture called ALBOMCCA obtained by mixing CaCO_3 and Bi_2O_3 , and BaSO_4 with calcium aluminate phase in a ratio of 2:2:1. Finally, water was added to the mixture in a 1:2 ratio, to create cement paste. The second material used was calcium silicate (CS): 60% of the total quantity was $\beta\text{-C}_2\text{S}$ and C_3S phase, with added components: 20% calcium carbonate (CaCO_3) and 20% BaSO_4 (Merck, Germany)^[1,12].

General Experimental Procedures and Experimental Groups

In the experiment, 27 adult rats were used, divided into two groups. The first group (control) underwent surgical (dental) procedures, but without the application of dental cements. This group consisted of nine (9) animals.

The second experimental group, to which dental cements, were applied consisted of 18 animals. Ca aluminate

was applied to the dental pulp of nine (9) rats, and Ca silicate was applied to the remaining nine (9) rats of the experimental group.

Surgical (Dental) Procedures

General anesthesia was administered to the rats in the experimental groups (Ketamine HCl, Injection USP) Rotexmedica-German, i.m., 90 mg/kg body weight, for one h. Dental procedures followed, with the use of sterile instruments, including the plates on which dental cement was prepared. The application site on the teeth was relatively dry following use of absorbent cotton and a saliva pump. Cavity preparations on the occlusal surface of the non-carious first and second maxillary molars were made with a technical micromotor and a sterile round diamond ISO 008 drill, with continuous cooling with water. Blood from the pulp was removed with sterile cotton balls, and the cavity was flushed with saline to remove possible blood debris, as well as dentin dust. Trepanation of the apex of the pulp cavum and placement of cement was performed directly on the pulp. Rats from the control group were subjected to surgery in an identical manner, but without any application of dental cements.

Hematological-Histological Procedures

Peripheral blood samples were collected by *v. caudalis* puncture into 3 mL tubes containing ethylenediaminetetraacetic acid (EDTA) and gel. The injection site was previously disinfected with a standard disinfectant (0.2% chlorhexidine spray).

A drop of blood from each rat from the control and experimental groups was transferred to the slides, and smears were made at an angle of 45 degrees. After air-drying, according to standard laboratory practice, the smears were stained by the Giemsa method^[13].

Geometric Morphometric Tests

The research was performed on two-dimensional models of leukocytes from the peripheral blood smear of the experimental rats. The tested leukocytes were divided into two groups: the group of leukocytes from the experimental animals to which the investigated dental cements were applied (Group 2), and the group of leukocytes from the experimental animals to which no dental cement was applied (Group 1).

After detailed microscopic observation of the blood smears of peripheral blood, a binocular microscope (Boeko, Germany) was used, at 1000 times magnification. Two-dimensional models of the visual fields with the most representative leukocytes of the examined samples were then made using Motic Images Plus 2.0 software. In the tested samples, lymphocytes dominated, followed by neutrophils and eosinophils, while the number of

basophils and monocytes was not sufficient to meet the statistical criteria for inclusion in the study. Furthermore, an analysis of the shape of the lymphocytes, neutrophils and eosinophils from the peripheral blood smear was performed on two-dimensional models using geometric morphometry.

The two-dimensional models of the examined leukocytes were converted in the tpsUtil program into tps files on which sixteen (16) specific points (landmarks) were marked in the tpsDig program. Eight points were marked on the outside of the tested cell and eight points were marked on the core of the tested cell. Specific points were marked in the same order on all the cells of the tested sample, which was necessary for the correct implementation of geometric morphometry.

After marking the specific points, data on their position in the coordinate system (based on x and y axis values) were used to analyze the morphological differences in the leukocytes between the two examined groups. For the analysis of morphological differences, the MorphoJ program was used, in which the x and y axis values of specific points for each examined cell were entered. After centering, scaling and rotation, generalized Procrustes analysis and principal component analysis were performed.

Statistical Analysis

All statistical analyses were performed using SPSS version 13.0 for Windows (Chicago, IL, USA). The distribution of quantitative variables was tested using the Kolmogorov-Smirnov test. The descriptive statistics results for continuous variables are expressed as mean and standard deviation (SD) for normally distributed variables, or as the median and interquartile range for variables with skewed distributions. Categorical variables are expressed as frequencies and percentages. An independent two-sample Student's t-test assessed the significance of the mean differences between two groups. The Mann-Whitney U-test assessed the differences in parameter values that showed a non-normal distribution. Differences between categorical variables were assessed using the chi-square test. P-values less than 0.05 were considered statistically significant^[11].

RESULTS

After centering, scaling and rotation, generalized Procrustes analysis and principal component analysis were performed. *Table 1* shows the results of morphological variability described by principal components (PCs).

Fig. 1 shows the percentage of variability according to the principal components.

The examined leukocyte cells were divided according to their specificities (lymphocytes, neutrophils and

Table 1. Eigenvalues and percent variability defined by principal components (PCs)

Principal Components	Eigenvalues	% Variance	Cumulative %
PC1.	0.00617628	39.681	39.681
PC2.	0.00192800	12.387	52.068
PC3.	0.00146929	9.440	61.507
PC4.	0.00139279	8.948	70.456
PC5.	0.00115537	7.423	77.879
PC6.	0.00070528	4.531	82.410
PC7.	0.00068653	4.411	86.821
PC8.	0.00053314	3.425	90.246
PC9.	0.00037407	2.403	92.649
PC10.	0.00035343	2.271	94.920
PC11.	0.00029818	1.916	96.836
PC12.	0.00022685	1.457	98.293
PC13.	0.00015913	1.022	99.315
PC14.	0.00010656	0.685	100.000

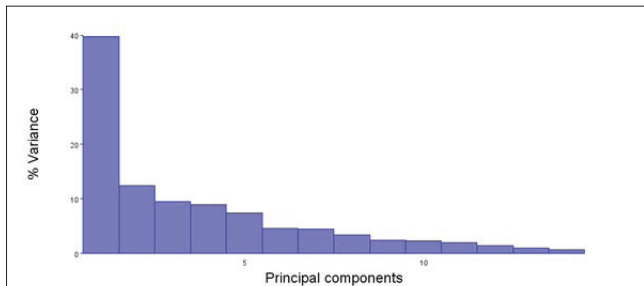


Fig 1. Presentation of the eigenvalues of the principal components and the percentage of variability that they describe (PC1 always describes the highest variability, then PC2 and so on)

eosinophils), and within these groups they were divided into two other groups depending on whether dental cements were applied or not. A discriminant functional analysis was performed comparing the two groups by morphological characteristics.

Fig. 2 shows the position of the leukocytes in the examined groups in the morphological space, defined by the first two principal components (Principal Component 1 and Principal Component 2). The graph clearly shows that there is separation based on morphological characteristics between the control group and the experimental group with dental cements applied.

The results of the discriminant functional analysis show that there was a statistically significant difference in the shape of the lymphocytes between the two experimental groups, i.e. the shape of the lymphocytes of the experimental animals that received dental cements was statistically significantly different from the lymphocytes

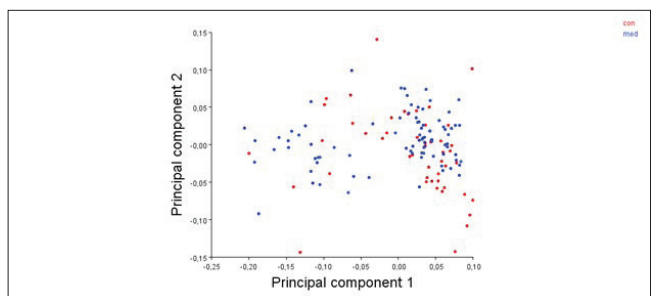


Fig 2. The position of the investigated peripheral blood smear leukocytes in the morphological space defined by the first two principal components (Principal Component 1 and Principal Component 2)

of the control group. The Procrustes distance was 0.036. The Mahalanobis distance value was 1.3179, while the P value (with 1000 permutations) was 0.0135. The T-test value is 0.0110.

Table 2 shows the results of the classification, where it can be seen that, on the basis of the shape, as many as 83.33% of lymphocytes from the group with applied dental cements were correctly classified (Group 2).

Fig. 3 shows the results of the discriminant functional analysis.

Table 2. Results of the correct classification test based on the morphological characteristics of lymphocytes

Group	Group 1	Group 2	Total
Group 1	19	16	35
Group 2	9	45	54

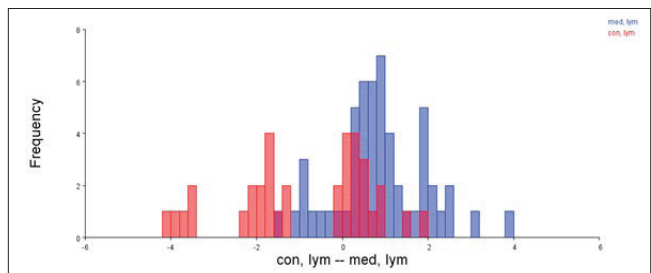


Fig 3. Histogram representation of the results of the discriminant functional analysis of the morphological differences of the lymphocytes of the two examined groups (Blue histograms represent lymphocytes of animals with applied dental cements (med, lym), red histograms represent lymphocytes of animals from the control group (con, lym))

Taking into account that statistically significant differences were found in the shape of lymphocytes between the control group and the group where dental cements were applied, further research was conducted in the direction of examining the morphological changes in the lymphocytes between the control group and the two groups with dental cements, i.e. calcium aluminate and calcium silicate. The results of the discriminant functional analysis of the

morphological differences in lymphocytes between these groups showed that there were statistically significant differences in the shape of the lymphocytes between all these groups.

When comparing the morphological characteristics between the control group of lymphocytes and the lymphocytes where calcium aluminate was applied, the discriminant functional analysis showed statistically significant differences ($P=0.03$). The results are shown in Fig. 4.

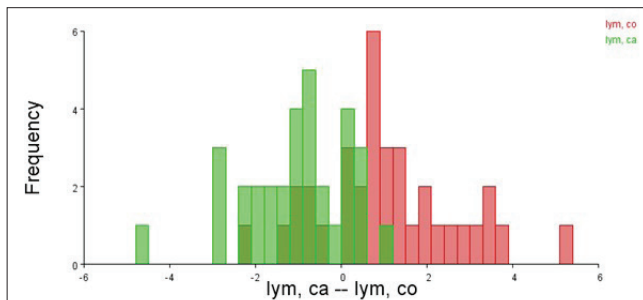


Fig 4. Histogram presentation of the results of the discriminant functional analysis of the morphological differences in the lymphocytes of the two examined groups, the control group of lymphocytes (lym, co) is shown in red, lymphocytes where calcium aluminate was applied (lym, ca) are shown in green

When comparing the morphological characteristics between the control group of lymphocytes and lymphocytes where calcium silicate was applied, the discriminant functional analysis showed statistically significant differences ($P=0.030$). The results are shown in Fig. 5.

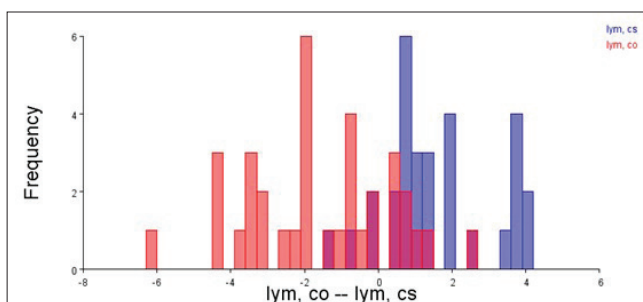


Fig 5. Histogram of the results of the discriminant functional analysis of the morphological differences of the lymphocytes of the two examined groups, the control group of lymphocytes (lym, co) is shown in red, the lymphocytes where calcium silicate was applied (lym, cs) are shown in blue

The discriminant functional analysis examined the morphological differences between lymphocytes when two different types of dental cements, calcium aluminate and calcium silicate, were applied, and the results showed that there are statistically significant morphological differences between these two groups of lymphocytes ($P=0.02$). The results are shown in Fig. 6. and Fig. 7.

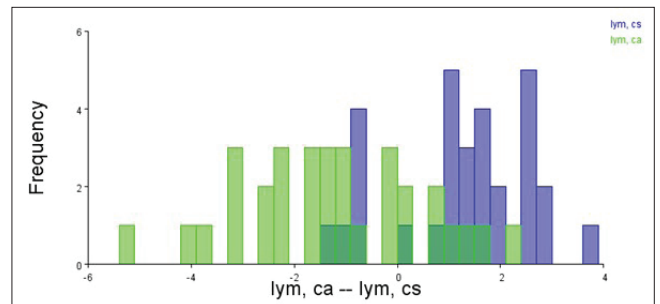


Fig 6. Histogram of the results of the discriminant functional analysis of the morphological differences in the lymphocytes of the two investigated groups, the lymphocyte group where calcium aluminate was applied (lym,ca) is shown in green, the lymphocyte group where calcium silicate (lym, cs) was applied is shown in blue

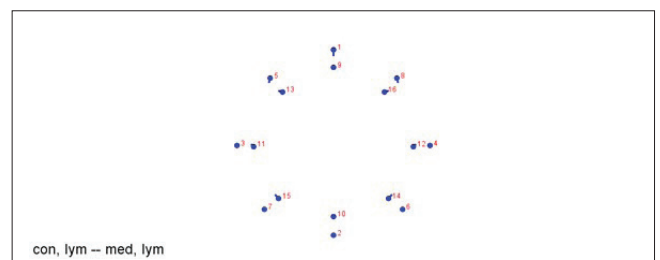


Fig 7. Location of specific points on the tested lymphocytes. The blue dot represents the mean value of the position, the blue line represents the intensity and the direction of change between the control group of lymphocytes (con, lym) and the group where dental cement was applied (med, lym)

No statistically significant morphological differences in neutrophils and eosinophils were found on the two-dimensional models of peripheral blood smears using geometric morphometry between the two investigated groups (the P -value in the analysis of the morphological differences in neutrophils was 0.1635, while the P -value in the analysis of the morphological differences in eosinophils between the two investigated groups was 0.9036.

DISCUSSION

In general, the bioactive materials applied achieve a specific response with the surface of the examined tissue [2].

In addition, according to research by Paraš et al. [14] and Janković et al. [1] the biocompatibility was determined of dental cements based on calcium aluminate and calcium silicate, when observing the potential adverse effects on the liver and subcutaneous tissue of the tested animals. Immunohistochemical studies revealed that nanostructured biomaterials induced hepatocyte proliferation to a certain extent, but this was not clinically relevant and represented a normal and reversible response [14]. Furthermore, the *in vitro* studies by Čolović et al. [15] and Janković et al. [16], determined that calcium aluminate did not show any adverse cytotoxic and genotoxic effects on the MRC-5 diploid cell line of lung fibroblasts.

The research by Janković et al.^[17] also confirmed that the newly synthesized Ca aluminate tested did not cause inflammation of the pulp tissue, with a lower number of neutrophils observed, and their number was not statistically significant compared to the control group.

Thus, all these studies indicate that these dental cements did not have unfavorable local effects on different types of tested tissues in *in vivo* and *in vitro* conditions. However, the influence of the tested dental cements on the blood corpuscles of the peripheral blood shows possible adverse effects, especially on the erythrocytes, in the form of mild hypochromic anemia of the normocytic type. A more unfavorable effect was determined in the case of calcium silicate, where pronounced annulocytosis was determined, and moderate stomatocytosis was determined in the tested rodents that had calcium aluminate applied to the dental pulp^[2]. The same study Katica et al.^[2] determined that, after the application of calcium aluminate and calcium silicate to the dental pulp of the tested rats, the total number of leukocytes remained within the reference intervals of Car et al.^[18], but leukocyte values gravitated towards the lower physiological limit. Mild lymphopenia was found on the leukogram^[18], which was more pronounced in rats treated with calcium silicate. Neutrophils and other leukocyte cells were within the physiological limits. The exception was monocytes, where a significant difference was observed between the mean values of these cells treated with calcium silicate compared to monocytes from the control group^[2].

In our research, using geometric morphometric tests, we obtained representative results in relation to the lymphocytes in the tested rats. These animals, in conditions of physiological balance, had the highest percentage of lymphocytes in their leukograms^[19]. The results of our study indicate statistically significant differences in lymphocyte morphology between the control group and the group where dental cements were applied. Accordingly, it may be understood that dental cements have an adverse effect on lymphocytes to a certain extent. In support of this claim, the results from a similar study by Katica et al.^[2] indicate the occurrence of lymphopenia in the experimental groups to which calcium aluminate and calcium silicate dental cements were applied. The main risk factors for the development of lymphopenia in both human and veterinary medicine are inadequate nutrition, and in particular, various infections, diseases, and the use of certain medications that contribute to lymphopenia, which above all increases the risk of developing lymphopenia^[20].

A less favorable effect in terms of lymphopenia was caused by calcium silicate compared to calcium aluminate^[2]. Calcium silicate cement is a well-known material used in dental practice, and is valued for its exceptional

physical properties. However, this dental cement needs a long time for binding and washing from the application site, which is not the case with calcium aluminate^[16]. Furthermore, according to the same author, Janković et al.^[16], nanostructured biomaterial based on calcium aluminate did not show any genotoxic potential on human lung fibroblasts. The percentage of DNA damage at all the applied concentrations was at the level of untreated control fibroblast cells. However, calcium silicate showed a certain amount of genotoxic potential.

In the light of this, the results from our study are interesting, where morphological differences between the lymphocytes were determined through geometrical and morphometric tests where two different types of dental cements, calcium aluminate and calcium silicate, were applied. The results showed that there were statistically significant morphological differences between these two groups of lymphocytes ($P=0.02$), which indirectly points to the possible unfavorable diversity of the influence of these dental cements after application to the tooth bud, and indicates that our results correspond with similar studies by Katica et al.^[2], Janković et al.^[16] and Janković et al.^[17].

In addition to analyzed lymphocytes, the subject of geometric-morphometric tests in our study were neutrophils, as well as acidophilus. However, no statistically significant morphological differences in neutrophils and eosinophils were found on the two-dimensional models of the peripheral blood smear of the tested rats. As already stated, the number of basophils and monocytes was not sufficient to meet the statistical criteria for inclusion in the study. The reason for this is the usual low percentage values of acidophils, basophils and monocytes in the peripheral blood of rats under physiological conditions^[6,11].

Our research is partly limited since we did not classify lymphocytes into B and T lymphocytes. More detailed knowledge within this classification, and in the context of our research goals, would significantly help in a better understanding of the possible adverse impact of dental cements on lymphocytes.

The results obtained from our study unequivocally indicate that the tested dental cements have a somewhat unfavorable effect on leukocyte cells. It is to be assumed that human and veterinary dentists should be careful when applying them to vulnerable populations, especially geriatric and puerperal populations, as well as other immunocompromised patients.

DECLARATIONS

Availability of Data and Materials: The datasets used and/or analyzed during the current study are available from the corresponding authors (M.K.) on reasonable request.

Funding Support: This research was partly supported by the Ministry of Science, Higher Education and Youth of Sarajevo Canton, Bosnia and Herzegovina in 2023/24.

Ethics Committee Approval

This study was approved by the Ethics Committee of the University of Sarajevo-Veterinary Faculty under registration number 07-03-535-3/22, Bosnia and Herzegovina.

Competing Interests: The authors declare that they have no conflicts of interest.

Declaration of Generative Artificial Intelligence (AI): Authors declare that the article and/or tables and figures were not written/created by AI and AI-assisted technologies.

Author Contributions: MK, ZA, AB, OJ, ED and VJ supervised the study. MK, NH, TF, SP and AL collected the data. ZA, AL and AB made the statistics. The first draft of the manuscript was written by MK, ZA, AB, ED, OJ, SP, TF and NH and all authors contributed to the critical revision of the manuscript and have read and approved the final version.

REFERENCES

- Janković O, Paraš S, Tadić-Latinović Lj, Josipović R, Jokanović V, Živković S: Biocompatibility of nanostructured biomaterials based on calcium aluminate. *Srp Arh Celok Lek*, 146, 634-640, 2018. DOI: 10.2298/SARH171211030J
- Katica M, Janković O, Tandir F, Gradašević N, Dekić R, Manojlović M, Paraš S, Tadić-Latinović L: The effects of calcium aluminate and calcium silicate cements implantation on haematological profile in rats. *Kafkas Univ Vet Fak Derg*, 26 (3): 427-434, 2020. DOI: 10.9775/kvfd.2019.23476
- Primus C, Gutmann JL, Tay FR, Fuks AB: Calcium silicate and calcium aluminate cement for dentistry reviewed. *J Am Ceramic Soc*, 105 (3): 1841-1863, 2022. DOI: 10.1111/jace.18051
- Fu T, Adams MP, Ideker JH: A preliminary study on A calcium aluminate cement concrete maturity theory in predicting conversion. In, *14th International Congress on the Chemistry of Cement, at Beijing, CH*, October, 2015.
- Grigár A, Iványi I, Balogh AE, Rosivall L, Nyárasdy I: Acute effect of calcium hydroxide-containing material in the rat's dental pulp microcirculation. *Fogorv Sz Hungarian*, 94 (3): 107-109, 2001.
- Katica M, Delibegović S: Laboratorijske životinje-Osnovne tehnike eksperimentalnog rada. Dobra Knjiga, Sarajevo, 2019.
- Katica M, Celebicić M, Gradasević N, Obhodzas M, Suljić E, Ocuz M, Delibegović S: Morphological changes in blood cells after implantation of titanium and plastic clips in the neurocranium - Experimental study on dogs. *Med Arch*, 71 (2): 84-88, 2017. DOI: 10.5455/medarh.2017.71.84-88
- Moruzi R, Morar D, Văduva C, Boboc M, Dumitrescu E, Muselin F, Puvača N, Cristina R: Leukogram patterns significance and prevalence for an accurate diagnosis in dogs. *J Hellenic Vet Med Soc*, 74 (1): 5193-5202, 2023. DOI: 10.12681/jhvms.28696
- Gundemir O, Hadžiomerović N, Pazvan G, Erdikmen DO: Radiometric and geometric morphometric analysis of the carpal joint area in 2-year-old thoroughbred horses. *Veterinaria*, 70 (2): 209-217, 2021. DOI: 10.51607/22331360.2021.70.2.209
- Hadžiomerović N, Gundemir O, Tandir F, Avdić R, Katica M: Geometric and morphometric analysis of the auditory ossicles in the red fox (*Vulpes vulpes*). *Animals*, 13, 1230, 2023. DOI: 10.3390/ani13071230
- Ajanović Z, Dervišević E, Katica M, Dervišević L, Dervišević A, Salihbegović A, Dervišević M, Numanagić D, Sarajlić N, Sarač-Hadžihalilović A: Analysis of effect of hyperthermia on white blood cells of experimental rats using geometric morphometrics method. *Kafkas Univ Vet Fak Derg*, 30 (2): 251-257, 2024. DOI: 10.9775/kvfd.2023.30976
- Jokanović V, Čolović B, Mitrić M, Marković D, Četenović B: Synthesis and properties of a new dental material based on nano-structured highly active calcium silicates and calcium carbonates. *Int J Appl Ceram Technol*, 11 (1): 57-64, 2014. DOI: 10.1111/ijac.12070
- Katica M, Bešić A, Kapo N, Klarić Soldo D, Elmir Čičkušić E, Hadžiomerović N: Commensal brown rat (*Rattus norvegicus*) as a carrier of potential zoonotic parasites in the urban area of Bosnia and Herzegovina. *Wien Tierarztl Monat - Vet Med Austria*, 111:Doc4, 2024. DOI: 10.5680/wtm000031
- Paraš S, Janković O, Trišić D, Čolović B, Mitrović -Ajtić O, Dekić R, Soldatović I, Živković Sandić M, Živković S, Jokanović V: Influence of nanostructured calcium aluminate and calcium silicate on the liver: Histological and unbiased stereological analysis. *Int Endod J*, 52, 1162-1172, 2019. DOI: 10.1111/iej.13105
- Čolović B, Janković O, Živković S, Žižak Ž, Besu Žižak I, Jokanovića V: A new endodontic mixture based on calcium aluminate cement obtained by hydrothermal synthesis. *Ceram Internat*, 45 (7): 9211-9218, 2019. DOI: 10.1016/j.ceramint.2019.01.266
- Janković O, Arbutina R, Adamović T, Gnjata S, Josipović R, Đukić I, Vladan Mirjanić V, Jokanović V, Žižak Ž: Genotoxic effect of newly synthesized nanomaterials for potential dental application. *Contemp Mat*, XV-1, 93-103, 2024. DOI: 10.7251/COMEN2401093J
- Janković O, Arbutina R, Adamović T, Đukić I, Kapetanović J, Lovrić J, Vukoje K: Histopathological pulp response of teeth capped with calcium aluminate cement and biodentine: Experimental study on rodents. *Veterinaria*, 73 (1): 34-43, 2024b. DOI: 10.51607/22331360.2024.73.1.34
- Car BD, Eng VM, Everds NE, Bounous DI: Clinical pathology of the rat. In, Suckow MA, Weisbroth SH, Franklin CL (Eds): *The Laboratory Rat*. 2nd ed., 127-145, Elsevier, London, 2006.
- Kampfmann I, Bauer N, Johannes S, Moritz A: Differences in hematologic variables in rats of the same strain but different origin. *Vet Clin Pathol*, 41 (2): 228-234, 2012. DOI: 10.1111/j.1939-165X.2012.00427.x
- Božić T, Ivanović Z: Patofiziologija Čelija Krvi. In, Božić T (Ed): *Patološka Fiziologija Domaćih Životinja*. 2nd ed., 40-67, Naučna KMD, Belgrade, 2012.

