

## CASE REPORT

# Surgical Correction of Congenital Meatal Stenosis Concurrent with Phimosis

Sungin LEE <sup>1</sup> (\*)  Seungwook KIM <sup>1</sup>  Yujin KIM <sup>1</sup> <sup>1</sup> Chungbuk National University, College of Veterinary Medicine, Department of Veterinary Surgery, 28644 Cheongju, KOREA

(\*) Corresponding author: Sungin LEE

Phone: +82 43 261 3248

Cellular phone: +82 10 293 62002

Fax: +82 43 261 3248

E-mail: [sunginlee@cbnu.ac.kr](mailto:sunginlee@cbnu.ac.kr)

How to cite this article?

Lee S, Kim S, Kim Y: Surgical correction of congenital meatal stenosis concurrent with phimosis. *Kafkas Univ Vet Fak Derg*, 30 (4): 569-572, 2024.

DOI: 10.9775/kvfd.2024.31778

Article ID: KVFD-2024-31778

Received: 14.02.2024

Accepted: 14.05.2024

Published Online: 27.05.2024

## Abstract

An 18-month-old male cat presented with pollakiuria and hematuria. It had experienced misty urination and dampness around the genital area since the age of three months. Physical examination displayed small preputial and urethral openings, and subcutaneous cryptorchidism. Blood tests revealed elevated levels of blood urea nitrogen, creatinine, potassium, and phosphate. Radiography revealed a distended bladder. Castration and perineal urethrostomy were conducted to correct subcutaneous cryptorchidism and relieve urinary incontinence due to meatal stenosis and phimosis. Normal postoperative urination was observed; no complications were reported during the follow-up. This case highlights the successful surgical intervention of meatal stenosis concurrent with phimosis.

**Keywords:** Cat, Cryptorchidism, Perineal urethrostomy, Phimosis, Urethral stricture

## INTRODUCTION

Feline urethral obstruction is a common disorder, with an incidence rate ranging from 1.5% to 9% <sup>[1]</sup>. The etiology of urethral obstruction is mostly acquired, including urethral plug, calculi, stricture, and neoplasia, although congenital anomalies have also been documented <sup>[2]</sup>. Meatal stenosis and phimosis, contributing to urethral obstruction, are often acquired through trauma and excessive grooming <sup>[3]</sup>. Clinical manifestations such as stranguria, pollakiuria, hematuria, and vomiting vary based on the extent of the obstruction. Diagnosis of meatal stenosis and phimosis involves visual examination of the penis and preputial ring. The management of both conditions typically requires surgical intervention via perineal urethrostomy (PU). Nonetheless, preputioplasty has been effective in treating phimosis, and wedge meatoplasty can be an option for addressing meatal stenosis <sup>[3-7]</sup>.

This case report demonstrates the urinary obstruction resulting from suspected congenital meatal stenosis concurrent with phimosis in a cat. Both meatal stenosis and phimosis were successfully managed through PU,

and the obstructive uropathy was resolved without complications.

## CASE HISTORY

Written informed consent was obtained from the owner for the participation of the animal in this study.

An 18-month-old intact male domestic short-haired cat weighing 3.5 kg presented with pollakiuria and hematuria. The cat had been experiencing sporadic voiding difficulties since the age of three months, characterized by a misty pattern during urination and dampness around the genital area. There was no evidence of trauma or excessive licking of the genital region. While the vital signs were normal during the physical examination, abnormal findings included a small preputial opening, a small urethral opening, and a misty pattern during urination. The prepuce could not be fully retracted, exposing only the tip of the penis owing to its small opening. Attempts to assess patency using a 3-fr tomcat urinary catheter were unsuccessful because of the narrow urethral opening. Subcutaneous cryptorchidism was observed in the left inguinal region.



Blood tests, including complete blood count, blood gas analysis and serum blood chemistry, revealed increased blood urea nitrogen (BUN, 182.1 mg/dL [reference interval {RI} 15-37 mg/dL]), increased creatinine (13.2 mg/dL [RI 0.7-2.1 mg/dL]), hyperkalemia (8.1 mmol/L [RI 3.2-5.5 mmol/L]) and hyperphosphatemia (9.4 mg/dL [RI 2.6-6.4 mg/dL]). Radiography revealed no abnormalities, except for a distended bladder (Fig. 1). Cystocentesis was performed to relieve urinary retention temporarily.

The patient underwent castration and PU to address the voiding difficulties and correct cryptorchidism. Intravenous propofol (5 mg/kg, Provive, Myungmoon Pharm. Co., Ltd.; Seoul, South Korea) was administered to induce anesthesia. Under general anesthesia using 2.0% isoflurane (Terrell; Piramal Critical Care; Bethlehem, PA, USA) with 100% oxygen ventilation and an intravenous infusion of 0.9% NaCl solution (2 mL/kg/h; 0.9% NS, JW Pharm. Co., Ltd.; Gwacheon, South Korea), the patient was maintained in the perineal position throughout the surgery. Conventional castration was performed prior to PU. While the right testicle was in a normal position, the left testicle was located in the subcutaneous inguinal region. The removed testicle showed hypoplasia on the left side (10.5 x 5.5 mm) compared to the right testicle (15.8 x 12.3 mm) (Fig. 2). A partial prepuce incision exposed the penis. An incision at the penile tip revealed a urethral stricture, obstructing the insertion of a urinary catheter despite the extension of the incision (Fig. 3-A). Subsequently, PU was conducted. When the perineal urethra was exposed, a urinary catheter was inserted retrogradely to evaluate patency, revealing only urethral strictures in the glans penis region. After PU, urethral patency assessed by insertion of a urinary catheter, indicating no evidence of constriction in the urethral passage (Fig. 3-B).

The surgery was uneventful, and remifentanyl (2.5 µg/kg/h; Tivare, BCWORLD Pharm. Co., Ltd.; Yeojoo, South Korea) was administered intravenously for pain management during and after surgery. Normal urination was observed during hospitalization. The patient was discharged 3 days after surgery and received amoxicillin/clavulanate (13.75 mg/kg; AMOCLA, KUHNIL Pharm. Co., Ltd.; Cheonan, South Korea), metronidazole (10 mg/kg; Flasinyl, HK inno.N; Cheongju, South Korea), and famotidine (1 mg/kg; Famotidine, NELSON; Cheongju, South Korea) orally for 7 days. Post-surgical assessment was conducted 1 week, 3 weeks, 6 weeks, and 3 months after the surgery. The blood analysis conducted 3 weeks after the operation showed marked improvement in BUN (21 mg/dL [RI 15-37 mg/dL]), creatinine (1.1 mg/dL [RI 0.7-2.1 mg/dL]), potassium (4.7 mmol/L [RI 3.2-5.5 mmol/L]), and phosphate (5.8 mg/dL [RI 2.6-6.4 mg/dL]). The owner did not observe any urinary dysfunction

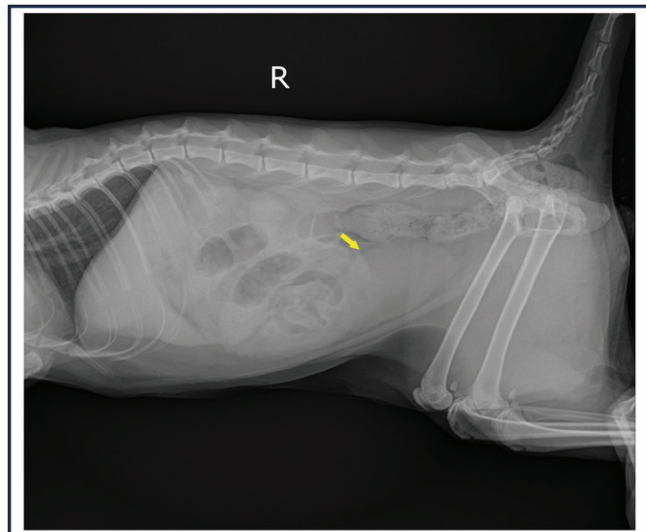


Fig 1. Preoperative abdominal radiography revealed urinary bladder distention (arrow). No other factors contributing to urinary blockage were detected

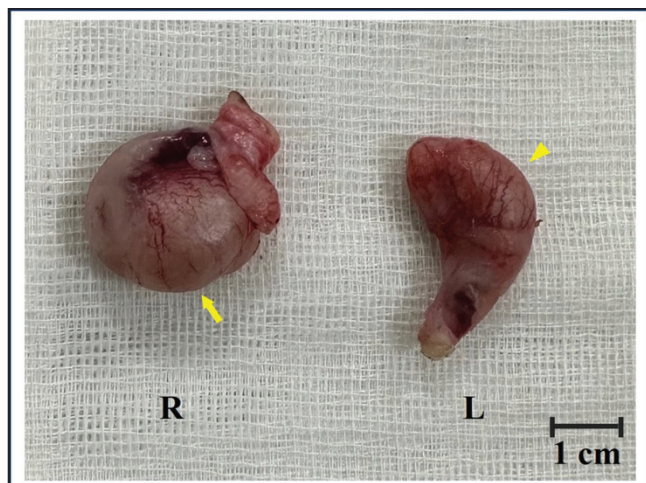


Fig 2. Gross pathology of the testicles showed the left testicle (10.5 x 5.5 mm) (arrowhead) is smaller than the right testicle (15.8 x 12.3 mm) (arrow) indicating left testicular hypoplasia

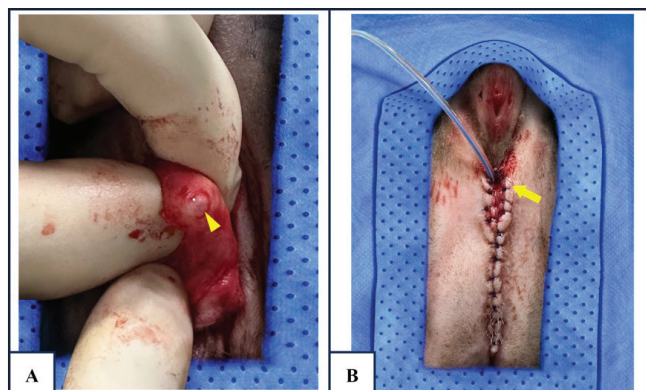


Fig 3. Urethral patency of the patient. A- The penis was exposed by a partial preputial incision, and an incision at the penile tip revealed the presence of meatal stenosis (arrowhead), B- Urethral patency was assessed through the normograde insertion of a urinary catheter (arrow), demonstrating the absence of stricture in the urethra

or surgical site problems, and no complications were reported during the three-month follow-up period.

## DISCUSSION

This case report documents the successful surgical management of urethral obstruction resulting from congenital meatal stenosis along with phimosis in a cat.

When initially presented to the hospital, the patient was suspected with urinary obstruction due to clinical signs, elevated BUN and creatinine levels, and electrolyte imbalance, necessitating immediate treatment [8]. Despite considering urethral catheterization as the primary method to alleviate the obstruction, the narrow preputial and urethral openings of the patient prevented the insertion of a 3-fr tomcat catheter. Visual inspection and radiography revealed no evidence of other causes of urinary obstruction. Although cystocentesis provided temporary relief for the distended bladder, structural urethral obstruction required surgical intervention.

In this case, PU was chosen as the surgical technique to address both meatal stenosis and phimosis. The surgical approach for phimosis varies based on the presence of penile-preputial adhesions [4]. These methods include circumferential preputioplasty, preputial urethrostomy, and PU [6,7]. Feline meatal stenosis requires PU or wedge meatoplasty [5,9]. Due to the potential risk of urethral stricture associated with both circumferential preputioplasty and wedge meatoplasty, the concomitant application of these surgical techniques was not conducted [10,11]. The wedge meatoplasty or amputation at the penile tip was considered incompletely resolving the urethral stricture at the distal urethra, necessitating PU to alleviate urinary obstruction. During surgery, a catheter was used to verify urethral patency and uncover a stricture solely in the penile urethra. Consequently, PU emerged as the optimal decision to address the structural obstruction arising from both phimosis and meatal stenosis.

The evaluation of PU outcomes focused on identifying complications, with short- and long-term issues reported in 62.2% and 14.3% of cases, respectively [12]. Possible short- and long-term complications include sterile cystitis, repeated urethral obstruction, urinary tract infection, urinary incontinence, urethrostomy stricture, and urine leakage into the subcutaneous space of the peristoma. In this case, no complications related to urinary clinical signs were identified for three-months follow-up period.

Disorders of sexual development (DSDs) are abnormalities resulting from inadequate development of the reproductive system. DSDs in tomcats are infrequently reported and manifest as ambiguous genitalia, penile frenulum, penile hypoplasia, cryptorchidism, hypospadias, and phimosis. DSDs often occur alongside other congenital

abnormalities in cats. Cryptorchidism is associated with hypospadias, and penile, preputial, and testicular hypoplasia [1]. Phimosis is also frequently observed in conjunction with penile hypoplasia [4]. In this case, the patient experienced urinary obstruction due to congenital phimosis concomitant with meatal stenosis. While feline meatal stenosis is typically considered an acquired abnormality rather than a congenital defect, the patient in this case exhibited obstructive clinical signs shortly after birth with no evidence of traumatic events causing the meatal stenosis [3]. In addition, subcutaneous cryptorchidism was identified, along with testicular hypoplasia. Thus, the patient exhibited a combination of DSDs, making this case distinct and offering valuable insights into feline DSDs.

One limitation of this report was the absence of positive cystourethrography results to identify and assess the location of the urethral stricture. Positive cystourethrography is less sensitive for detecting urethral strictures at the penile tip, and the diagnosis of meatal stenosis relies on direct catheterization [3]. Urethral patency was examined through direct insertion of a catheter during the operation, leading to the diagnosis of meatal stenosis.

This case report represents the documentation of congenital phimosis concurrent with meatal stenosis in a cat. The patient also presented with cryptorchidism and testicular hypoplasia, and simultaneous occurrence of DSDs is rarely observed in cats. This case report highlights the clinical insight that male kittens displaying urethral obstruction and presenting with a misty urinary pattern should be suspected of having congenital meatal stenosis and phimosis. In cases of DSDs, a thorough examination of other DSDs should be conducted. Moreover, it is advisable to contemplate PU as a surgical technique to alleviate urinary blockage caused by the simultaneous presence of phimosis and meatal stenosis.

## DECLARATIONS

**Availability of Data and Materials:** The datasets analyzed during the study are available from the corresponding author (S. LEE) on request.

**Acknowledgements:** The authors would like to thank the owners of the cat for consenting to publish this report.

**Funding Support:** This research was supported by "Regional Innovation Strategy (RIS)" through the National Research Foundation of Korea(NRF) funded by the Ministry of Education(MOE)(2024RIS-001) and also supported by the National Research Foundation of Korea(NRF) grant funded by the Korea government(MSIT) (RS-2023-00253736).

**Competing Interests:** The authors declared that there is no conflict of interest.

**Authors' Contributions:** Conceptualization was done by SK and

SL, data curation was done by SK and YK, visualization was done by SK and YK, and the article was written by SK, YK and SL.

## REFERENCES

- Kutzler MA:** Disorders of the prepuce and penis. In, Johnson AK, Kutzler MA (Eds): *Feline Reproduction*. 204-212, CABI, USA, 2022. DOI: 10.1079/9781789247107.0022
- Henry P, Schiavo L, Owen L, McCallum KE:** Urinary incontinence secondary to a suspected congenital urethral deformity in a kitten. *J Feline Med Surg*, 7 (2): 20551169211045642, 2021. DOI: 10.1177/20551169211045642
- Corgozinho KB, de Souza HJ, Pereira AN, Belchior C, da Silva MA, Martins MC, Damico CB:** Catheter-induced urethral trauma in cats with urethral obstruction. *J Feline Med Surg*, 9 (6): 481-486, 2007. DOI: 10.1016/j.jfms.2007.09.002
- de Vlaming A, Wallace ML, Ellison GW:** Clinical characteristics, classification, and surgical outcome for kittens with phimosis: 8 cases (2009-2017). *J Am Vet Med Assoc*, 255 (9): 1039-1046, 2019. DOI: 10.2460/javma.255.9.1039
- Freeman AI:** Wedge meatoplasty as a treatment for stricture of the urethral meatus in a cat. *J Feline Med Surg*, 14 (6): 428-431, 2012. DOI: 10.1177/1098612X12442040
- Okur S, Yanmaz LE, Ersöz U, Şenocak MG, Gölgeli A, Turgut F, Gümürçinler B:** Outcome of preputioplasty in cats with acquired phimosis: 8 cases. *MAE Vet Fak Derg*, 8 (1): 15-18, 2023. DOI: 10.24880/maevfd.1172488
- Akhtardanesh B, Delshad S, Shafipour A, Ghoreishi S, Abbasi MF, Abbasi MF:** Congenital phimosis in Scottish Fold kitten. *J Adv Vet Res*, 12 (2): 174-176, 2022.
- Lee JA, Drobatz KJ:** Characterization of the clinical characteristics, electrolytes, acid-base, and renal parameters in male cats with urethral obstruction. *J Vet Emerg Crit Care*, 13 (4): 227-233, 2003. DOI: 10.1111/j.1534-6935.2003.00100.x
- Wilson GP, Harrison JW:** Perineal urethrostomy in cats. *J Am Vet Med Assoc*, 159 (12): 1789-1793, 1971.
- Boothe HW:** Penis, prepuce, and scrotum. In, Slatter DH (Ed): *Textbook of Small Animal Surgery*. 3<sup>rd</sup> ed., 1531-1541, Saunders, 2003.
- Armenakas NA, Morey AF, McAninch JW:** Reconstruction of resistant strictures of the fossa navicularis and meatus. *J Urol*, 160, 359-363, 1998. DOI: 10.1016/S0022-5347(01)62895-7
- Seneviratne M, Stamenova P, Lee K:** Comparison of surgical indications and short- and long-term complications in 56 cats undergoing perineal, transpelvic or prepubic urethrostomy. *J Feline Med Surg*, 23 (6): 477-486, 2021. DOI: 10.1177/1098612X20959032