

Treatment of Traumatic Articulatio Cubiti Luxation: A Retrospective Study in Six Cats

Mehmet SAĞLAM^{1,a} Pınar CAN^{2,b} Abdurrahim FADIL^{2,c}

¹ Department of Surgery, Faculty of Veterinary Medicine, Aksaray University, TR-68100 Aksaray - TURKEY

² Department of Surgery, Faculty of Veterinary Medicine, Ankara University, TR-06110 Ankara - TURKEY
ORCID: ^a 0000-0001-8934-8529; ^b 0000-0001-9955-0499; ^c 0000-0001-5815-0173

Article ID: KVFD-2020-23943 Received: 21.01.2020 Accepted: 26.05.2020 Published Online: 28.05.2020

How to Cite This Article

Sağlam M, Can P, Fadil A: Treatment of traumatic articulatio cubiti luxation: A retrospective study in six cats. *Kafkas Univ Vet Fak Derg*, 26 (5): 603-607, 2020. DOI: 10.9775/kvfd.2020.23943

Abstract

Traumatic elbow joint luxation is the displacement of one or more bones forming the elbow joint due to blunt trauma, and it is uncommon in dogs and rare in cats. Although there are numerous case series in dogs, a few feline reports have been described. The aim of this study is to present the results of the clinical, radiological findings and administered treatments in cats with traumatic elbow luxation. Six cats with a diagnosis of traumatic elbow luxation due to clinical and radiological examinations were included in this study. Two acute cases were treated with closed reduction, but it was not possible to achieve reduction by close manipulation in four chronic cases. Two of the chronic cases, the lateral collateral ligament was repaired with a 2/0 polypropylene suture. The lateral collateral ligament was beyond to repair in 2 of the remaining chronic cases; in one of these cases the stability was achieved with circumferential wire prostheses, in other case with two screw and figure-eight-wire technique. There was no failure and/or complication in none of the cases after treatment. In conclusion, when the closed reduction is unsuccessful for the treatment of traumatic elbow luxation or in chronic cases, open reduction is found satisfactory.

Keywords: Cat, Elbow joint, Luxation, Trauma

Travmatik Articulatio Cubiti Luksasyonunun Tedavisi: Altı Kedide Retrospektif Bir Çalışma

Öz

Travmatik dirsek eklemi luksasyonu, küt travma nedeniyle dirsek eklemi oluşturan bir veya daha fazla kemiğin yer değiştirmesi olgusudur, köpeklerde karşılaşılmamasına rağmen kedilerde nadir görülmektedir. Köpeklerde çok sayıda vaka serisi olmasına rağmen, kedilerde birkaç bildiri yayımlanmıştır. Bu çalışmanın amacı travmatik dirsek luksasyonu olan kedilerde klinik, radyolojik bulgular ve uygulanan tedavilerin sonuçlarını sunmaktır. Klinik ve radyolojik incelemeler sonucunda travmatik dirsek luksasyonu belirlenen altı kedi çalışmaya dahil edildi. İki akut olgu kapalı redüksiyon ile tedavi edildi, ancak dört kronik olguda kapalı manipülasyon ile redüksiyon sağlanamadı. Kronik olgulardan ikisinde lateral kollateral ligament 2/0 polipropilen suture ile onarıldı. Diğer kronik olgularda ise lateral kollateral ligamentin onarımı yerine; bunlardan birinde çevresel serklaj ile diğerinde iki vidalı sekiz şekinde germe teli tekniği ile stabilizasyon sağlandı. Tedavi sonrası hiçbir olguda relüksasyon veya komplikasyon görülmedi. Sonuç olarak, travmatik dirsek luksasyonunun tedavisi için kapalı redüksiyon başarısız olduğunda veya kronik vakalarda, açık redüksiyon girişimi memnuniyet verici bulunmuştur.

Anahtar sözcükler: Dirsek eklemi, Kedi, Luksasyon, Travma

INTRODUCTION

Elbow luxation can be congenital or occurs traumatically^[1,2]. Traumatic elbow joint luxation is the displacement of one or more bones forming the elbow joint because of blunt trauma, and it is uncommon in dogs and rare in cats^[3-7]. Luxation can occur because of high-energy trauma such as vehicular accidents, falls, animal fights

and limb entrapments^[8,9]. Because of the displacement of the bones, the normal anatomical contact of the articular surfaces of the relevant bones is disrupted^[10]. Since the large medial condyle of the humerus blocks the medial luxation of the Radius-ulna, mostly the lateral luxation is seen^[6,7,11]. Although there are numerous case series in dogs^[8,9,12,13], a few feline reports have been described^[5,6,14].



Correspondence



+90 532 3753136



saglam45@gmail.com

The history usually includes trauma, mostly a vehicular accident [8]. In addition to this, it can also be caused by falling from high and cat-dog fights. The angle of the joint should be 45° or less at the time of trauma in order to allow luxation of the elbow joint without fracture [10,11].

Clinical finding is that the animal is unable to bear its weight on the affected limb and the elbow is carried in a flexed position. Palpation of the elbow reveals pain, crepitation, swelling of the joint and the resistance to flexion and extension. Two-planes radiography should be used for definite diagnosis [7,10].

Most luxated elbows can be reduced by closed manipulation if treated within the first few days after injury [3,6,15]. Closed reduction should be performed under general anesthesia [3,6,7]. The elbow joint is brought to the flexion position at an angle of 100-110° and the medial rotation of the radius-ulna is performed. After the anconeal process hooks over the lateral condyle, elbow is extended slightly. Then flexed while medial pressure on the radial head is continued. Pronation the radial head can be forced under the capitulum humeri, especially with abduction of the elbow. A straight cranio-caudal radiograph of both elbows is necessary for comparison to ascertain full reduction [7,16]. Open reduction of a luxated elbow is indicated when it is impossible to achieve closed reduction or if the joint and muscle contractures occur [7,10]. Following the general anesthesia, lateral approach to the joint is performed. A curved elevator is used for reduction. The elevator is placed under the humerus with the convex side facing upwards, inverted and pressed downwards to provide reduction of the joint. Care should be taken not to injure the joint cartilage when performing these procedures [10]. If the tension created by the triceps brachii prevents the reduction, osteotomy of olecranon can be performed [7,10,16]. Myotomy of the triceps brachii muscle can also be carried out for preventing the tension, when the olecranon osteotomy is not preferred [10]. In cases where it is not possible to repair the ruptured collateral ligaments observed during the operation, it can be replaced with two screws which are placed to lateral condyle of the humerus and caput radii and a figure-eight wire in dogs [6,7,10], or circumferential suture prostheses can be performed in cats as described by Farrell et al. [4].

After the surgery, the limb should be positioned with the elbow in extension and supported with a soft padded splinted bandage for 1-3 weeks. After removal of the bandage, passive range of motion should be performed daily, but exercise should be limited for 3 to 4 weeks [7,16].

The aim of this study is to present the results of the clinical, radiological findings and administered treatments in cats with traumatic elbow luxation.

MATERIAL and METHODS

Between June 2018 and December 2019, 6 cats were

presented to the Ankara University, Faculty of Veterinary Medicine, Department of Surgery for traumatic elbow luxation. Records of all cats were reviewed for signalment, history, clinical and radiological findings and applied treatments.

Same anesthesia induction protocol was used for both open and closed reduction. Medetomidine HCl (Domitor®, Zoetis, Finland) 80 µg/kg i.m. ve Ketamine HCl (Ketasol® 10%, İnterhas, Turkey) 5 mg/kg i.m. were used for induction. Maintenance of anesthesia was achieved with isoflurane (Isoflurane-USP, Piramal, USA) & oxygen for open reduction. Perioperative cefazolin sodium (İespor®, İ.E. Ulagay, Turkey) 25 mg/kg i.v. was used for antibiotherapy. Analgesia was achieved with 0.1 mg/kg sc morphine HCl (Morphine®, Galen, Turkey).

In acute cases, reduction was achieved with closed manipulation as previously described [7,16]. In chronic cases or if the reduction was not achieved with closed manipulation, open reduction was performed via lateral approach as previously described [7]. If the lateral collateral ligament is beyond the repair, stability was enhanced by two different techniques; 1) Circumferential wire prostheses, 2) Two screw and a figure-eight wire. In the first technique, 3 bone tunnels were created with a 2 mm drill; at the humeral condyl (lateral to medial), radial head (lateral to medial) and the mid-portion of the ulnar trachlear notch (lateral to medial) as previously described by Farrell et al. [4]. Then a 0.8 mm wire was passed through the humeral tunnel, a 1.2×40 mm injector cannula was inserted to tunnel at the radial head lateral to medial, the free end of the wire was passed through the cannula, after that cannula was removed. The same procedure was applied between the humeral and ulnar notch tunnels. The four free wire ends were tightened together at the lateral side of the joint. In the second technique a 2 mm cortical screw was placed one to humeral condyl and one to radial head, then the collateral ligament was replaced with figure-eight wire which placed between these 2 screws. Except the cases which the lateral collateral ligament was replaced with one of the defined techniques above, splinted bandage was applied to the cases as the elbow joint in extension position for 3 weeks postoperatively. In the cases which an implantation is performed, soft padded bandage was applied for 3 days postoperatively. The cage rest was recommended to all cases until postoperative 3rd week. Owners were contacted through telephone for long-term follow up until 5th month postoperatively.

RESULTS

Six cats with traumatic elbow luxation were included in this study. Detailed data of the cases is presented in the *Table 1*.

Four of the cats were male and two were female. Mean age was 20.66 months (range 3 to 49 months). Four of the

Table 1. Detailed data of the cases

Case No	Signalement	Traumatic Cause	Clinical Complaining	Surgical Method	Outcome
1	13 month intact male DSH	TA	3 days lameness	Open reduction	S
2	11 month intact male DSH	TA	7 days lameness	Open reduction	S
3	49 month intact male DSH	TA	10 days lameness	Open reduction, circumferential suture prostheses with wire	S
4	24 month intact female DSH	FH	Unable to bear weight for 1 day	Close reduction	S
5	3 month intact male DSH	TA	Unable to bear weight for 1 day	Close reduction	S
6	24 month spayed female DSH	FH	Unable to bear weight for 8 days	Open reduction, two screw and eight-shaped wire	S

DSH: domestic short hair, FH: falling from heigh, S: succesfull, TA: traffic accident

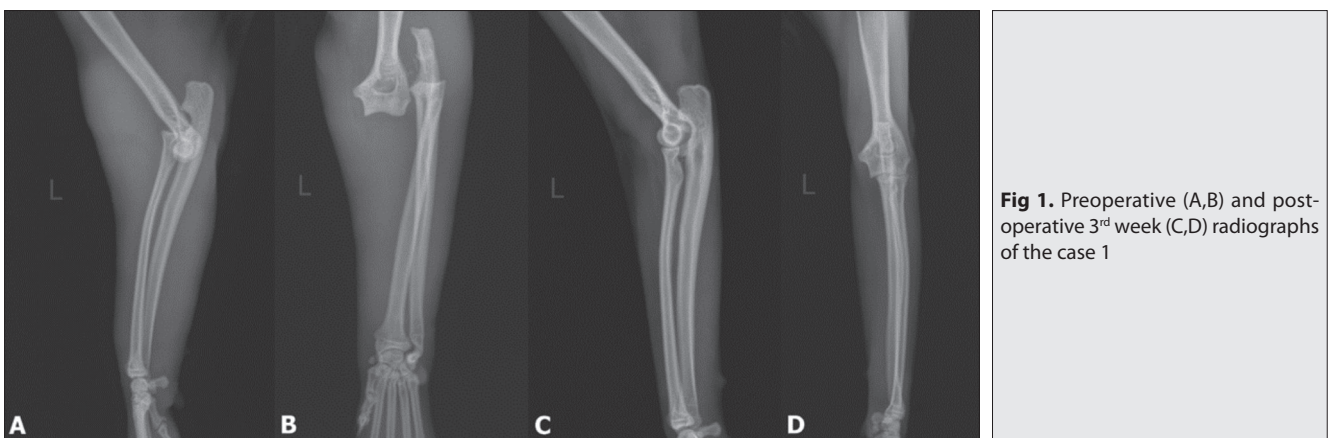


Fig 1. Preoperative (A,B) and post-operative 3rd week (C,D) radiographs of the case 1

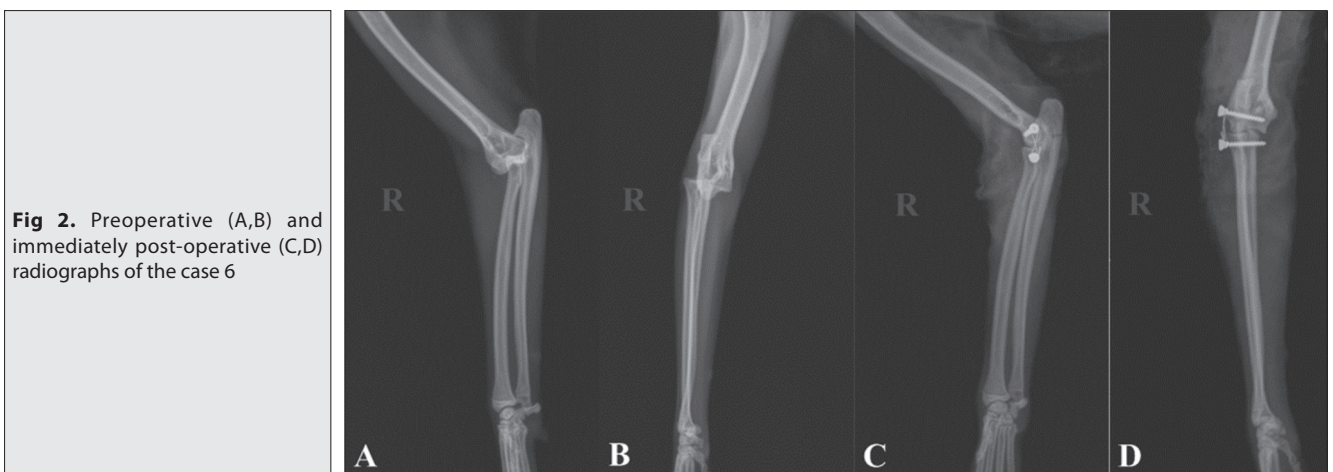

Fig 2. Preoperative (A,B) and immediately post-operative (C,D) radiographs of the case 6

cases (case 1, 2, 3 and 5) were outdoor cats which were kept in the owners' garden.

The cause of the trauma was traffic accident in four cases and falling from height in two cases. Clinical findings were that the animal is unable to bear its weight on the affected limb and the elbow is carried in a flexed position (In case 1 and 4 left; in case 2, 3, 5 and 6 right forelimb).

Lateral elbow luxation was diagnosed by means of clinical and radiologic examinations in all cats. In all cases after general anesthesia, treatment with closed reduction was

tried, but in four cases (case 1, 2, 3 and 6) it was not possible to achieve reduction with closed manipulation due to the muscle and joint contractures, so open reduction was performed. In case 1 and 2, avulsed lateral collateral ligament ends were apposed with 2/0 polypropylene suture in a locking-loop pattern, and the control x-rays that were taken immediately after the surgery showed that joint stability was successful in these two cases (Fig. 1).

In case 3, the stability was achieved using circumferential suture prostheses with wire. Two screw and a figure-eight wire was used to obtain the stability in case 6 (Fig. 2).

In case 4 and 5, closed reduction was performed. Because the cases were acute it was easy to achieve the reduction, control radiographs showed the stability of the joint. Although there was no complication in any of the cases after surgery, case 5 was died due to viral infection 1 month after surgery.

All cat owners except case 5 were contacted through telephone until the postoperative 5th month, no complaint related with the treated elbow joint was reported by the owners.

DISCUSSION

Dislocations of the elbow joint can occur congenitally or due to traumatic causes [6,10,16]. Although traffic accident is the most reported primary cause of the luxation in dogs, a data about the primary cause of the traumatic elbow luxation in cats is not available, because there is a small number of case reports in cats with traumatic elbow luxation [5,6]. In our study, the cause of the luxation was traffic accident in four cases (80%) and falling from height in two cases. Although there is no available case series in cats, these data is in accordance with previous literatures about the dogs. In Güzel et al.[2] study, the cause of trauma was reported as traffic accident in two of five cats and as falling from height in two of five cats. The difference between these two results may be due to the fact that four of the cats in our study were outdoor cats and they were more prone to a traffic accident.

Two-plane radiography was used for definitive diagnosis, and lateral luxation was diagnosed in all cats. The lateral luxation of the elbow is more common than medial luxation because of the fact that the medial condyle of the humerus is wide [6,7,11]. Also according to results of a cadaveric study by Farrell et al.[4], unless both medial and lateral collateral ligaments are transected, it is not possible to induce elbow luxation in cats. Also, the authors stated that the applied manual indirect rotational forces may not mimic the *in-vivo* condition as traffic accident or falling [4]. However, in our four cases which underwent the open reduction, the ruptured medial and collateral ligament were seen intraoperatively.

In this study, four of the subjected cases were chronic, so closed reduction was not successful due to joint and muscle contraction. In addition, the fibrosis of the ruptured ligaments and muscle fibrils prevented the treatment with closed reduction. In case 1 and 2 it was easy to achieve reduction despite the contraction of triceps brachii by open reduction. Nevertheless, in case 3 myotomy of this muscle was needed to perform the reduction. In case 3, a circumferential suture prostheses technique, which was defined by Farrell et al.[4], was chosen as a stabilization method. Farrell et al.[4,5] used braided polyblend suture as a prostheses, but we did not have this material in our clinics. Although we tried to stabilize the joint with

No:1 polypropylene suture material, it was not possible to stabilize the joint and the suture material ruptured, and then we preferred to use wire. Although there is no comparative biomechanical or clinical study about these 2 techniques, the result of our case may show that using wire is also acceptable in some selected cases. However, it is very difficult to make a conclusion by the means of only one case's results.

A splinted bandage was applied to cases that were treated with closed reduction and cage rest was recommended for three weeks postoperatively to prevent re-luxation. Bandage application in addition to limiting the movement of the animal is suggested most of the authors, however, a simple transarticular external skeletal fixator type IIa had been applied to maintain the stability of the joint and to prevent the re-luxation in cats with caudal elbow luxation in one study [17]. Even though bandage has some disadvantages, as most of the cats do not well tolerate and mostly sedation requirement for applying, it was well tolerated by the cats in our study. Compatible temperament of the cats in this study provided an advantaged as renewing the bandage without sedation.

In conclusion, when the closed reduction is unsuccessful for the treatment of traumatic elbow luxation or in chronic cases, open reduction was found satisfactory. Even though it is not possible to claim that circumferential wire prostheses can be used in cats with traumatic elbow luxation according to results of only one case, cadaveric studies can be done to compare these two implant material (suture and wire) and to evaluate the biomechanics of wire prostheses.

AUTHOR CONTRIBUTIONS

MS conceived and supervised the study. PC and AF collected and analyzed data, assisted MS in the operations. PC wrote the first draft of manuscript. All authors contributed to the critical revision of the manuscript for important intellectual content and have read and approved the final version.

REFERENCES

1. Valastro C, Di Bello A, Crovace A: Congenital elbow subluxation in a cat. *Vet Radiol Ultrasound*, 46, 63-64, 2005. DOI: 10.1111/j.1740-8261.2005.00012.x
2. Güzel Ö, Altunatmaz K, Şaroğlu M, Aksoy Ö: Traumatic luxations of the elbow in cats and dogs. *İstanbul Üniv Vet Fak Derg*, 32, 31-43, 2006.
3. Savoldelli D, Montavon PM, Suter PF: Die traumatische ellbogengelenkluxation bei Hund und Katze: Perioperative befunde. *Schweiz Arch Tierheilk*, 138, 387-391, 1996. DOI: 10.5169/seals-592641
4. Farrell M, Draffan D, Gemmil T, Mellor D, Carmichael S: *In vitro* validation of a technique for assessment of canine and feline elbow joint collateral ligament integrity and description of a new method for collateral ligament prosthetic replacement. *Vet Surg*, 36, 548-556, 2007. DOI: 10.1111/j.1532-950X.2007.00281.x
5. Farrell M, Thomson DG, Carmichael S: Surgical management of traumatic elbow luxation in two cats using circumferential suture prostheses. *Vet Comp Orthop Traumatol*, 22, 66-69, 2009. DOI: 10.3415/vcot-08-03-0026

- 6. Mitchell KE:** Traumatic elbow luxation in 14 dogs and 11 cats. *Aust Vet J*, 89, 213-216, 2011. DOI: 10.1111/j.1751-0813.2011.00718.x
- 7. Schulz KS, Hayashi K, Fossum TW:** Diseases of the joints. In, Fossum TW (Ed): Small Animal Surgery. 1193-1196, 5th ed., Elsevier, St. Louis, Missouri, USA, 2019.
- 8. O'Brien MG, Boudrieau RJ, Clark GN:** Traumatic luxation of the cubital joint (elbow) in dogs: 44 cases (1978-1988). *J Am Vet Med Assoc*, 201, 1760-1765, 1992.
- 9. Sajik D, Meeson RL, Kulendra N, Jordan CJ, James D, Calvo I, Farrell M, Kulendra E:** Multi-centre retrospective study of long-term outcomes following traumatic elbow luxation in 37 dogs. *J Small Anim Pract*, 57, 422-428, 2016. DOI: 10.1111/jsap.12499
- 10. Candaş A, Sağlam M, Kaya Ü, Bilgili H:** Köpeklerde travmatik articulatio cubiti lüksasyonlarında redüksiyon yöntemleri ve sonuçlarına ilişkin klinik çalışmalar. *Ankara Üniv Vet Fak Derg*, 45, 171-179, 1998.
- 11. Bongartz A, Carofiglio F, Piaia T, Balligand M:** Traumatic partial elbow luxation in a dog. *J Small Anim Pract*, 49, 359-362, 2008. DOI: 10.1111/j.1748-5827.2007.00511.x
- 12. Schaeffer IGF, Wolvekamp P, Meij BP, Theijse LFH, Hazewinkel HAW:** Traumatic luxation of the elbow in 31 dogs. *Vet Comp Orthop Traumatol*, 12, 33-39, 1999. DOI: 10.1055/s-0038-1632555
- 13. McCartney WT, Kiss K, McGovern F:** Surgical stabilisation as the primary treatment for traumatic luxation of the elbow joint in 10 dogs. *Intern J Appl Res Vet Med*, 8, 97-100, 2010.
- 14. Vedrine B:** Use of an elastic transarticular external fixator construct for immobilization of the elbow joint. *Can Vet J*, 58, 353-359, 2017.
- 15. Dean BL:** In dogs with traumatic elbow luxation, does treatment using closed reduction and conservative management have a better prognosis than those treated with open reduction and surgery? *Vet Evidence*, 2 (4): 1-19, 2017. DOI: 10.18849/ve.v2i4.128
- 16. Decamp CE, Johnston SA, Déjardin LM, Schaefer SL:** The elbow joint. In, Brinker, Piermattei and Flo's Handbook of Small Animal Orthopedics and Fracture Repair. 327-365, 5th ed., Elsevier, St. Louis, Missouri, USA, 2016.
- 17. Abrescia P, Cinti F, Pisani G:** Traumatic caudal elbow luxation in two cats. *Open Vet J*, 9 (4): 361-365, 2019. DOI: 10.4314/ovj.v9i4.14