

Ultrasonographic Examination of Sea Turtle Eyes (*Caretta caretta* and *Chelonioidas mydas*)

Cafer Tayer İŞLER^{1,2,a}

¹ Department of Surgery, Faculty of Veterinary Medicine, University of Mustafa Kemal, TR-31040 Hatay - TÜRKİYE

² Department of Sea Turtles First Aid, Treatment and Resque Research and Application Center (DEKİYM), University of Mustafa Kemal, TR-31040 Hatay - TÜRKİYE

^a ORCID: 0000-0002-1910-8316

Article ID: KVFD-2019-23805 Received: 20.12.2019 Accepted: 20.04.2020 Published Online: 20.04.2020

How to Cite This Article

İşler CT: Ultrasonographic examination of sea turtle eyes (*Caretta caretta* and *Chelonioidas mydas*). *Kafkas Univ Vet Fak Derg*, 26 (4): 521-524, 2020. DOI: 10.9775/kvfd.2019.23805

Abstract

Biometrical knowledge in both illness and health is important for correct diagnosis and treatment. There is little information on the biometric and disorders of sea turtles. In this study, we evaluated the use of orbital ultrasonographic examination in sea turtles (*Caretta caretta* and *Chelonioidas mydas*). We used 10-12 MHz probes to examine clinically healthy eyes in the 10 *Caretta caretta* and 10 *Chelonioidas mydas* through ocular ultrasonography. Polar axis, equatorial axis, corneal thickness, anterior chamber, lens thickness and vitreous chamber were all determined. Statistical differences in the sea turtle were noted in the corneal thickness ($P<0.01$). Statistical difference was not found between *Caretta caretta*, *Chelonioidas mydas* and right or left eyes in the measurements of polar diameter, equatorial diameter, corneal thickness, anterior camera, lens thickness, vitreous space. In this study, ultrasonographic findings of the eye of sea turtles were evaluated. These data are the first in terms of literature and therefore, it is important.

Keywords: Wild life, Sea turtle, *Caretta caretta*, *Chelonioidas mydas*, Eye, Ultrasonographic biometry

Deniz Kaplumbağaları (*Caretta caretta* ve *Chelonioidas mydas*) Gözlerinin Ultrasonografik İncelenmesi

Öz

Hem hastalıklı hem de sağlıklı göze ait biometrik bilgi doğru tanı ve tedavi için önemlidir. Deniz kaplumbağalarının biometrisi ve hastalıkları hakkında çok az bilgi vardır. Bu çalışmada, *Caretta caretta* ve *Chelonioidas mydas* kaplumbağa gözlerinin ultrasonografik muayene bulguları değerlendirildi. On *Caretta caretta* ve 10 *Chelonioidas mydas* klinik açıdan sağlıklı gözlerinin ultrasonografik muayenesi için, 10-12 MHz'lik prob kullanıldı. Polar çap, ekvatoryal çap, korneal kalınlık, ön kamera, lens kalınlığı ve vitröz boşluk değerlendirildi. *Caretta caretta* ve *Chelonioidas mydas* deniz kaplumbağaları gözleri arasında, istatistiksel fark korneal kalınlıkta ($P<0.01$) belirlendi. Polar çap, ekvatoryal çap, korneal kalınlık, ön kamera, lens kalınlığı, vitröz boşluğun ölçümlerinde hem *Caretta caretta*, *Chelonioidas mydas* türleri arasında hem de sağ veya sol gözleri ölçümleri arasında istatistiksel fark bulunamadı. Bu çalışmada deniz kaplumbağalarına ait gözün ultrasonografik bulguları değerlendirilmiştir. Bu veriler literatür açısından ilk veridir ve bu nedenle önemlidir.

Anahtar sözcükler: Yaban hayatı, Deniz kaplumbağaları, *Caretta caretta*, *Chelonioidas mydas*, Göz, Diagnostik ultrasonografi

INTRODUCTION

The species of sea turtle examined lives in the Mediterranean Sea of Greece, Turkey, Italy and Africa. The main nesting sites are on the Sicilian and Calabrian coasts. Both juvenile and adult sea turtles forage in these rich shallow local habitats^[1-3]. These animals are threatened and are in danger of extinction through the destruction of nesting

sites, the pollution of the seas, from fish-hooks and other foreign bodies, including plastic bags, from propeller injuries and accidents with fishermen or boats^[3-6]. Anatomical knowledge of the sea turtle using diagnostic imaging techniques can help to improve their preservation and their treatment following injury^[7-9]. The turtle's sense organs function both in the water and out of it and include the orbit, ear and cloaca, but biologists and veterinarians,



Correspondence



+90 507 0200401 Fax: +90 326 2455704



cafer.isler@gmail.com, caferisler@mku.edu.tr

as yet, have little information about them. Turtles suffering from ocular illness and injuries are brought into the rescue centres; therefore, a knowledge of anatomical orbital features is of high importance. Ultrasonography has already been used to identify normal biometrics in many other species [10-12]. The aim of this study was to use ultrasonography (US) to describe the normal anatomical features of the eyes of the sea turtle.

MATERIAL and METHODS

Forty sea turtles' eyes were examined by US. The *Caretta caretta* and *Chelonioidas mydas* species of sea turtles living along the Samandağ coast were used in this study. The ultrasonographic examinations were applied by one researcher and the study was authorised by the Republic of Turkey Ministry of Agriculture and Forestry (11.10.2019 date and 3121635 protocol number). After completion of the ophthalmic examination such as rutin clinicial and ophthalmoscopic examination, measurement of intra-ocular pressure, schirmer tear test, all the turtles were found to have normal eyes. First, all the animals were gently restrained manually. A topical anaesthetic was then administered (intravenous, 1-2 mg/kg diazem and 4-5 mg/kg propofol), and the B-mode US process was then applied. The eye is closed during the ultrasound examination and useful a gel. All eye examinations were done using ultrasound devices, equipped with a 12-MHz linear probe (MyLab30®) (Esaote, Florence, Italy) at the hospital centre. The probe (Sterile Aquasonic 100; Parker La. Inc., Fairfield, NJ, USA) was used in a horizontal and vertical position until optimal images were obtained for the corresponding US scans. The ocular parameters were: polar axis (PA), equatorial axis (EA), corneal thickness (CT), anterior chamber (AC), lens thickness (LT), vitreous chamber, distance between the anterior and the posterior capsules, the distance from the posterior capsule of the lens to the retinal surface, the distance from the posterior line of the cornea to the anterior capsule of the lens, the

distance between the two lines of the cornea, the maximal diameter perpendicular to the PA, and the distance from the corneal surface to the posterior wall of the retinal layer. These were all measured using the US device (Fig. 1).

Data collected were analysed using the SPSS programme and were reported as Mean ± SD in the 10 CC and 10 CM [13]. Differences between the CC and CM eyes in PA, EA, CT, AC, LT, were analysed with the t-test or the Mann Whitney U test. The level of statistical significance used was P<0.01.

RESULTS

The turtles were all adults and females. There is a retraction reflex in this species, and for this reason some difficulties were encountered. However, the US exam of the eye was successfully performed within three minutes for each turtle. The anatomical structures of the eye were examined through the ultrasonographic examination. The optic disc was not visible. Regular retinal fundus was seen. The vitreous chamber (VC) was anechoic. The anterior chamber was somewhat thin and had an anechoic area. The lens contained two hyperechoic convex lines, presenting as the anterior and posterior capsules. The scleral appeared as a shadowing artefact as two hyperechoic lines at the level of the limbus. The cornea was seen as a slight anterior convexity with two hyperechoic parallel lines.

The ultrasonographic ophthalmic measurements for the sea turtle are summarized in Table 1.

In this species; statistical differences were not identified between PA, EA, AC, LT and right or left eyes. Statistical differences between the CC and CM eyes of the sea turtles were identified in CT (P<0.01).

DISCUSSION

In the sea turtle, the eye is placed dorsally and laterally in the skull [14], there are three keratinized eyelids, the dorsal

Fig 1. Loggerhead eye with the measurements performed and Ultrasonographic image of the Loggerhead eye; Legend 1= corneal thickness; Legend A = anterior chamber depth; B = lens thickness; C = vitreous chamber depth; D = polar axis; E = equatorial axis; 1 = cornea; 2 = scleral ossicle; 3 = anterior chamber; 4 = anterior capsule of the lens; 5 = posterior capsule of the lens; 6 = vitreous body; 7 = retinal layer; 8 = scleral cartilage; 9 = artifact shadowing from scleral ossicle; 10 = salt gland

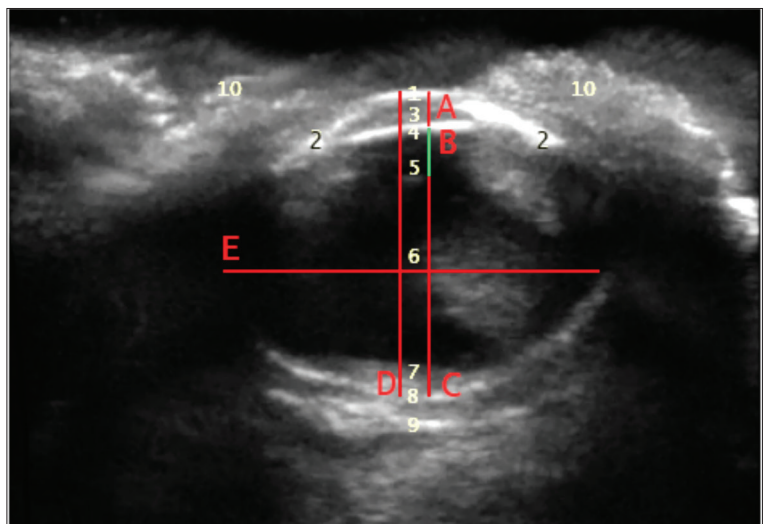


Table 1. Ultrasonographic ophthalmic measurements in the sea turtle

Measurement of the Eye	<i>Caretta caretta</i>	<i>Chelonioidas mydas</i>
Polar axis	17.61±2.71	17.30±2.33
Equatorial axis	20.81±3.90	21.13±3.01
Corneal thickness ^a	0.81±0.35 ^a	0.63±0.11 ^a
Anterior chamber	0.86±0.10	0.84±0.148
Lens thickness	4.60±0.50	4.50±0.50
Vitreous chamber	10.12±1.01	10.65±1.18

^aStatistical difference between the CC and CM eyes of the sea turtles (P<0.01)

and ventral eyelids are mobile, the medial lid (secondary lid) is non-mobile [15,16]. The ocular globe is formed by three layers: 1) the sclera and the cornea, formed by connective tissue; 2) the intermediate and vascularized layer, the uvea; and 3) the inner sensory layer, the retina. Differing from other animals, in addition there are two supporting structures: posteriorly the scleral cartilage and anteriorly the scleral ossicle [16-18]. The study using US was very easy to perform but the scleral ossicle and the retraction reflex did give some difficulties. There are good correlations between the eye dimensions. This study determined the normal ocular ultrasonographic features of the sea turtle. We learned that the orbit has a polar axis that is shorter than the equatorial in addition to a slight corneal curvature, a very thin anterior chamber and a relatively small lens. The orbit and the equatorial border of the lens do not permit complete visualization due to the shadowing artefact of the scleral ossicle. This muscle determines the movement of the sclera towards the inside and the outside of the eye within its orbit.

Sea turtles can be affected by many eye diseases, which can make the anterior portions of the eye opaque, and these situations prevent normal ophthalmic examination [14,17-19]. Ultrasonography allows the evaluation of the direct visualization resulting from any disease that causes ocular opacity.

The results of Brudenall et al. [16] and Raposo et al. [10] are very close to each other and one of them reported in Leatherback sea turtle in post mortem examination. They reported significant differences among CT, anterior chamber depth, lens thickness, vitreal cavity depth (P<0.001). Our results may be slightly higher than those of the reported since our results were reported in healthy sea turtles under anesthesia. We found a statistically significant difference between the CC and CM in the CT (P<0.001). This finding is first reported in the world.

We conclude that the technique of ultrasonographic evaluation is very useful for studying the eye in this species. The ultrasonographic features are useful for clinical evaluation and for presenting reliable information on the normal dimensions and intraocular anatomy of sea turtles' eyes. Use of the 10-12 MHz probes in US allows images to

be obtained of all ocular structures. Ultrasonographical examination of the orbit should become routine in the technic of clinical examination. Diagnosis of diseases causing disruption of the normal biometry of the eye can be easily made using US.

REFERENCES

- Mingozzi T, Masciari G, Paolillo G, Pisani B, Russo M, Massolo A:** Discovery of a regular nesting area of loggerhead turtle *Caretta caretta* in southern Italy: A new perspective for national conservation. *Biodivers Conserv*, 16, 3519-3541, 2007. DOI 10.1007/s10531-006-9098-6
- Hochscheid S, Travaglini A, Maffucci F, Hays GC, Bentivegna F:** Since turtles cannot talk: What beak movement sensors can tell us about the feeding ecology of neritic loggerhead turtles, *Caretta caretta*. *Mar Ecol*, 34, 321-333, 2013. DOI: 10.1111/maec.12018
- Maffucci F, D'Angelo I, Hochscheid S, Ciampa M, De Martino G, Travaglini A, Treglia G, Bentivegna F:** Sex ratio of juvenile loggerhead turtles in the Mediterranean Sea: Is it really 1:1. *Mar Biol*, 160, 1097-1107, 2013. DOI: 10.1007/s00227-012-2160-x
- Lazar B, Gracan R:** Ingestion of marine debris by loggerhead sea turtles, *Caretta caretta*, in the Adriatic Sea. *Mar Pollut Bull*, 62, 43-47, 2011. DOI: 10.1016/j.marpolbul.2010.09.013
- Santos RG, Andrades R, Boldrini MA, Martins AS:** Debris ingestion by juvenile marine turtles: An underestimated problem, *Mar Pollut Bull*, 93, 37-43, 2015. DOI: 10.1016/j.marpolbul.2015.02.022
- De Majo M, Macri F, Masucci M, Coci G, Pennisi MG:** Clinical ultrasonography in loggerhead sea turtles (*Caretta caretta*): Imaging of pathological features. *Vet Med-Czech*, 61, 155-161, 2019. DOI: 10.17221/8767-VETMED
- Franchini D, Valastro C, Ciccarelli S, Caprio F, Lenoci D, Di Bello A:** Ultrasonographic detection of ingested fishing lines in loggerheads (*Caretta caretta*). *J Wildl Dis*, 54 (4): 680-690, 2018. DOI: 10.7589/2017-12-302
- Valente AL, Cuenca R, Parga ML, Lavín S, Franch J, Marco I:** Cervical and coelomic radiologic features of the loggerhead sea turtle, *Caretta caretta*. *Can J Vet Res*, 70, 285-290, 2006.
- Crognale MA, Eckert SA, Levenson DH, Harms CA:** Leatherback sea turtle *Dermochelys coriacea* visual capacities and potential reduction of bycatch by pelagic longline fisheries. *Endang Species Res*, 5, 249-256, 2008. DOI: 10.3354/esr00112
- Raposo ACS, Muramoto C, Pires TT, Dòrea Neto FA, Brito VJSC, Orià AP:** Normal sonographic aspects of the eye in healthy sea turtles. *Vet Ophthalmol*, 20, E1-E14, 2017. DOI: 10.1111/vop.12498
- Somma AT, Lima L, Lange RR, Turner-Giannico A, Montiani-Ferreira F:** The eye of the red-eared slider turtle: Morphologic observations and reference values for selected ophthalmic diagnostic tests. *Vet Ophthalmol*, 18, 61-70, 2015. DOI: 10.1111/vop.12213
- Williams SR, Dennison S, Dunnigan B, Moore B, Nicholson J, Zagzebski K, Ketten D, Cramer S, Arruda J:** Diagnosis and management of intestinal partial obstruction in a loggerhead turtle (*Caretta caretta*). *J Zoo Wildl Med*, 44 (2): 457-461, 2013. DOI: 10.1638/2011-0179R1.1

13. Boyacıođlu H, Güneri P: Sağlık arařtırmalarında kullanılan temel istatistik yöntemler. *Hacettepe Diřhekimliđi Fak Derg*, 30, 33-39, 2006.

14. Wyneken J: The Anatomy of Sea Turtles. 1-172,. U.S. Department of Commerce NOAA Technical, Memorandum NMFS-SEFSC-470, National Marine Fisheries Service, Southeast Fisheries Science Center, Miami, 2001.

15. İşler CT, Altuđ M, Cantekin Z, Özsoy řY, Yurtal Z, Deveci MZY: Evaluation of the eye diseases seen in loggerhead sea turtle (*Caretta caretta*). *Revue Méd Vét*, 165 (9-10): 258-262, 2014.

16. Brudenall DK, Schwab IR, Fritsches KA: Ocular morphology of the Leatherback sea turtle (*Dermochelys Coriacea*). *Vet Ophthalmol*, 11, 99-

110, 2008. DOI: 10.1111/j.1463-5224.2008.00607.x

17. Altuđ ME, İşler CT, Yurtal Z, Deveci MZY, Kırgız Ö: Deniz kaplumbađalarında ilk yardım ve rehabilitasyon. *Türkiye Klinikleri J Vet Sci*, 8 (1-2): 42-50, 2017. DOI: 10.5336/vetsci.2017-59219

18. MacKay CS, Mattoon JS: The eye. In, Mattoon JS, Nyland TG (Eds): Small Animal Diagnostic Ultrasound. 3rd ed., 128-154, Saunders, Elsevier. St. Louis, Missouri, 2015.

19. İşler CT, Altuđ ME, Seçer FS, Cantekin Z: Treatment of bath with enrofloxacin in red-eared slider (*Trachemys scripta elegans*) suffer from conjunctivitis and its results. *Kafkas Univ Vet Fak Derg*, 21 (3): 429-431, 2015. DOI: 10.9775/kvfd.2014.12621