

Effects of Ozone and L-Carnitine on Kidney MDA, GSH, and GSHPx Levels in Acetaminophen Toxicity

Hüseyin Avni EROĞLU^{1,a} Mustafa MAKAV^{2,b} Yasemen ADALI^{3,c} Mehmet ÇİTİL^{4,d}

¹ Çanakkale Onsekiz Mart University, Departments of Physiology, Faculty of Medicine, TR-17110 Çanakkale - TURKEY

² Kafkas University, Departments of Physiology, Faculty of Veterinary Medicine, TR-36100 Kars - TURKEY

³ Çanakkale Onsekiz Mart University, Departments of Pathology, Faculty of Medicine, TR-17110 Çanakkale - TURKEY

⁴ Erciyes University, Departments of Internal Diseases, Faculty of Veterinary Medicine, TR-38280 Kayseri - TURKEY

^a ORCID: 0000-0002-1040-3255; ^b ORCID: 0000-0003-1879-8180; ^c ORCID: 0000-0002-8004-7364; ^d ORCID: 0000-0001-9839-7533

Article ID: KVFD-2019-22456 Received: 11.04.2019 Accepted: 06.08.2019 Published Online: 05.09.2019

How to Cite This Article

Eroğlu HA, Makav M, Adalı Y, Çitil M: Effects of ozone and L-carnitine on kidney MDA, GSH, and GSHPx levels in acetaminophen toxicity. *Kafkas Univ Vet Fak Derg*, 26 (1): 127-134, 2020. DOI: 10.9775/kvfd.2019.22456

Abstract

This study aimed to determine the therapeutic effects of medical ozone and L-carnitine therapy on acetaminophen (APAP)-induced kidney damage by evaluating malondialdehyde (MDA), glutathione (GSH), and GSHPx levels. In this study, 56 rats were randomized into 8 groups with 7 rats in each group. Kidney injury was induced by the administration of a single dose N-acetyl-p-aminophenol (1 g/kg) orally. Therapeutic ozone (0.7 mg/kg) and L-carnitine (500 mg/kg) were administered intraperitoneally. After the therapy, the rat kidneys were homogenized, and the tissue MDA, GSH, and GSHPx levels were measured. Compared to the control groups, there were higher MDA levels in the kidney tissues only in the "APAP", "APAP + Ozone", and "APAP + Ozone + L-carnitine" groups ($P < 0.001$). Besides, the decrease in the GSH and GSHPx levels of the kidney tissues in the study groups were significant compared to the control groups, and the highest decreases were observed in the "APAP", "APAP + Ozone" and "APAP + Ozone + L-carnitine" groups ($P < 0.001$). Findings obtained from this study revealed that acetaminophen toxicity caused oxidative damage in the examined kidney tissues, and L-carnitine and/ or ozone applications for protective purposes decreased MDA levels, a product of lipid peroxidation, and increased tissue GSH levels thru GSHPx antioxidant enzyme activity. In this context, the most important protective effect was observed in the group where L-carnitine and ozone were administered together.

Keywords: Acetaminophen, Ozone, L-Carnitine, Nephrotoxicity

Asetaminofen Toksisitesinde Ozon ve L-Karnitinin Böbrek MDA, GSH ve GSHPx Düzeylerine Etkisi

Öz

Bu çalışmada, malondialdehit (MDA), glutatyon (GSH) ve GSHPx seviyelerini değerlendirerek tıbbi ozonve L-Karnitin tedavisinin asetaminofen (APAP) kaynaklı böbrek hasarı üzerindeki terapötik etkilerinin belirlenmesi amaçlanmıştır. Çalışmada 56 adet rat her bir grupta 7 tane olmak üzere toplam 8 gruba ayrılmıştır. Böbrek hasarı N-acetyl-p-aminopenol'ün (1 g/kg) oral yolla tek doz uygulamasıyla oluşturulmuştur. Terapotik olarak kullanılan ozon (0.7 mg/kg) ve L-karnitine (500 mg/kg) intraperitoneal yolla uygulanmıştır. Daha sonra ratların böbrekleri homojenize edilerek doku MDA, GSH ve GSHPx değerleri ölçülmüştür. Çalışma gruplarında böbrek dokusu MDA düzeylerinin yalnızca APAP, APAP + Ozon ve APAP + Ozon + L-karnitin uygulanan gruplardaki artışlarının kontrol amaçlı kullanılan tüm gruplara göre istatistiksel olarak anlamlı ($P < 0.001$) olduğu saptanmıştır. Ayrıca çalışma gruplarında böbrek dokusu GSH ve GSHPx düzeylerinin yalnızca APAP, APAP+Ozon ve APAP + Ozon + L-karnitin uygulanan gruplardaki düşüşlerin kontrol amaçlı kullanılan tüm gruplara göre istatistiksel olarak anlamlı ($P < 0.001$) olduğu ve en yüksek düşüşlerin ise yalnızca APAP verilen grupta olduğu belirlenmiştir. Çalışmadan elde edilen bulgular asetaminofen toksikasyonun incelenen böbrek dokularında oksidatif hasarlara yol açtığı, koruyucu amaçla L-karnitin ve/veya ozon uygulamalarının dokularda lipid peroksidasyon ürünü olan MDA düzeylerini düşürdüğü ve antioksidan enzimlerden GSHPx aktivitesi ile doku GSH düzeylerini artırdığı tespit edilmiştir. Bu bağlamda en önemli koruyucu etkinin L-karnitin ve ozonun beraber uygulandığı grupta izlendiği dikkati çekmiştir.

Anahtar sözcükler: Asetaminofen, Ozon, L-karnitin, Nefrotoksisite

INTRODUCTION

Acetaminophen (paracetamol-APAP) is widely used for its analgesic and antipyretic effects. Although it is a trusted

medication, frequent cases of intoxications^[1], as well as, suicide attempts are observed due to its easy accessibility. The most important toxic effects of APAP occur on the liver and kidneys^[2]. Elimination of this molecule occurs from the



İletişim (Correspondence)



Mobile: +90 532 4958285



haeroglu@comu.edu.tr

liver via sulfation (20-46%) and glucuronidation (40-67%)^[3]. When an overdose of APAP is taken, rapid glucuronidation and sulfation mechanism ensue, swiftly depleting glutathione (GSH) levels. Under normal conditions, this intermediate product is detoxified by conjugation with GSH and is metabolized to mercapturic acid and excreted by the kidneys (<5%). However, if toxic doses are taken, hepatic GSH, an important factor in the antioxidant defense of the body, decreases by more than 70%. When the hepatic GSH reserves decrease by more than 30%, the reactive intermediate N-acetyl p-benzoquinone (NAPQI) binds to hepatic macromolecules by covalent linkage and inhibits the function of enzymatic systems in the liver. As a result, the increased amount of active metabolite NAPQI exceeds the binding (detoxifying) capacity of glutathione and cannot be excreted via GSH, and thus, it binds to cytosol proteins in the tissues and leads to cell necrosis^[2,4,5]. Although 1-2% renal insufficiency was reported after high-dose APAP use^[6], the exact mechanism of nephrotoxicity could not be clearly elucidated. It is thought that inflammation and GSH decrease in the kidneys may be related to oxidative stress^[7]. It is claimed that in most cases of APAP toxication, nephrotoxicity develops after hepatotoxicity.

Free radicals are electron acceptor molecules in biological systems that arise as a degradation product in the aldehyde structure by the breakdown of carbon bonds during the peroxidation of lipids^[8]. As a result, they cause mutagenic, genotoxic, and carcinogenic damage in the cells by affecting the structure and function of molecules, cell membrane, genetic materials such as DNA, RNA, and various enzymatic events. Malondialdehyde (MDA), one of the most important end products of lipid peroxidation, is known to be one of the most sensitive indicators of lipid peroxidation during oxidation^[9,10].

Reduced GSH, ceruloplasmin, transferrin, and ascorbic acid (vitamin C) used in reducing hydrogen peroxide as well as antioxidant enzymes such as superoxide dismutase (SOD), catalase (CAT), glutathione peroxidase (GSHPx), glutathione S-transferase (GST), and antioxidants such as alpha-tocopherol are used in the cells for reducing and neutralizing the harmful effects of free radicals in the organism^[11]. GSH is a compound that can easily release hydrogen ions. Because of the sulfur groups it contains, GSH plays a significant role in the protection of the tissues from peroxidative effects. GSH can also serve as a reductant by reducing oxidized glutathione (GSSG) and reducing hydrogen peroxide and lipid hydroperoxides directly to H₂O. Intracellular GSH is consumed under continuous intracellular oxidative stress conditions. The depletion of intracellular GSH causes oxidation and damage of lipids, proteins, and DNA by reactive oxygen species (ROS)^[12]. Additionally, also the glutathione peroxidase enzyme (GSHPx) is involved in the elimination of peroxidative damage. The increase of free oxygen radicals in tissues disrupts the balance between the prooxidant and antioxidant system and causes oxidative

stress by affecting the enzymatic and non-enzymatic antioxidant defense mechanisms in the cells^[11]. The level of oxidative stress is determined by evaluating the decreases in the quantity of antioxidants or increases in their metabolites^[13].

L-carnitine is an amino acid-like compound that is synthesized in liver and kidneys and plays an important role in the β -oxidation of long-chain fatty acids in the mitochondria. L-carnitine, however, helps the organism by acting as a buffer for excess acyl-Co A, which may be harmful to the cells^[14]. Many studies have demonstrated that L-carnitine, which is an important cofactor in fatty acid metabolism, can improve the antioxidant status in mice and rats by accelerating the removal of free radicals from cells and has a strong antioxidant effect on lipid peroxidation^[15-17].

The application of the ozone/oxygen gas mixture is defined as ozone therapy^[18]. In clinical studies, ozone therapy has been found to be useful in cases such as peritonitis, infected wounds, chronic skin ulcers, burns, ischemic diseases, necrotic enterocolitis, and acute necrotic pancreatitis^[19-22]. Ozone is readily soluble in biological fluids such as plasma, lymph, and urine, and reacts immediately with polyunsaturated fatty acids, antioxidants, reduced GSH, and albumin. These compounds act as electron donors and undergo oxidation resulting in the formation of hydrogen peroxide (H₂O₂) and lipid oxidation products. H₂O₂, an essential ROS molecule, can act as an ozone messenger to reveal its various biological and therapeutic effects^[22]. Free radicals are important for the emergence of the biological effects of ozone because free radicals are sometimes starting agents in chemical reactions, sometimes interfering in the intermediate steps, or resulting from the reaction of reagents. It is evident that ozone activates the antioxidant defense system in living beings against the effects of free radicals as a result of increasing the free radicals by creating an oxidative effect^[23]. Studies have shown that ozone increases the activity of antioxidant enzymes such as GSHPx, SOD and CAT in physiopathological conditions in which ROS occur^[24]. In a study conducted in 2010 Demirbag et al.^[25], reported that high-dose APAP applications lead to renal damage and ozone therapy has a curative effect on renal damage caused by APAP toxicity.

In this study, we aimed to determine whether L-carnitine and ozone applications have protective and/or therapeutic properties in kidneys with experimental APAP toxication, and tried to measure the tissue levels of GSHPx, a potent antioxidant enzyme, MDA an end product of lipid peroxidation, and reduced GSH.

MATERIAL and METHODS

Ethical Approval

All procedures performed in studies involving animals were

in accordance with the ethical standards of the institution or practice at which the studies were conducted (Ethical approval: KAÜ-HADYEK- 2018/42).

Animals

Fifty-six female Wistar Albino Rats aged 4-6 months and weighing 190-250 g were used in this study. The rats were obtained from the Atatürk University Experimental Animals Breeding Unit, and housed individually in plastic cages in a ventilated and temperature-controlled room at 25°C with a 12 h light-12 h dark cycle, and fed as *ad-libitum*.

Experimental Design

Animals were randomized into eight groups according to their weights making seven rats in each group.

The groups were;

Control group: Received only 0.9% NaCl orally.

Ozone group: O₃ (0.7 mg/kg) administered intraperitoneally [21].

L-carnitine group: L-carnitine (500 mg/kg) administered intraperitoneally [17].

Ozone + L-carnitine group: O₃ (0.7 mg/kg) intraperitoneally and L-carnitine (500 mg/kg) administered intraperitoneally.

APAP group (2nd Control): Damage caused by a single dose N-acetyl-p-aminophenol (1 g/kg) administered orally [7].

APAP + Ozone group: Damage caused by a single dose N-acetyl-p-aminophenol (1 g/kg) administered orally followed by intraperitoneal O₃ (0.7 mg/kg).

APAP + L-carnitine group: Damage caused by a single dose N-acetyl-p-aminophenol (1 g/kg) administered orally followed by intraperitoneal L-carnitine (500 mg/kg) administered one h later.

APAP + Ozone+ L-carnitine group: Damage caused by a single dose N-acetyl-p-aminophenol (1 g/kg) administered orally followed by intraperitoneal O₃ (0.7 mg/kg) and L-carnitine (500 mg/kg) administered one h later.

At the end of the study, the animals were not fed overnight. 24 h after the last administration sacrifice was performed with cervical vertebra dislocation under ethical rules. Blood and tissue samples were obtained after sacrifice. The renal tissue samples were collected in 10% formaldehyde for pathological examinations.

Ozone Administration

Ozone used in the study was obtained from Kafkas University Health Research and Application Hospital Medical Ozone Generator (Blue Medical Ozone Generator, Turkozone/TR). The ozone gas (oxygen 95%, ozone 5%), which was taken into the 20 mL injectors just before the application, was transferred to the application area with the airtight part up to prevent ozone from volatile. During the application, 26 Gauge (13 mm) injector tip was used.

Tissue Biochemical Analysis

Malondialdehyde, GSH, and GSHPx levels were analyzed from the renal tissue samples. Kidneys were harvested, and the tissues were rinsed with 0.9% NaCl. Tissues were homogenized in phosphate buffer (pH 7.4) in 0.1 M KCl, and the homogenates were centrifuged at 1500 rpm for 5 min. All samples were stored at -25°C until analysis. Analyses for GSH and MDA concentrations were carried out by the methods described by Beutler et al. [28] and Yoshiko et al. [29], respectively.

Histopathological Examination

For histopathological examinations, fixation was achieved by keeping the kidney tissues in 10% formaldehyde for 24 h. Concomitantly, the kidneys were put into histology cassettes and left for tissue follow-up. Using a microtome, sections of 4-micron thickness were taken from the paraffin blocks, stained with hematoxylin-eosin, and evaluated under a light microscope. For the evaluation, a 4-point scoring system (0=none, 1=mild, 2=moderate, 3=severe) was used for vascular congestion, glomerular damage, tubulointerstitial inflammation, and tubular damage.

Statistical Analysis

Statistical analysis of all data obtained from the study was performed with the SPSS for Windows, version 10.0 program. Statistical differences between the groups were tested by analysis of variance (ANOVA) and Tukey's test. Data were presented as mean±standard errors, and P values less than 0.05 were considered significant. As the significance level was accepted as P<0.05 a total of 7 subjects in each group corresponds to a power of about 80%. We conducted a normality test with the data and subsequently conducted ANOVA analyses when no evidence of deviation from the normality. We did not detect any deviations from the normality.

RESULTS

The levels of MDA, GSH, and GSHPx in the kidney tissues are shown in *Table 1*.

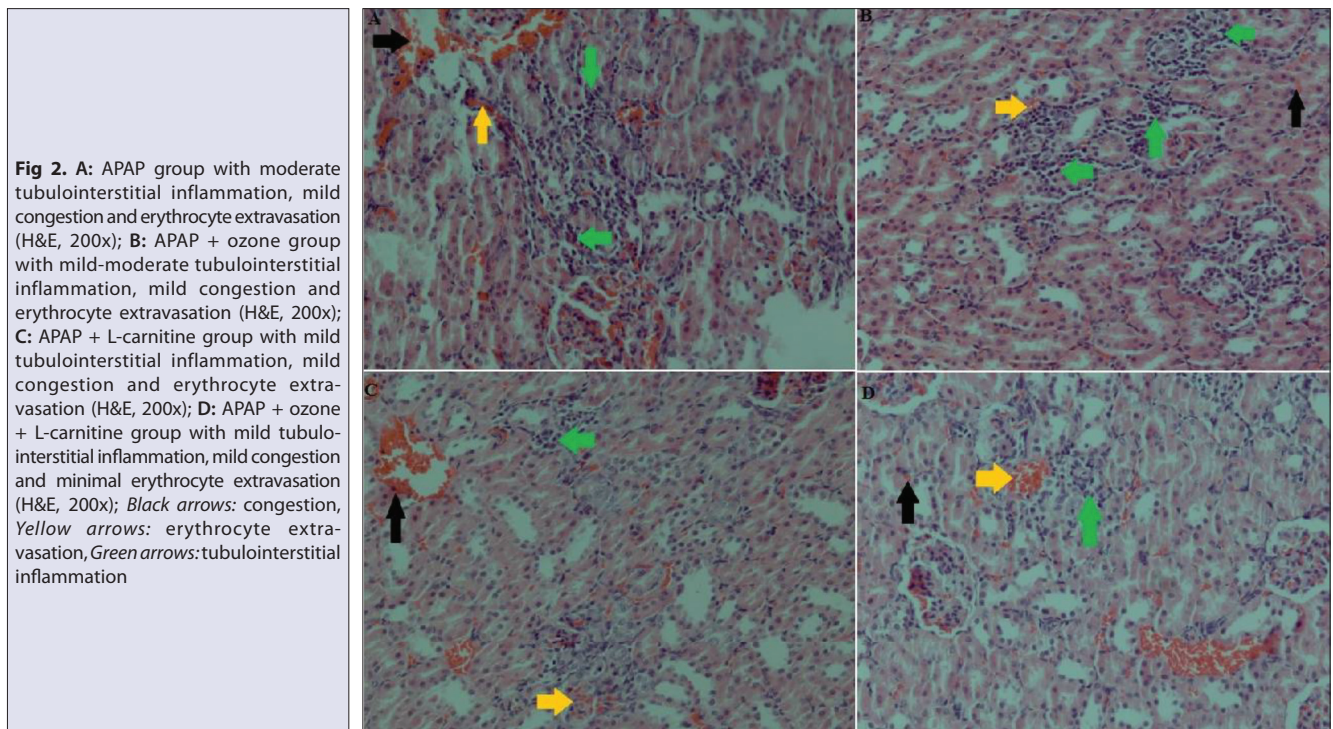
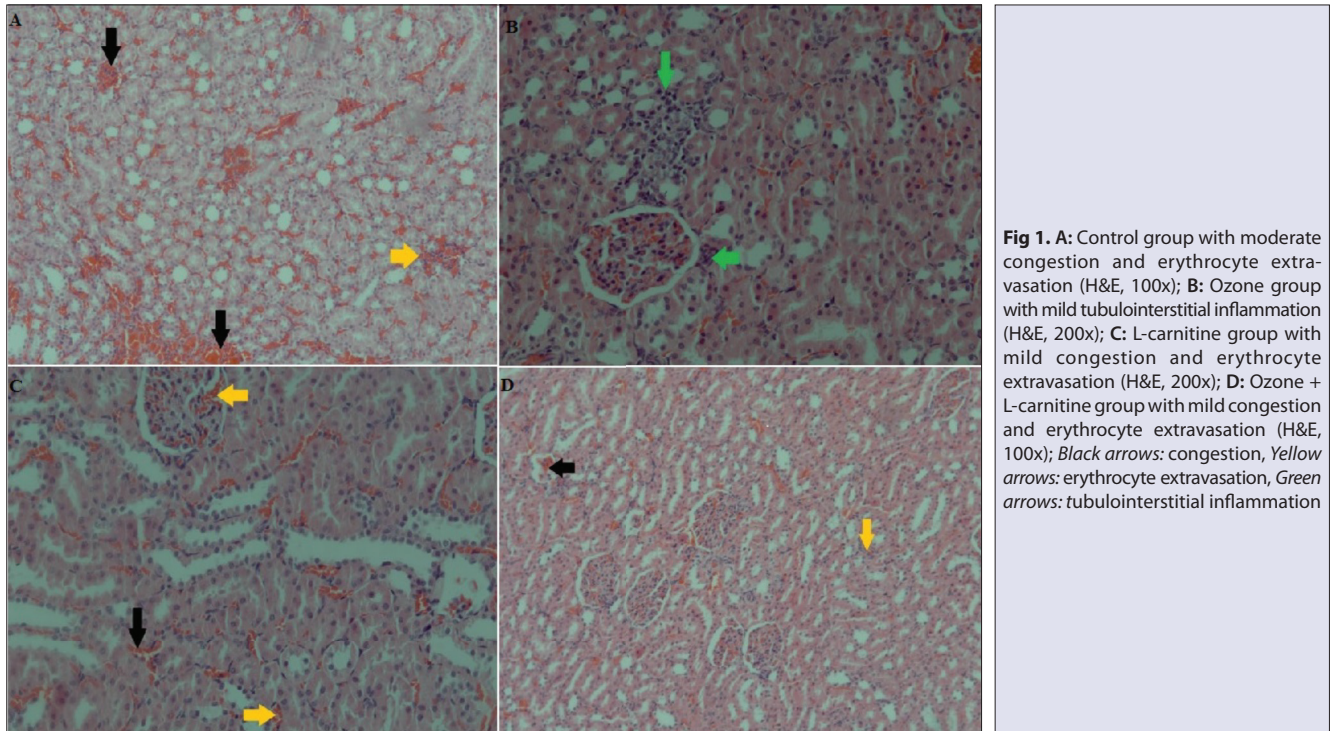
Statistically significant difference was observed in the MDA levels in the APAP, APAP + Ozone, and APAP + Ozone + L-carnitine groups compared to the control groups (control, Ozone alone, L-carnitine, and Ozone + L-carnitine) (p<0.001), and the highest increase was seen in the APAP-only group (*Table 1*).

Statistically significant difference was observed in the GSH and GSHPx levels in the APAP, APAP + Ozone, and APAP + Ozone + L-carnitine groups compared to the control groups (control, Ozone alone, L-carnitine, and Ozone + L-carnitine) (P<0.001), and the highest decrease was seen in the APAP-only group (*Table 1*).

Table 1. The levels of MDA, GSH, and GSHPx in the kidney tissues

Parameters	Control	Ozone	L-Carnitine	Ozone + L-Carnitine	APAP	APAP + Ozone	APAP + L-Carnitine	APAP + Ozone + L-Carnitine	P
MDA (nmol/g)	1.58±0.13 ^c	1.60±0.11 ^c	1.54±0.10 ^c	1.50±0.13 ^c	2.30±0.17 ^a	1.96±0.12 ^b	1.90±0.03 ^b	1.83±0.09 ^b	<0.001
GSH (nmol/g)	4.39±0.13 ^a	4.42±0.11 ^a	4.45±0.09 ^a	4.40±0.14 ^a	3.09±0.13 ^c	3.61±0.18 ^b	3.75±0.12 ^b	3.80±0.17 ^b	<0.001
GPx (U/g)	0.49±0.05 ^a	0.43±0.06 ^a	0.51±0.06 ^a	0.47±0.02 ^a	0.26±0.01 ^c	0.37±0.04 ^b	0.39±0.03 ^b	0.34±0.05 ^b	<0.001

MDA: malondialdehyde; GSH: glutathione; GSHPx: glutathione peroxidase; APAP: acetaminophen; ^{a,b,c,d} show statistical significance between groups per line (P<0.05)



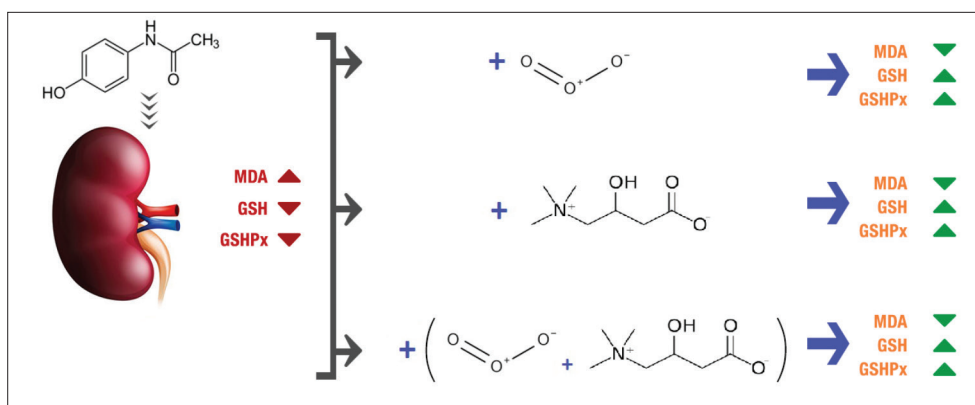


Fig 3. Summary of the results

A significant difference was found between APAP group and APAP + Ozone, APAP + L-carnitine and APAP + Ozone + L-carnitine groups in terms of MDA, GSH and GSHPx levels ($P < 0.001$). Considering this analysis the mean of MDA levels were observed as: APAP > APAP + Ozone > APAP + L-carnitine > APAP + Ozone + L-carnitine; the mean of the GSH levels were APAP + ozone + L-carnitine > APAP + L-carnitine > APAP + ozone > APAP; and lastly the mean levels of the GSHPx were APAP + L-carnitine > APAP + Ozone > APAP + Ozone + L-carnitine > APAP respectively.

Histopathological examinations revealed mild vascular congestion, which was attributed to the procedure. While tubular damage was not observed in any of the cases (Fig. 1A-D), the APAP group was noticed as having the most prominent tubulointerstitial inflammation (Fig. 2A). Concerning the frequency and extent of the tubulointerstitial inflammation, the "APAP" group had intermediate-level tubulointerstitial inflammation in all cases, followed by "APAP + Ozone", "APAP + Ozone + L-carnitine," and "APAP + L-carnitine" groups (Fig. 2B-D). In the evaluation of the control groups, mild tubulointerstitial inflammation was observed only in one case in the ozone group (Fig. 1B).

Summary of the results is shown in Fig. 3.

DISCUSSION

This study was designed to evaluate the effects of L-carnitine and ozone on kidney tissues exposed to APAP-induced oxidative damage. Single-dose APAP (1 g/kg) administration is used according to Ucar et al.^[7] in order to induce renal damage. APAP, L-carnitine (500 mg/kg), and ozone (0.7 mg/kg) were given to rats, and at the end of the experiment, kidney tissues were collected for the evaluation of oxidative damage and histopathological examination. Oxidative stress caused by APAP toxicity has been evidenced by increased levels of MDA and decreased levels of GSH and GSHPx activity following APAP administration. Single dose of ozone administration is shown to be effective for APAP induced hepatotoxicity^[26] and L-carnitine for oxidative damage^[27].

Long-chain unsaturated fatty acids are involved in a series of reactions with free radicals, resulting in lipid peroxidation and the degradation of membrane lipids into lower molecular weight moieties such as hydrocarbons, ketones, and epoxides. Determination of lipid peroxidation is a key marker of oxidative stress, and MDA formation is the most important oxidation by-product of lipid degradation, which can indicate the degree of lipid peroxidation in many organs^[30]. In this study, the levels of MDA increased significantly in tissue samples of rats treated with APAP. These findings are similar to the results of other studies where increased tissue MDA levels were reported^[31,32] after the application of some toxic substances in mice and rats.

Glutathione peroxidase, SOD, CAT, and GST are cellular antioxidant enzymes playing essential roles in the destruction of free radicals and the prevention of oxidative damage. These enzymes have a balance under normal physiological conditions and give an initial response to oxidative damage in tissues. Reduced GSH is a vital member of the antioxidant system and contributes to the cellular defense against oxidative damage through the formation of creatinine S-substituted GSH by reacting with toxic substances^[31]. Because GSH is an important antioxidant with a significant cleansing function against ROS, it acts as an important redox buffer to stabilize the cellular redox state. It has been reported that GSH acts as an electron donor in protecting toxic substances from oxidative damage by promoting methylation of toxic substances to less toxic metabolites^[31] and making toxic substances less harmful^[33], which can significantly improve the production of hydroxyl radicals^[17]. In our study, it was observed that APAP administration caused a significant decrease in GSH activity in the renal tissue samples. These findings are consistent with previous studies^[31,34], which reported significant reductions of GSH levels in mice and rats exposed to various toxic substances. We share the opinion that decreases in GSH levels in animals exposed to toxicity may be due to the use of GSH as a cofactor by GST and by the use of GSH during cellular protection against oxidative stress to prevent oxidative

damage and to sustain the cellular redox state due to the suppression of this antioxidant enzyme [35].

In this study, it was shown that L-carnitine administration decreases MDA levels in renal tissue samples and increases reduced GSH and GSHPx levels. These results are in good agreement with other study results [34,36] in which L-carnitine as a preservative in various toxicity studies has been shown to prevent liver, heart, and brain damage caused by some toxic substances. It was also reported that GSH reduction was prevented when L-carnitine was administered before APAP; an increase in GSH level was also important for GSHPx, and it increased the activity of GSHPx [37]. We consider that L-carnitine significantly reduces the elevated levels of MDA in different organs [36], it keeps the GSH content of various organs close to the normal values in rats exposed to toxication, and possibly play a role as free radical scavengers [15], and these effects minimize oxidative damage in tissues by reducing NAPQI levels.

As shown in *Table 1*, L-carnitine administration has been found to significantly reduce high levels of MDA in tissues of animals exposed to APAP toxicity and to maintain almost normal values of GSH. These results are consistent with the previous findings, reporting antioxidant properties of L-carnitine. This effect of L-carnitine plays an important role in the oxidation of fatty acids, acting as a possible free radical scavenger and preventing the depletion of GSH [36]. Although there may also be some role of the stimulation of glutathione production, we suggest that the enhancement of the antioxidant enzyme activity by L-carnitine [34,36] may have contributed to the elimination of the oxidative stress due to APAP induced ROS.

Toxic exposure can lead to damage in most vital organ systems and especially in the kidneys, which are most sensitive to toxicity [38]. Increases in the end-products of lipid peroxidation and decreases in antioxidant parameter levels support our findings. It has been reported that oxidative stress and lipid peroxidation play an important role in the pathophysiology of nephrotoxicity in cisplatin-induced nephrotoxicity cases and that L-carnitine administration in rats normalizes renal function, decreases tissue MDA levels, and increases GSH levels [36]. Besides, the protective effects of L-carnitine have been demonstrated in the methamphetamine-neurotoxicity mediated by peroxynitrite roots [39].

The mechanism of APAP toxicity is well defined in the liver, but less understood in the kidney. Available evidence suggests that intracellular GSH plays an important role in the detoxification of APAP and in the prevention of toxicity caused by APAP in the liver and kidneys [40]. ROS production is seen as an early event that begins before intracellular GSH depletion and cell damage in APAP nephrotoxicity [4]. GSH can also serve as a reductant by the oxidation of glutathione (GSSG) and reducing hydrogen peroxide and

lipid hydroperoxides directly to H₂O. Intracellular GSH is consumed under continuous intracellular oxidative stress. The depletion of intracellular GSH causes oxidation and damage of lipids, proteins, and DNA by ROS [4]. In this study, application of nephrotoxic-dose APAP to rats caused oxidative stress damage in renal tissues. We suggest that this effect occurs by increasing the degree of lipid peroxidation via inhibiting enzymatic antioxidants (e.g., GSHPx) in the kidney.

We found that tissue GSHPx enzyme activity and GSH levels decreased in the APAP treated rats, but increased in "APAP+ozone" group. Furthermore, a significant increase in the levels of tissue MDA (an indicator of tissue damage) was observed in the group receiving no ozone, while a decrease was observed in the ozone treated group. Although this condition is in accordance with different studies reporting that APAP induced renal damage is consistent with acute tubular necrosis [41,42], we conclude that our findings may be due to the beneficial effects of ozone in increasing tissue antioxidant enzyme activity and reducing tissue damage [37]. These results are also in agreement with the findings of a study investigating the protective effect of ozone on the kidneys and reporting its beneficial effects on the regulation of the antioxidant defense system [43]. The main finding of this study is that ozone alone or in combination with L-carnitine decreases tissue MDA levels due to APAP toxicity and increases tissue antioxidant parameter levels.

Results of this study showed that APAP toxicity caused oxidative damage in the examined renal tissues, and L-carnitine and ozone applications for protective purposes decreased MDA, a product of lipid peroxidation and increased tissue GSH levels via the antioxidant GSHPx enzyme activity. As a result, it has been concluded that L-carnitine and ozone can be used for treatment and protective purposes to prevent organ and tissue damage in APAP toxicity. Further studies are necessary to determine possible side-effects of ozone treatment.

CONFLICT OF INTEREST

The authors declare that they have no conflict of interest.

REFERENCES

- Jung KY, Kim T, Hwang SY, Yoon H, Shin TG, Sim MS, Jo IJ, Cha WC:** Availability of drug at convenient stores is not associated with an increased incidence of their poisoning. *Pharmacoepidemiol Drug Saf*, 28 (4): 536-543, 2019. DOI: 10.1002/pds.4760
- Hussain Z, Khan JA, Arshad A, Asif P, Rashid H, Arshad MI:** Protective effects of *Cinnamomum zeylanicum* L. (Darchini) in acetaminophen-induced oxidative stress, hepatotoxicity and nephrotoxicity in mouse model. *Biomed Pharmacother*, 109, 2285-2292, 2019. DOI: 10.1016/j.biopha.2018.11.123
- Yan M, Huo Y, Yin S, Hu H:** Mechanisms of acetaminophen-induced liver injury and its implications for therapeutic interventions. *Redox Biol*, 17, 274-283, 2018. DOI: 10.1016/j.redox.2018.04.019
- David Josephy P:** The molecular toxicology of acetaminophen. *Drug*

Metab Rev, 37 (4): 581-594, 2005. DOI: 10.1080/03602530500205200

- 5. Bessems JGM, Vermeulen NPE:** Paracetamol (acetaminophen)-induced toxicity: Molecular and biochemical mechanisms, analogues and protective approaches. *Crit Rev Toxicol*, 31 (1): 55-138, 2001. DOI: 10.1080/20014091111677
- 6. Mazer M, Perrone J:** Acetaminophen-induced nephrotoxicity: Pathophysiology, clinical manifestations, and management. *J Med Toxicol*, 4 (1): 2-6, 2008. DOI: 10.1007/BF03160941
- 7. Ucar F, Taslipinar MY, Alp BF, Aydin I, Aydin FN, Agilli M, Toygar M, Ozkan E, Macit E, Oztosun M, Cayci T, Ozcan A:** The effects of N-acetylcysteine and ozone therapy on oxidative stress and inflammation in acetaminophen-induced nephrotoxicity model. *Ren Fail*, 35 (5): 640-647, 2013. DOI: 10.3109/0886022X.2013.780530
- 8. Marrocco I, Altieri F, Peluso I:** Measurement and clinical significance of biomarkers of oxidative stress in humans. *Oxid Med Cell Longev*, 2017:6501046, 2017. DOI: 10.1155/2017/6501046
- 9. Ayala A, Muñoz MF, Argüelles S:** Lipid peroxidation: Production, metabolism, and signaling mechanisms of malondialdehyde and 4-hydroxy-2-nonenal. *Oxid Med Cell Longev*, 2014:360438, 2014. DOI: 10.1155/2014/360438
- 10. Shadyro O, Lisovskaya A:** ROS-induced lipid transformations without oxygen participation. *Chem Phys Lipids*, 221, 176-183, 2019. DOI: 10.1016/j.chemphyslip.2019.03.013
- 11. Lei XG, Zhu JH, Cheng WH, Bao Y, Ho YS, Reddi AR, Holmgren A, Arnér ES:** Paradoxical roles of antioxidant enzymes: Basic mechanisms and health implications. *Physiol Rev*, 96 (1): 307-364, 2016. DOI: 10.1152/physrev.00010.2014
- 12. Liu YH, Huang QH, Wu X, Wu JZ, Liang JL, Lin GS, Xu LQ, Lai XP, Su ZR, Chen JN:** Polydatin protects against acetaminophen-induced hepatotoxicity in mice via anti-oxidative and anti-apoptotic activities. *Food Funct*, 9 (11): 5891-5902, 2018. DOI: 10.1039/c8fo01078a
- 13. Blumberg J:** Use of biomarkers of oxidative stress in research studies. *J Nutr*, 134 (11): 3188S-3189S, 2004. DOI: 10.1093/jn/134.11.3188S
- 14. Brass EP:** Supplemental carnitine and exercise. *Am J Clin Nutr*, 72 (Suppl. 2): 618S-623S, 2000. DOI: 10.1093/ajcn/72.2.618S
- 15. Abu-El-Zahab HSH, Hamza RZ, Montaser MM, El-Mahdi MM, Al-Harthi WA:** Antioxidant, antiapoptotic, antigenotoxic, and hepatic ameliorative effects of L-carnitine and selenium on cadmium-induced hepatotoxicity and alterations in liver cell structure in male mice. *Ecotoxicol Environ Saf*, 173, 419-428, 2019. DOI: 10.1016/j.ecoenv.2019.02.041
- 16. Al-Eisa RA, Al-Salmi FA, Hamza RZ, El-Shenawy NS:** Role of L-carnitine in protection against the cardiac oxidative stress induced by aspartame in Wistar albino rats. *PLoS One*, 13 (11): e0204913, 2018. DOI: 10.1371/journal.pone.0204913
- 17. Yapar K, Kart A, Karapehlivan M, Atakisi O, Tunca R, Erginsoy S, Citil M:** Hepatoprotective effect of L-carnitine against acute acetaminophen toxicity in mice. *Exp Toxicol Pathol*, 59 (2): 121-128, 2007. DOI: 10.1016/j.etp.2007.02.009
- 18. Zanardi I, Borrelli E, Valacchi G, Travagli V, Bocci V:** Ozone: A multifaceted molecule with unexpected therapeutic activity. *Curr Med Chem*, 23 (4): 304-314, 2016. DOI: 10.2174/0929867323666151221150420
- 19. Re L, Mawsouf MN, Menéndez S, León OS, Sánchez GM, Hernández F:** Ozone therapy: Clinical and basic evidence of its therapeutic potential. *Arch Med Res*, 39 (1): 17-26, 2008. DOI: 10.1016/j.arcmed.2007.07.005
- 20. Ajamieh H, Merino N, Candelario-Jalil E, Menéndez S, Martinez-Sanchez G, Re L, Giuliani A, Leon OS:** Similar protective effect of ischaemic and ozone oxidative preconditionings in liver ischaemia/reperfusion injury. *Pharmacol Res*, 45 (4): 333-339, 2002. DOI: 10.1006/phrs.2002.0952
- 21. Uysal B, Yasar M, Ersoz N, Coskun O, Kilic A, Cayc T, Kurt B, Oter S, Korkmaz A, Guven A:** Efficacy of hyperbaric oxygen therapy and medical ozone therapy in experimental acute necrotizing pancreatitis. *Pancreas*, 39 (1): 9-15, 2010. DOI: 10.1097/MPA.0b013e3181bb5ae3
- 22. Guven A, Gundogdu G, Vurucu S, Uysal B, Oztas E, Ozturk H, Korkmaz A:** Medical ozone therapy reduces oxidative stress and

intestinal damage in an experimental model of necrotizing enterocolitis in neonatal rats. *J Pediatr Surg*, 44 (9): 1730-1735, 2009. DOI: 10.1016/j.jpedsurg.2009.01.007

- 23. Bocci V:** Is it true that ozone is always toxic? The end of a dogma. *Toxicol Appl Pharmacol*, 216 (3): 493-504, 2006. DOI: 10.1016/j.taap.2006.06.009
- 24. Bocci VA:** Scientific and medical aspects of ozone therapy. State of the art. *Arch Med Res*, 37 (4): 425-435, 2006. DOI: 10.1016/j.arcmed.2005.08.006
- 25. Demirbag S, Uysal B, Guven A, Cayci T, Ozler M, Ozcan A, Kaldirim U, Surer I, Korkmaz A:** Effects of medical ozone therapy on acetaminophen-induced nephrotoxicity in rats. *Ren Fail*, 32 (4): 493-497, 2010. DOI: 10.3109/08860221003646352
- 26. Gul H, Uysal B, Cakir E, Yaman H, Macit E, Yildirim AO, Eyi YE, Kaldirim U, Oztas E, Akgul EO, Cayci T, Ozler M, Topal T, Oter S, Korkmaz A, Toygar M, Demirbag S:** The protective effects of ozone therapy in a rat model of acetaminophen-induced liver injury. *Environ Toxicol Pharmacol*, 34 (1): 81-86, 2012. DOI: 10.1016/j.etap.2012.02.006
- 27. Özgün E, Sayılan Özgün G, Eskioçak S, Yalçın Ö, Süer Gökmen S:** Deneysel kolitte L-karnitin serum paraoksonaz, arilesteraz ve laktonez aktivitelere ve oksidatif duruma etkisi. *Turk J Biochem*, 38 (2): 145-153, 2013.
- 28. Beutler E, Duron O, Kelly BM:** Improved method for the determination of blood glutathione. *J Lab Clin Med*, 61, 882-888, 1963.
- 29. Yoshioka T, Kawada K, Shimada T, Mori M:** Lipid peroxidation in maternal and cord blood and protective mechanism against activated-oxygen toxicity in the blood. *Am J Obstet Gynecol*, 135 (3): 372-376, 1979. DOI: 10.1016/0002-9378(79)90708-7
- 30. Tsikas D:** Assessment of lipid peroxidation by measuring malondialdehyde (MDA) and relatives in biological samples: Analytical and biological challenges. *Anal Biochem*, 524, 13-30, 2017. DOI: 10.1016/j.ab.2016.10.021
- 31. El-Demerdash FM, Yousef MI, Radwan FME:** Ameliorating effect of curcumin on sodium arsenite-induced oxidative damage and lipid peroxidation in different rat organs. *Food Chem Toxicol*, 47 (1): 249-254, 2009. DOI: 10.1016/j.fct.2008.11.013
- 32. Reis R, Charehsaz M, Sipahi H, Doğan Ekici AI, Macit Ç, Akkaya H, Aydin A:** Energy drink induced lipid peroxidation and oxidative damage in rat liver and brain when used alone or combined with alcohol. *J Food Sci*, 82 (4): 1037-1043, 2017. DOI: 10.1111/1750-3841.13662
- 33. Wu MM, Chiou HY, Wang TW, Hsueh YM, Wang IH, Chen CJ, Lee TC:** Association of blood arsenic levels with increased reactive oxidants and decreased antioxidant capacity in a human population of northeastern Taiwan. *Environ Health Perspect*, 109 (10): 1011-1017, 2001. DOI: 10.1289/ehp.011091011
- 34. Sepand MR, Razavi-Azarkhiavi K, Omid A, Zirak MR, Sabzevari S, Kazemi AR, Sabzevari O:** Effect of acetyl-L-carnitine on antioxidant status, lipid peroxidation, and oxidative damage of arsenic in rat. *Biol Trace Elem Res*, 171 (1): 107-115, 2016. DOI: 10.1007/s12011-015-0436-y
- 35. Barhwal K, Hota SK, Jain V, Prasad D, Singh SB, Ilavazhagan G:** Acetyl-L-carnitine (ALCAR) prevents hypobaric hypoxia-induced spatial memory impairment through extracellular related kinase-mediated nuclear factor erythroid 2-related factor 2 phosphorylation. *Neuroscience*, 161 (2): 501-514, 2009. DOI: 10.1016/j.neuroscience.2009.02.086
- 36. Karalija A, Novikova LN, Kingham PJ, Wiberg M, Novikov LN:** Neuroprotective effects of N-acetyl-cysteine and acetyl-L-carnitine after spinal cord injury in adult rats. *PLoS One*, 7 (7): e41086, 2012. DOI: 10.1371/journal.pone.0041086
- 37. Liu J, Li C, Qu W, Leslie E, Bonifant CL, Buzard GS, Saavedra JE, Keefer LK, Waalkes MP:** Nitric oxide prodrugs and metallochemotherapeutics: JS-K and CB-3-100 enhance arsenic and cisplatin cytotoxicity by increasing cellular accumulation. *Mol Cancer Ther*, 3 (6): 709-714, 2004.
- 38. Sayed-Ahmed MM, Eissa MA, Kenawy SA, Mostafa N, Calvani M, Osman AM:** Progression of cisplatin-induced nephrotoxicity in a carnitine-depleted rat model. *Chemotherapy*, 50 (4): 162-170, 2004. DOI: 10.1159/000080689

- 39. Virmani A, Gaetani F, Imam S, Binienda Z, Ali S:** The protective role of L-carnitine against neurotoxicity evoked by drug of abuse, methamphetamine, could be related to mitochondrial dysfunction. *Ann N Y Acad Sci*, 965, 225-232, 2002. DOI: 10.1111/j.1749-6632.2002.tb04164.x
- 40. Dhibi S, Mbarki S, Elfeki A, Hfaiedh N:** Eucalyptus globulus extract protects upon acetaminophen-induced kidney damages in male rat. *Bosn J Basic Med Sci*, 14 (2): 99-104, 2014. DOI: 10.17305/bjbms.2014.2272
- 41. Ilbey YO, Ozbek E, Cekmen M, Somay A, Ozcan L, Otünctemur A, Simsek A, Mete F:** Melatonin prevents acetaminophen-induced nephrotoxicity in rats. *Int Urol Nephrol*, 41 (3): 695-702, 2009. DOI: 10.1007/s11255-008-9503-z
- 42. Ito T, Watanabe S, Tsuruga K, Aizawa T, Hirono K, Ito E, Joh K, Tanaka H:** Severe intrinsic acute kidney injury associated with therapeutic doses of acetaminophen. *Pediatr Int*, 57 (2): e53-e55, 2015. DOI: 10.1111/ped.12607
- 43. Ozturk O, Eroglu HA, Ustebay S, Kuzucu M, Adali Y:** An experimental study on the preventive effects of N-acetyl cysteine and ozone treatment against contrast-induced nephropathy. *Acta Cir Bras*, 33 (6): 508-517, 2018. DOI: 10.1590/s0102-865020180060000005