

Scanning Electron Microscopy Images of *Rhipicephalus (Boophilus) kohlsi* from a Wild Goat in Northeastern Anatolia, Turkey

Esin GÜVEN ^{1,a}  Rıdvan KİRMAN ^{1,b} Muzaffer AKYÜZ ^{1,c}

¹Department of Parasitology, Faculty of Veterinary Medicine, Atatürk University, TR-25240 Erzurum - TURKEY
^a ORCID: 0000-0001-7067-8819; ^b ORCID: 0000-0001-5437-089X; ^c ORCID: 0000-0002-6095-7870

Article ID: KVFD-2019-21766 Received: 16.01.2019 Accepted: 02.05.2019 Published Online: 02.05.2019

How to Cite This Article

Güven E, Kirman R, Akyüz M: Scanning electron microscopy images of *Rhipicephalus (Boophilus) kohlsi* from a wild goat in Northeastern Anatolia, Turkey. *Kafkas Univ Vet Fak Derg*, 25 (5): 725-728, 2019. DOI: 10.9775/kvfd.2019.21766

Abstract

Tick samples were collected from a wild goat (*Capra aegagrus*) found in Uzundere province of Erzurum, Turkey. Species identification performed based on morphological criteria, and 3 males and 1 female tick were identified as *Rhipicephalus (Boophilus) kohlsi*. Scanning electron microscopy (SEM) used to view the characteristic morphologic features of the ticks. Although previous studies report the presence of *R. kohlsi* in Turkey and in the world, this study represents the first SEM images of male and female *R. kohlsi*.

Keywords: Wild goat, *Rhipicephalus (Boophilus) kohlsi*, Scanning electron microscopy

Türkiye'nin Kuzeydoğusunda Bir Yaban Keçisinden Elde Edilen *Rhipicephalus (Boophilus) kohlsi*'nin Taramalı Elektron Mikroskopu Görüntüleri

Öz

Erzurum'un Uzundere ilçesinde bulunan bir yaban keçisinden (*Capra aegagrus*) kene örnekleri toplandı. Morfolojik kriterlere göre yapılan tür identifikasyonunda, toplanan 3 erkek ve 1 dişi kene *Rhipicephalus (Boophilus) kohlsi* olarak tanımlandı. Kenelerin karakteristik morfolojik özelliklerini incelemek için taramalı elektron mikroskopu (SEM) kullanıldı. Önceki çalışmalarda *R. kohlsi*'nin Türkiye ve dünyadaki varlığı bildirilmiş olmakla beraber bu çalışma erkek ve dişi *R. kohlsi*'nin ilk SEM görüntülerini sunmaktadır.

Anahtar sözcükler: Yaban keçisi, *Rhipicephalus (Boophilus) kohlsi*, Taramalı elektron mikroskopu

INTRODUCTION

Wild goat (*Capra aegagrus*) exists intermittently at southwest Turkey, southwest and central Asia and southern Russia [1-6]. In Turkey, wild goats inhabit rugged, mountainous area with altitude between 1500 and 3500 meters in southern, southeastern, eastern and northeastern Anatolia especially in arid habitats.

Rhipicephalus (Boophilus) kohlsi was first recorded and described by Hoogstraal and Kaiser [7] from sheep and goats in Jordan, in 1970. In the following years, this species reported from Israel [8,9], Western Saudi Arabia [10], Iraq [11], West Africa [12], Iran [13], Uzbekistan [14], and Turkey [15,16]. This tick is primarily defined as a parasite of goats and sheep but also reported from cattle, horse, mule, pig and camel [8,14]. The preferred body sites by the tick are

especially neck and ears in goats, but it also attaches to the tail in fat-tailed sheep [8].

In this case report, we provide morphological data for the male and female *R. kohlsi* collected from a wild goat by using scanning electron microscopy (SEM).

CASE HISTORY

An injured wild goat was found in Uzundere, Erzurum (40° 32' 11" N and 41° 32' 54" E, 1140 m above sea level, northeastern of Turkey) in April, 2017 and taken to the Animal Hospital of the Faculty of Veterinary Medicine for treatment. The female and young (<1-year-old) wild goat was checked for ectoparasites during inspection. Four tick samples were taken from neck and ear, and kept in tubes containing 70% ethanol until identification. The ticks were



İletişim (Correspondence)



+90 442 2317212



esinguven@atauni.edu.tr

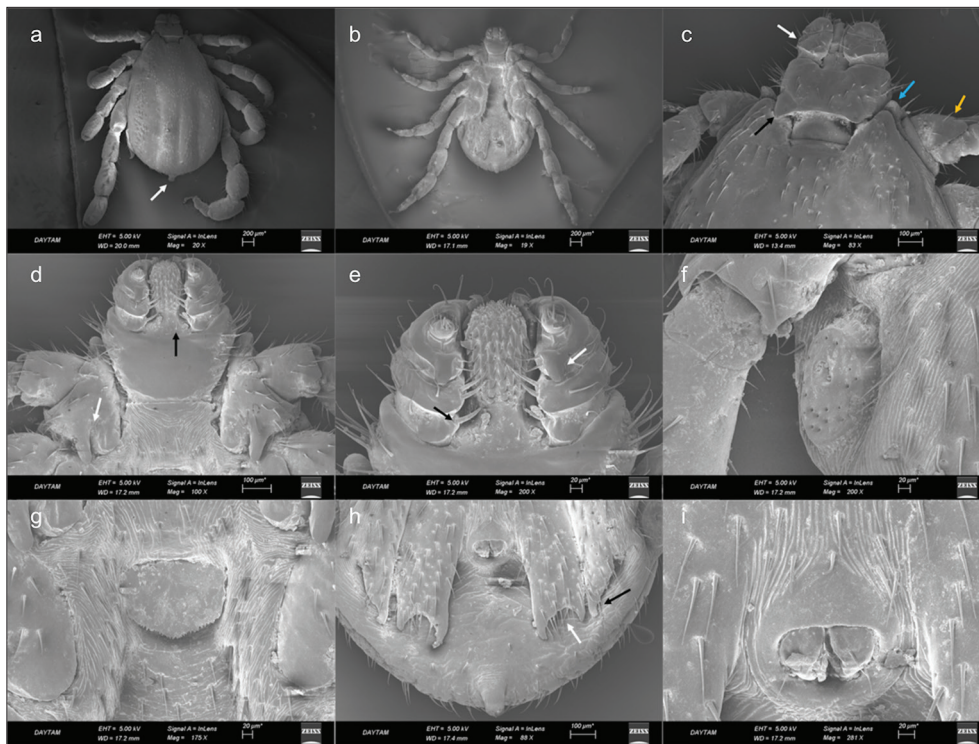


Fig 1. *Rhipicephalus kohlsi* male. (a) Dorsal view, arrow indicates caudal appendage, (b) Ventral view, (c) Dorsal view of capitulum, white arrow indicates palp article 2, blue arrow indicates coxa 1 anterior spur, orange arrow indicates trochanter 1, black arrow indicates cornua, (d) Ventral view of capitulum, white arrow indicates coxa 1 spur, black arrow indicates post hypostomal setae, (e) Ventral view of palpi and hypostome, black arrow indicates the lobe and seta on palp article 1, white arrow indicates inner spur of palp article 3, (f) Spiracular plate, (g) Genital aperture, (h) Adanal and accessory adanal plates, white arrow indicates posterior margin of adanal plate, black arrow indicates the bulge at accessory plates, (i) Anus

identified based on their morphological criteria using taxonomic keys described by Hoogstraal and Kaiser [7] under the stereomicroscope (Nikon SMZ 745T, Japan). Body dimensions of ticks are given as millimeter (mm). In the cleaning process of the ticks, an ultrasonic cleaner was used for 5 min while they were immersed in 5% potassium hydroxide solution in water. Also, three samples (one female and 2 males) were prepared for SEM imaging. Ticks were dehydrated through a graded series of ethanol (50, 70, 80 and 100%), sputtered with gold in the sputter coater (Quorum Q150R S, Germany) and examined with SEM (Zeiss Sigma 300, Germany).

Body length of male ticks vary between 3.1 and 3.3 (from apex of palpi to apex of caudal appendage), width vary between 1.7 and 1.9 (Fig. 1a,b). The color is yellowish brown.

Basis capituli subrectangular, more than twice as wide as long (average width/length: 0.5/0.2). Lateral margins slightly convex, posterior margin slightly concave. Triangle-shaped cornua with rounded margin. The base of hypostome deprived of setae. Setae on lateral and anterolateral parts but probably due to breakage during process exact number uncounted (Fig. 1c). At the ventral side, setae on posterior of palpi and posterolateral corners. Also, a pair of setae on the base level of palpal segment 1. Hypostome and palpi equal in length, hypostome dental formula 4/4 (Fig. 1d).

Palpal article 1 visible from ventral, bearing an apparent lobe with a large, thick seta at the inner margin (Fig. 1e). Article 2 with narrow outer and wider inner margin visible from dorsal (Fig. 1c), 2 thick setae at the inner margin visible from ventral. Article 3 bearing a conspicuous inner spur visible from ventral, with 2 narrow setae at the inner margin. Article 4 located on the apex of article 3 and bearing thick setae (Fig. 1e).

The length of scutum vary between 2.5 and 2.7 (from apex of scapulae to apex of caudal appendage), and the width between 1.7 and 1.9. Caudal appendage short but wide, and truncated cone like in shape (Fig. 1a). Eyes inconspicuous. Cervical grooves deep, extending to level of between coxa 2 and coxa 3. Posteromedian and paramedian grooves apparent, paramedian grooves longer than posteromedian groove (Fig. 1a). Spiracular plate nearly circular with very small pores (Fig. 1f). Genital aperture wide; located on the anterior margin of coxa 2; and small, irregular serrations on the posterior margin (Fig. 1g). Adanal plates extending to the body margin but not passing over. Posterior margin of adanal plate concave thoroughly with a longer inner spur and a short outer spur. Accessory adanal plate nearly triangular, extending to level of outer spur of adanal plates. A spur like bulge at the terminal part of the accessory plates (Fig. 1h). Anus nearly circular, with 2 setae on each

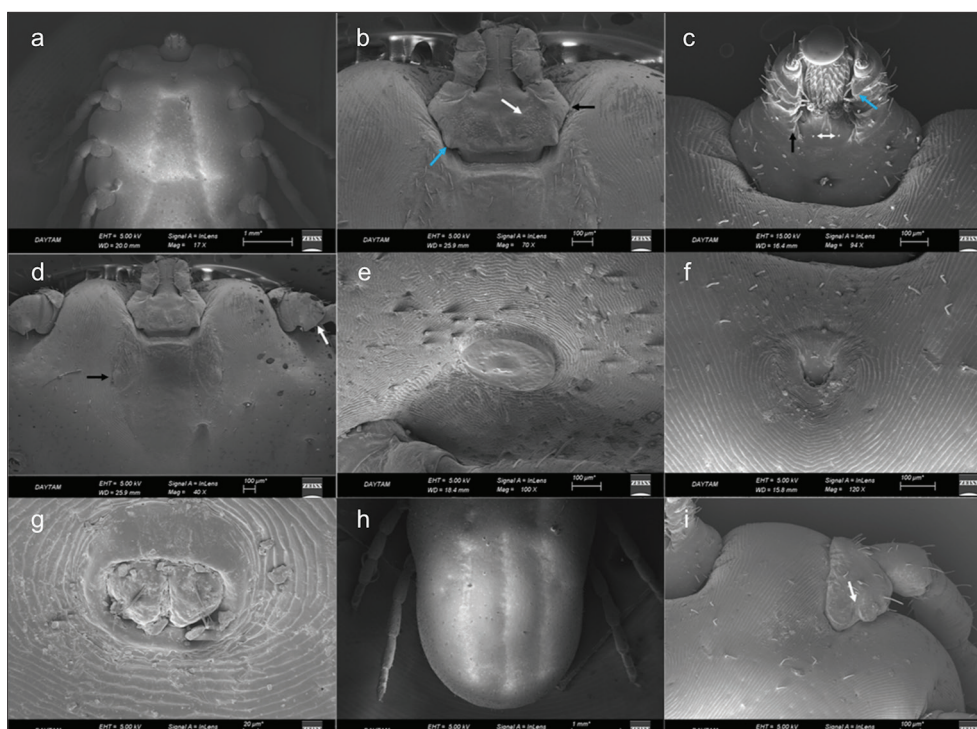


Fig 2. *Rhipicephalus kohlsi* female. (a) Ventral view, (b) Dorsal view of capitulum, white arrow indicates porose area, black arrow indicates lateral angle, blue arrow indicates cornua, (c) Ventral view of capitulum, white double headed arrow post hypostomal setae, black arrow indicates the lobe and seta on palp article 1, blue arrow indicates inner spur of palp article 3, (d) Black arrow indicates eyes; white arrow indicates trochanter 1, (e) Spiracular plate, (f) Genital aperture, (g) Anus, (h) Dorsal view of idiosoma, (i) Ventral view of coxa 1 spur

valve (Fig. 1i). Idiosoma covered with large, seta bearing punctuations regularly (Fig. 1a,b).

Legs strong and long. Coxa 1 elongate a large anterior spur visible from dorsal view (Fig. 1c). From ventral view coxa 1 bearing a wider and round shaped inner spur and a narrow, a bit longer and sharper outer spur (Fig. 1d). A large, triangular shield on trochanter 1 visible from dorsal view (Fig. 1c). Coxa 2 with a bulge like outer spur, and a spur located at the junction point of inner and posterior margins. The structure of coxa 3 similar with coxa 2 but inconspicuous. Coxa 4 with a small, triangular shaped and median located spur (Fig. 1b).

Body length of partially fed female tick 7.3, and width 4.1 (Fig. 2a).

Basis capituli hexagonal, with sharp lateral angles; the length 0.7 and the width 0.3. Posterior margin slightly convex. Cornua mildly subtriangle in shape but small, with rounded margin. Porose areas pear shaped, medium size, located separately (Fig. 2b). Setae on the ventral side could not be completely counted because of occurrence of setae breakage in these parts. A pair of setae visible at the post hypostomal region. Hypostome dental formula 4/4 (Fig. 2c). Palpal article 1 visible from ventral, with a lobe with a thick seta at the inner margin. Article 2 straight, with 2 or 3 setae at inner margin; article 3 bearing a conspicuous inner spur visible from dorsal, with 2 narrow setae at the

inner margin. Article 4 located on the apex of article 3 and bearing thick setae (Fig. 2c).

The length of scutum 1.3 (from apex of scapulae to posterior margin), and the width 1 (at widest point). Posterior margin slightly sinuous with a convex curve towards eyes. Eyes large, flat. Cervical grooves extending to posterolateral margin. At the proximal side of scutum, 13-14 setae on lateral parts (Fig. 2d). Spiracular plate nearly circular with very small pores (Fig. 2e). Genital aperture located on the posterior of coxa 1, posterior lips in a broad U shape and lateral margins diverging (Fig. 2f). Anus nearly circular, with 2 setae on each valve (Fig. 2g). Idiosoma covered with setae (Fig. 2h).

Legs strong and long (Fig. 2a). Coxa 1 spurs nearly equal, coxa 2-4 spurs indistinct (Fig. 2i). Trochanter 1 with a large, triangular shield visible from dorsal view (Fig. 2d).

DISCUSSION

Distribution area of *R. kohlsi* is known to be restricted in Middle East, Central Asia and West Africa [9-14]. In Turkey, reports were from southeastern Anatolia region [15,16] but with our study from northeastern Anatolia, it is understood that *R. kohlsi* possibly has a wider geographical distribution in our country than considered before.

Worldwide, records of this species are rare maybe because

of having a restricted distribution. Also, it is an unregarded tick species due to not having a known vectorial capacity until now [11]. One of the outcomes of global warming is the spread of tick species and tick-borne diseases to new areas. Although there is not a known vectorial role of *R. kohlsi* yet, but we cannot be sure from forthcoming years. Nonetheless, knowledge about the presence of tick species in a region is beneficial to consider possible emerging or re-emerging tick-borne diseases.

The ticks are confirmed to be *R. kohlsi* by using taxonomic keys of Hoogstraal and Kaiser [7]. The keys for the differential diagnosis of *R. kohlsi* are as follows: setae-bearing lobe on the inner margin of palpal article 1 visible from ventral, and dental formula 4/4 for both sexes. Male tick with caudal appendage, adanal plates not passing over the body margin and with a concave posterior margin. The size of accessory plates' inner spur is intermediate, between adanal plates' size. The genital aperture is wide in males and shield-shaped in female. Coxa 1 has a deep cleft in both sexes. Porose areas are pear shaped. Although Hoogstraal and Kaiser [7] stated that porose areas fairly small, our sample has medium sized porose areas.

This case report represents the presence and morphological data of *R. kohlsi* obtained from a wild goat. Also, the first SEM records of male and female *R. kohlsi* were presented. This species may have a wider distribution than expected so it has to be taken into consideration in tick identification studies.

ACKNOWLEDGMENTS

Scanning electron microscopy observations were carried out using facilities of the East Anatolia High Technology Application and Research Center (DAYTAM).

REFERENCES

- Grubb P:** Artiodactyla. In, Wilson DE, Reeder DM (Eds): Mammal Species of the World. A Taxonomic and Geographic Reference, 3rd ed., 637-722, Johns Hopkins University Press, Baltimore, USA, 2005.
- Rahim M:** Influence of Environmental Variables on Distribution of Wild Goat (*Capra aegagrus*), in Iraq by Maxent. *Am Sci Res J Eng Technol Sci*, 18, 97-107, 2016.
- Masseti M:** The wild goat, *Capra aegagrus* Erxleben, 1777, of the island of Montecristo (Northern Tyrrhenian Sea, Italy): Does it still exist. *Mammalia*, 80 (2): 125-141, 2015. DOI: 10.1515/mammalia-2014-0168.
- Gonenc B, Emir H, Jacob O:** Digestive tract helminths of Turkish ibex (*Capra aegagrus aegagrus* Erxleben, 1877). *Ankara Üniv Vet Fak Derg*, 65, 247-251, 2018. DOI: 10.1501/Vetfak_0000002853
- Ansari A, Karami M, Rezai HR, Riazi B:** Effects of habitat fragmentation on the genetic structure of populations of wild goat, *Capra aegagrus* Erxleben, 1777 (Artiodactyla: Bovidae) in Markazi province, central Iran. *Acta Zool Bulg*, 67 (4): 501-506, 2015.
- Gipoliti S:** The wild goat of Montecristo Island: Did it ever exist? *Mammalia*, 80 (2): 221-222, 2015. DOI: 10.1515/mammalia-2015-0078
- Hoogstraal H, Kaiser MN:** *Boophilus kohlsi* n.sp. (Acarina: Ixodidae) from sheep and goats in Jordan. *J Parasitol*, 46, 441-448, 1960. DOI: 10.2307/3275134
- Feldman-Muhsam B, Shechter R:** Some notes on the genus *Boophilus* (Ixodidae), with special reference to species found in Israel. *J Med Entomol*, 7 (6): 677-686, 1970. DOI: 10.1093/jmedent/7.6.677.
- Wallach AD, Shanas U, Mumcuoglu KY, Inbar M:** Ectoparasites on reintroduced roe deer *Capreolus capreolus* in Israel. *J Wildl Dis*, 44 (3): 693-696, 2008. DOI: 10.7589/0090-3558-44.3.693.
- Hussein HS, Al-Khalifa MS, Diab FM, Al-Asgah NA:** The distribution, host range and seasonal abundance of the Arabian goat and sheep tick, *Boophilus kohlsi* (Acari: Ixodidae) in Saudi Arabia. *Arab Gulf J Sci Res*, B6 (2): 275-287, 1988.
- Shamsuddin M, Mohammad MK:** Incidence, distribution, and host relationships of some ticks (Ixodidea) in Iraq. *Kuwait J Sci*, 15, 321-330, 1988.
- Walker AR, Bouattour A, Camicas JL, Estrada- Pena A, Horak IG, Latif AA, Pegram RG, Preston PM:** Ticks of Domestic Animals in Africa, A guide to Identification of Species. 157, Bioscience Reports, London, UK, 2003.
- Rahbari S, Nabian S:** The first report of *Rhipicephalus* (*Boophilus*) *kohlsi* (Hoogstraal and Kaiser 1960) from wild goats (*Capra hircus aegagrus*) in Iran. *Iran J Parasitol*, 2 (2): 53-56, 2007.
- Rasulov I:** Ticks status in central Asia with a special emphasis on Uzbekistan. *Parasitol Res*, 101 (2): 183-186, 2007. DOI: 10.1007/s00436-007-0691-8.
- Merdivenci A:** Türkiye Keneleri Üzerine Araştırmalar. 1-420, İstanbul Cerrahpaşa Tıp Fakültesi Yayını, Kutulmuş Matbaası, İstanbul, 1969.
- Özer E, Güler S:** Mardin'de keçilerde *Boophilus kohlsi* (Hoogstraal et Kaiser, 1960)'nin bulunuşu. *Turk J Vet Anim Sci*, 18 (1): 23-26, 1994.