

# An Evaluation of Post-operative Urinary Incontinence in Dogs with Intramural Ectopic Ureter Treated with Neoureterocystostomy <sup>[1]</sup>

Murat KARABAĞLI <sup>1</sup> 

<sup>[1]</sup> A part of this study was presented as oral presentation in 1st International Turkey Veterinary Surgery Congress, 11-14 May 2016, Erzurum, Turkey

<sup>1</sup> Faculty of Veterinary Medicine, University of Istanbul, Department of Surgery, TR-34320 Avcilar, Istanbul - TURKEY

Article Code: KVFD-2016-16030 Received: 29.04.2016 Accepted: 01.08.2016 Published Online: 01.08.2016

## Citation of This Article

**Karabağlı M:** An evaluation of post-operative urinary incontinence in dogs with intramural ectopic ureter treated with neoureterocystostomy. *Kafkas Univ Vet Fak Derg*, 23, 145-154, 2017. DOI: 10.9775/kvfd.2016.16030

## Abstract

The main motivation in the treatment of ectopic ureter (EU) is achieving complete urinary continence. Although, new neoureterostomy techniques were developed for the surgical treatment of intramural ectopic ureters, it was determined that postoperative incontinence scores achieved with the latest techniques have no distinct superiority over those achieved with older techniques. Therefore, we aim to determine the post-operative urinary incontinence scores in dogs with intramural EU that were treated with neoureterocystostomy and compared with older reports which neoureterostomy techniques were used. Seven female dogs which were brought to our clinic with a complaint of constant urine dribbling since they were born or adopted were included the study. The radiographic diagnosis was made by excretory urography in four dogs, excretory urography and retrograde vagino-urethrography in 2 dogs and MRI in 1 dog. Definitive diagnosis was made by cystotomy. Ectopic ureters were intramural character in all cases. Neoureterocystostomy technique was used for the surgical treatment and incontinence scores at post-operative 1<sup>st</sup> and 2<sup>nd</sup> months were recorded. For the purpose of complete elimination of the postoperative urinary incontinence, phenylpropralamine were used in 4 cases and oxybutynin were used in 1 case as additional medical therapy. Urinary incontinence was completely disappeared, 5 out of 7 patients (71%) at the end of the study. In conclusion, the results suggest that EU is most successfully treated with a surgical method that does not involve urethrotomy and it should be performed simultaneously with a surgical method used in the treatment of urethral sphincter mechanism incompetence and should be combined with a treatment involving the use of post-operative alpha adrenergic medications.

**Keywords:** Dog, Ectopic ureter, Intramural, Neoureterocystostomy, Urinary incontinence

## Neoüreterosistostomi Yöntemiyle Tedavi Edilen İnamural Ektopik Üreter Hastası Köpeklerde Postoperatif Üriner İnkontinensin Değerlendirilmesi

### Özet

Ektopik üreterin cerrahi tedavisinde ana motivasyon üriner inkontinensi ortadan kaldırmaktır. Özellikle intramural tipteki ektopik üreterin cerrahi tedavisi için farklı neoüretostomi teknikleri geliştirilmesine rağmen, postoperatif üriner inkontinens skorlarının, eski teknikler kullanılarak elde edilenlere önemli bir üstünlüğü olmadığı tespit edilmiştir. Çalışmamızda, neoüretostomi tekniğiyle tedavi edilen intramural ektopik üreter hastası köpeklerde postoperatif üriner inkontinens skorlarının, neoüretostomi teknikleri kullanılarak elde edilen eski skorlarla karşılaştırılması amaçlanmıştır. Çalışmaya kliniğimize, doğduğundan veya sahiplenildiğinden beri sürekli damla damla idrar kaçırma şikayeti olan 7 dişi köpek dahil edildi. Radyolojik tanı için 4 hastada ekskretör ürografi, 2 hastada ekskretör ürografi ve retrograd vajinoüretrografi, bir hastada ise magnetik rezonans görüntüleme (MRG) faydalandı. Kesin tanı sistotomi ile kondu. Hastaların tümünde ektopik üreter intramural karakterde idi. Hastalar neoüretostomi tekniği kullanılarak sağlandı ve postoperatif 1. ve 2. ay inkontinens skorları kaydedildi. Postoperatif dönemde, üriner inkontinensin tamamen ortadan kaldırılması için, ek medikal tedavi olarak 4 hastada fenilpropralamine, bir hastada ise oksibutininden faydalandı. Çalışmanın sonunda, yedi hastanın 5 tanesinde (%71) üriner inkontinens tamamen ortadan kalktı. Elde ettiğimiz sonuçlar, farklı neoüretostomi teknikleri kullanılarak elde edilenlerle benzer bulundu. Sonuçlar, intramural ektopik üreterin tedavisinde, üretrotomi içermeyen bir cerrahi yöntemin, üretra sfinkteri mekanizması yetersizliğinin cerrahi tedavisinde kullanılan bir yöntemle birlikte, eş zamanlı olarak uygulanması ve postoperatif dönemde alfa adrenerjik ilaçların kullanılmasını içeren bir kombine terapiyle en başarılı şekilde tedavi edilebileceğini düşündürdü.

**Anahtar sözcükler:** Köpek, Ektopik üreter, İnamural, Neoüretostomi, Üriner inkontinens



### İletişim (Correspondence)



+90 212 4737070/17019



[murat.karabagli@istanbul.edu.tr](mailto:murat.karabagli@istanbul.edu.tr)

## INTRODUCTION

The ureters are fibromuscular tube-like channels that transport urine from the pelvis renalis of the kidneys to the bladder [1]. Normally, they reach the dorsolateral surface of the bladder just cranial to its neck and enter the bladder obliquely at the trigonum vesicae after a short intramural course. Ectopic ureter (EU) is defined as an abnormality where one or both of the ureters opens into an area distal to the bladder neck. Common sites of the termination of the ectopic ureter include the urethra, vagina and the uterus. This congenital anomaly is caused by the disembryogenesis of the ureteric bud [2] and EU is observed more frequently in females than males [3].

Even though there are different classifications, ectopic ureters are classified into two categories; extramural and intramural [2,4-7]. With extramural EU, the ureter completely bypasses the urinary bladder to insert more distally into the urogenital system. With intramural EU, the ureter attaches to the dorsal or dorsolateral part of the bladder, running submucosally through the bladder wall and opens into the bladder neck, urethra or vagina, instead of opening its normal position [8]. The major clinical sign of EU is urinary incontinence [9,10]. Peri-vulvar dermatitis, cystitis and pyelonephritis secondary to ascending infection can also occur [2]. Hematology and serum biochemistry findings are usually normal [8].

Urinary incontinence is defined as involuntary passage of urine through the urethra [11]. Even though continuous or intermittent urinary incontinence is reported as primary complaint since birth in the history [5], urinary incontinence is generally continuous character in EU patients [11-13].

Excretory urography, retrograde vagino-urethrography, positive-contrast cystography, double-contrast cystography, pneumocystography [14], ultrasonography [8], fluoroscopy [2], cystoscopy [15] contrast-enhanced computer tomography [4], transurethral cystoscopy [16] and magnetic resonance imaging (MRI) [12] are used in the diagnosis of EU. Although transurethral cystoscopy is considered the most reliable method of diagnosis because it allows direct imaging of urethra and bladder trigone, definitive diagnosis can be made using cystotomy or postmortem examination [5,15].

It is recommended that the decision about the choice of which surgical method will be used in the treatment of EU is based on the location and morphological characteristics of the ectopy and the presence of secondary lower and upper urinary system abnormalities [4]. In the surgical treatment of extramural EU, the ureter is transected from the dorsal wall of the urethra, vagina or uterus and reimplanted in the urinary bladder through a point between the bladder neck and apex. This procedure is called neoureterocystostomy or ureteroneocystostomy [4,17]. With intramural EU, a new stoma is usually created in the mucosa of the urinary bladder in the normal anatomical position of the ureter

orificium and the distal submucosal ureteral tunnel is ligated. This technique is called neoureterostomy [2,4,17]. Cystoscopic-guided laser ablation has also been used in the treatment of intramural EU [18].

The correlation between the morphological classification of EU and the preferred surgical method with the prognosis has not been established [2]. Different neoureterostomy techniques have been developed, especially for the treatment of intramural EU [13,18,19]. The primary objective of these studies is to minimize the presence of post-operative incontinence. However, it was determined that incontinence scores achieved with the latest techniques have no distinct superiority over those achieved with older techniques [13]. Therefore, we aim to evaluate the presence of post-operative urinary incontinence in dogs with intramural EU that we treated with neoureterocystostomy.

## MATERIAL and METHODS

### Patient Selection

The material of our study consisted of 7 female dogs, brought to our clinic between March 2010 and July 2015 (Table 1). Common complaint of the dogs included in the study was the constant urine dribbling, every 10-30 seconds since they are born or adopted. The hair coat on the distal vulva was moist or wet, and they had peri-vulvar dermatitis of varying severities in all dogs. Anamnesis revealed that dogs rarely voluntarily urinate and both the amount of urine passed was smaller and the urination time was shorter than those of other dogs.

### Clinical Examination

Before starting the examination, questions about whether or not the dog was sterilized, history of trauma, history of urinary system disease, as well as when and how often it had urinary incontinence were asked and recorded. In the inspection, the presence of neurological findings such as ataxic gait, coordination disorder, nystagmus, and anisocoria was investigated. The perineal and bulbospongiosus reflexes, patellar reflex response and conscious proprioception were evaluated. In the next step, the peri-vulvar region of the patient was examined for dermatitis and continuous urine dribbling while the patient was standing. The size of the urinary bladder (large, normal or small) was evaluated through abdominal palpation during the clinical examination. The urine sample collected by cystosynthesis was sent for complete urinalysis and urine culture test.

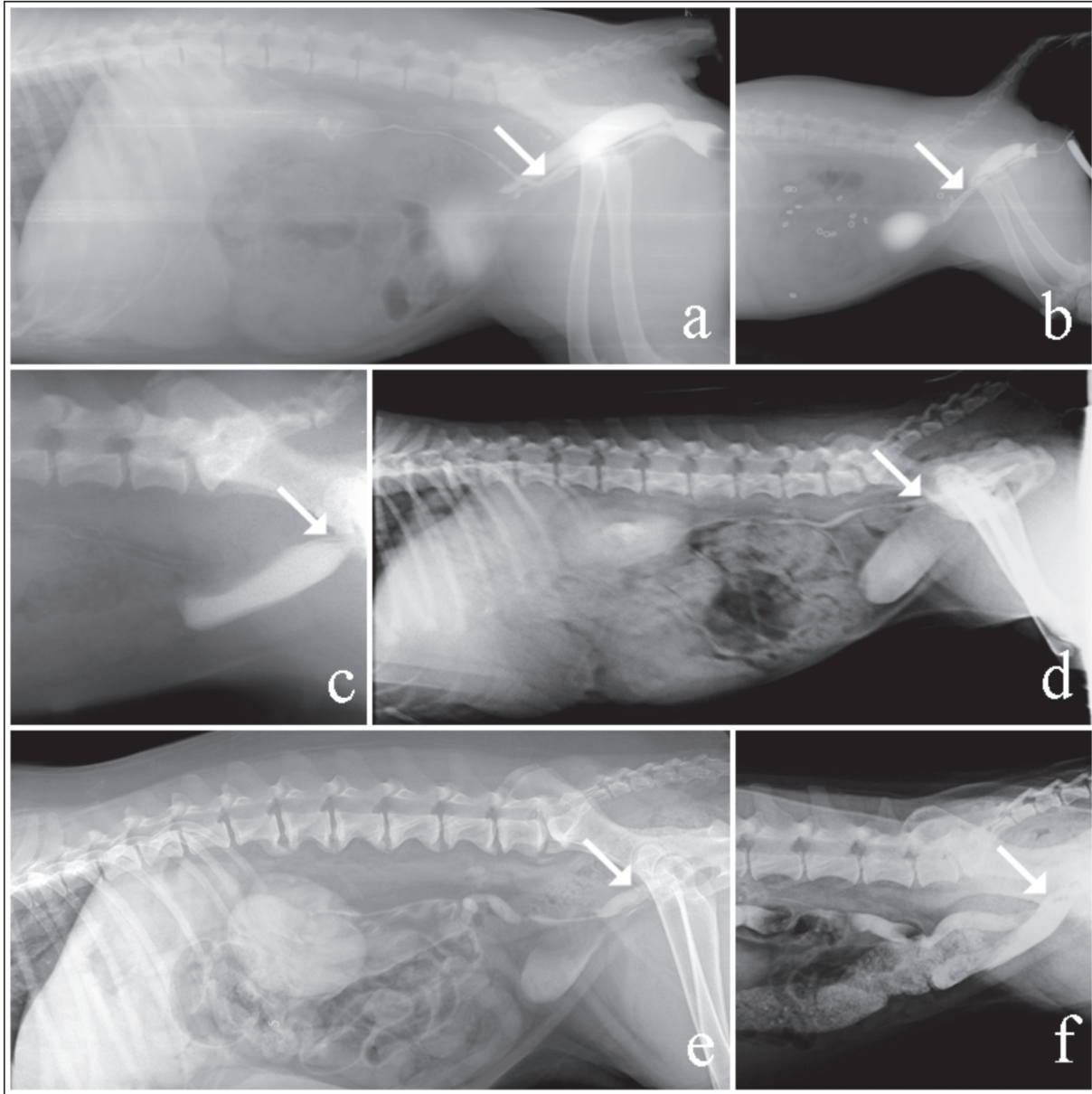
### Excretory Urography

Excretory urography was used to diagnose EU in 6 patients (Case No. 1,2,3,4,5 and 7) (Fig. 1). A 20G intravenous catheter was placed in the vena cephalica antebrachii. Direct LL and VD abdominal X-rays were taken before

**Table 1.** Signalment, diagnostic procedures, features of ureteral ectopia, urinary tract anomalies and postoperative 30th and 60th day incontinence scores of the patients  
**Tablo 1.** Hastaların eşgali, tanı için kullanılan prosedürler, üreteral ektopinin özellikleri, üriner sistem anomalileri ve postoperatif 30. ve 60. gün inkontinens skorları

Case No	Breed	Age (month)	Sex	Type	Diagnosis	Side	Surgical Procedure	Renal Hypoplasia	Ureter Dilatation	Tortuous Ureter	Pelvic Bladder	Hypoplastic Bladder	Post-op 30 <sup>th</sup> day Incontinence Score	Post-op 60 <sup>th</sup> day Incontinence Score
1	Golden Ret.	5	IF	Intramural	EU + RVU + Celiotomy	Unilateral Left	Ureteroneocystostomy	-	-	-	-	-	1	1
2	Golden Ret.	5	IF	Intramural	EU + RVU + Celiotomy	Unilateral Left	Ureteroneocystostomy	-	-	-	-	+	3	1
3	Boston Terrier	11	IF	Intramural	EU + Celiotomy	Unilateral Right	Ureteroneocystostomy	-	-	-	-	-	1	1
4	Golden Ret.	4	IF	Intramural	EU + Celiotomy	Unilateral Left	Ureteroneocystostomy	-	+	+	+	-	3	2
5	Golden Ret.	36	SF	Intramural	EU + Celiotomy	Unilateral Right	Ureteroneocystostomy	Right	+	+	-	-	4	3
6	Golden Ret.	36	SF	Intramural	EU + MRI + Celiotomy	Bilateral	Right Nephroureterectomy Left Ureteroneocystostomy	Left	+	+	-	-	5	5
7	Golden Ret.	19	SF	Intramural	EU + Celiotomy	Unilateral Left	Ureteroneocystostomy	-	+	+	+	-	3	2

Abbreviations: IF, intact female; SF, spayed female; EU, excretory urography; RV, retrograde vagino-urethrography; MRI, magnetic resonance imaging



**Fig 1.** Lateral radiographic view of excretory urography and retrograd vagino-urethrography procedures of case no.1, ectopic ureter (*white arrow*) (a), Lateral radiographic view of excretory urography and retrograd vagino-urethrography procedures of case no.2, ectopic ureter (*white arrow*) (b), Lateral radiographic view of excretory urography of case no.3, ectopic ureter (*white arrow*) (c), Lateral radiographic view of excretory urography of case no.4, ectopic ureter (*white arrow*) (d), Lateral radiographic view of excretory urography of case no.5, ectopic ureter (*white arrow*) (e), Lateral radiographic view of excretory urography of case no.7, ectopic ureter (*white arrow*) (f)

**Şekil 1.** Bir numaralı olgunun ekskretör ürografi ve retrograd vajinoüretrografi işlemi esnasında çekilmiş LL grafisi, ektopik üreter (*beyaz ok*) (a), İki numaralı olgunun ekskretör ürografi ve retrograd vajinoüretrografi işlemi esnasında çekilmiş LL grafisi, ektopik üreter (*beyaz ok*) (b), Üç numaralı olgunun ekskretör ürografi esnasında çekilmiş LL grafisi, ektopik üreter (*beyaz ok*) (c), Dört numaralı olgunun ekskretör ürografi esnasında çekilmiş LL grafisi, ektopik üreter (*beyaz ok*) (d), Beş numaralı olgunun ekskretör ürografi esnasında çekilmiş LL grafisi, ektopik üreter (*beyaz ok*) (e), Yedi numaralı olgunun ekskretör ürografi esnasında çekilmiş LL grafisi, ektopik üreter (*beyaz ok*) (f)

excretory urography. Contrast medium containing 800 mg/kg iodine (Urografin® 76%, 370 mg iodine/mL, Bayer) was administered to the patients as IV bolus. The kidneys, ureters, and bladder were evaluated with radiographs taken at post-injection 1, 5, 10 and 20 min. Because digital fluoroscopy was not used, additional radiographs were taken between 5-10 min post-injection to obtain clear images of the distal parts of the ureters. In radiographs taken in the cystogram phase, whether or not the bladder

neck lies caudally to the cranial border of the pubis (the presence of pelvic bladder) and the presence of persistent urachus was examined and recorded. In cases where a combination of excretory urography and retrograde vagino-urethrography is used (Case 1, Case 2), the procedures were performed under general anesthesia. General anesthesia was induced by IV administration of 5 mg/kg ketamine HCl (Ketalar® 10% vial, Pfizer) after pre-medication with 1 mg/kg xylazine HCl (Rompun® 2%



vial, Bayer) IM. Compression bandage was not applied to the abdomen during the procedure, and enema was not performed on any of the patients.

### **Retrograde Vagino-Urethrography**

Retrograde vagino-urethrography was used to diagnose EU in 2 patients (Case No. 1 and 2) (Fig. 1). For positive-contrast retrograde vagino-urethrography, a 12 FR 2-way latex Foley catheter (Galena®) was inserted in the vaginal opening, and the balloon was inflated. During the administration of contrast medium, curved intestinal forceps was placed in the distal vulva to prevent the falling out of the Foley catheter and contrast medium leakage. Presence of pain response during the placement of the intestinal forceps was checked, because it was reported that, if anesthetic depth is inadequate, the passage of the contrast medium to the urethra fails [6]. In the next step, contrast medium was administered intravenously as explained above, and excretory urography was started. When the passage of contrast medium to the ureters was established by radiography, contrast medium (Urografin® 76%, 370 mg iodine/mL, Bayer) was administered through the Foley catheter at a dose of 1 mL/kg.

### **Magnetic Resonance Imaging (MRI)**

MRI was used to diagnose EU in 1 patient (Case No. 6) (Fig. 2). MRI was performed using 1.5-T Signa Excite (GE Medical Systems, Milwaukee, WI, USA) MRI system under general anesthesia. General anesthesia was induced by IV administration of 5 mg/kg ketamine HCl (Ketalar® 10% vial, Pfizer) after pre-medication with 1 mg/kg xylazine HCl (Rompun® 2% vial, Bayer) IM. The patient was positioned in right lateral and dorsal recumbency. MRI was performed with heavily T2-weighted (T2-W) 2D turbo-spin echo (TSE), sagittal sequences (TR 3572 ms, TE 78 ms, 24 slices, section thickness 4 mm) and coronal sequences (TR 924 ms, TE 75 ms, 21 slices, section thickness 5.0 mm).

### **Surgical Procedure**

In all patients, CBC and serum biochemical parameters were examined pre-operatively. Pre-anesthesia was induced with IV administration of 0.4 mg/kg diazepam (Diazem® Deva). Anesthesia was induced with IV administration of 5 mg/kg ketamine HCl (Ketalar®, Pfizer). After intubation, anesthesia was maintained with 2-3% isoflurane (Isoflurane®, Adeka) and 100% oxygen. The patients were positioned in dorsal recumbency, and ventral and lateral parts of the abdomen were shaved and disinfected. Access to the abdominal cavity was obtained with median celiotomy. The urogenital system was inspected. The kidneys were evaluated for size and shape, and ureters for dilatation and tortuosity. A stay suture was then placed in the apex of the urinary bladder, and access to the urinary bladder was obtained with ventral incision. The course of the ureters and the position of the ureteral orifices were evaluated,

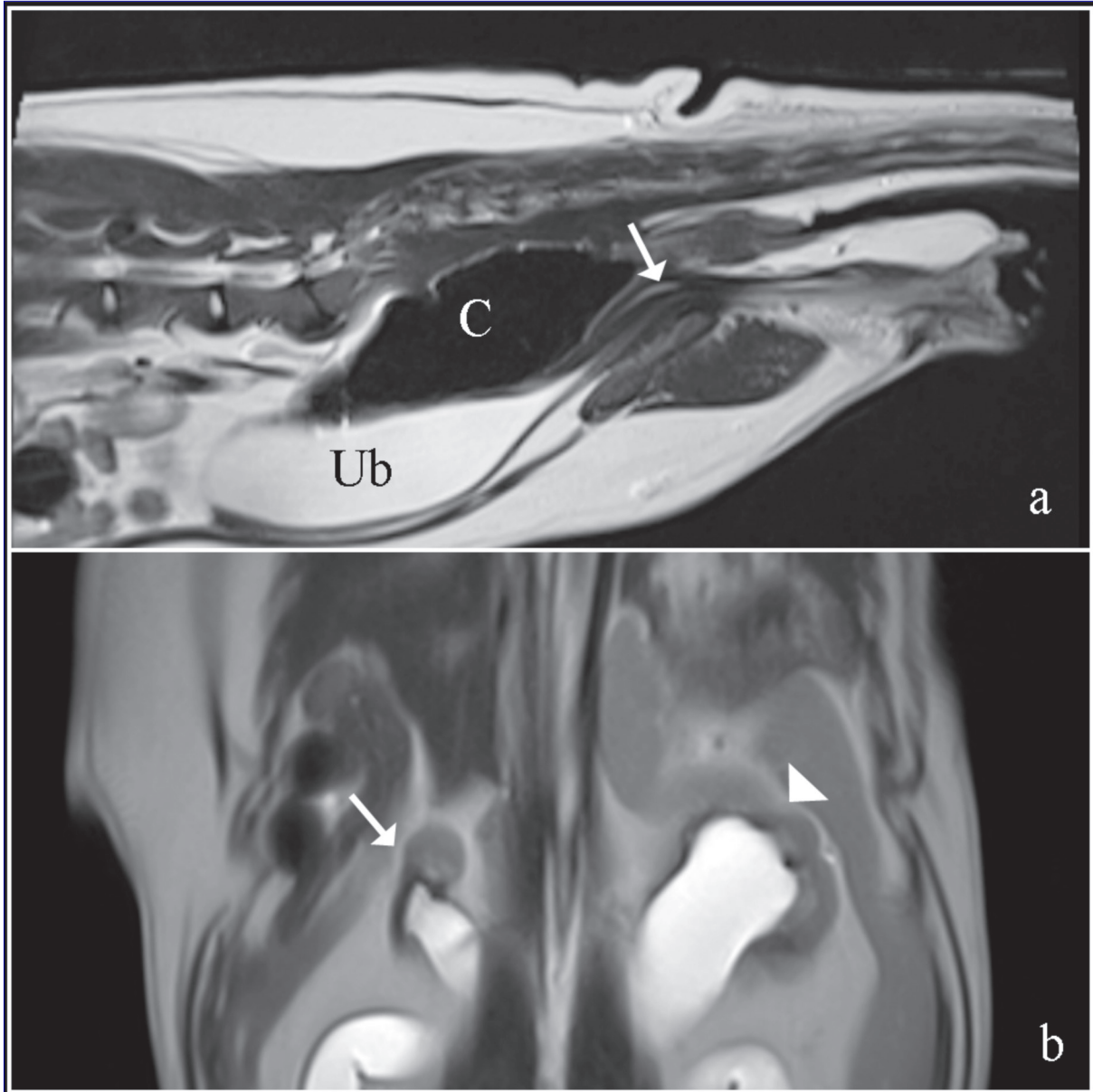
and EU were classified as unilateral, bilateral, extramural or intramural. After accessing the bladder, whether or not the ureters open into the bladder from the normal anatomic position was checked by inserting a closed-end tomcat-style catheter (Buster®, Kruuse) to both ureters. By this means, absolute classification of ureteral ectopia as intramural or extramural could be established.

Surgical treatment was performed with neoureterocystostomy in all patients with EU. In this procedure, the EU was dissected after ligating at the point where it enters the urinary bladder using 2/0 monofilament absorbable suture material (Monocryl®, Ethicon). A longitudinal incision measuring 2-3 mm in length was then made on the distal ureter, after pulled into the bladder from a point between the trigone and apex of the bladder, and the mucosa of the ureter was attached to the mucosa of the urinary bladder with a 5/0 monofilament absorbable suture (Monocryl®, Ethicon) using a simple interrupted pattern. The incision made on the urinary bladder was closed without passing through the mucosa by using a simple interrupted suture technique as the first layer with 2/0 monofilament absorbable suture material (Monocryl®, Ethicon). Continuous Cushing suture technique were used for the second layer with the same suture material. In two cases (Case No. 4 and 7), pelvic bladder was diagnosed and cystopexy was performed before closing the abdomen.

In one case (Case No. 6), it was determined that the right kidney was severely atrophic, and nephroureterectomy was performed. In this procedure, the kidney was removed from the retroperitoneal space using blunt dissection and it was reflected medially. After that, the fat on the renal hilus was dissected, and the vascular pedicle was exposed. The arteria and vena renalis were ligated at a point as close as possible to the aorta abdominalis and vena cava caudalis respectively. The ureter was then separated from the ureteral fascia and it was ligated and cut at the point attached to the urinary bladder.

### **Post-Operative Assessment**

After the patients were awakened in the reanimation room, they were discharged from hospital. Amoxicilline-clavulanic acid (Synulox®, Pfizer) 8.75 mg/kg IM for 10 days and carprofen (Rimadyl®, Pfizer) 2 mg/kg PO for 5 days were prescribed to the patients. No medical treatment was administered to the patients between post-operative 10<sup>th</sup> and 30<sup>th</sup> days. All patients were called to come in for follow-up at post-operative 30<sup>th</sup> and 60<sup>th</sup> days and were evaluated for urinary incontinence although more frequent follow-ups and phone calls were carried out for some patients. Urinary incontinence at post-operative 30<sup>th</sup> and 60<sup>th</sup> days was scored between 1-5. The patients in which complete urinary continence was achieved without any need for additional medical treatment scored 1; the patients in which complete urinary continence was achieved with phenylpropanolamine use scored 2; the patients in



**Fig 2.** MRI images of case no. 6. Saggital t2 view, ectopic ureter suspicion (*white arrow*) (a), Coroner t2 view of the same patient, right atrophic kidney (*white arrow*), left hypoplastic kidney (*arrow head*) (b), C, colon; Ub, urinary bladder

**Şekil 2.** Altı numaralı olgunun magnetik rezonans görüntüleri. Sagital t2 görüntüsü, ektopik üreter şüphesi (*beyaz ok*) (a), Koroner t2 görüntüsü, sağ atrofik böbrek (*beyaz ok*), sol hipoplastik böbrek (*ok başı*) (b), C, kolon; Ub, idrar kesesi

which the complaint of urinary incontinence diminished but still occurred once or twice a week scored 3; the patients in which urinary incontinence persists at the same frequency but at a lower quantity scored 4; and the patients with no regression of urinary incontinence scored 5. Prognosis was considered successful in patients that scored 1 and 2 <sup>[15]</sup>.

## RESULTS

Six of our patients were female Golden Retriever and one was a female Boston Terrier. Their ages varied between 4 and 36 months (average 16.5 months). Three of our patients (43%) had been sterilized, and 4 (53%) were

intact. In sterilized patients, the owners did not know the date of sterilization because they were adopted after the spaying procedure. The history revealed that all dogs had a complaint of continuous urine dribbling. Their neurological examination findings were normal. Clinical examination revealed that all dogs had peri-vulvar dermatitis of varying severities and their urinary bladders were small or normal in size. Four of our patients were diagnosed with left EU, two with right EU and one with bilateral EU. Four patients were diagnosed with ipsilateral ureter dilatation and tortuous ureter, two with renal hypoplasia and pelvic bladder, one with renal atrophy and one with urinary bladder hypoplasia. Reimplantation of the ureter to the urinary bladder was made using neoureterocystostomy in

seven out of eight EU cases. In one EU case, where atrophy developed in the ipsilateral kidney, nephroureterectomy was performed. None of the cases had renal agenesis, ureterocele or persistent urachus (Table 1).

The average urea concentration of our patients was 30.8 mg/dL (reference range 10-55 mg/dL), and the average creatinine concentration was 1.2 mg/dL (reference range 0.6-1.4 mg/dL). Pre-operative urinary culture showed *E. coli* growth in 2 patients (Case 5 and 6) and *Pseudomonas spp.* growth in one patient (Case 7). These patients were administered 8.75 mg/kg IM amoxicillin/clavulanate (Synulox®, Pfizer) and 5 mg/kg IM enrofloxacin (Baytril®, Bayer) for 14 days before the surgery, and the urine culture was repeated. When the urine culture results were negative, the surgery was performed.

In two cases (Case No. 1 and 3) it was determined that complete continence was achieved at post-operative 30<sup>th</sup> day control. Urinary incontinence persisted in varying severities in cases number 2, 4, 5, 6, and 7 (Table 1). Phenylpropranolamine (Proin®, PRN Pharmacal) was prescribed at the dose of 1 mg/kg three times a day for 1 month in cases, number 4, 5, 6, and 7. Oxybutynin (Uropan®, Kocak Farma) was prescribed for case number 2 at the dose of 5 mg/kg (splitting the total dose in half) PO two times a day for 1 month.

It was determined that, urinary continence was completely achieved in cases, number 2, 4, and 7 at post-operative 60<sup>th</sup> day control. At the end of the study, complete continence was achieved in 5 out of 7 patients (71%). The treatment failed in cases number 5 and 6 (29%) (Table 1).

## DISCUSSION

The decision about which surgical technique will be used for the treatment of EU in dogs is made based on the morphology of the EU [20]. Generally, neoureterostomy is preferred in the surgical treatment of intramural EU, and neoureterocystostomy is the preferred surgical technique for the treatment of extramural EU [24,17]. However, it is also known that this is not a hard and fast rule, which means that in some cases, neoureterocystostomy can be used for the surgical treatment of intramural EU [5,21]. For example, intramural EU is hard or sometimes impossible to treat with neoureterostomy in male dogs with prostatomegaly, small dog breeds in which catheterization of the distal ureteral segment is difficult [5] and in cases where EU opens into the distal urethra and vagina [2]. In neoureterostomy, surgical intervention to the distal ureteral segment can be performed while a new ureter stoma is created in the normal anatomic position. These surgical interventions can be classified as ligating the distal ureteral segment [2], complete resection of the distal submucosal ureteral tunnel [19] or resection of the intravesical part of the distal submucosal ureteral tunnel [13] have also been described.

In addition to these techniques performed in combination with celiotomy and cystotomy, cystoscopic-guided laser ablation was also used for the same purpose [18]; however, it has certain disadvantages such as requiring special equipment and experience [15].

The main motivation in the treatment of EU is achieving complete urinary continence. The persistence of urinary incontinence in the post-operative period is attributed to urethral sphincter mechanism incompetence (USMI), recanalization of the distal ureteral segment despite ligation, insufficient urethral closure due to failure to remove the distal ureteral segment or poorly developed trigone [13]. At this point, it is beneficial to analyze the relationship between the surgical method to chosen in the treatment of EU and post-operative incontinence scores. The reason for efforts to describe new neoureterostomy techniques over time is that efforts have been made to improve post-operative incontinence scores.

It is believed that the more intact the urethra sphincter is, the less likely post-operative urinary incontinence is, particularly in female dogs [15]. Given that EU most commonly terminate at the urethra, structural degenerations of the urethra and USMI can occur because it is continuously exposed to urine and is open to bacterial infections until the EU diagnosis is made. Therefore, one might think that, performing a surgical intervention to the distal ureteral segment in urethra that is already damaged to varying degrees, may not provide a significant improvement in post-operative incontinence scores [13].

Reichler et al. [13] used the neoureterostomy technique for the treatment of intramural EU but resected only the part of the distal ureteral segment that is in the bladder wall and did not touch the part in the urethra. The reason for this is they wanted to avoid further damage to the sphincter by urethrotomy because USMI is frequently observed in EU patients. At the end of the study, they found no difference between the post-operative incontinence scores achieved in studies where neoureterostomy was performed without resection of the distal ureteral segment and those achieved following neoureterocystostomy and their own results, which forced them to conclude that resection of the distal ureteral segment is unnecessary. In other words, they demonstrated that the effect of recanalization or removal of the distal ureteral segment on the elimination of urinary incontinence in the post-operative period is not as important as thought.

As a matter of fact, these results demonstrate that an observation made years ago is still valid: 'There is no study which successfully establishes the correlation between classifying EU by their morphological characters and choosing a method specific to this morphology and the results achieved with the recommended surgical methods' [2]. The rate of persisting urinary incontinence following surgical treatment of intramural EU using different neoureterostomy



techniques varies between 42% and 78% [19]. The urinary incontinence scores achieved with cystoscopic-guided laser ablation, which has begun to be used recently, is similar to those achieved with neoureterostomy and neoureterocystostomy [15].

Another reason why urinary incontinence persists in the post-operative period in dogs with EU is reported to be USMI [5,13,20]. We were unable to conduct a pre-operative urethral pressure profile measurement in our study. However, it is a fact that no clear relationship was found between the measurement of maximal urethral closure strength by pre-operative urethral pressure profilometry and post-operative incontinence prognosis [19].

Although the definitive diagnosis of EU can be made by cystotomy, we generally need to use an additional imaging technique to support our suspicion about the presence of ureteral ectopia in pre-operative period. As we mentioned above, several techniques can be used to diagnose EU, excretory urography and retrograde vagino-urethrography are simple and cost effective techniques and can be used where ever x-ray machine available. In excretory urography, it is possible to diagnose ureteral ectopia at 5-10 min post-injection of IV contrast medium and we successfully used excretory urography 6 of 7 patients. But in one case (Case No. 6), ureteral ectopia could not be diagnosed even at 45<sup>th</sup> min post injection of contrast medium and just ureteral dilation was determined. In other words, excretory urography did not provide enough information about presence of EU. In this case, the age of the patient was 3 and information about medical history were pure since the dog was adopted from an animal shelter a couple of weeks ago. Because of these reasons, it was thought that, using an advanced imaging technique before laparotomy could be useful. Although transurethral cystoscopy is considered most reliable method, we could not use because of appropriate cystoscopy system was not available. MRI was used as advanced imaging technique to diagnose ectopic ureter in this case although we could be used computed tomography. The main reason to prefer MRI was, it could be achieved to provide more detailed information about other soft tissue structures in abdomen at the same time when compared to computed tomography. Also a distal ureteral segment was determined at sagittal section due to MRI (Fig. 2-b).

Estrogen or phenylpropanolamine could be use in the treatment of USMI. Estrogen increases the closure pressure of the urethra by synthesizing new alpha receptors. On the other hand, phenylpropanolamine like alpha adrenergic agonists increases the closure pressure of the urethra by stimulating these receptors [22]. Phenylpropanolamine is usually used in the treatment of post-operative urinary incontinence, and it has gained a sit even in scoring post-operative incontinence [15]. In our study, we used phenylpropanolamine for 1 month in 4 patients with persistent urinary incontinence between post-operative

30<sup>th</sup> and 60<sup>th</sup> days and it was observed that complete continence was achieved in 2 patients.

Peri-vulvar dermatitis is a clinical examination finding that encountered due to continuous contact with urine of the peri-vulvar region and is frequently observed in dogs with EU [2,5]. Although we observed peri-vulvar dermatitis in all of our patients, this condition was very severe and dermatitis in a much more extensive area than peri-vulvar region, including the posterior part of the hindlimbs was determined in two cases (Case No. 5 and 6). In these two cases we were not achieved to stop urine dribbling despite of the phenylpropanolamine use. Even though it could not be evaluated objectively, the prognosis should be accepted doubtful in female dogs with urinary incontinence due to EU when dermatitis is so severe and constant urine dribbling causes a large part of the coat in the posterior area of the hindlims to be considerably moist.

Case number 2 was diagnosed with urinary bladder hypoplasia during the pre-operative radiography and intra-operative examination. In this case, persistence of urinary incontinence at post-operative 30 days was attributed to the urinary bladder hypoplasia, and only oxybutynin was prescribed. Oxybutynin is an anti-muscarinic agent that increases the urine storage capacity of the bladder [11]. Complete continence was achieved following oxybutynin use for 1 month in this case. We did not choose to use phenylpropanolamine in this case because the patient had not had its first estrus cycle. Our prediction that the estrogen that would be secreted during the first estrus cycle would raise the alpha-receptor count in the urethra and thus increase the closing strength of the urethra sphincter proved to be correct.

However, we preferred phenylpropanolamine in case number 4 even though she also had not had her first estrus cycle. The reason for this was that unlike cases who had not reached puberty, this case had dilated and tortuous ureter and pelvic bladder. Even though the bladder neck was reflected into the abdomen via cystopexy during the operation, phenylpropanolamine was used to eliminate the adverse effects of pelvic bladder on the urethra sphincter mechanism, and complete continence was achieved at the follow-up at post-operative 60 days.

Excretion of urine directly without accumulation in the bladder makes the urinary system susceptible to infections. A study reported that the prevalence of urinary system infections in dogs with EU is 64% [23]. We found urinary system infections in 3 of our patients (43%) in our study. The negative effect of bacterial toxins on the tonus of smooth muscles [8] causes USMI in dogs with EU and thus can be considered one of the factors that cause the incontinence to persist in the post-operative period. However, urinary system infections are not considered the primary cause of persistent post-operative urinary incontinence [1]. In our study, 3 cases were diagnosed with pre-operative urinary



system infection. Bacterial culture analysis revealed *E. Coli* growth in 2 of our patients, and *Pseudomonas spp.* growth in 1 of them. Urinary continence could not be achieved in 2 of our patients in which we isolated *E. coli*. The treatment was successful in our patient with *Pseudomonas spp.* growth. This result was consistent with a previous study which reported that post-operative urinary incontinence is quite hard to cure in patients with *E. coli* growth [1].

On the other hand, complete continence is reportedly achieved after the first estrous cycle in approximately 50% of female puppies suffering from this condition without surgical intervention [5]. In the light of this argument, postponing surgical treatment in dogs diagnosed with EU before the first estrus cycle might be considered. However, it is recommended that surgical treatment should be administered as soon as possible to prevent the development of secondary abnormalities such as hydronephrosis and hydroureter, which may cause ascending urinary system infections or urinary tract obstruction, even in cases where complete continence can be achieved with medical treatment [17]. Three of the cases (cases number 1, 2, and 4) were puppies which have not had their estrous yet, and we achieved successful results in these patients.

Several breeds are reported to be predisposed to EU. These include Siberian Husky, Miniature and Toy Poodles, Golden Retriever, Labrador Retriever, Shetland Sheepdogs, Spaniels, West Highland White Terrier, Wire Fox Terrier, Bulldog and Newfoundland [3,8]. Of these breeds, Labrador Retriever dogs are reported to have a better prognosis of post-operative urinary incontinence compared to other breeds [13,24]. Studies show that Golden Retriever breed dogs are related to Labrador Retriever dogs and they have similar chromosome structures [25]. Of the 7 dogs diagnosed with EU in our study, 6 (86%) were Golden Retrievers, and we achieved complete urinary continence in 4 (67%) of them. This is important for showing that the results obtained in this study and previous studies evaluating the results of surgical treatment of EU in dogs may vary based on the breed distribution of the population.

EU is usually accompanied by other urinary and urogenital system abnormalities such as renal agenesis, dysplasia and hypoplasia, hydronephrosis, ureter dilatation, tortuous ureter, pelvic bladder, hypoplastic bladder, urachal remnant, paramesonephric remnant, vaginal septum and dual vagina [2,18,26-28]. Paramesonephric remnant, vaginal septum and dual vagina is quite hard to diagnose without cystoscopy [18]. Other abnormalities can be diagnosed by excretory urography, ultrasonography and celiotomy [2,8,13].

In dogs with EU, ureter dilatation is frequently observed [10,21,29,30]. It is thought that this condition develops congenital or secondary to functional or physical ureteral obstruction or chronic pyelonephritis. However, its definitive pathogenesis has not been established.

Experience shows that partial ureteral obstructions impair ureteral functions but peristaltic contractions can still continue. However, ureteral contractions reportedly disappear and ureteral functions are impaired in the presence of chronic ureteral obstruction accompanied by infection [21,31]. Ureteral dilatation is observed in 59% - 76% of dogs with EU [32]. We found ureteral dilatation and tortuous ureter in four of our cases (57%). However, post-operative changes in ureteral dilatation could not be observed because long-term post-operative follow-up could not be carried out.

Cases 5 and 6 were diagnosed with renal hypoplasia and their treatment failed. In addition, dermatitis, induced by continuous urinary incontinence affected not only the peri-vulvar region but a much more extensive area including the skin surface and coat on the posterior part of the femur in these two cases. These patients also had bacterial growth in their pre-operative urine cultures. Right nephroureterectomy was performed in case number 6, which we diagnosed with bilateral EU, because the right kidney was completely atrophic, but neoureterocystostomy was performed despite the presence of left renal hypoplasia.

In conclusion, various factors such as age, breed, gender, sterilization, the presence of urinary system infections, location of the bladder and other urinary system abnormalities accompanying EU may affect the result of the surgery in dogs with EU. Additionally, the results obtained with different surgical techniques in different populations where the aforementioned factors were heterogeneous did not provide clear guidance to veterinarians for selecting the appropriate technique. On the other hand, the post-operative incontinence scores that we achieved with neoureterocystostomy in the surgical treatment of 7 dogs with intramural EU are similar to those achieved with different neoureterostomy techniques. The results we achieved suggest that EU can be most successfully managed with a surgical method that does not involve urethrotomy and it should be combined with a surgical method which is used in the treatment of USMI and post-operative alpha adrenergic medications.

## REFERENCES

1. **McLaughlin R, Miller CW:** Urinary incontinence after surgical repair of ureteral ectopia in dogs. *Vet Surg*, 20, 100-103, 1991. DOI: 10.1111/j.1532-950X.1991.tb00315.x
2. **McLoughlin MA, Chew DJ:** Diagnosis and surgical management of ectopic ureters. *Clin Tech Small Anim Pract*, 15, 17-24, 2000. DOI: 10.1053/svms.2000.7302
3. **Novellas R, Stone J, Pratschke K, Hammond G:** Duplicated ectopic ureter in a nine-year-old Labrador. *J Small Anim Pract*, 54, 386-389, 2013. DOI: 10.1111/jsap.12056
4. **McLoughlin MA, Bjorling DE:** Ureters. In, Slatter D (Ed): Textbook of Small Animal Surgery. Vol. 2. 3<sup>rd</sup> edn., 1619-1628, Saunders, Philadelphia, 2003.
5. **Hoelzler MG, Lidbetter DA:** Surgical management of urinary

incontinence. *Vet Clin Small Anim Pract*, 34, 1057-1073, 2004. DOI: 10.1016/j.cvsm.2004.03.003

**6. Holt PE:** Urinary incontinence. In, Holp PE (Ed): Urological Disorders of the Dog and Cat Investigation, Diagnosis and Treatment. 134-142, Manson, London, 2008.

**7. Gultekin C, Ozgencil E, Seyrek-Intas D:** The effect of deslorelin acetate in the treatment of persistent urinary incontinence after operation of ectopic ureter in a Golden Retriever bitch. *Kafkas Univ Vet Fak Derg*, 22, 465-468, 2016. DOI: 10.9775/kvfd.2015.14628

**8. Oglesby PA, Carter A:** Ultrasonographic diagnosis of unilateral ectopic ureter in a Labrador dog. *JSAVA*, 74, 84-86, 2003. DOI: 10.4102/jsava.v74i3.517

**9. Hayes HM:** Ectopic ureter in dogs: Epidemiologic features. *Teratology*, 10, 129-132, 1974. DOI: 10.1002/tera.1420100206

**10. Holt PE, Gibbs C, Pearson H:** Canine ectopic ureter a review of twenty nine cases. *J Small Anim Pract*, 23, 195-208, 1982. DOI: 10.1111/j.1748-5827.1982.tb01658.x

**11. Fischer J, Lane IF:** Micturation Disorders. In, Bartges J, Polzin DJ (Eds): Nephrology and Urology of Small Animals. 755-778, Wiley Blackwell, Malaysia, 2011.

**12. Sach J, Möller S:** Ectopic ureter in a seven-week-old Tibetan terrier using MRI imaging. *Kleintierpraxis*, 54, 688-694, 2009.

**13. Reichler IM, Specker CE, Hubler M, Alois B, Haessig M, Arnold S:** Ectopic ureters in dogs: Clinical features, surgical techniques and outcome. *Vet Surg*, 41, 515-522, 2012. DOI: 10.1111/j.1532-950X.2012.00952.x

**14. Mason LK, Stone EA, Biery DN:** Surgery of ectopic ureters: pre and postoperative radiographic morphology. *JAAHA*, 26, 73-79, 1990.

**15. Smith AL, Radlinsky MG, Rawlings CA:** Cystoscopic diagnosis and treatment of ectopic ureters in female dogs: 16 cases (2005-2008). *JAVMA*, 237, 191-195, 2010. DOI: 10.2460/javma.237.2.191

**16. Cannizzo KL, McLoughlin MA, Mattoon JS, Samii VF, Chew DJ, Dibartola SP:** Evaluation of transurethral cystoscopy and excretory urography for diagnosis of ectopic ureters in female dogs: 25 cases (1992-2000). *JAVMA*, 223, 475-481, 2003. DOI: 10.2460/javma.2003.223.475

**17. Fossum TW:** Surgery of the kidney and ureter. In, Fossum TW (Ed): Small Animal Surgery. 549-568, Mosby, China, 2012.

**18. Berent AC, Weisse C, Mayhew PD, Todd K, Wright M, Bagley D:** Evaluation of cystoscopic-guided laser ablation of intramural ectopic ureters in female dogs. *JAVMA*, 240, 716-724, 2012. DOI: 10.2460/javma.240.6.716

**19. Mayhew PD, Lee KCL, Gregory SP, Brockman DJ:** Comparison of

two surgical techniques for management of intramural ureteral ectopia in dogs: 36 cases (1994-2004). *JAVMA*, 229, 389-393, 2006. DOI: 10.2460/javma.229.3.389

**20. Newman M, Landon B:** Surgical treatment of a duplicated and ectopic ureter in a dog. *J Small Anim Pract*, 55, 475-478, 2014. DOI: 10.1111/jsap.12227

**21. Steffey MA, Brockman DJ:** Congenital ectopic ureters in a continent male dog and cat. *JAVMA*, 224, 1607-1610, 2004. DOI: 10.2460/javma.2004.224.1607

**22. Reichler IM, Hubler M:** Urinary incontinence in the bitch: An update. *Reprod Dom Anim*, 49 (Suppl. 2): 75-80, 2014. DOI: 10.1111/rda.12298

**23. Stone EA, Mason LK:** Surgery of ectopic ureters: types, method of correction, and postoperative results. *JAAHA*, 26, 81-88, 1990.

**24. Wiegand U, Rickel RF, van den Brom WE:** Prognostic factors in the treatment of canine ectopic ureters. *Kleintierpraxis*, 41, 157-167, 1996.

**25. Sutter NB, Eberle MA, Parker HG, Pullar BJ, Kirknes EF, Kruglyak L, Ostrander EA:** Extensive and breed-specific linkage disequilibrium in *Canis familiaris*. *Genome Res*, 14, 2388-2396, 2004. DOI: 10.1101/gr.3147604

**26. Agut A, Fernández del Palacio MJ, Laredo FG, Murciano J, Bayon A, Soler M:** Unilateral renal agenesis associated with additional congenital abnormalities of the urinary tract in a Pekingese bitch. *J Small Anim Pract*, 43, 32-35, 2002. DOI: 10.1111/j.1748-5827.2002.tb00007.x

**27. Taney KG, Moore KW, Carro T, Spencer C:** Bilateral ectopic ureters in a male dog with unilateral renal agenesis. *JAVMA*, 223, 817-820, 2003. DOI: 10.2460/javma.2003.223.817

**28. Yoon HY, Mann FA, Punke JP, Jeong SW:** Bilateral ureteral ectopia with renal dysplasia and urolithiasis in a dog. *JAAHA*, 46, 209-214, 2010. DOI: 10.5326/0460209

**29. Dean PW, Bojrap MJ, Constantinescu GM:** Canine ectopic ureter. *Compend Contin Educ Pract Vet*, 10, 146-157, 1988.

**30. Holt PE, Moore AH:** Canine ureteral ectopia: An analysis of 175 cases and comparison of surgical treatments. *Vet Rec*, 136, 345-349, 1995. DOI: 10.1136/vr.136.14.345

**31. Rose JG, Gillenwater JY:** The effect of chronic ureteral obstruction and infection upon ureteral function. *Invest Urol*, 11, 471-478, 1974.

**32. Samii VF, McLoughlin MA, Mattoon JS, Drost WmT, Chew DJ, Dibartola SP, Woodard SH:** Digital fluoroscopic excretory urography, digital fluoroscopic urethrography, helical computed tomography, and cystoscopy in 24 dogs with suspected ureteral ectopia. *J Vet Intern Med*, 18, 271-281, 2004. DOI: 10.1111/j.1939-1676.2004.tb02545.x