

## Mitotane-Induced Hypoadrenocorticism in a Dog with Hyperadrenocorticism <sup>[1]</sup>

Ekrem Çağatay ÇOLAKOĞLU <sup>1</sup>  Ali Evren HAYDARDEDEOĞLU <sup>2</sup>  
Hadi ALİHOSSEİNİ <sup>1</sup> Arif KURTDEDE <sup>1</sup>

<sup>[1]</sup> This case report has been accepted as poster presentation by the scientific committee of 5<sup>th</sup> Turkish Small Animal Veterinary Association (TSAVA) Congress, 2010, İstanbul, Turkey

<sup>1</sup> Ankara University, Faculty of Veterinary Medicine, Department of Internal Medicine, TR-06110 Ankara - TURKEY

<sup>2</sup> Aksaray University, Faculty of Veterinary Medicine, Department of Internal Medicine, TR-68100 Aksaray - TURKEY

Article Code: KVFD-2014-11933 Received: 09.07.2014 Accepted: 03.09.2014 Published Online: 22.09.2014

### Abstract

A 5-year-old, Terrier breed dog having the complaints of anestrus, polyuria, polydipsia and alopecia referred to Small Animal Veterinary Teaching Hospital. Paraclinical and clinical assessments confirmed the diagnosis of pituitary-dependent hyperadrenocorticism and Mitotane (25 mg/kg BID 5 days) prescribed. The dog was presented to clinic with the signs of vomiting, ataxia and weakness after two weeks. The owner reported that Mitotane therapy continued for 14 days without decreasing the dosage contrary to what is describe. Routin blood work and basal cortisol concentration revealed severe hypoglycemia and hypocortisolemia. Methylprednisolone acetate and supportive therapy were initiated. The dog died after three weeks according to owner's information. This case report emphasized that one of the possible complication of Mitotane therapy is hypoadrenocorticism.

**Keywords:** Mitotane, Hypoadrenocorticism, Dog, Hyperadrenocorticism

## Hiperadrenokortisizimli Bir Köpekte Mitotan Kullanımına Bağlı Gelişen Hipoadrenokortisizm

### Özet

5 yaşlı Terrier ırkı köpek, anöstrus, poliüri, polidipsi ve alopesi şikayetleriyle küçük hayvan hastanesine getirildi. Klinik ve paraklinik değerlendirmeler hipofiz kaynaklı hiperadrenokortisizmi doğruladı ve hastaya Mitotan (25 mg/kg BID 5 gün) reçete edildi. İki hafta sonra hasta; kusma, ataksi ve güçsüzlük şikayetleriyle getirildi. Hasta sahibi; herhangi bir dozaj azaltımı yapmaksızın, önerim dışı olarak Mitotan tedavisine 14 gün boyunca devam ettiğini belirtti. Rutin kan analizleri ve bazal kortizol ölçümlerinde şiddetli hipoglisemi ve hipokortisolemi belirlendi. Metilprednisolon asetat ve destekleyici sağaltıma başlandı. 3 hafta sonra hasta sahibinden köpeğin öldüğü bilgisi alındı. Bu olgu sunumu ile Mitotan tedavisinin olası komplikasyonunun hipoadrenokortisizm olabileceği vurgulanmıştır.

**Anahtar sözcükler:** Mitotan, Hipoadrenokortisizm, Köpek, Hiperadrenokortisizm

### INTRODUCTION

Cushing's disease is a common endocrinological disorder of middle to old age dogs. A breed predisposition has been particularly noted in the Miniature Poodles, German Shepherds, Dachshunds, Boxers, Terriers and Beagles <sup>[1]</sup>. Cushing's Syndrome is characterised by the symptoms of polyuria, polydipsia, polyphagy, alopecia, pendulous abdomen, lethargy, recurrent urinary tract disease, hypotrichosis, hyperpigmentation, comedones and calcinosis cutis. Less common symptoms include

hypertension, pulmonary thromboembolism, testicular atrophy, clitoral hypertrophy, anestrus, facial paralysis and corneal ulceration <sup>[2]</sup>. Pituitary-dependent hyperadrenocorticism (PDH) is responsible for 80% of all naturally occurred cases and more than 90% of dogs with PDH have a pituitary tumor. The pituitary tumors secreting excessive amounts of cortisol could be tiny (microadenoma) not easily identified by magnetic resonance imaging (MRI) <sup>[3]</sup>.

Dogs with Cushing's disease have the stress leukogram,



### İletişim (Correspondence)



+90 534 4304355



colakoglu@ankara.edu.tr

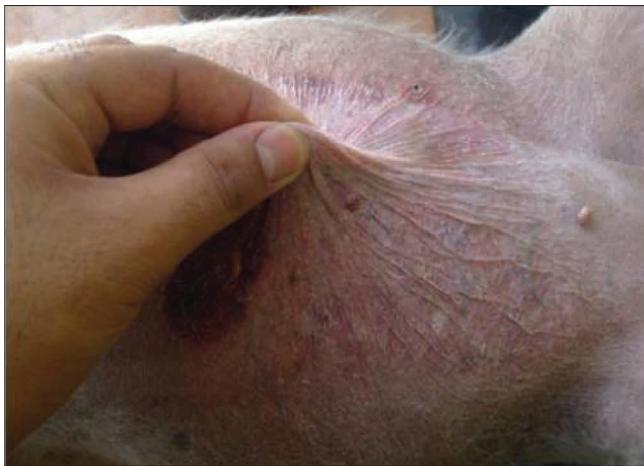thrombocytosis (403.000-1.140.000 platelet/ $\mu$ l) and remarkable elevation of serum alkaline phosphatase level [4]. Hypercortisolemia is the most prominent sign for the Cushing's disease [5]. Thyroid hormone levels may be slightly low because of the suppression of glucocorticoids on TSH in dogs with Cushing's disease [3]. Adrenocorticotropic hormone stimulation and low-high dose dexamethasone suppression tests may be required for a definite diagnosis. Useful diagnostic tools to identify etiopathologic changes in Cushing's disease include abdominal radiography, ultrasonography and MRI. Options of surgery, radiation, adrenalectomy, hypophysectomy or medical therapy (Mitotane, Trilostane etc.) have been reported for treating hyperadrenocorticism in dogs [5].

Hypoadrenocorticism as an overlooked condition results from primary or secondary etiological reasons. Mitotane used for the control of PDH causes selective and progressive necrosis, cytotoxic effects on adrenal cortex and iatrogenic hypoadrenocorticism even when carefully procedure of dosing [6,7].

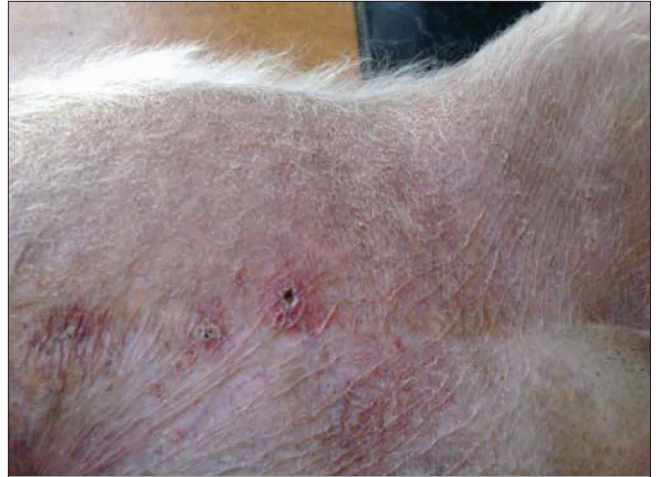The purpose of this case report is to focus on the monitoring of Mitotane therapy in a dog with hyperadrenocorticism.

## CASE HISTORY

A 5-year-old, 12 kg female, Terrier breed dog having the complaints of anestrus, polyuria, polydipsia and alopecia referred to Small Animal Veterinary Teaching Hospital. Alopecia, thin skin with hyperpigmentation, calcinosis cutis and vascularization and, pendulous abdomen were remarkable in physical examination (Fig. 1-2). Initial diagnostic tests included complete blood count (CBC), liver function (Alkaline phosphatase, Alanin aminotransferase, Aspartate aminotransferase, Gamma-glutamyl transferase), some electrolyte analysis (Sodium, Potassium, Chloride) and high dose dexamethasone

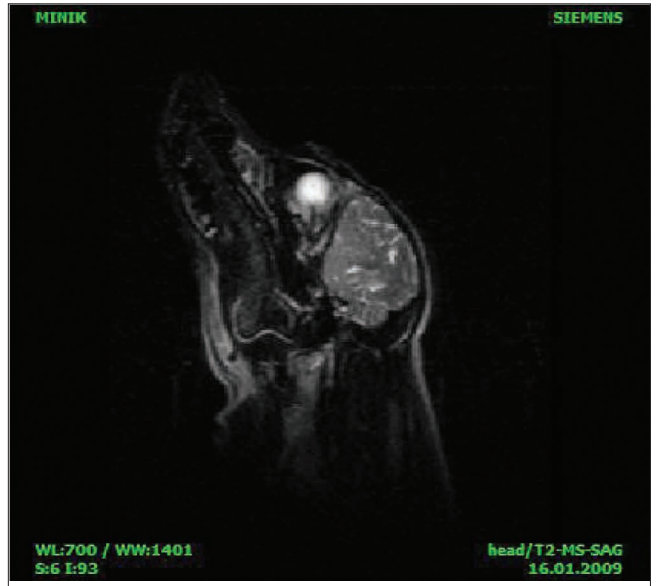


**Fig 1.** Alopecia, thin skin and vascularization  
**Şekil 1.** Alopesi, incelmış deri ve damarlaşma



**Fig 2.** Calcinosis cutis

**Şekil 2.** Kalsinozis kutis



**Fig 3.** MRI imaging

**Şekil 3.** Hastanın MR görüntülemesi

suppression test. CBC revealed no abnormalities. High alkaline phosphatase (1301 IU/L; reference range [8], 20-156 IU/L), alanine aminotransferase (309 IU/L; reference range [8], 21-102 IU/L), glutamyl transferase (353 IU/L; reference range [8], 1.2-6.4 IU/L) and slightly elevated aspartate aminotransferase (93 IU/L; reference range [8], 23-66 IU/L) were noted. Serum sodium (149 mmol/l), potassium (3.9 mmol/l) and chloride (111 mmol/l) concentrations were obtained. The sodium:potassium (Na:K) ratio was 38 (reference range, 27-40 [8]). The analysis revealed total thyroxine (tT<sub>4</sub>) and free thyroxine (fT<sub>4</sub>) concentrations as 1.30  $\mu$ g/dl and 7.00 pmol/L respectively (tT<sub>4</sub>, reference range, 1.20-3.00  $\mu$ g/dl; fT<sub>4</sub>, reference range, 9.00-42.50 pmol/L). An increase in basal cortisol levels (28.50  $\mu$ g/dl; reference range [8], 0.96-6.81  $\mu$ g/dl) was also determined. The presence of hepatomegaly was

detected by abdominal ultrasonography. Any adrenal or pituitary masses and contour deformities were defined by ultrasonography and MRI (Fig. 3). High dose Dexamethasone suppression test (0.1 mg/kg dexamethasone IV) was performed for the suspicion of hyperadrenocorticism. Post-dexamethasone cortisol concentrations were 6.1 µg/dl and 0.3 µg/dl at 4 and 6 h respectively. Paraclinical and clinical assessments confirmed the diagnosis of PDH. Mitotane (Lysodren®; 25 mg/kg BID 5 days) was prescribed for the dog. Fourteen days later the dog was presented to clinic with the signs of vomiting, ataxia and weakness. The owner reported that Mitotane therapy continued for 14 consecutive days in the same dose. Routin blood work and basal cortisol concentration revealed severe hypoglycemia (44 mg/dl; reference range [8], 70-120 mg/dl) and hypocortisolemia (<0.1 ng/dl; reference range [8], 1-6 µg/dl). In spite of optimal medical therapy with Methylprednisolone acetate (Prednol tablet®; 1 mg/kg) and supportive therapy, the dog died three weeks later.

## DISCUSSION

Although new therapeutic options have been introduced, Mitotane is still the most common medical therapy for hyperadrenocorticism in dogs [9]. The therapeutic goal of the Mitotane as an adrenocorticolitic agent for dogs with PDH should be to provide the relatively hypoadrenal state without causing excessive Adrenocorticotrophic hormone stimulation. For decreasing serum cortisol concentration, induction therapy with Mitotane is initiated at a dose of 25 mg/kg BID for 5 following days. Cortisol concentration falls in reference range during the induction phase. After induction therapy, Mitotane is administered for two times in a week with decreasing the dosage [10]. The adverse effects of Mitotane therapy associated with the gastrointestinal and neurologic signs can develop during the induction phase. The adverse effects include anorexia, episodes of

vomiting, diarrhea, ataxia and weakness and decreases in water consumption. Long term Mitotane administration in induction phase may cause Addisonian crisis [3]. In a study of 200 dogs treated with induction doses of Mitotane, adverse effects developed in 50 dogs [10]. In this case report, using Mitotane for 14 days by the owner instead of 5 days caused adverse effects and death in a dog with hyperadrenocorticism.

Veterinarians should be careful during the therapy period while using Mitotane in dogs. It is a necessity to follow the adverse clinical signs by the owners. In the third day of the induction phase (25 mg/kg BID), identifying the basal cortisol levels to prevent Addisonian crisis may be lifesaving.

## REFERENCES

1. **Kaufman J:** Diseases of the adrenal cortex of dogs and cats. *Mod Vet Pract*, 65 (6): 429-434, 1984.
2. **Kooistra HS, Galac S:** Recent advances in the diagnosis of Cushing's syndrome in dogs. *Vet Clin North Am: Small Anim Pract*, 40 (2): 259-267, 2010.
3. **Melian C:** Hyperadrenocorticism in dogs. In, Ettinger SJ, Feldman EC (Eds): Textbook of Veterinary Internal Medicine. 7<sup>th</sup> ed., 1816-1840, Saunders, Philadelphia, 2010.
4. **Peterson ME:** Diagnosis of hyperadrenocorticism in dogs. *Clin Tech Small Anim Pract*, 22 (1): 2-11, 2007.
5. **Brown CG, Graves TK:** Hyperadrenocorticism: treating dogs. *Compendium*, 132-145, 2007.
6. **Sande A, Lanen KV:** Canine hypoadrenocorticism: Pathogenesis, diagnosis, and treatment. *Topics Comp Anim Med*, 29 (2): 1-7, 2014.
7. **Baumstark ME, Sieber-Ruckstuhl NS, Müller C, Wenger M, Boretti FS, Reusch CE:** Evaluation of aldosterone concentrations in dogs with hypoadrenocorticism. *J Vet Intern Med*, 28, 154-159, 2014.
8. **Kaneko JJ, Harvey JW, Bruss ML:** Clinical Biochemistry of Domestic Animals. 8<sup>th</sup> ed., 889-895, Academic Press, 2008.
9. **Feldman EC, Nelson RW:** Canine and Feline Endocrinology and Reproduction. 3<sup>rd</sup> ed., 252-353, St. Louis, WB Saunders, 2004.
10. **Kintzer PP, Peterson ME:** Mitotane (o, p'-DDD) treatment of 200 dogs with pituitary-dependent hyperadrenocorticism. *J Vet Intern Med*, 5 (3): 182-190, 1991.