

***Ascaridia* sp. Infection in A Cockatiel in Turkey (Türkiye'de Bir Kokateil'de *Ascaridia* sp. Enfeksiyonu)**

C. Çağrı CINGI *  Turan CİVELEK * Armağan E. ÜTÜK **

* Afyon Kocatepe University, Faculty of Veterinary Medicine, Department of Internal Medicine, TR-03200 Afyonkarahisar - TURKEY

** Central Veterinary Control and Research Institute, Parasitology and Bee Diseases Laboratory, TR-06020 Ankara - TURKEY

Makale Kodu (Article Code): KVFD-2010-2923

Dear Editor,

In the present letter, *Ascaridia* sp. infection and efficiency of pyrantel pamoate treatment in a cockatiel was described and concurrently this case was the first report in Turkey.

Ascarids are among the most prevalent of the gastrointestinal parasites encountered in cage and aviary birds. The life cycle of *Ascaridia* is direct, with the infective larva developing within the egg after 2-3 weeks ¹. Transmission is generally occurs directly via ingestion of embryonated ova. Clinical findings include loss of condition, weakness, emaciation, and death; intestinal obstruction occurs commonly in heavy infections ². Diagnosis is made by the observation of the eggs in faecal samples ³. There are many anthelmintics that are efficacious against ascarids including levamisole, fenbendazole, mebendazole, pyrantel tartrate, pyrantel pamoate and ivermectin ^{1,3}.

In the present letter, an one year old Cockatiel was referred to the Internal Medicine Department. At the history, lethargy, lack of appetite, depression, diarrhoea were detected. In clinical examination; depression,

unwilling movement, frequently lie down at the bottom of the cage were observed (Fig. 1-a). Diagnosis were carried out on faecal sample of the patient with observation of the *Ascaridia* sp. eggs in the native examination (Fig. 1-b).

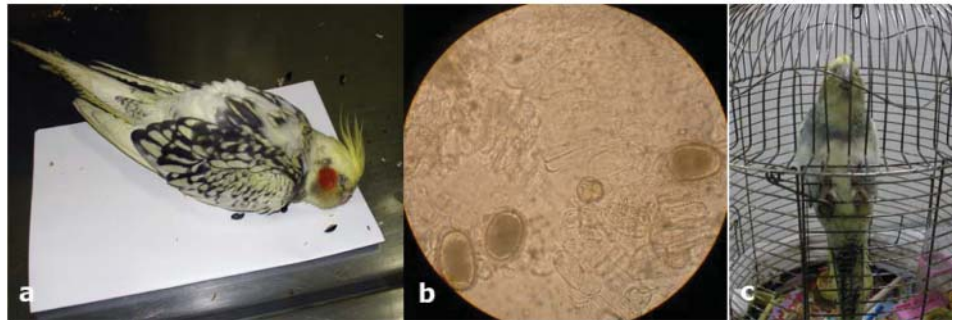
At treatment; pyrantel pamoate (Kontil susp.[®], Hüsni Arsan) 0.045 mg/10 g bw, was applied orally twice with one week interval. After first application, mature parasites were observed in the stool and afterwards general condition, depression and appetite were recovered entirely (Fig. 1-c). In the conclusion *Ascaridia* sp. infection is an important parasitic and also life-threatening problem in cage and aviary birds however can be treated successfully by pyrantel pamoate in cockatiels.

REFERENCES

- 1. Greve JH:** Gastrointestinal parasites. In, Roskopf WJ, Woerpel RW (Eds): Disease of Cage and Aviary Birds. 3rd ed. pp. 613-619. Williams & Wilkins Co. Baltimore Maryland - USA, 1996.
- 2. Aiello SE and Mays A:** The Merck Veterinary Manual, Eighth ed., A Merck and Rhone-Poulenc Company, Philadelphia, Pennsylvania - USA, 1998.
- 3. Kurtdede A:** Kafes Kuşlarının Muayenesi ve Hastalıkları. II. Baskı, Azim Matbaacılık Ankara - Türkiye, 2002.

Fig 1. Before treatment (a), *Ascaridia* sp. eggs in faecal samples (b), after treatment (c)

Şekil 1. Sağaltım öncesi (a), Dışkıda *Ascaridia* sp. yumurtaları (b), sağaltım sonrası (c)



İletişim (Correspondence)

+90 272 2149309/215

cagringi@gmail.com