

# Role of Dietary Supplementation with Plant Origin Carotenoids (Curcumin and Lutein) for the Control of *Eimeria*-Challenged Broiler Chickens

Nasir RAJPUT <sup>1,2,a</sup> Sher ALI <sup>3,b</sup> Muhammad NAEEM <sup>1,2,c</sup> Rana Muhammad BILAL <sup>4,d</sup> Wang TIAN <sup>1,e (\*)</sup>

<sup>1</sup> College of Animal Science and Technology, Key Laboratory of Meat Processing and Quality Control, Nanjing Agricultural University, Nanjing 210095, P. R. CHINA; <sup>2</sup> Faculty of Animal Husbandry & Veterinary Sciences, Sindh Agriculture University Tandojam, Sindh, PAKISTAN; <sup>3</sup> Department of Meat Science and Technology, Faculty of Animal Production & Technology, University of Veterinary and Animal Sciences, Lahore, PAKISTAN; <sup>4</sup> Department of Animal Nutrition, Faculty of Veterinary & Animal Sciences, The Islamia University of Bahawalpur, 63100 PAKISTAN

ORCID: <sup>a</sup> 0000-0001-7495-8850; <sup>b</sup> 0000-0002-9236-2660; <sup>c</sup> 0000-0002-0870-8180; <sup>d</sup> 0000-0002-1760-0841; <sup>e</sup> 0000-0002-9036-5009

Article ID: KVFD-2021-26402 Received: 15.08.2021 Accepted: 29.11.2021 Published Online: 30.11.2021

## Abstract

The influence of anti-coccidial naturally occurring plant origin carotenoids (curcumin and lutein) in *Eimeria*-challenged broiler chicks were tested. A total of 200, day-old commercial Arbor Acres chicks were reared for 42 days. The chicks were weighed individually and randomly assigned into equally 4 treatment groups having 5 replicates. Chicks of control group T<sub>0</sub> were raised on a basal diet with no supplement. The chicks of group T<sub>1</sub>, T<sub>2</sub> and T<sub>3</sub> were supplemented with curcumin 300 mg/kg, lutein 300 mg/kg, and curcumin plus lutein 150 mg each with per kg of feed, respectively. On day 21 all the chicks were challenged with *Eimeria maxima*. The findings of this study revealed that among all the groups feed intake, body weight gain and feed efficiency remained statistically unchanged (P>0.05). A significantly higher (P<0.05) liver and spleen weights were observed in the T<sub>0</sub> group as compared to the birds fed lutein supplemented diets whilst the bursa and thymus remained statistically alike and the same trend was observed for bloody diarrhea, intestinal lesion scores except for the oocyte count which was significantly lower in the T<sub>3</sub> group. On day 20, T<sub>3</sub> dietary groups exhibited numerically increased antibody titers against Newcastle disease virus (NDV) and Avian influenza virus (AIV), additionally T<sub>3</sub> also exhibited the same trend on day 30. The serum malondialdehyde (MDA) and aspartate aminotransferase (AST) levels were at a lower rate in the T<sub>3</sub> group while the liver MDA was statistically lower in the T<sub>1</sub> (P<0.05) group as compared to other groups. The alanine aminotransferase (ALT) remained unchanged within the groups. Compared to T<sub>0</sub> (control), all the carotenoid supplemented groups exhibited increased (P>0.05) shank color and skin b\* value (yellowness). Our conclusion showed that application of curcumin single or in combination with lutein may promote skin pigmentation, lowered liver injury, and exhibit a better anti-coccidial impact.

**Keywords:** Broilers, Carotenoids, Curcumin, Lutein, *Eimeria*, Feed efficiency

## *Eimeria* İle Enfekte Edilmiş Etlik Piliçlerde Bitki Kökenli Karotenoidleri (Curcumin ve Lutein) İçeren Diyet Takviyesinin Enfeksiyonun Kontrolündeki Rolü

### Öz

Doğal olarak oluşan bitki kökenli karotenoidlerin (kurkumin ve lutein), *Eimeria* verilmiş etlik piliçlerde anti-koksidyal etkinliği test edildi. Toplam 200 adet bir günlük ticari Arbor Acres civcivine 42 gün boyunca bakım uygulandı. Civcivler tek tek tartıldı ve 5 tekrarlı olmak üzere rastgele 4 eşit sağaltım grubuna ayrıldı. Kontrol grubu T<sub>0</sub>'a ait civcivler, ek besin içermeyen temel bir diyetle beslendi. T<sub>1</sub>, T<sub>2</sub> ve T<sub>3</sub> grubundaki civcivlere, her bir kg yem içerisinde sırasıyla 300 mg/kg kurkumin, 300 mg/kg lutein ve 150 mg kurkumin artı 150 mg lutein içeren diyet uygulandı. 21. günde tüm civcivlere *Eimeria maxima* verildi. Çalışma bulguları, tüm gruplar arasında yem tüketimi, canlı ağırlık artışı ve yemden yararlanmanın istatistiksel olarak değişmediğini ortaya koydu (P>0.05). Lutein takviyeli diyetlerle beslenen piliçlere kıyasla, T<sub>0</sub> grubunda karaciğer ve dalak ağırlıklarında anlamlı derecede (P<0.05) artışa rastlanırken, bursa ve timus istatistiksel olarak benzerliklerini korudu ve T<sub>3</sub> grubunda anlamlı olarak daha düşük olan oosit sayısı dışında kanlı ishal ve bağırsak lezyon skorları için de aynı eğilim gözlemlendi. 20. günde, T<sub>3</sub> diyet grupları Newcastle hastalığı virüsüne (NDV) ve Avian influenza virüsüne (AIV) karşı sayısal olarak artan antikor titreleri sergiledi, aynı eğilim T<sub>3</sub>'te 30. günde de saptandı. Diğer gruplara göre serum malondialdehit (MDA) ve aspartat aminotransferaz (AST) düzeyleri T<sub>3</sub> grubunda daha düşük oranda bulunurken, karaciğer MDA'sı T<sub>1</sub> grubunda istatistiksel olarak daha düşüktü (P<0.05). Alanin aminotransferaz (ALT), gruplar içerisinde değişim göstermeden kaldı. T<sub>0</sub> (kontrol) ile karşılaştırıldığında, tüm karotenoid takviyeli gruplar artmış gövde rengi (P>0.05) ve cilt b\* değeri (sarılık) sergiledi. Sonuç olarak, kurkuminin tek başına veya lutein ile kombinasyon halinde uygulanmasının cilt pigmentasyonunu artırabileceği, karaciğer hasarını azaltabileceği ve daha iyi bir koksidyal etki sergileyebileceği sonucuna varıldı.

**Anahtar sözcükler:** Etlik piliç, Karotenoidler, Kurkumin, Lutein, *Eimeria*, Yemden yararlanma

### How to cite this article?

Rajput N, Ali S, Naem M, Bilal RM, Tian W: Role of dietary supplementation with plant origin carotenoids (curcumin and lutein) for the control of *Eimeria*-challenged broiler chickens. *Kafkas Univ Vet Fak Derg*, 2021 (Article in Press). DOI: 10.9775/kvfd.2021.26402

### (\*) Corresponding Author

Tel: +90 86 1395 209 3562

E-mail: [tianwangnjau@yahoo.com](mailto:tianwangnjau@yahoo.com) (W. Tian)



## INTRODUCTION

World poultry production plays a significant role in the nutritional security of human beings but this industry is under threat of disease outbreaks. The infectious origin diseases of poultry may be effectively controlled by applying vaccines, however, a protozoal disease i.e coccidiosis caused by several different *Eimeria* species is still seriously impairing poultry development [1]. The species of *Eimeria* destroy the intestinal lumen, exhibit a negative impact on the immunity and nutrient absorption mechanism of broiler chickens. Moreover, the cost of prophylactic measures, professionals, and low production efficiency resulting from coccidiosis further aggravate the condition, leading to a huge global economic loss [2].

The conventional coccidiosis control approaches heavily rely on chemoprophylaxis and vaccination, which seemed to be operative during the past decade, however, the widespread occurrence of anti-microbial resistance to anti-coccidial drugs has raised serious concerns for the poultry industry with a renewed challenge. Further, the legislative limitations from the European Union regarding the inclusion of anti-microbial drugs and increasing consumers' preference for organic food have compelled professionals to explore new alternative natural feed additives that may serve the purpose successfully [3].

Published literature indicates that negative consequences of coccidial infection may be reduced by the inclusion of natural antioxidants, herbs, essential oils, and anti-microbial in the avian feed [4]. Recently, plant-origin carotenoids have gained much attention as feed ingredients due to their high nutraceutical activities. Moreover, these promote bird's health and performance by beneficially modulating gut morphology, digestion, immunity, pigmentation of broiler and layer chicks [5-8]. Hence, the current study was carried out to evaluate the potential beneficial impact of curcumin and lutein (individual and in combination) against the *Eimeria maxima* infected broiler chicks.

## MATERIAL AND METHODS

The recommendation of the Animal Care and Use Committee of Nanjing Agricultural University (Nanjing, People's Republic of China) was used for the execution of this trial. A total of 200 1-d old broiler chicks (Arbor Acres) were run randomly into 4 groups (each group with 5 replicates; 10 chicks per each). Four nearly iso-nitrogenous CP (21.19%) and isocaloric (ME= 2998 kcal/kg) broiler starter diets (Table 1) were prepared and fed from 1-21 days of age. The T<sub>0</sub> was (control) diet, whilst the diets T<sub>1</sub>, T<sub>2</sub> and T<sub>3</sub> were enriched with curcumin 300 mg/kg, lutein 300 mg/kg and curcumin and lutein 150+150 mg/kg, respectively. Similarly, four nearly iso-nitrogenous CP (19.20%) and iso-caloric (3023, 90 kcal/kg) finisher diets (Table 1) encompassing the similar treatment as in starter diet were fed from 22-42 days of

age. The carotenoids were supplied from Guangzhou Leader Biotechnology Co Ltd, Guangzhou, China with 98% purity. The basal diet was prepared with a major portion of the rice-soybean meal (Table 1) under the guideline of the NRC 1994 [9]. The birds were reared according to the managed metal procedures of Arbor Acres and kept in a triple-stack cage in an environmentally controlled poultry house. A specific amount of sporulated oocysts *Eimeria maxima* were harvested from the Laboratory of Veterinary Parasitology, Nanjing Agricultural University, Nanjing, China. A weighed quantity of feed was provided to chicks however water was *ad libitum*. On the 21<sup>st</sup> day, all the chicks were challenged orally with pure *Eimeria maxima* containing 1×10<sup>4</sup> sporulated oocysts which were diluted in distilled water (0.5 mL) [10]. Roche color fan score was used to measure the strength of shank skin color with the help of Konica Minolta chromameter CR-400 (Japan) method was used for yellowness measurement of breast skin color after 45 min of slaughtering. The relative organ weight was found by equation i.e =100 × (organ weight/total live body weight) (Table 2). The Mc Master counting chamber was used for counting the fecal oocysts [11] (Table 3). The 15 mL of concentrated salt (NaCl) solution was homogenized for one gram of the fecal sample and filtered via muslin cloth. From sterile plastic tubes, the liquid was collected and the solid material was discarded. Then on the Mc-Master counting chamber, a specific volume was loaded for 15 min, which cause the oocysts to settle upon the surface, and counting was done under the microscope easily. One mL of solution per total number of *Eimeria* oocysts were

**Table 1.** Composition (g/kg) of experimental starter and finisher diets

| Ingredients  | Starter | Finisher |
|--|---------|----------|
| Rice broken  | 602.5   | 654.7    |
| Soybean meal 45%   | 325.0   | 280.0    |
| Corn gluten meal 60%   | 30.0    | 25.0     |
| Lime stone   | 12.0    | 12.0     |
| Di calcium phosphate   | 20.0    | 18.0     |
| NaCl   | 3.0     | 3.0      |
| Vitamin mineral premix <sup>1</sup>  | 5.0     | 5.0      |
| L- lysine HCL  | 1.0     | 1.0      |
| DL- Methionine   | 1.5     | 1.3      |
| Percent calculated nutrient composition  |         |          |
| ME (kcal/kg)   | 2998    | 3023.9   |
| Crude Protein  | 21.19   | 19.2     |
| L-Lysine   | 1.21    | 1.1      |
| Methionine   | 0.496   | 0.4      |
| Methionine and cystine   | 0.80    | 0.7      |
| Calcium  | 0.988   | 0.9      |
| Available P  | 0.531   | 0.5      |
| Supplied the following per kg fed: Vit. B <sub>12</sub> , 0.012 mg; Fe 82 mg; Cu 7.5 mg; Mn 110 mg; Zn, 64 mg; Calcium iodate, 1.1 mg; Se 0.28 mg; Vit. B <sub>1</sub> , 2.3 mg; Vit. B <sub>2</sub> 8 mg; Vit. B <sub>3</sub> 42 mg; Biotin, 0.04 mg; Folic acid, 1 mg; Vit. B <sub>5</sub> , 10 mg; Pyridoxine HCl, 4 mg; Choline chloride, 400 mg; Vit. A, 25 mg; Vit. D <sub>3</sub> , 6 mg; Vitamin K <sub>3</sub> , 1.2 mg |         |          |

**Table 2.** The Influence of natural carotenoids supplementation on the relative organ's weight in *Eimeria* challenged broiler chicks

| Parameters | Diets <sup>1</sup>     |                         |                        |                         |
|------------|------------------------|-------------------------|------------------------|-------------------------|
|            | T <sub>0</sub>         | T <sub>1</sub>          | T <sub>2</sub>         | T <sub>3</sub>          |
| Liver      | 2.57±0.60 <sup>a</sup> | 1.96±0.34 <sup>ab</sup> | 1.84±0.19 <sup>b</sup> | 2.27±0.41 <sup>ab</sup> |
| Spleen     | 0.06±0.01 <sup>a</sup> | 0.05±0.01 <sup>ab</sup> | 0.04±0.01 <sup>b</sup> | 0.05±0.01 <sup>ab</sup> |
| Bursa      | 0.08±0.02              | 0.08±0.05               | 0.06±0.02              | 0.07±0.04               |
| Thymus     | 0.05±0.01              | 0.06±0.01               | 0.05±0.01              | 0.05±0.01               |

<sup>1</sup> T<sub>0</sub> (Control), T<sub>1</sub> contained (curcumin 300 mg/kg), T<sub>2</sub> (lutein 300 mg/kg), T<sub>3</sub> contained a mixture of curcumin + lutein (150+150 mg/kg); <sup>abc</sup> Mean values with common superscript did not differ (P>0.05)

**Table 3.** The Influence of natural carotenoid supplementation on the intestinal lesion score, bloody diarrhea, and fecal oocyst count score in *Eimeria* infected broiler chicks

| Item            | Diets <sup>1</sup>                       |   |  |  |
|-----------------|--|---|--|--|
|                 | T <sub>0</sub>                           | T <sub>1</sub>                            | T <sub>2</sub>                           | T <sub>3</sub>                           |
| Bloody diarrhea | 3.75 ±0.50 <sup>a</sup>                  | 3.00±0.81 <sup>ab</sup>                   | 2.17±0.57 <sup>b</sup>                   | 2.08±0.83 <sup>b</sup>                   |
| Lesion score    | 2.17±0.18 <sup>a</sup>                   | 1.66±0.24 <sup>b</sup>                    | 1.94±0.06 <sup>ab</sup>                  | 1.87±0.01 <sup>ab</sup>                  |
| Oocyst count    | 104.4×10 <sup>3</sup> ±8.87 <sup>a</sup> | 64.96×10 <sup>3</sup> ±6.30 <sup>bc</sup> | 83.11×10 <sup>3</sup> ±8.03 <sup>b</sup> | 49.55×10 <sup>3</sup> ±5.48 <sup>c</sup> |

<sup>1</sup> T<sub>0</sub> (Control), T<sub>1</sub> contained (curcumin 300 mg/kg), T<sub>2</sub> (lutein 300 mg/kg), T<sub>3</sub> contained a mixture of curcumin + lutein (150+150 mg/kg); <sup>abc</sup> Mean values with common superscript did not differ (P>0.05)

used for counting and reading. The number of oocysts was estimated by the formula i.e Oocysts per gram (OPG) of a fecal sample of broiler = oocysts count x dilution factor x (volume of fecal sample/volume of counting chamber/ number of broiler chicks per treatment group were determined. On 3-10 (dpi) intensity of bloody diarrhea was observed twice a day. According to Youn and Noh <sup>[12]</sup> the score was assigned from 0 to 4 scale. The zero value was recognized as the normal condition, however, the values of 1, 2, 3, and 4 exhibited the percentage as 1-25, 26-50, 51-75, or over 75 bloody diarrhea in the total fecal samples. During the 2<sup>nd</sup> week of production, birds were vaccinated for the Newcastle disease virus NDV and AIV.

### Data Collection

The data regarding the growth performance including feed consumption, body weight gain was recorded to estimate feed conversion ratio (FCR). Then after 6 h of feed deprivation, fresh samples of blood (10 mL) were collected by randomly selecting one bird for each replicate. The birds were slaughtered and the de-feathered carcass was then eviscerated. The weight of the visceral organ (liver and spleen) for each group was individually found. To measure the shade of shank skin color three birds per replicate were selected on the 28<sup>th</sup> day, whilst for examination breast skin color one bird from each replicate was selected. After a post-infection period, the collection of feces was done twice a day. The collected pooled feces of each replicate of all treated groups were measured for the *Eimeria* oocyst shedding.

Further, on the 7<sup>th</sup> day (dpi), 5 birds/treatment groups were selected randomly for intestinal lesions scores determination

as suggested by Johnson and Reid <sup>[13]</sup>. A volume of 2 mL blood was collected from the wing vein of 2 birds per pen (10 birds/treatment group) to measure antibody titers against NDV and AIV twice at 20 and 30 days of age. The samples of the blood were centrifuged at 3000×g for 10 min at 4°C to isolate serum aliquots and further stored at -20°C temperature. Then by using the protocol of haemagglutination inhibition (HI) tests the antibody titer against NDV and AIV was measured. The plasma concentrations of enzymes, AST and ALT were observed by a corresponding test. Thio-barbituric acid reactive substances (TBARS) as the concentration of MDA (from liver tissue and blood plasma) were measured by the protocol of Zhang et al. <sup>[14]</sup>.

Additionally, fecal samples were observed for continuously 6 days (3 dpi) for spots of bloody diarrhea. The component of blood was visually detected (4 dpi) in almost all of the treatment groups, and scores were assigned based on the severity of bloody appearance.

### Statistical Analysis

The statistical software SPSS version (SPSS 15.0 K for Windows, Chicago, IL) was used to perform statistical analysis and all calculated values were presented as means ± SEM. One-way analysis of variance technique was applied to compare the mean. By using Tukey's method at (P<0.05) the significant variations among the mean values were evaluated. The lesion scores were assessed from the mean score of one bird per replicate. Bloody diarrhea and oocysts count were observed by a pooled fecal sample of each replicate and the mean value of 5 replicate/treatment groups were considered bloody diarrhea and oocysts count.

## RESULTS

### Growth Performance

Concerning the influence of dietary supplementation of curcumin, lutein, or as a mixture of both investigated in this study failed to exhibit significant change ( $P>0.05$ ) on the feed consumption, body weight gain, and FCR as presented in (Table 4). A significantly better ( $P<0.05$ ) weight of liver and spleen was found in the  $T_0$  (control) group as compared to other counterparts. Moreover, the relative weight of the thymus and bursa remained statistically unchanged as illustrated in (Table 2).

### Fecal Oocysts Count, Intestinal Lesion Score, and Bloody Diarrhea

Table 3 illustrates the findings regarding the oocyst count, intestinal lesion score, and bloody diarrhea of broilers. The results revealed that  $T_2$  and  $T_3$  dietary groups exhibited significantly decreased bloody diarrhea values. The carotenoid inclusion controls the harmful effects of *Eimeria* concerning intestinal lesion scores. Lesion score of intestine was significantly low in  $T_1$  group followed by  $T_3$ ,  $T_2$  and  $T_0$  dietary groups. A significantly lower ( $P<0.05$ ) fecal shedding of oocyte count was recorded in the  $T_3$  dietary group followed by  $T_1$ ,  $T_2$  and  $T_0$  dietary group.

### Antibody Titers Against Newcastle Disease Virus and Avian Influenza Virus

The antibody titers against NDV and AIV have been presented in Table 5. It could be observed that birds of treatment

group  $T_1$  and  $T_3$  produced slightly greater antibodies against NDV as compared to  $T_0$  and  $T_2$  counterparts (at day 20). Moreover, the highest ( $P<0.05$ ) antibody titers were in the  $T_3$  dietary group however, the  $T_2$  dietary group produced the lowest ( $P>0.05$ ) antibody titers against NDV. The  $T_0$  and  $T_1$  group exhibited statistically similar immunogenic responses.

### Shank and Skin Color

The results of shank and skin color are presented in (Fig. 1). Dietary supplementation with lutein produced a darker yellow color on the broiler shank skin. The highest intensity of the shank skin color (Fig. 1) was observed in the broilers supplemented with a combination of both carotenoids (C+L) followed by LTN, curcumin CRM and control groups. While, the skin color was significantly higher in LTN and CRM than L+C and Control as measured by chroma meter.

### Plasma Alanine Aminotransferase, Aspartate, Aminotransferase

Fig. 2 indicates the plasma AST and ALT concentrations. The AST (U/L) was significantly higher ( $P<0.05$ ) in  $T_2$  diets whilst  $T_3$  exhibited a minimum level of AST. Moreover, birds reared with diet  $T_0$  and  $T_1$  groups exhibited statistically similar results. Similarly, the  $T_2$  group produced a higher level of ALT among all other counterparts whilst the  $T_3$  group exhibited a minimum level.

### Plasma and Hepatic Thiobarbituric Acid Reactive Substances (TBARS) Activities

As shown in (Fig. 3) the hepatic and plasma TBARS were

**Table 4.** Impact of natural carotenoids supplementation on growth performance in *Eimeria* challenged broiler chicks

| Parameters           | Diets <sup>1</sup> |           |           |           |
|----------------------|--------------------|-----------|-----------|-----------|
|                      | $T_0$              | $T_1$     | $T_2$     | $T_3$     |
| Feed Intake(kg/bird) | 2.20±0.18          | 2.16±0.59 | 2.18±0.42 | 2.04±0.24 |
| Bodyweight(kg/bird)  | 1.15±0.13          | 1.25±0.34 | 1.28±0.27 | 1.22±0.17 |
| FCR                  | 1.75±0.03          | 1.72±0.04 | 1.70±0.05 | 1.67±0.04 |

<sup>1</sup>  $T_0$  (Control),  $T_1$  contained (curcumin 300 mg/kg),  $T_2$  (lutein 300 mg/kg),  $T_3$  contained a mixture of curcumin+lutein (150+150 mg/kg)

**Table 5.** The Influence of natural carotenoid supplementation on the serum Antibody titer against Newcastle Disease Virus (NDV) and Avian Influenza Virus (AIV) and against *Eimeria* infected broiler chicks

| Item | Diets <sup>1</sup>      |                         |                        |                        |
|------|-------------------------|-------------------------|------------------------|------------------------|
|      | $T_0$                   | $T_1$                   | $T_2$                  | $T_3$                  |
| 20 d |                         |                         |                        |                        |
| ND   | 5.60±0.36               | 5.80±0.34               | 5.40±0.52              | 5.80±1.05              |
| AI   | 5.67±1.15               | 5.67±0.06               | 6.33±1.15              | 6.00±1.00              |
| 30 d |                         |                         |                        |                        |
| ND   | 4.50±0.52 <sup>ab</sup> | 4.20±0.95 <sup>ab</sup> | 3.80±0.26 <sup>b</sup> | 5.40±0.26 <sup>a</sup> |
| AI   | 4.33±0.58               | 4.67±0.57               | 5.00±1.00              | 4.67±0.57              |

<sup>1</sup>  $T_0$  (Control),  $T_1$  contained (curcumin 300 mg/kg),  $T_2$  (lutein 300 mg/kg),  $T_3$  contained a mixture of curcumin + lutein (150+150 mg/kg); <sup>abc</sup> Mean values with common superscript did not differ ( $P>0.05$ )



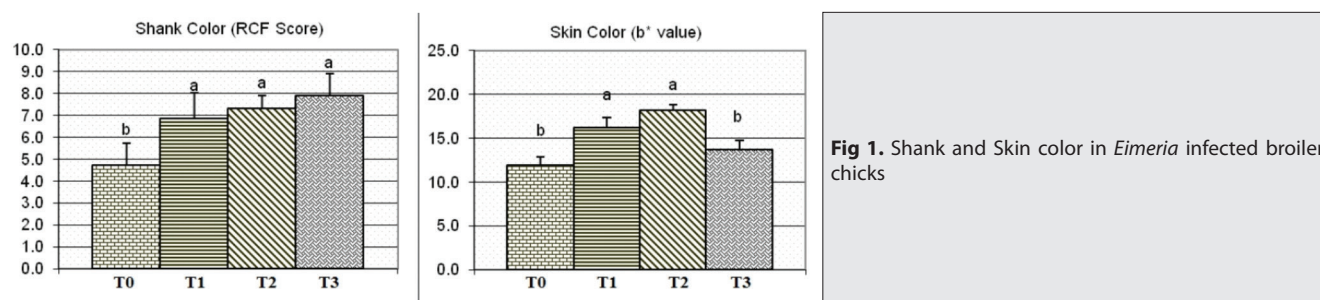


Fig 1. Shank and Skin color in *Eimeria* infected broiler chicks

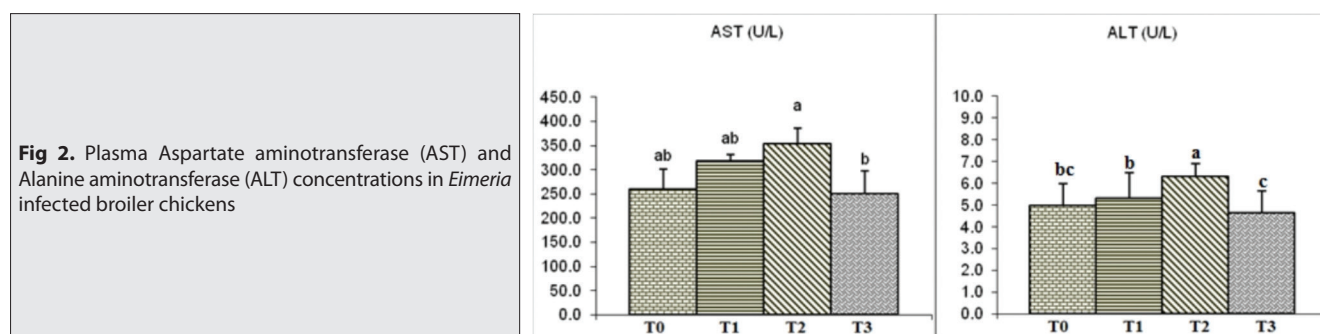


Fig 2. Plasma Aspartate aminotransferase (AST) and Alanine aminotransferase (ALT) concentrations in *Eimeria* infected broiler chickens

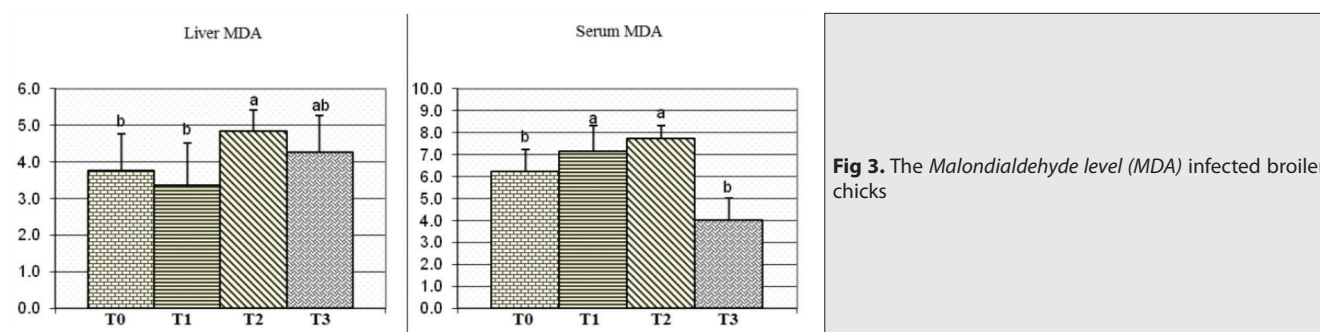


Fig 3. The Malondialdehyde level (MDA) in infected broiler chicks

recorded by MDA concentrations. The  $T_2$  dietary group ( $P < 0.05$ ) produced the highest values for hepatic MDA followed by the  $T_3$  group. The broiler chicks reared with  $T_0$  and  $T_1$  diets exhibited similar results. The serum MDA concentration was statistically similar in the  $T_2$ ,  $T_1$ , and  $T_0$  dietary groups. The  $T_3$  dietary group exhibited minimum values.

## DISCUSSION

Phyto-chemicals including curcumin and lutein are extracted from natural sources. According to Partovi et al.<sup>[15]</sup>, these natural phytochemicals have a wide range of therapeutic properties and may elevate the growth potential of birds. Further, carotenoids rich feeds improve the antioxidant status and immunogenic response of broilers<sup>[5,7]</sup>. Among the group's optimum performance was shown in  $T_2$  and these results correlate with the conclusion of Rajput et al.<sup>[7]</sup> who recorded no significant changes in the performance traits of broiler subjected to a diet containing carotenoids. The outcomes of the study showed that the body weight was found to be higher in the  $T_1$  group after the challenge of coccidiosis. The turmeric (*Curcuma longa*

L.) supplementation promoted the live body weight of *Eimeria*-infected broiler chicks, these findings align with our results<sup>[16]</sup>. Besides, low-level contamination of oocysts and improved body weight gain show that animals are resistant to *Eimeria*, but interestingly, these parameters have not always been documented in review<sup>[17]</sup>. Likewise, in our study, curcumin supplementation failed to produce a significant change in growth performance relative to the control group, however, curcumin supplementation lowered the level of oocyst shedding. In the present study, dietary alone supplementation of lutein seems inefficient whereas, curcumin supplementation showed more promising effects towards the promotion of feed efficiency. Moreover, this study found that livers' relative weights were increased in the lutein and control groups as compared to other groups. Significant changes in the organ weight of broilers were recorded by the inclusion of 5 g/kg *Curcuma longa*<sup>[18]</sup>. The experiment also revealed an increase in the liver and spleen weights by the treatment of the curcumin+lutein mixture. A significantly increased liver weight might be associated with the doses of the compound, which may cause hepatotoxicity. Further, overall carotenoid supplementation posed no adverse effects on

the organ's weight of the broiler. After inoculation avian *Eimeria* sporozoites appear to pass through mucosa and travel to the spleen and liver then leave these tissues very shortly and this action may reveal morphological modifications in the liver and spleen tissues<sup>[19]</sup>. According to this study, at 4-6 (dpi) signs of intestinal coccidiosis including bloody diarrhea were visible in nearly all groups, whilst the reduced bloody diarrhea was in the chickens reared on individual lutein and with a mixture of curcumin and lutein enriched diets. After the coccidiosis challenge, a lower value fecal oocysts count was recorded in the group of birds supplemented with carotenoid. More encouraging results were in the birds reared on basal diet added with curcumin and a mixture of curcumin and lutein than the diets of control and alone lutein group. Although, both the plant phytochemicals prevented the infection of intestinal tissue as detected by intestinal lesion scores. Moreover, broilers fed a diet enriched with carotenoid showed a lower rate of lesion scores than reared with a carotenoid-free diet. Both the bioactive nutrients exerted protective effects against coccidiosis because they are being known as *anti-oxidant* and *anti-radical* activities.

Another report by Allen et al.<sup>[16]</sup> demonstrated that *turmeric* (*Curcuma longa* L.) lowered small intestinal lesion scores and fecal oocyst counts in meat birds. Antibody titers against the disease are a biomarker of explicit humoral immunity. Before the onset of coccidiosis, both carotenoids slightly raised the antibody titer at the 20<sup>th</sup> d of age, as in this study. The inclusion of 2 mL/L herbal mixture improved the immunity of coccidiosis challenged broiler by regulating the mRNA expression<sup>[20]</sup>.

Further, Ntrallou et al.<sup>[21]</sup> observed that *food colorants* derived from *natural* sources enhance antibody production. But, here diets supplemented with curcumin, lutein and their mixture could not raise antibody concentrations against (AIV) at 30 d (10 dpi). The current study opposes our earlier observations, which confirmed that antibody titers were increased in curcumin and lutein treated, *Lipopolysaccharide* (LPS)-induced broiler chickens augmented with the increase of age<sup>[7]</sup>, which align the hypothesis that coccidiosis decreases immunity. According to our findings, all the tested diets enriched with carotenoids promoted the skin color of broilers and these findings are verified by Karadas et al.<sup>[22]</sup> who recorded that a dose of 25 mg/kg keto-carotenoid pigment i.e canthaxanthin promoted the leg skin color. Moreover, the author also observed that other carotenoids sources also improved color parameters on an overall basis. Further, carotenoids promoted the shank color of broilers. The tissues of chickens were saved from stress as zeaxanthin and  $\beta$ -carotene contents maintain immunity<sup>[8]</sup>.

Certain environmental factors and metabolic pathways generate free radicals which cause oxidative stress, which is measured as an important cause of various liver diseases. Hepato-cellular injuries cause the production

of enzymes aspartate aminotransferase AST and alanine aminotransferase ALT into the rotation and promote in the plasma levels of AST indicate hepatic injuries likely to hepatitis and muscular damages<sup>[23,24]</sup>. The plasma AST concentrations were high among all the groups but the plasma ALT level was not significantly high in any of the experimental groups. The reason for this is not clear, and the normal levels may be deceptive because significantly injured hepatic cells do not generate ALT enzyme. This study found that AST concentrations and hepatic structures reflected the hepatocellular damage. Furthermore, plasma ALT and AST concentrations are associated with the reduction of plasma antioxidant levels, mainly when carotenoids are supplemented. The addition of  $\beta$ -carotene was many operatives in reducing the liver infection and generated a concomitant reduction in plasma AST level<sup>[25]</sup>. Further, carotenoids reduced the level of ALT and AST in mule ducklings stimulated by aflatoxin<sup>[26]</sup>. At present, this finding of peroxidation MDA levels, histopathology, and ALT and AST concentrations highlighted the beneficial effects and potential anti-oxidative role of natural carotenoids in the liver tissue of *Eimeria* affected broiler chicks. The previous finding of Rajput et al.<sup>[6]</sup>, was also observed carotenoids numerically recorded the capability of improving growth even in challenging conditions. All challenged birds showed a high level of AST compared with the previous observation of Partovi et al.<sup>[15]</sup>, in which broilers were challenged with LPS. No influence of *Eimeria* infection and tested diets on the ALT concentration in birds at (42 dpi).

Zhang et al.<sup>[3]</sup> and Zhai et al.<sup>[27]</sup> reported that curcumin may positively impact liver and kidney activity. Moreover, lutein may behave as a powerful antioxidant carotenoid; but, our results found that lutein created an adverse effect on the biochemical analysis and liver histology. The deterioration of the liver may be associated with relatively higher (300 mg/kg) supplementation of lutein which may exhibit clinically toxic effects on the liver. But interestingly, Rajput et al.<sup>[7]</sup>, recorded that 200 mg/kg lutein exhibited beneficial effects on LPS-infected chickens.

The current experiment revealed that a dose of 300 mg/kg lutein and curcumin failed to express any significant change in the growth performance of the coccidiosis-infected broiler. Supplementation of 300 mg/kg curcumin lowered lesion score, oocyst shedding and decreased coccidial effect. Similarly, lutein reduced bloody diarrhea but produced adverse effects on the liver at the same dose. Additionally, a mixture of both the doses of carotenoids not only elevated the skin pigmentation but also exhibited a positive impact on the humoral and cell-mediated immunity of the broiler chicks.

#### AVAILABILITY OF DATA AND MATERIALS

The datasets during and/or analyzed during the current study available from the corresponding author and can be provided on your request.

## ACKNOWLEDGMENTS

This research was supported by the College of Animal Science and Technology, Key Laboratory of Meat Processing and Quality Control, Nanjing Agricultural University, Nanjing 210095, P. R. China.

## FUNDING SUPPORT

The project was financially supported by the China Scholarship Council, People's Republic of China

## COMPETING INTERESTS

The authors whose names are listed in the manuscript certify that they have NO conflicts of research in the subject matter or materials discussed in this manuscript.

## AUTHORS' CONTRIBUTIONS

WT and NR, designed the project. The sampling, data collection, processing and interpretation of results were made by NR, SA, and MN. The data analysis was made by MN, SA and the manuscript was written and reviewed by NR, RMB and WT. All the authors read the manuscript and approved the contents.

## REFERENCES

- Soutter F, Werling D, Tomley FM, Blake DP:** Poultry coccidiosis: Design and interpretation of vaccine studies. *Front Vet Sci*, 7:101, 2020. DOI: 10.3389/fvets.2020.00101
- Blake DP, Knox J, Dehaeck B, Huntington B, Rathinam T, Ravipati V, Ayode S, Gilbert W, Adebambo AO, Jatau ID, Raman M, Parker D, Rushton J, Tomley FM:** Re-calculating the cost of coccidiosis in chickens. *Vet Res*, 51(1): 1-14, 2020. DOI: 10.1186/s13567-020-00837-2
- Zhang K, Li X, Na C, Abbas A, Abbas RZ, Zaman MA:** Anticoccidial effects of *Camellia sinensis* (green tea) extract and its effect on blood and serum chemistry of broiler chickens. *Pak Vet J*, 40, 77-80, 2020.
- Kim WH, Lillehoj HS:** Immunity, immunomodulation, and antibiotic alternatives to maximize the genetic potential of poultry for growth and disease response. *Anim Feed Sci Technol*, 250, 41-50, 2019. DOI: 10.1016/j.anifeedsci.2018.09.016
- Rajput N, Naeem M, Ali S, Rui Y, Tian W:** Effect of dietary supplementation of marigold pigment (lutein) on immunity, skin and meat color, and growth performance of broiler chickens. *Braz J Poult Sci*, 14 (4): 233-304, 2012. DOI: 10.1590/S1516-635X2012000400009
- Rajput N, Muhammad N, Yan R, Zhong X, Wang T:** Effect of dietary supplementation of curcumin on growth performance, intestinal morphology and nutrients utilization of broiler chicks. *J Poult Sci*, 50, 44-52, 2013. DOI: 10.2141/jpsa.0120065
- Rajput N, Naeem M, Ali S, Zhang JF, Zhang L, Wang T:** The effect of dietary supplementation with the natural carotenoids curcumin and lutein on broiler pigmentation and immunity. *Poult Sci*, 92, 1177-1185, 2013. DOI: 10.3382/ps.2012-02853
- Nogareda C, Moreno JA, Angulo, E, Sandmann G, Portero M, Capell T, Zhu C, Christou P:** Carotenoid-enriched transgenic corn delivers bioavailable carotenoids to poultry and protects them against coccidiosis. *Plant Biotechnol J*, 14 (1): 160-168, 2016. DOI: 10.1111/pbi.12369
- NRC:** National Research Council. Nutrient Requirements of Poultry. 9<sup>th</sup> revised ed., National Academy Press. Washington, USA. 1994. DOI: 10.17226/2114
- Michels MG, Bertolini LCT, Esteves AF, Moreira P, Franca SC:** Anticoccidial effects of coumestans from *Eclipta alba* for sustainable control of *Eimeria tenella* parasitosis in poultry production. *Vet Parasitol*, 177, 55-60, 2011. DOI: 10.1016/j.vetpar.2010.11.022
- Ogbe AO, Atawodi SE, Abdu PA, Sannusi A, Itodo AE:** Changes in weight gain, faecal oocyst count and packed cell volume of *Eimeria tenella*-infected broilers treated with a wild mushroom (*Ganoderma lucidum*) aqueous extract. *J S Afr Vet Assoc*, 80, 97-102, 2009. DOI: 10.4102/jsava.v80i2.179
- Youn HJ, Noh JW:** Screening of the anticoccidial effects of herb extracts against *Eimeria tenella*. *Vet Parasitol*, 9 (4): 257-263, 2001. DOI: 10.1016/s0304-4017(01)00385-5
- Johnson J, Reid WM:** Anticoccidial drugs: Lesion scoring techniques in battery and floor-pen experiments with chickens. *Exp Parasitol*, 28, 30-36, 1970. DOI: 10.1016/0014-4894(70)90063-9
- Zhang XH, Zhong X, Zhou YM, Du HM, Wang T:** Effect of RRR- $\alpha$ -tocopherol succinate on the growth and immunity in broilers. *Poult Sci*, 88, 959-966, 2009. DOI: 10.3382/ps.2008-00512
- Partovi R, Saeed S, Pabast M, Mohajer A, Sadighara P:** Effect of dietary supplementation of nano curcumin on oxidant stability of broiler chicken meat infected with *Eimeria* species. *Vet Res Forum*, 11 (2): 159-163, 2020. DOI: 10.30466/vrf.2018.86733.2125
- Allen PC, Danforth HD, Augustine PC:** Dietary modulation of avian coccidiosis. *Int J Parasitol*, 28, 1131-1140, 1998. DOI: 10.1016/s0020-7519(98)00029-0
- Lee SH, Lillehoj HS, Lillehoj EP, Cho SM, Park DW, Hong YH, Chun HK, Park HJ:** Immunomodulatory properties of dietary plum on coccidiosis. *Comp Immunol Microbiol Infect Dis*, 3, 389-402, 2008. DOI: 10.1016/j.cimid.2007.06.005
- Durrani FR, Ismail M, Sultan A, Suhail SM, Chand N, Durrani Z:** Effect of different levels of feed added turmeric (*Curcuma longa*) on the performance of broiler chicks. *Am J Agric Biol Sci*, 1, 9-11, 2006.
- Allen PC, Fetterer RH:** Recent advances in biology and immunobiology of *Eimeria* species and in diagnosis and control of infection with these coccidian parasites of poultry. *Clin Microbiol Rev*, 15, 58-65, 2002. DOI: 10.1128/CMR.15.1.58-65.2002
- Moryani AA, Rajput N, Naeem M, Shah AH, Jahejo AR:** Screening of the herbs and evaluation of their combined effects on the health and immunity of coccidiosis challenged broiler chickens. *Pak Vet J*, 41 (2): 228-234, 2021.
- Ntrallou K, Gika H, Tsochatzis E:** Analytical and sample preparation techniques for the determination of food colorants in food matrices. *Foods*, 9(1):58, 2020. DOI: 10.3390/foods9010058
- Karadas F, Erdogan S, Kor D, Ot G, Uluman M:** The effects of different types of antioxidants (Se, vitamin E and carotenoids) in broiler diets on the growth performance, skin pigmentation and liver and plasma antioxidant concentrations. *Braz J Poult Sci*, 18 (1): 101-116, 2016. DOI: 10.1590/18069061-2015-0155
- Abolfathi AA, Daryoush M, Ali R, Mehrdad N:** Green tea attenuates hepatic tissue injury in STZ-streptozotocin-induced diabetic rats. *J Anim Vet Adv*, 11, 2081-2090, 2012. DOI: 10.3923/javaa.2012.2081.2090
- Navaei-Nigjeh M, Rahimifard M, Pourkhalili N, Nili-Ahmadabadi A, Pakzad M, Baeeri M, Abdollahi M:** Multi-organ protective effects of cerium oxide nanoparticle/selenium in diabetic rats: Evidence for more efficiency of nanocerium in comparison to metal form of cerium. *Asian J Anim Vet Adv*, 7, 605-612, 2012. DOI: 10.3923/ajava.2012.605.612
- Zamora R, Hidalgo FJ, Tappel AL:** Comparative antioxidant effectiveness of dietary  $\beta$ -carotene, vitamin E, selenium and coenzyme Q10 in rat erythrocytes and plasma. *J Nutr*, 121, 50-56, 1991. DOI: 10.1093/jn/121.1.50
- Cheng YH, Shen TF, Pang VF, Chen BJ:** Effects of aflatoxin and carotenoids on growth performance and immune response in mule ducklings. *Comp Biochem Physiol C Toxicol Pharmacol*, 128, 19-26, 2001. DOI: 10.1016/s1532-0456(00)00173-3
- Zhai SS, Ruan D, Zhu YW, Li MC, Ye H, Wang WC, Yang L:** Protective effect of curcumin on ochratoxin A-induced liver oxidative injury in duck is mediated by modulating lipid metabolism and the intestinal microbiota. *Poult Sci*, 99 (2): 1124-1134, 2020. DOI: 10.1016/j.psj.2019.10.041