

The Investigation of the Effect of Ozone Therapy on Gout in Experimental Rat Models

Ali BİLGE ^{1,a} Murat TÜYSÜZ ^{1,b} Ömür ÖZTÜRK ^{2,c} Yasemen ADALI ^{3,d}
Hüseyin Avni EROĞLU ^{4,e} Mustafa MAKAV ^{5,f} Gözde ATİLA USLU ^{5,g} Ramazan TISKAOĞLU ^{6,h}

¹ Canakkale Onsekiz Mart University, Faculty of Medicine, Department of Orthopaedics and Traumatology, TR-17100 Canakkale - TURKEY

² Canakkale Onsekiz Mart University, Faculty of Medicine, Department of Anesthesiology And Reanimation, TR-17100 Canakkale - TURKEY

³ Canakkale Onsekiz Mart University, Faculty of Medicine, Department of Medical Pathology, TR-17100 Canakkale - TURKEY

⁴ Canakkale Onsekiz Mart University, Faculty of Medicine, Department of Physiology, TR-17100 Canakkale - TURKEY

⁵ Kafkas University, Faculty of Medicine, Department of Physiology, TR-36100 Kars - TURKEY

⁶ Kurtalan State Hospital, Department of Orthopaedics and Traumatology, TR-56500 Siirt -TURKEY

^a ORCID: 0000-0002-8277-8697; ^b ORCID: 0000-0002-6381-0348; ^c ORCID:0000-0003-2270-2778; ^d ORCID: 0000-0002-8004-7364

^e ORCID: 0000-0002-1040-3255; ^f ORCID: 0000-0003-1879-8180; ^g ORCID: 0000-0002-2328-9164; ^h ORCID: 0000-0002-6282-8378

Article ID: KVFD-2018-20793 Received: 15.08.2018 Accepted: 30.12.2018 Published Online: 31.12.2018

How to Cite This Article

Bilge A, Tüysüz M, Öztürk Ö, Adalı Y, Eroğlu HA, Makav M, Atila Uslu G, Tiskaoğlu R: The investigation of the effect of ozone therapy on gout in experimental rat models. *Kafkas Univ Vet Fak Derg*, 25 (2): 245-249, 2019. DOI: 10.9775/kvfd.2018.20793

Abstract

The effect of ozone treatment in experimental rat gout arthritis was investigated. Twenty adult albino male rats were divided into 4 groups: Group 1 (Control) was followed without any medication, Group 2 (Gout control) was injected with a single dose of 0.2 mL (10 mg) monosodium urate (MSU) intraarticular to 1st metatarsophalangeal joint to create experimental Gouty arthritis. Group 3 (Gout + Ozone) was injected intraarticular to 1st metatarsophalangeal joint with a single dose of 0.2 mL (10 mg) MSU to generate experimental gout, followed by ozone therapy to the rats a single dose of 1 mL (10 µg/mL) intraperitoneally daily for 3 weeks. The Group 4 (Ozone control) ozone therapy was given a single dose of 1 mL (10 µg/mL) intraperitoneally daily for 3 weeks without gout formation. The results were recorded and compared statistically between the groups. In conclusion, the low level of inflammation in the third group (Gout + Ozone) was considered statistically significant as compared to the second group. With Ozone treatment the gout joint has been shown to have reduced acute inflammation, it has not been affected by the chronic proliferation process.

Keywords: Gout, Ozone, Immunomodulators, Anti-inflammatory agents

DeneySEL Olarak Gut Oluşturulmuş Ratlarda Ozon Terapinin Etkisi

Öz

Bu çalışmada deneysel olarak Gut artriti oluşturulmuş rat ekleminde ozon tedavisinin etkisi araştırıldı. Yirmi adet albino cinsi erişkin erkek rat 4 gruba bölünerek: 1. Gruba (Kontrol) herhangi bir ilaç verilmeden takip edildi, 2. Gruba (Gut kontrol) deneysel Gut artriti oluşturulmak üzere tek doz 0.2 mL (10 mg) monosodyum urat (MSU) 1. metatarsofalangeal ekleme enjekte edildi, 3. Gruba (Gut + Ozon) deneysel Gut oluşturulmak üzere tek doz 0.2 mL (10 mg) monosodyum urat (MSU) 1. metatarsofalangeal ekleme intraartiküler olarak enjekte edildi ve arkasından ratlara 3 hafta süreyle günde tek doz 1 mL (10 µg/mL) intraperitoneal ozon terapi verildi, 4. Gruba ise (Ozon kontrol) Gut oluşturulmaksızın 3 hafta günde tek doz 1 mL (10 µg/mL) intraperitoneal ozon terapi uygulandı. Sonuçlar patolojik olarak kayıt altına alındı ve gruplar arası istatistik olarak karşılaştırıldı. Sonuç olarak 3. Gruptaki (Gut + Ozon) inflamasyon düzeyindeki düşüklük 2. Gruba göre istatistiksel olarak anlamlı kabul edildi. Ozon tedavisinin Gut oluşturulan eklemden akut inflamasyonu azalttığı gösterilse de kronik olan proliferasyon sürecine etkisi görülmedi.

Anahtar sözcükler: Gut, Ozon, Antiinflatmatuar ajan, İmmünomodülatörler

INTRODUCTION

Gout disease is the most common cause of inflammatory

arthritis in adults at the time of the US registry ^[1]. Gout disease is a chronic disorder associated with self-limiting acute gout attacks (gout flare), caused by accumulation



İletişim (Correspondence)



+90 505 4980868 Fax: +90 286 2635950



alibilge498@hotmail.com

of monosodium urate (MSU) deposits in joints and surrounding soft tissue and bursa [1]. Acute attacks of gout disease are one of the most important causes of adverse health-related quality of life [2,3]. It has also been reported that 12 to 15% of individuals aged 40-60 years worldwide have hyperuricemia and 3% are affected with gout arthritis [4]. As the molecular basis of gout disease, oxidative stress has been noted in studies that have shown promise in the pathogenesis of gout.

In the extracellular compartment, the uric acid molecules are present in 98% of the MSU at dense sodium concentration and physiological pH. If the urate concentration exceeds 6.8 mg/dL, the urate molecules will crystallize and precipitate and play a role in the initiation of the inflammatory reaction. In addition to exceeding the value of the urate density, conversion to MSU crystal formation is also implicated in a number of factors such as ambient temperature, hydrogen ion formation, concentration of cations, and the viscosity of the joint fluid [5,6]. This suggests that Gout arthritis is more common in peripheral joints, such as the first metatarsophalangeal joint [7]. MSU crystals are detected and presented to phagocytes by receptors such as Toll-Like Receptor (TLR) 1 and 2 and surface antigens such as CD14 [8-10]. In this context, anti-inflammatory treatments have found wide use in the treatment of gout arthritis, especially acute gout attack (gout flare) and chronic gout prophylaxis. These include interleukin 1 antagonists (anakinra, canakinumab, rilonacept), uricosuric drugs (probenecid, benzbromarone), xanthine oxidase inhibitors (allopurinol, febuxostat), cyclooxygenase 2 (COX2) inhibitors, colchicine and steroids that inhibit the migration of inflammatory cells [11].

Medical ozone treatment consists of 95% Oxygen (O₂) and 5% Ozone (O₃) mixture. The present rates are therapeutic ratios. There is toxic effects of ozone (O₃) ratio above 5% in ozone treatment [12]. On the other hand, ozone therapy has shown that ozone can be safely used at doses between 10 and 80 µg/mL and immunomodulators, anti-inflammatory, bactericidal, antifungal and analgesic effects are at these doses [13]. Medical ozone therapy affects anti-inflammatory activity in two phases. Studies have shown that in the first phase, the levels of proinflammatory mediators such as prostaglandin E₂, phospholipase A₂, cyclooxygenase I-II, callicrein and bradykinin are reduced. In addition, ozone treatment reduces levels of molecules responsible for joint destruction such as metalloproteinase, collagenase, and gelatinase. In the second phase, ozone therapy increases the levels of antioxidant enzymes, molecules and cytokines. Examples include oxidative shock proteins (hemo-oxygenase-1), Interleukin 4 and Interleukin 10, Transforming Growth Factor-β (TGF-β). It has also been shown that ozone therapy induced new vessel formation (neoangiogenesis), increases nitric oxide (NO) endorphin, adrenocorticotrophic hormone (ACTH) and cortisol levels [14].

In the face of this wide spectrum of activities, today's ozone therapy is available in many different system diseases such as osteomyelitis, chronic obstructive pulmonary disease, hepatitis, cystitis, rheumatoid arthritis, osteoarthritis, back pain, multiple sclerosis and coronary artery disease [15]. The aim of our study was to examine the effects of nontoxic ozone administration on the gout-induced joint model in therapeutic doses and to create an alternative to current in the future.

MATERIAL and METHODS

Following approval from the Kafkas University Local Experimental Animals Ethics Committee (KAÜ-HADYEK/2017-012) twenty adult albino male rats were used in the study. Rats were randomly divided into 4 groups and group 1 (Control, n=5) was followed up without any drug. 0.2 mL (10 mg) MSU was injected intra-articularly to 1st metatarsophalangeal joint through the right footpad to create experimental gout in the 2nd group (Control group, n=5) and was followed without additional treatment. A single dose of 0.2 mL (10 mg) MSU was injected intraarticularly to 1st metatarsophalangeal joint through the right footpad to create an experimental gout in group 3 (Gout + Ozone, n=5) followed by intraperitoneal 1 mL (10 µg/mL) ozone therapy daily in rats. Group 4 (ozone control, n=5) Ozone therapy was administered intraperitoneally 1 mL (10 µg/mL) daily without gout. Group 3 and group 4 administered once daily dose of 1 mL (10 µg/mL) intraperitoneally for 3 weeks. After 3 weeks of treatment, euthanasia was performed according to the condition of the rats and then the right hind paws were cut, and histopathology examined.

RESULTS

Confirmed radiological imaging of rats with gout (*Fig. 1*). The pathological results of the groups were compared statistically (P=0.003) (*Table 1*). In addition, the rate of suppression of inflammation in the ozone group was significantly higher than the control group (P=0.005). On the other hand, no statistically significant inflammation was observed in the 4th group which was given only ozone according to the control group (P=0.03). Control group (1st group) and ozone control group (4th group) and gout control group (2nd group) and ozone control group (3th group) were compared between each other in terms of epithelization (*Fig. 2A,B,C,D*). There was no statistically significant difference between the groups.

DISCUSSION

Gout is a common disease that causes severe pain and loss of work power during an acute exacerbation. The etiopathogenesis has been well researched with a wide range of treatments ranging from monoclonal antibody therapy to anti-inflammatory therapy in the treatment

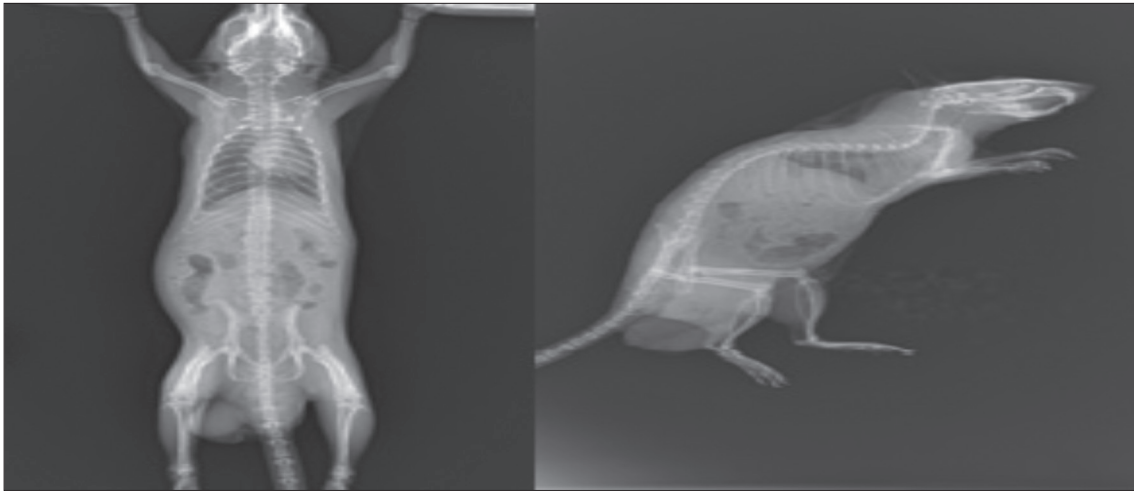


Fig 1. Radiological image of gut-generated rats

Table 1. Histopathological evaluation of the groups

Rat Number	Group Name	Inflammation	Proliferation	Reactive Epithelium
1	Control	No	No	No
2	Control	No	No	No
3	Control	No	No	No
4	Control	No	No	No
5	Control	No	No	No
6	Gout control	Distinct	Yes	Yes
7	Gout control	Distinct	Yes	Yes
8	Gout control	Distinct	Yes	Yes
9	Gout control	Distinct	Yes	Yes
10	Gout control	Distinct	Yes	Yes
11	Gout+Ozone	Moderate	Yes	Yes
12	Gout+Ozone	Moderate	Yes	Yes
13	Gout+Ozone	Moderate	Yes	No
14	Gout+Ozone	Slight	Yes	No
15	Gout+Ozone	Slight	Yes	Yes
16	Ozone control	No	No	Yes
17	Ozone control	No	No	No
18	Ozone control	No	No	No
19	Ozone control	No	No	No
20	Ozone control	Slight	No	No

of the disease. These treatments are given in the form of step-by-step treatment and are constantly updated as both side effects and treatment costs are considered [1]. Glucocorticoids and non-steroidal anti-inflammatory drugs are the leading cost-effective treatments for gout. Although its efficacy in long-term therapy has been proven, alternative forms of treatment are still needed in terms of potential side effects (Chronic Renal Failure, Diabetes Mellitus, Cushing Syndrome). In addition, xanthine oxidase inhibitors (allopurinol), selective xanthine oxidase inhibitor (febuxostat), drugs that increase uric acid excretion

(losartan, fenofibrate), turgous drugs (rasburicase) that provide resorption of tofus are tested among current medical treatments [16]. In the treatment of gout, two main titles are being considered today; to reduce the uric acid increase and to minimize the destructive effect of increased uric acid.

Ozone treatments instead of conventional therapy has been experimented on for many diseases because of the better understanding of the mechanism of action and lowering of treatment costs. It has been shown that ozone

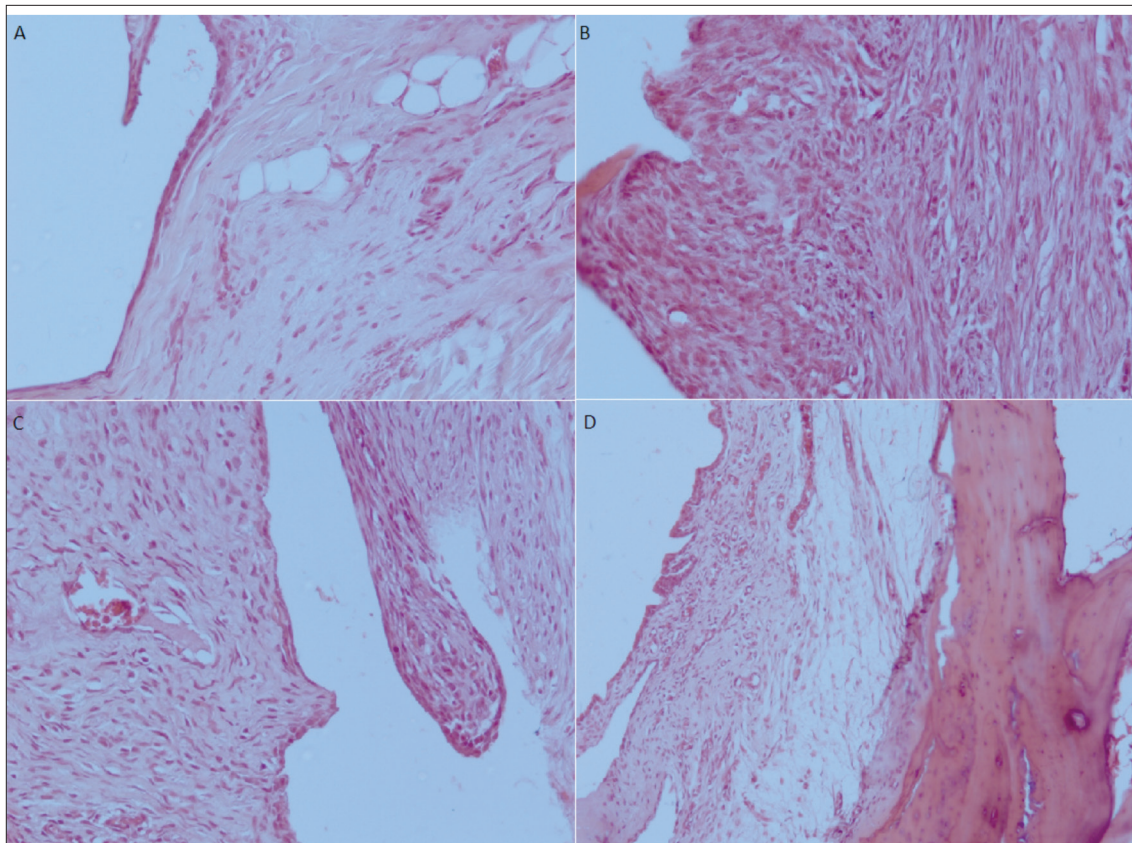


Fig. 2. Microscopic view of histopathological sections. A. Control group showing normal synovial and perisynovial tissue (H&E, 200x); B. Gouty arthritis group with reactive epithelial changes and active chronic inflammatory cells (H&E, 200x); C. Gouty arthritis + Ozon treatment group with mild active chronic inflammatory cells and no reactive changes (H&E, 200x); D. Ozon control group showing minimal reactive epithelial change and no inflammation (H&E, 100x)

treatment reduces serum uric acid levels in patients with osteoarthritis and also reduces VAS (visual analogue scale) and WOMAC (Western Ontario and Mac master index) scores and reduces joint pain [17,18]. Li and Ni [19] evaluated gut arthritis-associated pain-associated VAS scores in their study of ozone at a dose of 20 µg/mL on subjects with gout disease and found that the VAS score fell from 5.35 ± 2.78 to 3.30 ± 2.21 . As mentioned above, although there are studies in which the ozone treatment is given in the form of major hemotherapy in hyperuricemic patients and intraarticular in osteoarthritic patients, there is no study in the literature that examines the ozone effect in experimental gout joints in the literature. In ozone-treated patients, as indicated in other publications, it has been shown that the molecules responsible for joint destruction are reduced. In the study we conducted, a significant proliferation increases in the ozone Gout group was observed compared to the control group. Bilge et al. [20] studies on ozone treated rats with osteomyelitis found higher total serum antioxidant capacity and histopathologically found more positive results in terms of inflammation and abscess formation. Similarly, in our study ozone-induced inflammation was significantly suppressed. Although our study did not prevent the formation of proliferation or reactive epithelium when given intraarticularly, it showed suppressed inflammation,

and there was no significant pathologic change in the joints in the osteonecrosis test group 4. As a result, intraarticular ozone treatment was considered to be one of the advanced treatment options considering the potency and efficacy in Gout.

REFERENCES

- Khanna D, Khanna PP, Fitzgerald JD, Singh MK, Bae S, Neogi T:** American College of Rheumatology guidelines for management of gout. Part 2: Therapy and antiinflammatory prophylaxis of acute gouty arthritis. *Arthritis Care Res.* 64, 1447-1461, 2012. DOI: 10.1002/acr.21773
- Ahern M, Reid C, Gordon T, McCredle M, Brooks PM, Jones M:** Does colchicine work? The results of the first controlled study in acute gout. *Intern Med J*, 17 (3): 301-304, 1987. DOI: 10.1111/j.1445-5994.1987.tb01232.x
- Paulus HE, Schlosstein LH, Godfrey RG, Klinenberg JR, Bluestone R:** Prophylactic colchicine therapy of intercritical gout. A placebo-controlled study of probenecid-treated patients. *Arthritis Rheu*, 17 (5): 609-614, 1974. DOI: 10.1002/art.1780170517
- Zhu Y, Pandya BJ, Choi HK:** Prevalence of gout and hyperuricemia in the US general population: The National Health and Nutrition Examination Survey 2007-2008. *Arthritis Rheu*, 63 (10): 3136-3141, 2011. DOI: 10.1002/art.30520
- Martillo MA, Nazzari L, Crittenden DB:** The crystallization of monosodium urate. *Curr Rheumatol Rep*, 16:400, 2014. DOI: 10.1007/s11926-013-0400-9
- Parekh BB, Vasant SR, Tank KP, Raut A, Vaidya ADB, Joshi MJ:** *In vitro* growth and inhibition studies of monosodium urate monohydrate crystals by different herbal extracts. *Am J Infect Dis*, 5(3): 225-230, 2009.

DOI: 10.3844/ajidsp.2009.225.230

7. Richette P, Bardin T: Gout. *Lancet*, 375 (9711): 318-328, 2010. DOI: 10.1016/s0140-6736(09)60883-7

8. Cronstein BN, Terkeltaub R: The inflammatory process of gout and its treatment. *Arthritis Res Ther*, 8 (Suppl. 1): S3, 2006. DOI: 10.1186/ar1908

9. Martinon F, Pétrilli V, Mayor A, Tardivel A, Tschopp J: Gout-associated uric acid crystals activate the NALP3 inflammasome. *Nature*, 440, 237-241, 2006. DOI: 10.1038/nature04516

10. Pouliot M, James MJ, McColl SR, Naccache PH, Cleland LG: Monosodium urate microcrystals induce cyclooxygenase-2 in human monocytes. *Blood*, 91 (5): 1769-1776, 1998.

11. Punzi L, Scanu A, Ramonda R, Oliviero F: Gout as autoinflammatory disease: New mechanisms for more appropriated treatment targets. *Autoimmun Rev*, 12 (1): 66-71, 2012. DOI: 10.1016/j.autrev.2012.07.024

12. Bocci VA: Scientific and medical aspects of ozone therapy. State of the art. *Arch Med Res*, 37 (4): 425-435, 2006. DOI: 10.1016/j.arcmed.2005.08.006

13. Tapia SA, Grigorio MS: Ozone therapy and its scientific foundations. Биорадикалы и антиоксиданты, 1 (1): 10-33, 2014.

14. Bocci V: Ozone: A New Medical Drug. 19-29. Springer, Netherlands. 2005. DOI: 10.1007/1-4020-3140-8

15. do Prado Vendruscolo C, Moreira JJ, Seidel SRT, Fülber J,

Neuenschwander HM, Bonagura G, Agreste FR, Baccarin RYA: Effects of medical ozone upon healthy equine joints: Clinical and laboratorial aspects. *PloS One* 13 (5):e0197736, 2018. DOI: 10.1371/journal.pone.0197736

16. Terkeltaub R: Update on gout: New therapeutic strategies and options. *Nat Rev Rheumatol*, 6 (1): 30-38, 2010. DOI: 10.1038/nrrheum.2009.236

17. Camelia C, Madalina I, Tatiana M, Marilena P, Oana A: The role of ozone therapy in maintaining the articular function and in relieving the pain for patients with knee osteoarthritis. *Arsm*, 20 (1): 25-29, 2014. DOI: 10.2478/arsm-2014-0005

18. Fernandez-Cuadros ME, Perez-Moro OS, Albaladejo-Florin MJ, Algarra-Lopez R: Intra articular ozone reduces serum uric acid and improves pain, function and quality of life in knee osteoarthritis patients: A before-and-after study. *Middle East J Rehabil Health Stud*, 5 (3): e68599, 2018. DOI: 10.5812/mejrh.68599

19. LI LY, NI JX: Efficacy and safety of ozonated autohemotherapy in patients with hyperuricemia and gout: A phase I pilot study. *Exp Ther Med*, 8 (5): 1423-1427, 2014. DOI: 10.3892/etm.2014.1951

20. Bilge A, Ozturk O, Adali Y, Ustebay S: Could ozone treatment be a promising alternative for osteomyelitis? An experimental study. *Acta Ortop Bras*, 26 (1): 67-71, 2018. DOI: 10.1590/1413-785220182601179926