


## Conjunctival Dermoid in A Belgian Malinois Dog

Musa KORKMAZ <sup>1</sup>  Unal YAVUZ <sup>2</sup> H. Huseyin DEMIREL <sup>3</sup> Ibrahim DEMIRKAN <sup>1</sup>

<sup>1</sup> Department of Surgery, Faculty of Veterinary Medicine, University of Afyon Kocatepe, TR-03200 Afyonkarahisar - TURKEY

<sup>2</sup> JAKEM, Horse and Small Animal Clinics, TR-50000 Nevsehir - TURKEY

<sup>3</sup> Department of Pathology, Faculty of Veterinary Medicine, University of Afyon Kocatepe, TR-03200 Afyonkarahisar - TURKEY

Makale Kodu (Article Code): KVFD-2013-9256

### Summary

In this report, the gross and histopathological findings and the surgical treatment of a rarely seen case conjunctival dermoid was described in Belgian Malinois dog. A 6 month-old female Belgian Malinois dog, weighing 8 kg was referred to the University animal hospital with the complaint an abnormal mass on the right eye. In ophthalmic examination of right eye, epiphora and conjunctival hyperaemia were observed. Mass in the right conjunctiva at the temporal canthus was surgically removed. In microscopic examination, resected tissue revealed that dermoid was originated from conjunctiva.

**Keywords:** *Malinois, Conjunctival dermoid, Choristoma, Dog, Sebaceous gland*

## Belçika Malinois Irkı Bir Köpekte Konjunktival Dermoid

### Özet

Bu makalede, Belçika Malinois ırkı bir köpekte nadir olarak görülen konjunktival dermoid olgusunun cerrahi tedavisi ile makroskopik ve histopatolojik bulguları tanımlandı. 6 aylık, 8 kg ağırlığında Belçika Malinois ırkı dişi bir köpek, sağ gözünde anormal bir kitle bulunduğu şikayeti ile üniversite hayvan hastanesine getirildi. Sağ gözün oftalmik muayenesinde aşırı göz yaşı akıntısı ve konjunktival hiperemi belirlendi. Sağ göz konjunktivasının temporal açısında izlenen kitle cerrahi olarak uzaklaştırıldı. Mikroskopik muayenede, rezeke edilen kitlenin konjunktivadan köken alan bir dermoid olduğu anlaşıldı.

**Anahtar sözcükler:** *Belçika Malinois, Konjunktival dermoid, Koristom, Köpek, Yağ bezi*

### INTRODUCTION

Dermoids are examples of a choristoma or congenital circumscribed overgrowth of microscopically normal tissue in an abnormal place <sup>[1,2]</sup>. This congenital malformation may involve the ocular and periocular tissues <sup>[3]</sup> and may occur on lids, the conjunctiva or the cornea or as an inclusion cyst within the orbit <sup>[4]</sup>. Ocular dermoid contains many of the structures of normal skin such as epidermis, dermis, fat, sebaceous glands or hair follicles <sup>[5,6]</sup>. Ocular dermoid has been reported in several domestic animals such as dogs <sup>[6-10]</sup>, cats <sup>[11]</sup>, horses <sup>[12]</sup>, sheep <sup>[13]</sup>, cattle <sup>[14]</sup>, rabbit <sup>[15,16]</sup>, Guinea pigs <sup>[4]</sup>, and birds <sup>[17]</sup>.

The aim of the present report was to describe a rarely seen case of conjunctival dermoid and its surgical intervention in Belgian Malinois dog.

### CASE HISTORY

A 6 month-old female Belgian Malinois dog, weighing 8 kg was referred to the University animal hospital with an abnormal mass on the right eye. Ophthalmic examination revealed that epiphora and hyperaemia at the right conjunctiva were evident. Moreover, a dermoid in the right conjunctiva at the temporal canthus was observed (*Fig. 1A*). Fluorescein stain test was performed to identification of any corneal ulceration. No corneal ulceration was evident. Then the surgical intervention was considered. The patient was premedicated by subcutaneous administration of 0.04 mg/kg atropine sulphate (Atropin 2%, Vetas, Turkey) 30 min before the surgery. The sedation was performed by 2 mg/kg intramuscular administration of xylazine HCl (Alfazyne 2%, Egevet, Turkey). General anaesthesia was



İletişim (Correspondence)



+90 555 5431187



musakorkmaz@aku.edu.tr

induced by intramuscular administration of 10 mg/kg ketamine HCl (Alfamine 10%, Egevet, Turkey). Cephalic vein was cannulated for the administration of lactated Ringer's solution (10 mL/kg/h) during the surgical procedure. Cefozolin sodium (20 mg/kg) was administered intravenously before surgery as a prophylactic treatment. Then aseptic surgery was performed. After fixation of globe, abnormal tissue at the conjunctiva was removed in a routine manner using a surgical blade and microsurgical instruments. The conjunctival defect was not sutured and the haemorrhage was controlled (Fig. 1B). Postoperatively, tobramycin (Tobrex 0.3%, Alcon, Turkey) was applied topically twice daily for 7 days. Epithelialisation of conjunctival defect completed about 10 days after surgery.

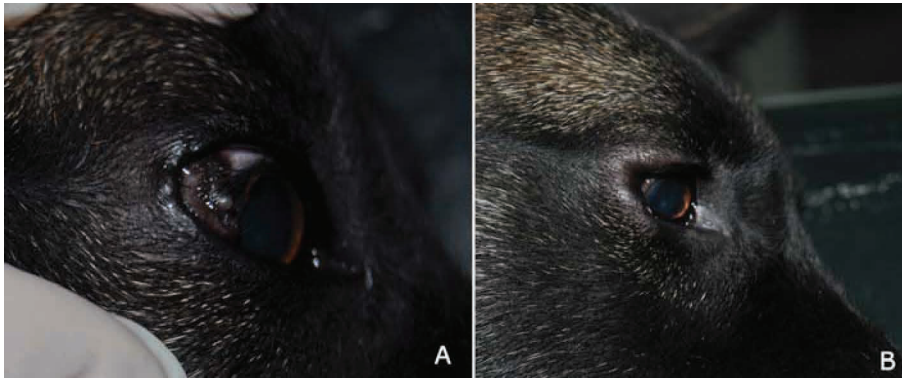
### Histopathologic Findings

Tissue (resected from the right conjunctiva) were fixed in 10% formalin solution and embedded in paraffin. Five micron sections were stained with haematoxylin and eosin (H&E) and examined under a light microscope (Olympus Bx51, Tokyo, Japan) and photographed by a digital camera

(DP20, Tokyo, Japan). Histopathologically, the excised lesion showed characteristics of normal epidermis with a squamous epithelium and dense melanin pigmentation in basal cells. Moreover, it was observed that the conjunctival dermoid contained sebaceous and sweat glands and blood vessels (Fig. 2). The examination of the resected tissue revealed that it was a conjunctival dermoid.

## DISCUSSION

Ocular dermoid have been reported in various animals [4,12-17] however there are limited reports which describe the conjunctival dermoids in dogs [6,9]. It has been postulated that most dermoids seen in dogs are corneal dermoids [7-10]. Erdikmen *et al.* [9] reported that 16 of 22 dogs with dermoids presented corneal dermoids. Dermoids may be existed in the eyelids, conjunctiva (palpebral or bulbar) and nictitating membrane, unlike cornea is commonly affected [1]. Dermoids usually localize at the temporal limbal area and extend to the sclera and cornea [7]. In our case, the dermoid was originated from conjunctiva and localized at

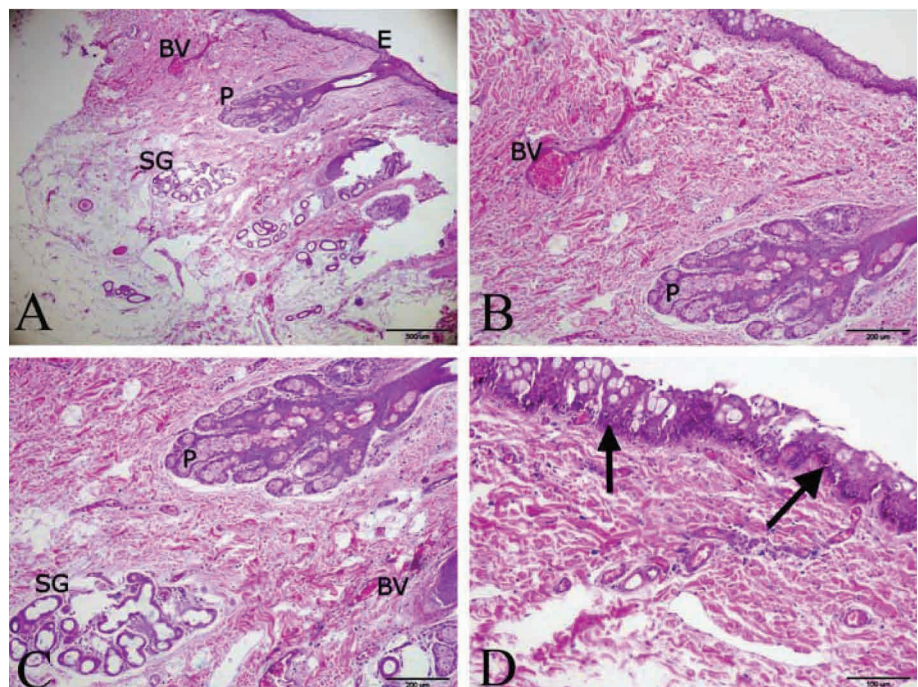


**Fig 1.** Preoperative (A) and postoperative (B) appearance of the right eye of case.

**Şekil 1.** Olgunun sağ gözünün preoperatif (A) ve postoperatif (B) görünümü

**Fig 2.** Histopathologic section of resected tissue from the conjunctiva

A- Epidermis (E), Sebaceous gland (P), sweat gland (SG), blood vessel (BV), H&E, x4, B- Sebaceous gland (P), blood vessel (BV), H&E, x10, C- Sebaceous gland (P), sweat gland (SG), blood vessel (BV), H&E, x10, D- Dense melanin pigmentation of basal cells (arrows), H&E, x20



**Şekil 2.** Konjuktivadan rezeke edilen dokunun histopatolojik kesiti

A- Epidermis (E), Yağ bezi (P), Ter bezi (SG), kan damarı (BV), H&E, x4, B- Yağ bezi (P), Kan damarı (BV), H&E, x10, C- Yağ bezi (P), Ter bezi (SG), Kan damarı (BV), H&E, x10, D- Bazal hücrelerde melanin pigmentinin birikimi (oklar), H&E, x20

the temporal limbal area as previously described above [7].

The ocular dermoids appear to be a breed predisposition in the German Shepherd dog [6,9], Saint Bernard, Golden Retriever and Dachshunds [9]. This malformation is generally congenital, but not hereditary [18]. Moreover, the ocular dermoids were determined in Anatolian Shepherd dog [8,9], Doberman Pincher, Dogo Argentina, Rottweiler, Gorden Setter [9]. To the authors' knowledge, this is the first case reported the conjunctival dermoid in Belgian Malinois dog in our clinics.

The epiphora and keratoconjunctivitis may occur due to the continuously irritation of hair to the cornea [6,8,18]. In our study, it has been observed that epiphora and mild conjunctivitis were seen on the right eye. Keratitis has not been determined due to the limited connection of hair and cornea. Our aforementioned findings suggest that ulcerative keratitis may not be observed in all cases of conjunctival dermoid in dogs. Histopathologically, the dermoids contain many of the elements of normal skin such as epidermis, dermis, fat, sebaceous glands, hair follicles and adipose tissue [2,7,9]. Similarly, in our case, sebaceous gland, sweat gland and blood vessels were observed in the microscopical examination of the resected tissue.

In conclusion, to the author's knowledge, this rarely seen conjunctival dermoid case is the first report in Belgian Malinois dog in our clinics and the data generated here may contribute to the current veterinary literature.

## REFERENCES

- 1. Gelatt KN:** Pediatric ophthalmology in small animal practice. *Vet Clin North Am: Small Anim Pract*, 3, 321-333, 1973.
- 2. Maggs DJ:** Conjunctiva. In, DJ Maggs, PE Miller, R Ofri (Eds): *Slatter's Fundamentals of Veterinary Ophthalmology*. 4<sup>th</sup> ed., 135-150, Saunders Elsevier, Missouri, 2008.
- 3. Shields JA, Laibson PR, Augsburger JJ, Michon CA:** Central corneal dermoid: A clinicopathologic correlation and review of the literature. *Can J Ophthalmol*, 21, 23-26, 1986.
- 4. Wappler O, Allgoewer I, Schaeffer EH:** Conjunctival dermoid in two guinea pigs: A case report. *Vet Ophthalmol*, 5, 245-248, 2002.
- 5. Oakman JH, Lambert SR, Grossniklaus HE:** Corneal dermoid: Case report and review of classification. *J Ped Ophthalmol Strabismus*, 30, 388-391, 1993.
- 6. Jhala SK, Joy N, Patil DB, Parikh PV, Kelawala NH, Patel AM:** Removal of dermoid cyst in a German shepherd dog. *Vet World*, 3, 339, 2010.
- 7. Brudenall DK, Bernays ME, Peiffer RL:** Central corneal dermoid in a Labrador retriever puppy. *J Small Anim Pract*, 48, 588-590, 2007.
- 8. Apaydin N, Albasan H, Alan E:** Kangal köpeğinde korneal dermoid olgusunun süperfişyal keratektomi ile sağaltımı. *Erciyes Üni Vet Fakt Derg*, 5, 129-131, 2008.
- 9. Erdikmen DO, Aydin D, Saroglu M, Güzel O, Hasimbegovic H, Ekici A, Yubasioglu Ozturk G:** Surgical correction of ocular dermoids in dogs: 22 cases. *Kafkas Univ Vet Fak Derg*, 19 (Suppl-A): A41-A47, 2013.
- 10. Lee JI, Kim MJ, Kim IH, Kim YB, Kim MC:** Surgical correction of corneal dermoid in a dog: Case report. *J Vet Sci*, 6, 369-370, 2005.
- 11. Glaze MB:** Congenital and hereditary ocular abnormalities in cats. *Clin Techn Small Anim Pract*, 20, 74-82, 2005.
- 12. Munoz E, Leiva M, Naranjo C, Penat T:** Retrobulbar dermoid cyst in a horse: A case report. *Vet Ophthalmol*, 10, 394-397, 2007.
- 13. Bukar MM, Geidam YA, Aliyu MM:** Corneal dermoid and microphthalmia of sheep and cattle in borno state, Nigeria. *J Anim Vet Adv*, 7, 911-914, 2008.
- 14. Isler CT, Bulut S, Kilic S:** Hatay bölgesinde yetiştirilen sığırlarda karşılaşılan göz problemlerinin insidanslarının araştırılması. *Fırat Üni Vet Fak Derg*, 22, 255-259, 2008.
- 15. Wagner F, Brugmann M, Drommer W, Fehr M:** Corneal dermoid in adwarf rabbit (*Oryctolagus cuniculi*). *Contemp Top Lab Anim Sci*, 39, 39-40, 2000.
- 16. Styer CM, Ferrier WT, Labelle P, Griffey SM, Kendall LV:** Limbic dermoid in a New Zealand White rabbit (*Oryctolagus cuniculus*). *Contemp Top Lab Anim Sci*, 44, 46-48, 2005.
- 17. Bayon A, Almela RM, Talavera J:** Avian ophthalmology. *Eur J Comp Anim Pract*, 17, 253-266, 2007.
- 18. Kalpravidh M, Tuntivanich P, Vongsakul S, Sirivaidyapong S:** Canine amniotic membrane transplantation for corneal reconstruction after the excision of dermoids in dogs. *Vet Res Commun*, 33, 1003-1012, 2009.