

LETTER TO THE EDITOR

Increasing Feline Mycobacterial Infections and Diagnostic Confusion

Ebru ERAVCI YALIN ¹(*) , Mehmet Fatih BOZKURT ² ¹ Istanbul University-Cerrahpaşa, Faculty of Veterinary Medicine, Surgery Department, TR-34320 Istanbul - TÜRKİYE² Afyon Kocatepe University, Faculty of Veterinary Medicine, Pathology Department, TR-03200 Afyonkarahisar - TÜRKİYE

(*) Corresponding author:

Ebru Eravci Yalin
Phone: +90 212 404 0300
Cellular phone: +90 537 572 9679
E-mail: eburu.eravciyalin@iuc.edu.tr

How to cite this article?

Eravci Yalin E, Bozkurt MF: Increasing Feline Mycobacterial Infections and Diagnostic Confusion. *Kafkas Univ Vet Fak Derg*, 32 (2): 299-300, 2026.
DOI: 10.9775/kvfd.2026.36194

Article ID: KVFD-2026-36194

Received: 24.01.2026

Accepted: 24.02.2026

Published Online: 24.02.2026

Dear Editor,

Mycobacterial infections in cats are characterized by granulomatous inflammation and are considered among diseases that are infrequently reported in the literature, while being capable of involving multiple organ systems and presenting with variable clinical manifestations ^[1]. During the evaluation of feline patients presenting to the clinics of Istanbul University-Cerrahpaşa Veterinary Hospital and the review of imaging consultations referred to our unit, cases exhibiting findings consistent with mycobacterial infections were encountered with noteworthy frequency. In addition, consultation requests from colleagues in different cities regarding feline cases with similar clinical and radiological features suggest that this situation may indicate a broader distribution rather than merely reflecting a local case accumulation.

When feline cases diagnosed with mycobacterial infection in the clinic were examined, it was observed that mycobacterial infections may involve numerous organs and systems. Ocular involvement was identified as retinal detachment, uveitis, intraocular or retrobulbar mass-like formations, and conjunctival masses. Central nervous system involvement manifested as single or multiple mass lesions in the brain and spinal cord, as well as a meningitis pattern. Pulmonary involvement was characterized by diffuse or localized interstitial pneumonia patterns accompanied by nodular opacities. In the nasal region,

space-occupying lesions involving the nasal cavity and sinuses, with associated involvement of the bone and the potential to cause soft tissue swelling or ulcerative lesions, were detected. In addition, single or multiple mass-like lesions in the skin and subcutaneous tissue, lytic lesions or cortical thickening in bone, enlargement and mineralization of lymph nodes, as well as various internal organ involvements, were identified during clinical and imaging evaluations.

One of the main problems encountered during the diagnostic process is that lesions may be interpreted as progressive histiocytoma or nonspecific histiocytic inflammation during histopathological evaluation of biopsy specimens. In lesions in which granulomatous or pyogranulomatous inflammation predominates, failure to adequately consider a mycobacterial etiology during the initial evaluation may lead to delays in diagnosis. Imaging findings also contribute significantly to diagnostic uncertainty. In cases with central nervous system involvement, contrast-enhancing lesions producing mass effect on magnetic resonance imaging are frequently interpreted in favor of neoplastic processes. Similarly, nodular or interstitial patterns detected on thoracic radiographs are often considered consistent with fungal infections. To illustrate these diagnostic challenges, representative examples of clinical appearance and imaging findings corresponding to different anatomical localizations are presented below (*Fig. 1*).



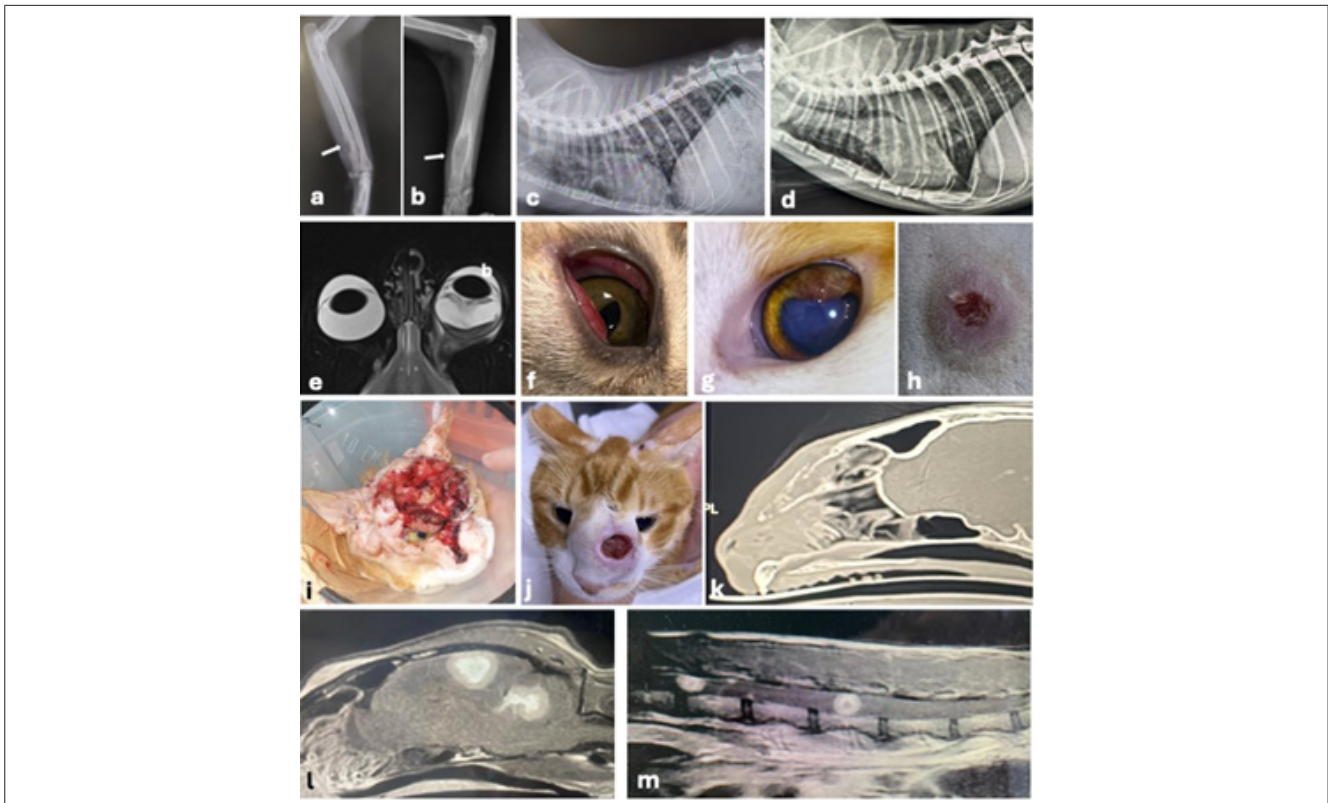


Fig 1. (a) Lateral radiograph of the ulna with osteolysis (arrow), (b) the radius with fusiform shaped, moth eaten- lysis and cortical expansion, (c) a miliary nodular pattern with multiple small soft tissue nodules, (d) marked perihilar lymphadenopathy, (e) retinal detachment with subretinal exudation and perineural mass surrounding the optic nerve, (f) upper and lower eyelid conjunctival mass, (g) dorsolateral uveal granuloma, (h) cutaneous nodular lesion with a centrally ulcerated, well-defined margin, (i) severe ulcerated cutaneous mass with raised, irregular margins, (j) nasal cutaneous lesion with central ulceration, raised margins, and expansion of the nasal bone, (k) computed tomography image of the nasal region showing soft tissue attenuation occupying the nasal cavity, and a focal lytic area involving the dorsal nasal wall, MRI images of the brain (l) and spinal cord (m), sagittal T1W post-contrast sequences shows round mass like lesions with a concentric target sign

Another important consequence of delayed or incorrect recognition of mycobacterial infections is the under-estimation of the disease's potential for transmission. Members of the *Mycobacterium tuberculosis* complex are known to pose a zoonotic risk in cats. In particular, *Mycobacterium bovis* infections represent a public health concern for animal owners and veterinary professionals who are in contact with infected animals ^[2,3].

In feline cases presenting with granulomatous lesions involving multiple organ systems and mimicking neoplastic or fungal diseases, mycobacterial infections should be carefully considered in the differential diagnosis. Considering the presence of similar cases reported from different cities, increasing veterinary awareness of this disease is expected to contribute significantly to improving diagnostic accuracy and to a better understanding of its epidemiological characteristics.

REFERENCES

1. Lloret A, Hartmann K, Pennisi MG, Gruffydd-Jones T, Addie D, Belák S, Boucraut-Baralon C, Egberink H, Frymus T, Hosie MJ, Lutz H, Marsilio F, Möstl K, Radford AD, Thiry E, Truyen U, Horzinek MC: Mycobacterioses in cats: ABCD guidelines on prevention and management. *J Feline Med Surg*, 15 (7): 591-597, 2013. DOI: 10.1177/1098612X13489221
2. O'Halloran C, Tørnqvist-Johnsen C, Woods G, Mitchell J, Reed N, Burr P, Gascoyne-Binzi D, Wegg M, Beardall S, Hope J, Gunn-Moore D: Feline tuberculosis caused by *Mycobacterium bovis* infection of domestic UK cats associated with feeding a commercial raw food diet. *Transbound Emerg Dis*, 68 (4): 2308-2320, 2021. DOI: 10.1111/tbed.13889
3. Commandeur S, van der Most M, Koomen J, van Keulen L, Dinkla A, Luinenburg X, Escher M, Jacobs P, Keur I, Grinwis GCM, Weerts E, Broens EM, Anthony R, Kamst-van Agterveld M, Rebel K, Huisman E, Heijne M, Koets A: *Mycobacterium bovis* infected domestic cats in an officially bovine tuberculosis free country resulting in human infection. *One Health*, 20:101048, 2025. DOI: 10.1016/j.onehlt.2025.101048