

RESEARCH ARTICLE

First Record of Trombiculosis Due to the Chigger Mite *Kepkatrombicula desaleri* in Domestic Goats in Bulgaria and Treatment Attempts

Nikola NIZAMOV¹ (*)  Petar ILIEV¹  Hristo BOYCHEV¹ ¹ Trakia University, Faculty of Veterinary Medicine, Department of Veterinary Microbiology, Infectious and Parasitic Diseases, 6014 Stara Zagora, BULGARIA

(*) Corresponding author: Nikola NIZAMOV

Phone: +359 042 699 590
Cellular phone: +359 898 332 326
E-mail: nikola_nizamov@abv.bg

How to cite this article?

Nizamov N, Iliev P, Boychev H: First record of trombiculosis due to the chigger mite *Kepkatrombicula desaleri* in domestic goats in Bulgaria and treatment attempts. *Kafkas Univ Vet Fak Derg*, 29 (4): 351-355, 2023.
DOI: 10.9775/kvfd.2023.29259

Article ID: KVFD-2023-29259

Received: 24.02.2023

Accepted: 22.06.2023

Published Online: 11.07.2023

ABSTRACT

Trombiculosis is a parasitic skin disease caused by larvae of mites from the family Trombiculidae (chiggers). In general, larvae provoke dermatitis. *Kepkatrombicula desaleri* Methlagl, 1928 is one of species involved in the etiology of animal trombiculosis, detected in European goats. The aim of the present study was to detect the species of trombiculid mites infesting goats and to recommend appropriate means for control of provoked disease. The study included total of 141 goats from two flocks in the Kalugerovo village, Pazardzhik district, Bulgaria. All infested goats from the first flock were treated with ivermectin, and those from the second flock - with cypermethrin. The identification of larvae showed their affiliation to the *K. desaleri* Methlagl, 1928 species. In the first flock, 15 infected goats were detected (17%) vs 7 (13%) in the second flock. The mites were detected on eyelids, medial eye angles, nose and ears as orange-red papules. Neither squamae nor crusts were found in the skin adjacent to chiggers' location, and goats did not show any clinical signs. The treatment with ivermectin was ineffective, and spraying with cypermethrin resulted in reduced motility and rapid death of 100% of mites only several minutes after the treatment. The mites infected only animals with dark haircoat regardless of their age and sex.

Keywords: Bulgaria, chiggers, goats, mites, treatment

INTRODUCTION

Trombiculosis is a parasitic skin disease caused by larvae of mites from the family Trombiculidae with more than 1500 known species worldwide [1]. The larvae (chiggers, red bugs, and harvest mites) may infect many host species, including amphibians, birds and mammals [2]. The consequent stages of their life cycle are: egg, prelarva (deutovum), larva, protonymph (nymphochrysalis), deutonymph (nymph), tritonymph (imagochrysalis) and imago. In moderate climatic areas, the parasite has one to three generations per year [3]. After successful attachment to an appropriate host, the chiggers feed on for 3-5 days and then pursue their development as free-living arthropods. Chiggers feed mainly on partially lysed cutaneous cells and lymph and usually cause dermatitis. Feeding is realized by a feeding tube or stylostome formed by the interaction of mite saliva and host tissue [2]. The host skin reaction is strong and manifested with intense infiltration of leukocytes, neutrophils and erythrocytes in inflammatory foci. Apart from inflammatory exudate, larvae may also uptake red blood cells from foci of

inflammation. In the view of [4] the swelling, epidermal hyperplasia and hyperkeratosis are not specific signs of this infestation. Some species serve as vectors of the rickettsia *Orientia tsutsugamushi*, which causes an acute infectious disease spread in southeastern Asia [5].

In Europe, trombiculosis is caused by the larvae of about 50 mite species [6], including 8 species isolated from murid rodents in Turkey [7]. Four species from this family have been described in men: *Neotrombicula autumnalis* Shaw, 1790, *Kepkatrombicula desaleri* Methlagl, 1928, *Blankaartia acuscutellaris*, Walch, 1922 and *Trombicula toldti*, Winkler, 1952 [6]. Despite that the parasites are known to infect numerous mammalian species, the reports in hoofed animals are rare [4,8,9]. In this connection, the most prevalent species is *N. autumnalis* Shaw, 1790 [10]. The morphology of *K. desaleri* larva is very similar to that of *N. autumnalis* larva [11]. The difference between the two species is the presence of elongated seta on the tibia of the last pair of legs. This fact as well as the unclear taxonomy of the group probably leads to misidentification, especially in hoofed mammals.



Kepkatrombicula desaleri Methlagl, 1928 has been detected on goats in Europe [8,11]. It infects ungulates, whereas in humans it was registered only by the author that described it for the first time. Unlike most trombiculid mites, this species has a sucker disk in the apical part of the hypostome, allowing successful feeding on large hosts [4].

Clinical signs reported in goats are milder than those observed in dogs and humans; in massive infestation, they include scratching, rubbing and licking. Also, they are similar to those of scabies, which should be considered in the differential diagnosis list [13].

Attempts for control of the disease at a global scale have been made only in companion animals and horses. Therefore, the aim of the present study was to determine the species of trombiculid mites infesting goats from studied flocks and to recommend appropriate means for control of resulting trombiculosis.

MATERIAL AND METHODS

Ethical Statement

Ethics committee approval is not required for this study as it is within the scope of veterinary practice.

Animals

The study was conducted from 30 October to 19 November 2022. It was performed on two goat flocks in Kalugerovo village, Pazardzhik district: the first with 88 goats and the second - with 53 goats.

Examinations

All animals were examined with a magnifying glass for presence of skin alterations and ectoparasites. Detected parasites were collected in 70% ethanol and transported to the laboratory for identification. A DMi1 S/M 424790 Leica® microscope (Leica Microsystems CMS GmbH) equipped with a Leica MC120 HD camera was used for the microscopic exams and photographic materials. The identification was done according to descriptions of Kudryashova and Stekolnikov [11].

Treatment

All infested goats from the first flock were treated subcutaneously with ivermectin (Pandex™ 1%, Biovet), at a dose of 0.2 mg/kg body weight. The treatment results were evaluated twice: on the 1st and 3rd post treatment days. The trombiculid-positive goats from the second flock were treated with cypermethrin (Ectomin 10%, Farmavet OOD), applied by spraying at a concentration of 0.2%.

Statistical Analysis

All measurements (total body length ± SD) were calculated by means of descriptive statistics (IBM® SPSS® Statistics 26.0 software).

RESULTS

Out of all collected 42 chiggers, 16 were with preserved integrity and were identified as larvae of the *K. desaleri* species (Fig. 1; Fig. 2; Fig. 3). The total body length varied from 240 to 520 µm (mean±SD 337.5±86.7 µm), depending on the feeding level. That is why, the latter is not used as an identification criterion. In contrast, the shape of the scutum and the number and arrangement of setae are indicative for identification. Our results revealed that the scutum is broad with rounded posterior margin; present of anterolateral shoulders; 48-61 dorsal idiosomal setae with anterior two rows paired; 4 sternal setae and 32-41 ventral setae; 82-103 total number of idiosomal setae.

Out of the studied 88 goats in the first flock, 15 were positive for the parasite (17%). In the second studied flock, 7 out of 53 animals (13%) harboured mites from the same species. Neither squamae nor crusts were found out on the skin surrounding the attachment site of the parasites, and goats showed no clinical signs. Infected goats were



Fig 1. *Kepkatrombicula desaleri* Methlagl, 1928 - dorsal view



Fig 2. *Kepkatrombicula desaleri* Methlagl, 1928 - scutum

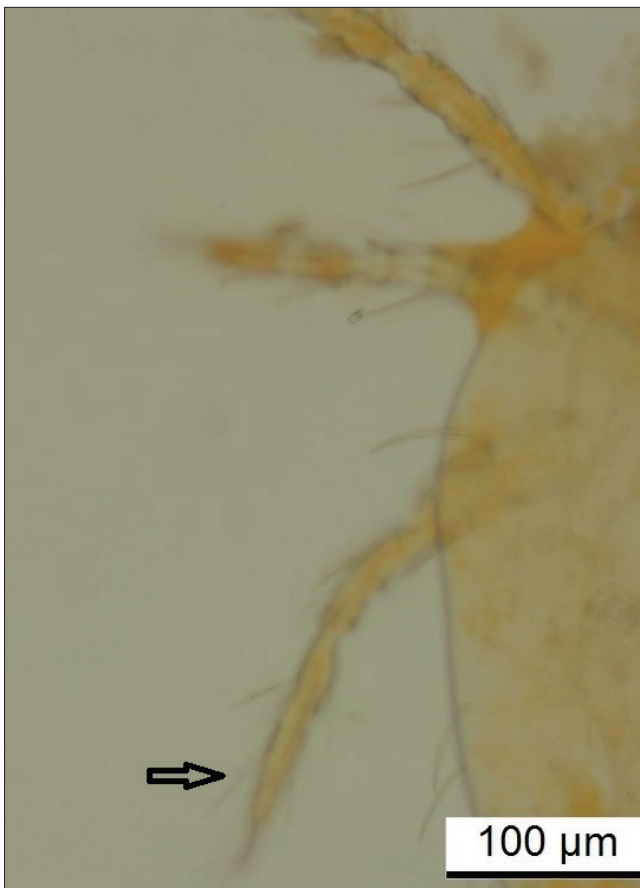


Fig 3. Elongated bristle (seta) of the tibia of the last pair of legs

from both sexes, at various ages and with different body conditions. A specific finding was that only goats with dark (black) haircoat were infested. The mean intensity of infestation was 32 mites per animal. In all goats, the mites were detected on eyelids, medial eye angles (Fig. 4), nose and only in one animal on ears.

The injection of ivermectin (Pandex™ 1%, Biovet) showed no efficacy against *K. desaleri* both on the first and on the third post treatment days. The treatment with cypermethrin (Ectomin 10%, Farmavet OOD) resulted in decreased motility and rapid death of all (100%) mites only within several minutes. No mites were found on the first and the third post treatment days.

DISCUSSION

The species affiliation of larvae detected in this study matched the data of Rehbein et al.^[8] and Stekolnikov and Mumcuoglu^[12]. Stekolnikov and Kar^[14] identified larvae of the *Neotrombicula heptneri* Kudryashova, 1973 species on goats in Turkey, whereas according to Faccini et al.^[15] caprine trombiculosis in Spain was caused by the species *Eutrombicula alfreddugesi* Oudemans, 1910 and *Eutrombicula batatas* Linnaeus, 1758. These findings made clear that goats may become infested with more

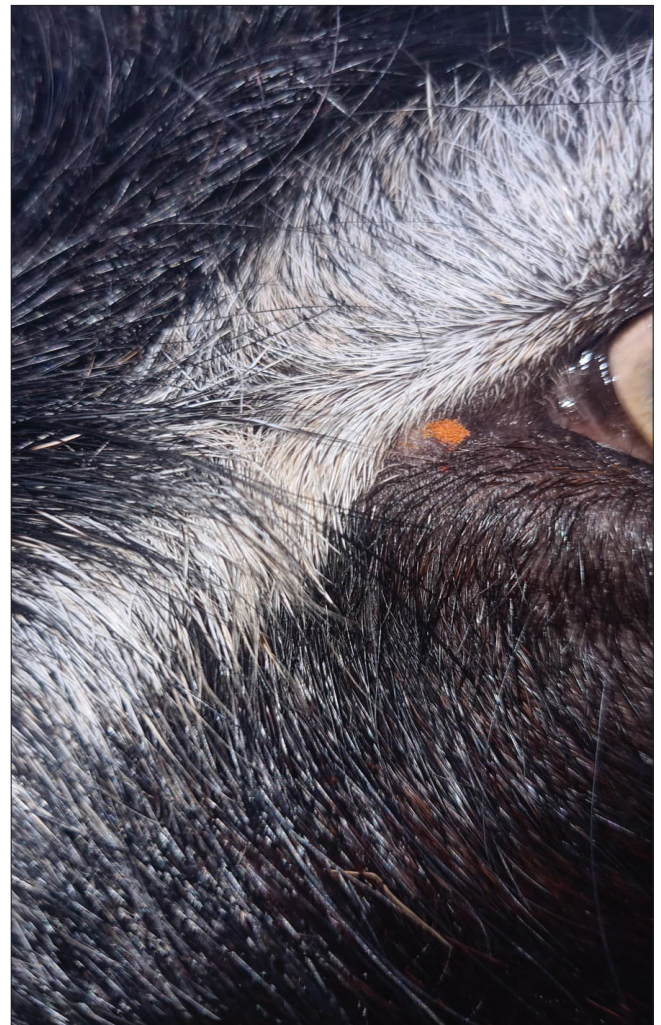


Fig 4. Localisation of *Kepkatrombicula desaleri* Methlagl, 1928 in the medial angle of the eye

than one trombiculid mite species. Additional studies are necessary to find out whether goats in Bulgaria are infested only with *K. desaleri* or other chigger species are also encountered.

In this study, the chiggers infestation was detected during the autumn, in line with data published by Gerstgraser^[16] and Stekolnikov and Kar^[14]. In Spain, Faccini et al.^[15] reported an extensive infestation during the rainy season (March-September) which contradicts our results. This may be attributed to the different climatic conditions specific for the two studies. The same researchers also indicated humidity, rainfall and ambient temperature as factors favouring the infestation, i.e. conditions similar to those during the autumn season in our country. According to Rashmir-Raven^[17], the different species from the family have various seasonal patterns.

The relatively low intensity and extensity of infestation, established in the present study, do not correspond to data of Stekolnikov and Kar^[12], reporting 100% extensity

and intensity from 20 to 80 mites per animal. A possible reason for the discrepant results may be sought in factors influencing the non-parasitic (free-living) life stages of mites.

Regarding the localisation of parasites, all authors agreed that orange-red skin bumps were detected on areas sparsely covered with hair in the region of the head - eyelids, ears, nose, mouth [8,14,15]. In infestations with high intensity, mites may also colonize the back, chest, abdomen, udder and extremities [15].

According to Gerstgraser [16], goats of all age groups may be affected. This was confirmed in our study, but a more extensive survey is needed to determine any age-dependent relationships.

Clinical signs and skin alterations, as scratching, rubbing, licking, alopecia, scaly erythematous skin and papules reported by others [15] were not observed, probably because of the low intensity of invasion (n=32).

In relation to disease treatment, phenylpyrozoles and isoxazolines have shown a high efficacy against mites from this family. Fipronil, as a broad-spectrum local insecticide, resulted in removal of most chiggers within 12 h after application, whereas isoxazoline administration - for 6-8 h [18]. These drug groups are however contraindicated for use in farm animals such as goats.

Leone and Albanese [19] have used a selamectin spot-on in cats at 6 mg/kg and established 100% efficacy on the second day without recurrence of the infestation until the 60th day. Despite that ivermectin is from the same therapeutic group (macrocyclic lactones), yet applied by a different route and in a different animal species, the reported result was not observed by us. This finding is perplexing as being a strongly lipophilic compound [20], ivermectin attains a high level in the skin [21], where the parasite feeds on. Mondragón and Guzmán [22] recommended the drug for local application in men. Possibly, its inefficacy was due to the route of application (s.c.) that could hardly yield the optimum skin concentrations.

In horses, Rashmir-Raven [17] recommended permethrin, pyrethrin, cypermethrin and foxim for treatment of trombiculosis, applied through spraying or bathing. The high efficacy of cypermethrin was confirmed in our studies on goats.

The detected chigger on goats in Bulgaria, *K. desaleri*, demonstrated low intensity and extensity of infestation and was not accompanied by clinical signs. Like all periodically stationary ectoparasites, the chiggers population was strongly influenced by environmental factors. The changes in the latter may increase mite numbers with appearance of medium- to severe clinical signs reported in the literature. The efficacy of ivermectin used for treatment

in the present study was poor which does not match with what has been published previously, therefore these results should be subjected to further controlled experiments. In contrast, the efficacy of cypermethrin was high (100%) and should be the treatment of choice for control and treatment of caprine trombiculosis.

Availability of Data and Materials

The datasets used and/or analyzed during the current study are available from the corresponding author (N. Nizamov) on reasonable request.

Acknowledgements

The authors would like to thank the owners of the animals Lyodmila Neschkova and Vasil Bangiozov for their cooperation during the collection of the samples.

Ethical Statement

Ethics committee approval is not required for this study as it is within the scope of veterinary practice.

Funding Support

The study is funded by the Faculty of Veterinary Medicine, Trakia University (Approval No: 08/2021).

Conflict of Interest

The authors declared that there is no conflict of interests.

Author Contributions

NN: Researched the literature, and drafted manuscript; PI: Participated in laboratory analyses and revised the manuscript; HB: Conceived the work. All the authors read and approved the final manuscript.

REFERENCES

1. Wall R, Shearer D: Mites (Acari). In, Veterinary Ectoparasites: Biology, Pathology and Control. 2nd ed., 47-48, Blackwell Science, London, U.K., 2001.
2. Mullen GR, OConnor BM: Mites (Acari). In, Medical and Veterinary Entomology. 533-602, Academic Press, Cambridge, USA, 2019.
3. Mendoza-Roldan JA, Otranto D: Chigger Mites (Trombiculidae). In, Benelli G, Encyclopedia of Infection and Immunity. 793-800, Stockholm, Sweden, 2022.
4. Shatrov AB, Stekolnikov AA: Redescription of a human-infesting European trombiculid mite *Kepkatrombicula desaleri* (Acari: Trombiculidae) with data on its mouthparts and stylostome. *Int J Acarol*, 37 (1): 176-193, 2022. DOI: 10.1080/01647954.2010.548342
5. Takahashi M, Misumi H, Urakami H, Nakajima S, Furui S, Yamamoto S, Furuya Y, Misumi M, Matsumoto I: Mite vector (Acari: Trombiculidae) of scrub typhus in a new endemic area in Northern Kyoto, *Japan J Med Entomol*, 41, 107-114, 2004. DOI: 10.1603/0022-2585-41.1.107
6. Silva RB: Chigger mites of Brazilian birds: Morphological studies and investigation of the presence of associated pathogens. *PhD/MSc Thesis*. Universidade de São Paulo, 2021.
7. Açıcı M, Demirtaş S, Gürler AT, Bölükbaş CS, Umur Ş: A diagnostic survey of chigger mites (Acari: Trombiculidae) of wild rodents and soricomorphs in Turkey. *Kafkas Univ Vet Fak Derg*, 27 (1): 123-128, 2021. DOI: 10.9775/kvfd.2020.24593
8. Rehbein S, Visser M, Messner C, Wohltmann A: Massiver Befall mit Larven von *Kepkatrombicula desaleri* (Acari: Trombiculidae) bei einem Gamskitz aus Tirol. *Vet Med Austria*, 98, 255-260, 2011.
9. Gomez-Puerta LA, Olazabal J, Lopez-Urbina MT, Gonzalez AE:

Trombiculiasis caused by chigger mites *Eutrombicula* (Acari: Trombiculidae) in Peruvian alpacas. *Vet Parasitol*, 190, 294-296, 2012. DOI: 10.1016/j.vetpar.2012.06.012

- 10. Kampen H:** Die Herbstmilbe *Neotrombicula autumnalis* und andere parasitische Laufmilben (Acari, Trombiculidae) als Verursacher von Hauterkrankungen in Mitteleuropa, 461-476, Linz, Austria, 2002.
- 11. Kudryashova NI, Stekolnikov AA:** *Kepkatrombicula* nom. n., a new name for the chigger mite genus *Eutonella* Kudryashova, 1988 (Acari: Trombiculidae), with notes on its systematics. *Acarina* 18, 79-80, 2010.
- 12. Stekolnikov AA, Mumcuoglu KY:** Contribution to the taxonomy of human-infesting chiggers (Acariformes: Trombiculidae) in Europe. *Syst Appl Acarol*, 26 (9): 1636-1652, 2021. DOI: 10.11158/saa.26.9.2
- 13. Glawischnig W:** Herbstgrasmilbenbefall bei einer Gamsgeiß. *Jagd Tirol*, 4:10, 1996.
- 14. Stekolnikov AA, Kar S:** A case of domestic goat parasitism by *Neotrombicula heptneri* (Acariformes: Trombiculidae) in Turkey. *Acarologia*, 55 (4): 355-359, 2015. DOI: 10.1051/acarologia/20152176
- 15. Faccini JLH, Santos ACG, Santos SB, Jacinavicius FDC, Bassini-Silva R, Barros-Battesti DM:** Trombiculiasis in domestic goats and humans in the state of Maranhão, Brazil. *Rev Bras Parasitol Vet*, 26, 104-109, 2017. DOI: 10.1590/S1984-29612016088
- 16. Gerstgrasser L:** Grasmilbenbefall bei einer Gamsgeiß. *Jägerzeitung. Magazin des Sudtiroler Jagdverbandes*, 2:41, 2011.
- 17. Rashmir-Raven AM:** Disorders of the skin. In, Reed SM, Bayly WM, Sellon DC (Eds): *Equine Internal Medicine*. 4th ed., 18, 1159-1183, 2018. DOI: 10.1016/B978-0-323-44329-6.00018-8
- 18. Santibáñez P, Gallo E, Palomar AM, Portillo A, Carrillo JA, Oteo JA:** Trombiculiasis in a dog with severe neurologic disorders, Spain. *Emerg Infect Dis*, 26 (4): 819-820, 2020. DOI: 10.3201/eid2604.191313
- 19. Leone F, Albanese F:** P-28 Efficacy of selamectin spot-on formulation against *Neotrombicula autumnalis* in eight cats. *Vet Dermatol*, 15, 49-49, 2004. DOI: 10.1111/j.1365-3164.2004.00414_28.x
- 20. Rocha LS, Soares DCL, Singh N, dos Santos Andrade TDJA, do Nascimento VA:** Ivermectin pharmacokinetics and the danger of its use in high dosage. *J Res Pharmaceut Sci*, 7 (4): 17-23, 2021.
- 21. Boussinesq M, Enyong P, Chounna-Ndongmo P, Njouendou AJ, Pion SD, Rech A, Wanji S:** Effects of an injectable long-acting formulation of ivermectin on *Onchocerca ochengi* in zebu cattle. *Parasite*, 27, 2020. DOI: 10.1051/parasite/2020036
- 22. Mondragón ÉAG, Guzmán RA:** Trombidiasis (trombiculiasis): Revisión de una enfermedad común pero poco diagnosticada. *Cuestionario. Dermatología Cosmética, Médica y Quir*, 19 (4): 353-358, 2022.

