

RESEARCH ARTICLE

Prognostic Value of Haptoglobin and Ceruloplasmin Levels Determined in Cows with Adhesive and Non-adhesive Traumatic Reticuloperitonitis

Enes AKYÜZ^{1,a (*)} Uğur AYDIN^{2,b}¹ Kafkas University, Faculty of Veterinary Medicine, Department of Internal Medicine, TR-36100 Kars - TÜRKİYE² Kafkas University, Faculty of Veterinary Medicine, Department of Surgery, TR-36100 Kars - TÜRKİYEORCID: ^a 0000-0002-3288-2058; ^b 0000-0001-5756-4841

Article ID: KVFD-2021-27040 Received: 29.12.2021 Accepted: 27.03.2022 Published Online: 28.03.2022

Abstract: The aim of this study was to compare haptoglobin, ceruloplasmin, some macro mineral levels and hematological parameters in cow with adhesive and non-adhesive traumatic reticuloperitonitis (TRP). For this purpose, 20 cow with adhesive TRP constituted group 1 (G1), 20 cow with non-adhesive TRP constituted group 2 (G2), and 20 healthy cow formed the control group (C). Blood samples were taken from cow with clinical suspicion of TRP, and the inflammation status was examined by performing the glutaraldehyde test. As a result of radiographic inspection, it was decided to perform rumenotomy for the cows determined that the foreign body had penetrated the reticulum. The cows were divided into groups according to the presence or absence of adhesion during the rumenotomy. Total leukocyte count was found to be significantly higher in G1 compared to G2 and C. Calcium, magnesium, phosphorus and albumin were found to be significantly lower in G1 and G2 compared to the C (P<0.05). Haptoglobin and ceruloplasmin were determined to be at the highest level in G1 compared to the other groups (P<0.05). In this study, detection of positive acute phase proteins with higher levels of G1 and lower levels of albumin was found to be important. In conclusion, we think that these parameters will provide important information in determining the presence of adhesion in cows with TRP. In addition, according to the information obtained from the cow owners after rumenotomy, it was learned that the general health status of the cows in G1 was distressed. In the light of these data, the relevant parameters before rumenotomy can give an idea for prognostic evaluation in TRP.

Keywords: Ceruloplasmin, Cow, Haptoglobin, Prognosis, Traumatic reticuloperitonitis

Adeziv ve Non-adeziv Travmatik Retikulooperitonitisli İneklerde Haptoglobin ve Seruloplazmin Düzeylerinin Prognostik Değeri

Öz: Bu çalışmanın amacı adeziv ve non-adeziv retikulooperitonitis travmatika'lı (RPT) ineklerde haptoglobin, seruloplazmin, bazı makro mineral düzeylerinin ve hematolojik parametrelerin karşılaştırılması ve ayırıcı tanısal önemi belirlenmeye çalışılmıştır. Bu amaçla çalışmada adeziv RPT'li 20 inek grup 1 (G1), non-adeziv RPT'li 20 inek grup 2 (G2) ve sağlıklı 20 inek kontrol grubu (K) olarak belirlenmiştir. Klinik olarak RPT şüphesi olan sığırlardan kan örnekleri alınarak glutaraldehit testi ile yangı durumu incelendi. Radyografik görüntüleme ile tanı konulduktan sonra sığırlara rumenotomi yapıldı. Rumenotomi sırasında adezyon olup olmamasına göre sığırlar gruplara ayrıldı. Toplam lökosit sayısı G1'de G2 ve kontrole göre anlamlı yüksek bulundu. Kalsiyum, magnezyum, fosfor ve albumin seviyeleri G1 ve G2'de K grubuna göre önemli derecede düşük bulundu (P<0.05). Pozitif akut faz proteinleri olan haptoglobin ve seruloplazmin diğer gruplara kıyasla G1'de en yüksek seviyede olduğu belirlendi (P<0.05). Bu çalışmada, G1'de pozitif akut faz proteinlerinin yüksek düzeyde ve albuminin ise daha düşük düzeyde saptanması önemli bulunmuştur. Sonuç olarak bu parametrelerin RPT'li ineklerde adezyon varlığının belirlenmesinde önemli bilgiler sağlayacağını düşünüyoruz. Ayrıca rumenotomi sonrası inek sahiplerinden alınan bilgilere göre G1'deki ineklerin genel sağlık durumlarının sıkıntılı olduğu öğrenildi. Bu veriler ışığında rumenotomi öncesi ilgili parametreler RPT'de prognostik değerlendirme için fikir verebilir.

Anahtar sözcükler: Haptoglobin, İnek, Prognoz, Retikulooperitonitis travmatika, Seruloplazmin

INTRODUCTION

Traumatic reticuloperitonitis (TRP) is a disease resulting in the development of various degrees of inflammation

and complications due to penetration of sharp pointed foreign bodies ingested with feed to the reticulum [1-5]. The reasons for the frequent occurrence of TRP in cow are that they do not use their lips while taking feed in, they

How to cite this article?

Akyüz E, Aydın U: Prognostic Value of haptoglobin and ceruloplasmin levels determined in cows with adhesive and non-adhesive traumatic reticuloperitonitis. *Kafkas Univ Vet Fak Derg*, 28 (3): 337-344, 2022.
DOI: 10.9775/kvfd.2021.27040

(*) Corresponding Author

Tel: +90 474 242 6836/5201

E-mail: enesakyuz_44@hotmail.com (E. Akyüz)



This article is licensed under a Creative Commons Attribution-NonCommercial 4.0 International License (CC BY-NC 4.0)

have no sense of detecting foreign body, they take their food voraciously and swallow it quickly without chewing in large masses, their sensitivity and sense of taste of the tongue is underdeveloped, their papillae on the tongue are turned backward, and their esophagus is wide and produce excessive saliva [4,6]. Many factors cause the formation of the disease including insufficient feeding, pica, penetrating objects randomly thrown into the environment and carelessness of the caregivers in preparing the feed. Foreign bodies coming into the reticulum after ingestion often puncture the reticulum wall and cause local or diffuse peritonitis. Sometimes, it causes more serious complications by sinking into the liver, kidney, spleen, lung and heart, causing various degrees of inflammation in these organs [3,7-10]. As a result of inflammation in the pathophysiology of TRP, the amount of fibrinogen, which is an acute phase protein, increases and will reveal the risk of adhesion formation [3]. As a result of these complications, many hematological and biochemical changes can occur in cow with TRP and serum calcium, magnesium, phosphorus and albumin levels are decreased. As a result of TRP, diffuse inflammation, intestinal malabsorption, liver dysfunction and anorexia can result in a decrease in negative acute phase protein albumin, calcium, magnesium and phosphorus concentrations [2,3,11-14]. Acute phase proteins are classified according to their increase or decrease after infection. Those that increase after infection are called positive acute phase proteins (e.g., haptoglobin and ceruloplasmin), those that decrease are called negative acute phase proteins (e.g., albumin) [15]. Acute phase proteins are proteins produced by the liver as a result of inflammation, tissue injury, infection, neoplastic growth or immunological disorders. The functions of these proteins include protecting the organism from further injury, clearing harmful molecules and residues for the organism, activating the repair process necessary for the organism to return to its normal function and restoring homeostasis. Although there are many acute phase proteins known today, important acute phase proteins for cattle include haptoglobin, serum amyloid A, fibrinogen, albumin, alpha 1 acid glycoprotein. There is an increase in positive acute phase proteins and a decrease in negative acute phase proteins in cattle with TRP [3]. Many studies have been reported on the importance of acute phase proteins in different animal diseases. In calves with diarrhea [15], peripartum period sheep [16], Holstein cows [17], in neonatal calves with diarrhea [18], cattle with brucellosis [19], cows with endometritis [20], cattle with foot and mouth disease [21], *Hypoderma* spp. infested cattle [22], infectious respiratory system diseases complex in cattle [23], normal and power-bearing cows [24], sheep infected with *Streptococcus plurimalium* [25], calves with pneumonia [26] acute phase proteins have been investigated on different animals and diseases.

We planned to conduct this study to determine which operation or platform treatment should be preferred according to the level of acute phase proteins determined in TRP and to determine the importance of measuring the level of acute phase proteins in this decision. In this study, it was aimed to compare the haptoglobin, ceruloplasmin and some macro mineral levels of the cow in the adhesion-formed TRP group compared to the cow in both the control group (C) and the non-adhesion group, and also to evaluate these parameters in terms of diagnosis.

MATERIAL AND METHODS

Ethical Statement

This study was conducted by the approval of the Local Ethics Board for Animal Experiments of Kafkas University (KAU-HADYEK), Research Code: KAU-HADYEK-2021/103), Kars, Türkiye.

Animals

In the study, 20 cows with adhesive TRP, 3-6 years old, Simmental, with clinical complaints of anorexia, pain, depression, hunched posture were diagnosed as TRP following clinical and radiographic examinations. Cases were brought to the clinic between 3-7 d after clinical symptoms appeared. A total of 60 cows have similar clinical symptoms, 20 with adhesive TRP in group 1 (G1), 20 with non-adhesive TRP in group 2 (G2), and 20 healthy cows in the C, were included. In our study, 65% of the cows with TRP gave birth in the last period of pregnancy and 35% of them gave birth recently. C group animals consist of cows of the same age, breed and characteristics, brought from the same barns to our faculty clinic for control purposes. Healthy animals consist of cows of the same age, breed and characteristics, brought to our faculty clinic for control purposes, in the same barn conditions as the sick ones. Since approximately 65% of the cows in the TRP groups were pregnant at last term, 65% of the cows in the C group were also selected from those in the last term. Adhesion was determined during the rumenotomy.

Blood Samples

All cows were blood sampled once by withdrawing 10 mL blood from the jugular vein into serum tubes with gel (BD Vacutainer®, BD, UK) and tubes with K₂EDTA (BD Vacutainer®, BD, UK). Blood samples taken for serum were kept at room temperature for about one hour and centrifuged at 3000 RPM for ten min (Hettich Rotina 380R®, Hettich, Germany). All blood samples were stored at -20°C until analysis.

Biochemical and Hematological Analyses

Blood samples in K₂EDTA were assessed for total leukocyte count (WBC x10³/µL) and other hematological parameters

using a complete blood cell count device (VG-MS4e®, Melet Schloesing, France). Complete blood cell count was measured within 15 min immediately after blood collection. Serum calcium, phosphorus, and magnesium were measured with a fully automatic biochemistry device (Mindray BS120®, Mindray Medical Technology, Türkiye). Haptoglobin was determined as reported by Skinner et al.^[27], ceruloplasmin was measured by the method of Colombo and Richterich^[28], and albumin was measured colorimetrically on device (Epoch, Biotek, USA) using a commercial test kit (Biolabo, France).

Glutaraldehyde Test

The test was performed by mixing 2 mL of blood and 2 mL of 1.4% glutaraldehyde solution. The mixture was put into a 10 mL glass tube. It was turned upside down at 30 sec intervals. Coagulation within 15 min was considered positive. Test result was considered as clotting between 0-5 min severe, 5-10 min moderate and 10-15 min mild inflammation. Coagulations longer than 15 min were considered normal^[29].

Radiography

Radiographic images of patients with suspected TRP were taken for definitive diagnosis. Reticulum and diaphragm border were evaluated in radiological examination. Dynamic brand ceiling static x-ray device and FCR prima brand (Fujifilm FCR Prima T2 Veterinary Set®, Medical Technology, Türkiye) imaging unit were used in the radiological evaluation. For this purpose, irradiation doses between 20-40 mA and 80-95 kW were adjusted according to the size of each cow. Radiographic images were taken by irradiation at a distance of 75 cm between the tube and the cassette. Then, the reticulum, diaphragmatic border and chest cavity were examined in detail for the presence of foreign body.

Rumenotomy

Rumenotomy was performed in the patients with foreign body detected as a result of radiological as well as other clinical examinations. The left fossa paralumbalis was prepared for the operation. After shaving and disinfection of the operation area (70% ethyl alcohol + 10% povidone iodine), local infiltrative (reverse L) anesthesia was applied using lidocaine (Vilcain®, Vilsan, Türkiye). Following anesthesia, a 12-15 cm long straight incision was made from the proximal to the distal 7-8 cm caudal to the last ribs, 5-6 cm below the processus transversus of the lumbar vertebrae. After incising the skin, subcutaneous connective tissues, muscles and peritoneum, the rumen were exposed. Before the rumen was opened, the abdominal cavity was examined in detail by inspection and palpation (trans-peritoneal exploration) for adhesions. Then the foreign body was removed from the reticulum by performing routine rumenotomy and all incised layers were

closed using appropriate suture materials. Postoperative medications were prescribed and the patient was discharged.

Statistical Analysis

Data were given as mean \pm standard error of mean (SEM). The groups were in accordance with the normal distribution according to the histogram, Q-Q graph method and Shapiro-Wilk test. The one-way ANOVA test was used for multiple comparisons of the groups, and the Tukey HSD test was used for post-hoc comparisons. SPSS (SPSS Version 26.0®, Chicago, IL, USA) program was used for all statistical analyses. The differences between the groups in terms of the parameters examined were considered significant at the $P < 0.05$ level.

RESULTS

Clinically, anorexia, depression, hunched posture, abdominal pain and groaning were determined in cows with TRP. In addition, 14 cows in G1 were pregnant for 6 months or more, and 6 of them gave birth within 10 d to 3 months. 12 cows in the G2 group were pregnant for 6 months or more, and 8 of them gave birth within 10 days to 3 months. Physical examination findings (rectal temperature, respirations per minute and pulse rate) of all cows in the study were given in the [Table 1](#). A partial increase was observed in the mean rectal temperature, respiratory and pulse rates per minute of cows in G1 and G2 compared to the C. While the total leukocyte, neutrophil, and lymphocyte counts were found to be high in TRP, the hemoglobin and red blood cell counts were found to be low ([Table 1](#)). Serum calcium, phosphorus, magnesium, albumin, haptoglobin and ceruloplasmin levels of cows in all groups were shown in [Fig. 1](#). While calcium, magnesium, phosphorus and albumin levels were found to be lower in the patient groups compared to the C ($P < 0.05$, [Fig. 1-A,B,C,D](#)), positive acute phase proteins haptoglobin and ceruloplasmin were found to be significantly higher ($P < 0.001$, [Fig. 1-E,F](#)).

Glutaraldehyde Test Findings

Glutaraldehyde test revealed very severe inflammation in 16 cows, moderate inflammation in 3 cows, and mild inflammation in 1 cow in G1. Six of the cows had very severe inflammation, 9 had moderate inflammation, and 5 had mild inflammation in G2. C had tested normal with glutaraldehyde.

Radiological Findings

In the radiological examination, it was observed that the foreign body penetrated the reticulum and passed into the abdominal cavity in 23 of the patients. Of these, 15 were in the direction of the base of the reticulum, and 8 of them were in the direction of the diaphragm ([Fig. 2-A](#)). In 6 of

Table 1. Hematology and physical examination findings of cow with traumatic reticuloperitonitis and control group

Parameters	Groups (Mean ± SEM)			P Value
	G1	G2	C	
Body temperature (°C)	38.67±0.28	38.43±0.26	38.23±0.12	0.364
Breaths/min.	27.80±1.82	29.70±6.11	19.60±0.88	0.140
Heart beats/min.	75.40±4.60	73.80±5.90	65.60±1.78	0.263
Total leukocytes count (x10 ³ /μL)	23.55±1.90 ^a	13.00±1.56 ^b	8.35±0.50 ^b	<0.001
Lymphocytes (%)	46.31±9.34 ^{ab}	25.28±2.28 ^b	48.18±5.32 ^a	0.030
Monocytes (%)	4.41±0.73 ^{ab}	2.22±0.30 ^b	6.89±1.47 ^a	0.008
Granulocytes (%)	49.28±9.95 ^{ab}	72.50±2.47 ^a	44.89±6.47 ^b	0.021
Lymphocytes count (x10 ³ /μL)	11.20±2.74 ^a	2.78±0.39 ^b	4.03±0.55 ^b	0.002
Monocytes count (x10 ³ /μL)	1.11±0.23 ^a	0.26±0.03 ^b	0.59±0.15 ^{ab}	0.004
Granulocytes count (x10 ³ /μL)	11.24±2.66 ^a	9.66±1.38 ^{ab}	3.73±0.57 ^b	0.013
Red blood cell count (x10 ⁶ /μL)	6.16±0.41 ^b	8.18±0.75 ^a	7.77±0.48 ^{ab}	0.042
Mean red cell volume (fL)	45.97±2.31	51.64±1.49	43.50±2.88	0.052
Hematocrit (%)	28.18±2.36 ^b	42.37±4.45 ^a	32.20±1.90 ^{ab}	0.010
Mean erythrocyte hemoglobin (pg)	13.28±0.56 ^b	15.18±0.49 ^a	13.85±0.42 ^{ab}	0.033
Mean erythrocyte hemoglobin volume (g/dL)	29.24±0.93 ^b	29.57±0.92 ^b	34.61±1.84 ^a	0.011
Erythrocyte distribution width (fL)	14.02±0.65	12.36±0.27	13.74±0.47	0.052
Hemoglobin (g/dL)	8.19±0.64 ^b	12.27±0.98 ^a	10.30±0.49 ^{ab}	0.002
Platelet count (x10 ³ /μL)	568.10±72.20	840.50±172.93	525.40±103.44	0.167
Mean platelet volume (fL)	6.91±0.08	6.72±0.07	6.86±0.09	0.249
Platelets (%)	0.39±0.05	0.57±0.12	0.43±0.07	0.310
Platelet distribution width (fL)	6.81±0.11	6.48±0.22	6.22±0.21	0.100

^{a, b} The mean values with different letters in the same line represent the difference between patient and control groups (P<0.05). The number of cow in all groups is 20; SEM: Standard error of mean; G1: Adhesive traumatic reticuloperitonitis group; G2: Non-adhesive traumatic reticuloperitonitis group; C: Control group

the other 17 cases, foreign bodies were observed within the borders of the reticulum while attached to the magnet; In addition, when the cases were examined in terms of the diaphragm border, it was observed that the diaphragm border was irregular in patients with a foreign body penetrating the reticulum and passing into the abdominal cavity. Abscession was observed at the diaphragm border in 3 of the cases. In non-adhesive cases, it was observed that the foreign body was embedded in the surface of the reticulum or appeared free, and the borders of the diaphragm and reticulum were regular (Fig. 2-C).

Intraoperative Findings

When the abdominal cavity was examined during the operation, it was observed that the adhesions were very severe in cases in which foreign bodies penetrating the reticulum and passed into the abdominal cavity (Fig. 2-B). On the other hand, adhesions were found to be more minimal in cases in which foreign bodies penetrated the reticulum but did not pass into the abdominal cavity, and

in cases in which foreign bodies were found to appear free in the reticulum. It was observed that the border of the diaphragm and reticulum was regular in non-adhesive cases where the foreign body was embedded in the surface of the reticulum or the foreign body appeared to be free in the reticulum (Fig. 2-D). It was remarkable that abdominal adhesions were very severe in patients with positive glutaraldehyde test in clinical examinations. In G1, the clinical symptoms were more severe, adhesion was evident on radiographic imaging, severe inflammation was found in the glutaraldehyde test, and the health status of the majority was poor in the information obtained after rumenotomy. In the first week after rumenotomy, cow owners were called and their health status was learned. According to the information given by the cow owners, it was reported that the general health status of 60% (12 to 20) of G1 cows and 15% (3 to 20) of G2 cows were deteriorated. In our study, the majority of foreign bodies causing TRP were wires (72.5%), and nails (17.5%) and other metal objects (10%) were less common.

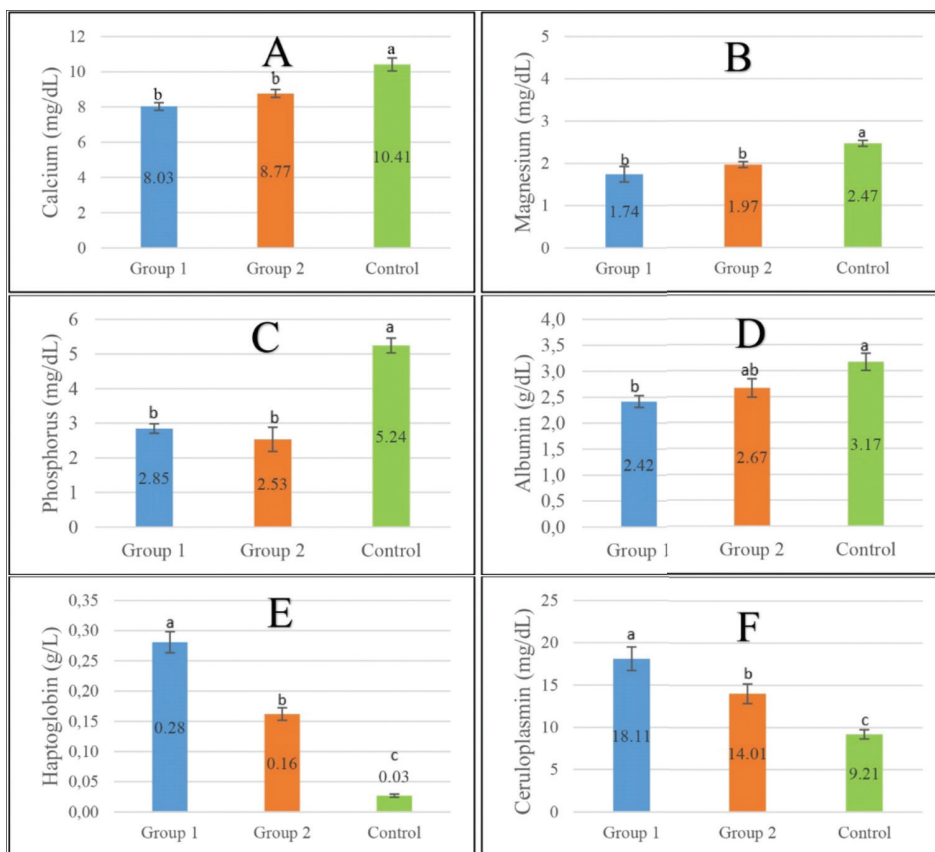
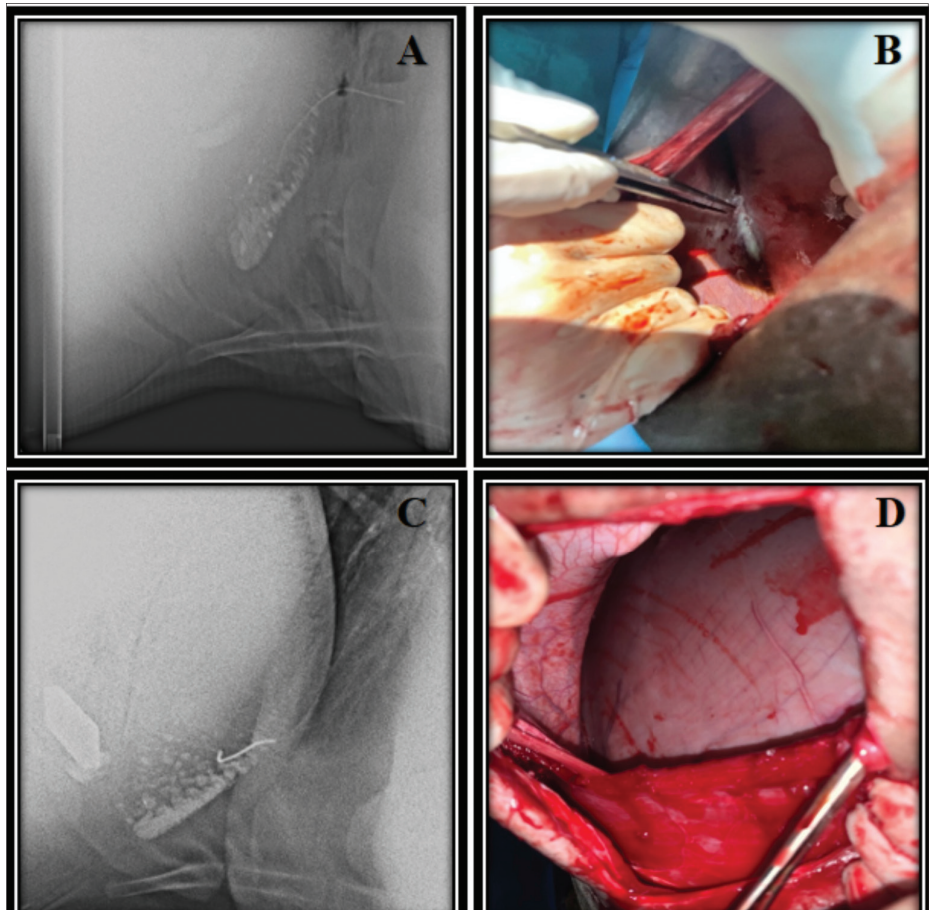


Fig 1. Comparison of mean values of serum calcium, magnesium, phosphorus, albumin, haptoglobin and ceruloplasmin levels of group 1, group 2 and control group cow. **A.** Comparison of mean serum calcium level of cow in group 1, group 2 and control group (P<0.001), **B.** Comparison of mean serum magnesium level of group 1, group 2 and control group cow (P<0.001), **C.** Comparison of mean serum phosphorus level of group 1, group 2 and control group cow (P<0.001), **D.** Comparison of mean serum albumin level of group 1, group 2 and control group cow (P=0.006), **E.** Comparison of mean serum haptoglobin level of group 1, group 2 and control group cow (P<0.001), **F.** Comparison of mean serum ceruloplasmin level of group 1, group 2 and control group cow (P<0.001). Group 1: Adhesive traumatic reticuloperitonitis group. Group 2: Non-adhesive traumatic reticuloperitonitis group

Fig 2. Radiographic and rumenotomy images of cows with adhesive and non-adhesive traumatic reticuloperitonitis. **A.** Radiographic image of a cow with adhesive traumatic reticuloperitonitis. Radiographic image of the foreign body penetrating the reticulum and traveling in the direction of the diaphragm and the image of the abscess at the diaphragm border, **B.** Rumenotomy image of a cow with adhesive traumatic reticuloperitonitis, **C.** Radiographic image of a cow with non-adhesive traumatic reticuloperitonitis. In non-adhesive cases, it was observed that the foreign body was embedded in the surface of the reticulum or appeared free, and the borders of the diaphragm and reticulum were regular, **D.** Rumenotomy image of a cow with non-adhesive traumatic reticuloperitonitis. It was observed that the border of the diaphragm and reticulum was regular in non-adhesive cases where the foreign body was embedded in the surface of the reticulum or the foreign body appeared to be free in the reticulum



DISCUSSION

The fact that 65% of the cows with TRP in our study were at the last period of term and 35% had just given birth supports the information that foreign bodies are taken and penetrate with more feed in this period [3,6]. In the present study, symptoms such as loss of appetite, weight loss, deterioration of general condition, symptoms of pain, signs of indigestion, hunched posture, and reluctance to move were also reported in previous studies in cows with TRP [3,9,30,31]. Studies have reported that metallic objects causing TRP are wires and nails, and often the cranioventral of the reticulum where it sinks [2,3,30]. In animals with TRP, serious changes occur in blood parameters in the acute period. Initially, a severe leukocytosis occurs depending on the severity and the complexity of the infectious agents [3,11]. In our study, leukocytosis in G1 and G2 was also present. In addition, a significant increase was detected in the granulocyte, monocyte and lymphocyte counts in G1 compared to the other groups, while a decrease was observed in the platelet, erythrocyte, hemoglobin and hematocrit percentages. Leukocytosis and anemia might have been the result of TRP related inflammation and bleeding. Studies have reported that the glutaraldehyde test in TRP groups gives positive results from inflammation compared to healthy groups [1,3]. In our study, we think that the reason why the total leukocyte counts were higher in G1 than in G2 was directly proportional to the severity of the inflammation. Depending on the severity of inflammation, the amount of neutrophils in the blood may increase. The fact that the glutaraldehyde test showed more severe inflammation in G1 than in G2 confirms this.

Changes in serum mineral levels were determined in previous studies in cows with TRP [3,14]. TRP causes inappetence food intake and digestive system disorders [32], and thus resulting in decrease of serum calcium and phosphorus levels [3,12,33]. In the presented study, serious decreases in serum calcium, phosphorus and magnesium levels were found in the sick groups as a result of anorexia, dilation of the digestive system due to peritonitis, and ruminal stasis. In addition, the decreased serum calcium level might be associated with hypoalbuminemia [2,3,11]. In addition, since the advanced pregnancy rate in the TRP groups was approximately 65% and the cows in the K group had similar pregnancy status, they were included in the study. In this way, the effect of pregnancy status on mineral levels was minimized.

Acute phase proteins are proteins synthesized by the liver in response to inflammation, tissue damage, infection, and neoplastic growth. The amount of serum albumin may decrease as a result of the destruction caused by infections and inflammation [15,33,34]. In our study, serious

decreases were observed in G1 and G2 as the total leukocyte count was higher than the C, positive glutaraldehyde test indicated severe inflammation, and food intake was also stopped, as it could cause disruption in the production of albumin, which is a negative acute phase protein. Haptoglobin levels increase in cases of acute infection, inflammation, and trauma [15], while decreases are observed in recovery or chronic stages [9,35]. It has been reported that increased haptoglobin levels in cow with TRP is due to the continuation of the traumatic situation, stress and surgery [9,35]. Stress can increase even more in the disease [36]. In our study, haptoglobin levels were significantly higher in the sick groups, especially in G1, compared to the C. This increase might have been the result of the traumatic effect of TRP, developing peritonitis, stress and severe inflammation. In addition, the fact that the glutaraldehyde test indicates severe inflammation, the high total leukocyte counts and the observation of serious adhesions during the operation in G1 support this increase in haptoglobin. Ceruloplasmin is used less frequently for diagnostic purposes compared to other acute phase proteins. It protects cells against oxidative damage and has cytoprotective activity [15,37]. It is used in determining the presence of infection and inflammation [19]. In this study, serum ceruloplasmin level may have increased in cows with TRP to protect cells more as a result of peritonitis and severe inflammation. This may also be the case in our study as inflammation was more severe in G1 and the ceruloplasmin levels accordingly increased more in G1.

In conclusion, haptoglobin and ceruloplasmin levels were very high in G1, in whom adhesion was present, and calcium, magnesium, phosphorus and albumin levels were lower than the other groups. The evaluation of these parameters before the operation in cows diagnosed with TRP may provide important information in terms of the presence of adhesion, the severity of the inflammation, the chance of success of the operation and the diagnostic value. We think that these parameters will provide important information in the prognostic evaluation before rumenotomy in TRP.

AVAILABILITY OF DATA AND MATERIALS

The datasets analyzed during the current study are available from the corresponding author (E. Akyüz) on reasonable request.

ACKNOWLEDGMENT

Authors thank to Prof. Hidayet Metin Erdogan, Assoc. Prof. Oguz Merhan, Assoc. Prof. Mushap Kuru, Dr. Res. Asst. Mert Sezer, Res. Asst. Ugur Yildiz, Res. Asst. Yusuf Umut Bati, Res. Asst. Ersin Tanrıverdi and PhD Student Mehmet Turan for contribution to the study.

FUNDING SUPPORT

There is no funding source.

ETHICAL STATEMENT

This study was conducted by the approval of the Local Ethics Board for Animal Experiments of Kafkas University (Research Code: KAU-HADYEK- 2021/103), Kars, Türkiye.

CONFLICT OF INTEREST

The authors report no conflicts of interest. The authors alone are responsible for the content and writing of paper.

AUTHOR CONTRIBUTIONS

EA and UA conceived the study. EA and UA collected and analyzed data. EA performed laboratory analyzes and complete blood count procedure. UA performed the radiographic examination and rumenotomy operation. EA and UA have approved and read the final version of the manuscript.

REFERENCES

- Gökçe G, Özba B, Gökçe HI, Erdogan HM, Kırmızıgül AH, Güneş V, Atalan G: Sığırlarda retikulo-peritonitis travmatikinin teşhisinde tripsin inhibitör (TI) testinin kullanımı. *Kafkas Univ Vet Fak Derg*, 5 (1): 19-24, 1999.
- Ward JL, Ducharme NG: Traumatic reticuloperitonitis in dairy cattle. *J Am Vet Med Assoc*, 204 (6): 874-877, 1994.
- Bozukluhan K, Gökçe Hİ: Retikulo-peritonitis travmatika ve retikulo-perikarditis travmatikalı sığırlarda bazı akut faz proteinlerin araştırılması. *Erciyes Univ Vet Fak Derg*, 4 (2): 107-113, 2007.
- Braun U, Gerspach C, Ohlerth S, Warislohner S, Nuss K: Aetiology, diagnosis, treatment and outcome of traumatic reticuloperitonitis in cattle. *Vet J*, 255:105424, 2020. DOI: 10.1016/j.tvjl.2020.105424
- de Souza VL, Pinto AMSV, Queiroz CRR, de Castro MB, Borges JRJ, Soto-Blanco B, Camara ACL: Traumatic reticuloperitonitis combined with embolic pneumonia and hepatitis as unusual symptoms of foreign body syndrome in a Holstein bull. *Vet Med Sci*, 7, 136-140, 2021. DOI: 10.1002/vms3.341
- Gül Y: Retikulo-peritonitis travmatikinin tanı-ayırıcı tanı ve tedavisindeki son gelişmeler. *FÜ Sağ Bil Vet Derg*, 31 (1): 59-66, 2017.
- Roth L, King JM: Traumatic reticulitis in cattle: A review of 60 fatal cases. *J Vet Diagn Invest*, 3, 52-54, 1991. DOI: 10.1177/104063879100300111
- Radostits OM, Blood DC, Gay CC: Traumatic reticuloperitonitis. In, Radostits OM, Blood DC, Gay CC (Eds): *Veterinary Medicine: A Textbook of the Diseases of Cattle, Sheep, Pigs, Goats and Horses*. 8th ed., 278-284, WB Saunders, London, 1994.
- Kirbas A, Ozkanlar Y, Aktas MS, Ozkanlar S, Ulas N, Erol HS: Acute phase biomarkers for inflammatory response in dairy cows with traumatic reticuloperitonitis. *Isr J Vet Med*, 70 (2): 23-29, 2015.
- Akyüz E, Aydın U: Traumatic biochemistry and hematology in cattle with reticulo-peritonitis clinical causing complications in the lung-case series-oral presentation. *2nd International Cukurova Agriculture and Veterinary Congress*, 4-5 January, Adana - Türkiye, 2021.
- Şahal M, Güzel N, Kaya Ü, Bilgili H, Tanyel B: Retikulo-peritonitis travmatikalı süt ineklerinde pre- ve post operatif klinik ve biyokimyasal değişiklikler. *Ankara Univ Vet Fak Derg*, 40, 261-80, 1993. DOI: 10.1501/Vetfak_0000001495
- Roussel AJ, Whitney MS, Cole D: Interpreting a bovine serum chemistry profile: Part: 1. *Vet Med*, 92 (6): 553-558, 1997.
- Balıkçı E, Günay C: Retikulo-peritonitis travmatikalı sığırlarda rumenotomi öncesi ve sonrası bazı klinik, hematolojik, biyokimyasal ve elektrokardiyografik bulguların karşılaştırılması. *FÜ Sağ Bil Derg*, 18 (1): 13-19, 2004.
- Gökçe HI, Gökçe G, Cihan M: Alterations in coagulation profiles and biochemical and haematological parameters in cattle with traumatic reticuloperitonitis. *Vet Res Commun*, 31, 529-537, 2007. DOI: 10.1007/s11259-007-3527-1
- Erkılıç EE, Merhan O, Kırmızıgül AH, Ögün M, Akyüz E, Çitil M: Salivary and serum levels of serum amyloid a, haptoglobin, ceruloplasmin and albumin in neonatal calves with diarrhoea. *Kafkas Univ Vet Fak Derg*, 25 (4): 583-586, 2019. DOI: 10.9775/kvfd.2018.21424
- Merhan O, Özcan A: Peripartum dönemdeki koyunlarda seruloplazmin, haptoglobin, fibrinojen, albümin ve transferrin düzeylerinin araştırılması. *Erciyes Univ Vet Fak Derg*, 7 (1): 13-20, 2010.
- Kuru M, Merhan O, Kaya S, Oral H, Kükürt S: The effect of short term progesterone-releasing intravaginal device treatment on acute inflammation markers for Holstein heifers. *Revue Méd Vét*, 166 (11): 336-340, 2015.
- Merhan O, Bozukluhan K, Gökçe G, Yılmaz O: İshalli buzağılarda haptoglobin, seruloplazmin ve bazı biyokimyasal parametre düzeylerinin araştırılması. *FÜ Sağ Bil Vet Derg*, 30 (3): 195-198, 2016.
- Bozukluhan K, Merhan O, Büyük F, Çelebi Ö, Gökçe G: Brusellozislili sığırlarda bazı akut faz proteinlerin düzeyinin saptanması. *Ankara Univ Vet Fak Derg*, 63: 13-16, 2016. DOI: 10.1501/Vetfak_0000002703
- Kaya S, Merhan O, Kacar C, Colak A, Bozukluhan K: Determination of ceruloplasmin, some other acute phase proteins, and biochemical parameters in cows with endometritis. *Vet World*, 9 (10): 1056-1062, 2016. DOI: 10.14202/vetworld.2016.1056-1062
- Merhan O, Bozukluhan K, Kiziltepe S, Gökçe HI: Investigation of levels of haptoglobin, serum amyloid A, ceruloplasmin and albumin in cattle with foot-and-mouth disease. *Isr J Vet Med*, 72 (4): 14-17, 2017.
- Merhan O, Bozukluhan K, Gökçe HI: Acute phase proteins and biochemical and oxidative stress parameters in *Hypoderma spp.* infested cattle. *J Hell Vet Med Soc*, 68 (4): 535-540, 2017. DOI: 10.12681/jhvms.16049
- Yılmaz O, Gökçe G: Sığırlarda enfeksiyöz solunum sistemi hastalıkları kompleksinde (BRDC) klinik, hematoloji, biyokimya, oksidatif stres, akut faz proteinler üzerinde araştırmalar. *Atatürk Üniversitesi Vet Bil Derg*, 12 (1): 34-44, 2017. DOI: 10.17094/ataunivbd.309771
- Bayyit E, Merhan O: Normal ve güç doğum yapan ineklerde bazı akut faz proteinlerinin ve oksidatif stres düzeyinin belirlenmesi. *Atatürk Üniversitesi Vet Bil Derg*, 15 (2): 145-150, 2020. DOI: 10.17094/ataunivbd.688400
- Kırbaş A, Kaman R, Merhan O, Bozukluhan K, Değirmençay S, Eroğlu MS: Evaluation of acute phase response and oxidative damage in sheep naturally infected with *Streptococcus pluranimalium* using haptoglobin, nitric oxide, and malondialdehyde levels. *FÜ Sağ Bil Vet Derg*, 35 (3): 145-150, 2021.
- Bozukluhan K, Merhan O, Kiziltepe S, Egritağ HE, Akyüz E, Gökçe HI: Determination of haptoglobin, some biochemical and oxidative stress parameters in calves with pneumonia. *Fresenius Environ Bull*, 30 (7): 9492-9496, 2021.
- Skinner JG, Brown RA, Roberts L: Bovine haptoglobin response in clinically defined field conditions. *Vet Rec*, 128, 147-149, 1991. DOI: 10.1136/vr.128.7.147
- Colombo JP, Richterich R: On the determination of ceruloplasmin in plasma. *Schweiz Med Wochenschr*, 23, 715-720, 1964.
- Turgut K: Disproteinler ve testleri. In, Turgut K (Ed): *Veteriner Klinik Laboratuvar Teşhis*. 2th ed., 505-506, Bahçivanlar Yayınevi, Ankara, 2000.
- Samad A, Awaz KB, Sarkate LB: Diagnosis of bovine traumatic peritonitis I: Strength of clinical signs in predicting correct diagnosis. *J Appl Anim Res*, 6, 13-18, 1994. DOI: 10.1080/09712119.1994.9706019
- Aiello SE: Traumatic reticuloperitonitis, hemostatic disorders, haematologic reference ranges. In, Aiello SE (Ed): *The Veterinary Merck Manual*. 8th ed., 1-2305, Merck & Co, Pennsylvania, 1998.
- Gökçe G, Şendil Ç, Sural E: 1996 yılında Kafkas Üniversitesi Veteriner Fakültesi Kliniklerine getirilen hayvanların iç hastalıklarının istatistiksel değerlendirilmesi. *Kafkas Univ Vet Fak Derg*, 3, 181-186, 1996.

33. Akyüz E, Gökce G: Neopterin, procalcitonin, clinical biochemistry, and hematology in calves with neonatal sepsis. *Trop Anim Health Prod*, 53:354, 2021. DOI: 10.1007/s11250-021-02779-z

34. Talkhan OFA, Salama SEM, Kholy MME, Mosallam SA, Atwa EI: Bacterial agent of respiratory manifestation in cattle and associated biochemical alterations in Menoufea Governorate. *J Nat Sci*, 7 (9): 26-30, 2009.

35. Petersen HH, Nielsen JB, Heegard PMH: Application of acute phase

protein measurements in veterinary clinical chemistry. *Vet Res*, 35, 163-187, 2004. DOI: 10.1051/vetres:2004002

36. Akyüz E, Makav M, Kuru M, Bayram P: The effect of *Tarantula cubensis* extract on gentamicin-induced acute kidney injury in ovariectomized rats. *Kafkas Univ Vet Fak Derg*, 27 (5): 559-566, 2021. DOI: 10.9775/kvfd.2021.25390

37. Coşkun A, Şen İ: Sığırlarda akut faz proteinleri ve klinik kullanım alanları. *Sağlık Bil Derg*, 20 (3): 240-246, 2011.