

RESEARCH ARTICLE

Evaluation of Surgical Treatment Using PRF Membrane in Deep Corneal Ulcers Accompanied by a Descemetocoele in Cats: Retrospective Study (2019-2021)

Aynur DEMİR^{1,a(*)} Dilek OLGUN ERDİKMEN^{1,b} Yusuf ALTUNDAĞ^{1,c} Zeynep TOL SEVİM^{1,d}¹ Istanbul University-Cerrahpaşa, Faculty of Veterinary Medicine, Surgery Department, TR-34315 Istanbul - TÜRKİYE
ORCID: a0000-0002-5471-1655; b 0000-0000-4676-2019; c 0000-0001-6364-7512; d 0000-0002-5179-1098

Article ID: KVFD-2021-26738 Received: 01.11.2021 Accepted: 13.02.2022 Published Online: 16.02.2022

Abstract: In the present study, the results of the new generation platelet-rich fibrin (PRF) membrane graft application in deep corneal ulcers accompanying descemetocoele in cats in ocular surface reconstruction surgery were evaluated, and a retrospective non-comparative study covering the period between May 2019 and August 2021 was conducted. Patients underwent routine surgical procedures for corneal ulcers, and then a new-generation autologous PRF membrane graft was transplanted to the ulcer site. Nineteen eyes were analyzed (14 males, five females). Corneal integrity and vision were achieved in all cases after treatment. No signs of infection and inflammation were noted after membrane transplantation. The PRF membrane was transplanted to the defected area with sutures generating highly effective results in eliminating the defect's urgency, supporting the cornea, and accelerating the corneal healing. Corneal integration of the PRF membrane was successful in all cases without postoperative separation or stretching. In conclusion, the PRF membrane grafting was safely and effectively utilized in the surgical treatment of deep corneal ulcers in cats with a success rate of 89.4% in descemetocoele cases.

Keywords: Cat, Corneal ulcer, Descemetocoele, Graft, PRF membrane

Kedilerde Desmatoselin Eşlik Ettiği Derin Kornea Ülserlerinde PRF Membran Kullanılarak Cerrahi Tedavinin Değerlendirilmesi: Retrospektif Çalışma (2019- 2021)

Öz: Sunulan bu çalışmada kedilerde desmatoselin eşlik ettiği derin kornea ülserlerinde yeni nesil trombosit zengin fibrin (PRF) membran grefti uygulamasının oküler yüzey rekonstrüksiyonu cerrahisindeki sonuçları değerlendirildi ve Mayıs 2019 ile Ağustos 2021 arasında kapsayan retrospektif karşılaştırmalı olmayan bir çalışma yapıldı. Kornea ülseri olan hastalara rutin cerrahi prosedürlerin ardından ülser bölgesine yeni nesil otolog PRF membran grefti nakledildi. Çalışmada on dokuz göz değerlendirildi (14 erkek, beş dişi). Tedavi sonrası tüm olgularda korneanın bütünlüğü ve gözde görme sağlandı. 10. günden itibaren tüm kedilerde göz içi basıncı ölçümü yapıldı ve tonometre oküler tonus seviyelerini rahatlıkla belirledi. Membran transplantasyonundan sonra herhangi bir enfeksiyon veya yangı belirtisi tespit edilmedi. PRF membran dikişlerle kornea defekt bölgesine nakledildi ve kusurun aciliyetini ortadan kaldırma, korneayı destekleme ve korneal iyileşmeyi hızlandırmada etkili olduğu belirlendi. PRF membranının kornea entegrasyonu, postoperatif ayrılma veya gerilme olmaksızın tüm vakalarda başarılı olduğu görüldü. PRF membran greftinin uygulandığı bu serideki desmatoselli olgularda elde edilen %89.4 başarı oranı ile kedilerde derin kornea ülserlerinin cerrahi tedavisinin yönetiminde diğer kornea rekonstrüksiyon yöntemlerine benzer şekilde güvenli ve etkili olarak kullanıldığı bulundu.

Anahtar sözcükler: Kedi, Kornea ülseri, Desmatosel, Greft, PRF membran

INTRODUCTION

Deep corneal ulcers and descemetocoele are common disorders seen in companion animals^[1,2]. In feline practice, these conditions can result from trauma, bacterial or viral

(feline herpes virus) agents, tear film deficiency, decreased corneal sensitivity, inflammation, or foreign bodies^[3,4]. A descemetocoele refers to the anterior bulging of the Descemet membrane through a defect of overlying corneal stromal and epithelial layers^[5]. The Descemet membrane

How to cite this article?

Demir A, Olgun Erdikmen D, Altundağ Y, Tol Sevim Z: Evaluation of surgical treatment using PRF membrane in deep corneal ulcers accompanied by a descemetocoele in cats: Retrospective study (2019-2021). *Kafkas Univ Vet Fak Derg*, 28 (2): 217-227, 2022.
DOI: 10.9775/kvfd.2021.26738

(*) Corresponding Author

Tel: +90 212 473 70 70. Cellular phone: +90 506 755 0873 Fax: +90 2124737240
E-mail: aynur.demir@istanbul.edu.tr (A. Demir)



This article is licensed under a Creative Commons Attribution-NonCommercial 4.0 International License (CC BY-NC 4.0)

restrains the perforation of the eye. Thus, cases with a suspected descemetocoele should be handled with utmost care to avoid potential ocular perforation. Therefore, a descemetocoele is considered a surgical emergency [6]. There are various reconstructive surgical procedures, such as conjunctival grafts and flaps [3,7-9], kerato-plasty [6], and the use of biomaterials [2,10,11]. However, these techniques also present with a number of disadvantages [10,11].

Platelet-rich fibrin (PRF), a second-generation platelet concentrate, was developed for use in oral and maxillo-facial surgery [12-14]. It is an autologous fibrin membrane, containing platelet-derived growth factor (PDGF), vascular endothelial growth factor (VEGF), and transforming growth factor-beta (TGF- α), as thrombospondin-1, fibronectin, and vitronectin in its supporting three-dimensional fibrin structure. These growth factors and matrix proteins stimulate angiogenesis and tissue healing [15]. Besides, PRF provides mechanical support with the three-dimensional fibrin structure as a scaffold for the migrating cells [16].

The aim of this study was to evaluate the healing process of autologous PRF membrane on deep corneal ulcers associated with descemetocoeles in cats.

MATERIAL AND METHODS

Ethical Statement

This study carried out in cats was approved by the Animal Experiments Ethics Commission of Istanbul University-Cerrahpaşa, with the decision numbered 2021/35.

Animals

The study included 19 eyes of 19 cats with different etiologies, treated with PRF membrane graft biomaterial in Istanbul University-Cerrahpaşa, Faculty of Veterinary Medicine, Department of Surgery between May 2019 and August 2021. In the data analysis of each case, age, sex, affected eye, simultaneous ocular diseases, localization, diameter and vascularization of the descemetocoele, vision evaluation, corneal opacity, and graft were evaluated (Table 1).

Ophthalmologic Examination

All cats in this study underwent an ophthalmic examination, including a neuroophthalmological assessment, fluorescein test, Schirmer's tear test, intraocular pressure measurement, and fundus evaluation.

Preparation of PRF Membrane

In the preparation of the PRF membrane in cats, the procedures described for the preparation of the human PRF were modified and followed Can et al. [5]. Fifteen to 20 min before the surgery, 3 to 5 mL fresh blood was taken from the jugular vein of the sedated cats into two 10

mL anticoagulant-free tubes using butterfly needles (19-21 G) as quickly as possible. The tubes were centrifuged immediately at 2.700 rpm for 12 min using a Hettich 200 EBA model centrifuge. After centrifugation, three regions formed in the tube: platelet-weak plasma (PPP) at the top, platelet-rich fibrin in the middle, and red blood cells accumulated at the bottom. The resulting product was gently removed from the tube with the aid of forceps, and the red blood cells were removed using sterile scissors. The PRF clot was placed on a sterile gauze and left to release its serum (PRF-clot exudate). Each fibrin clot was gently compressed between sterile gauze pads by forced exudate extraction method to expel maximum fluid to form a membrane to be sutured to the corneal ulcer bed (Fig. 1-A), and the membrane was left within the gauze to sustain releasing of the serum until it was transferred to the corneal region. Two tubes of blood were collected from each patient, and two membranes of different sizes and thicknesses were prepared.

Preparation of Surgery

Premedication was performed with 0.5-1.0 mg/kg xylazine HCl, intravenous (IV) (Basilazin, Bavet, Turkey), analgesia with 0.1-0.2 mg/kg meloxicam subcutaneous (SC) (Melox, Nobel Limited, Turkey), and antibiotics with 25-30 mg/kg ceftriaxone (IV) (Novosef, Sanofi, Turkey). General anesthesia was induced with 5 mg/kg ketamine (IV) (Alfamine, Atafen, Turkey) and maintained with isoflurane 2.0-2.5% (Forane, Abbott, Italy) and 100% oxygen.

Surgery

All necrotic and collagenolytic tissues at the edge of the corneal ulcer where the PRF membrane would be placed were debrided using a blunt corneal scalpel, and the visualization of the healthy cornea at the edges of the ulcer was achieved for suture placement. One of the grafts was prepared to be 1-2 mm larger than the corneal defect, and the second was larger to cover the other graft. The first small and thick graft was placed in the corneal ulcer bed and sutured to the margin of the healthy cornea by four to five cardinal simple interrupted sutures with 8/0 polyglactin 910 (Vicryl, Ethicon); then, the thinner and larger second graft was sutured to the healthy cornea, completely covering the first graft filling the defect (Fig. 1-B). Utmost care was taken to avoid the formation of corneal perforation when sewing the graft to the healthy cornea on the descemetocoele edge of the membrane, especially for the first layer. A nictitating membrane flap (NMF) was placed using 2/0 polyglactin 910 (10 days effective) (Vicryl, Ethicon) to prevent the de-hydration of the PRF membrane and damage from eyelid movements and to provide mechanical protection against external factors.

Postoperative Management

Systemic meloxicam (Metacam, Boehrienger Ingelheim,

Table 1. The patient's signalment, etiology of descemetocele, summary of surgical and visual outcomes of the cats

No	Breed	Age	Sex	Eye	Lesion Localization	Size of Lesion (mm)	Vascularization	Associated Findings	Follow-up Period	Clinical Outcome	Comments
1	DSH	3 M	M	R	Paracentral	OD: 6-8	+++	Corneal vascularization and diffuse corneal edema	2 months	Visual	Mild, focal corneal fibrosis+ anterior synechia
2	DSH	4 M	M	L	Paracentral	OS: 8-11	++	Corneal vascularization and local edema	3 months	Visual	Severe focal corneal fibrosis and anterior synechia
3	DSH	3 M	M	R	Central	OS: 3-4	+	Diffuse corneal edema, vascularization	3 months	Visual	Moderate, focal corneal fibrosis and anterior synechia
4	DSH	4 M	M	R	Paracentral	OS: 5-6	++	Diffuse corneal edema and vascularization+ upper eyelid entropion	1.5 months	Visual	Mild corneal fibrosis
5	DSH	3 Y	M	R	Paracentral	OD: 6-7	++	Corneal edema and vascularization	3 months	Visual	Mild corneal fibrosis
6	DSH	3 M	M	R	Central	OD: 3-4	+	Perilimbal corneal vascularization, diffuse edema	2 months	Visual	Transparent
7	DSH	6 M	M	L	Paracentral	OS:2-4	++	Corneal edema, vascularization, granulation tissue	8 months	Visual	Transparent
8	DSH	3 M	M	L	Central	OS: 2-3	+	Perilimbal and corneal vascularization, diffuse edema	2 months	Visual	Mild corneal fibrosis
9	DLH	8 Y	M	R	Central	OD: 9-11	+++	Diffuse corneal edema, granulation tissue	2 months	Visual	Mild corneal fibrosis
10	DLH	5 Y	F	L	Central	OS:2-3	+	PPM, corneal edema, mild corneal vascularization	6 months	Visual	Moderate corneal fibrosis
11	DSH	2 Y	M	L	Central	OD: 3-5	++	Corneal edema and vascularization	1.5 months	Visual	Mild corneal fibrosis
12	DSH	3 M	M	R	Central	OD: 4-6	+	Diffuse corneal edema, and vascularization	1 month	Visual	Mild corneal fibrosis
13	DLH	6 M	M	R	Central	OD: 3-4	+	Focal corneal edema, vascularization	2 months	---	Mild corneal fibrosis
14	DSH	1.5 Y	F	R	Central	OD: 3-4	+	Focal corneal edema and vascularization	5 months	Visual	Transparent
15	DSH	6 M	M	L	Central	OS: 2-4	+++	Corneal edema and vascularization	2 months	Visual	Transparent
16	DSH	2 M	F	L	Central	OS: 3-4	+	Diffuse corneal edema and vascularization	2 months	Visual	Transparent
17	DLH	4 M	M	R	Central	OD: 4-5	+	Mild corneal vascularization and diffuse edema	1 month	Visual	Transparent
18	DSH	5 Y	F	L	Central	OS: 7-10	++	Adverse corneal vascularization, focal corneal edema	3 months	Visual	Adverse corneal fibrosis
19	DSH	3 M	F	L	Central	OS: 6-8	++	Mild corneal vascularization and edema	1 month	Visual	Mild corneal fibrosis

DSH: Domestic Shorthair, **DLH:** Domestic Longhair, **M:** Male, **F:** Female, **R:** Right, **L:** Left, **M:** Month, **Y:** Year

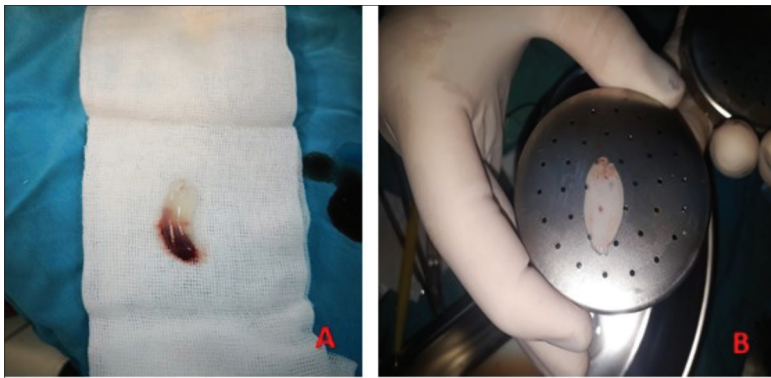


Fig 1. A- Clinical view of PRF clot and red blood cells accumulated at the bottom, B- The appearance of the PRF membrane after pressing between gauze

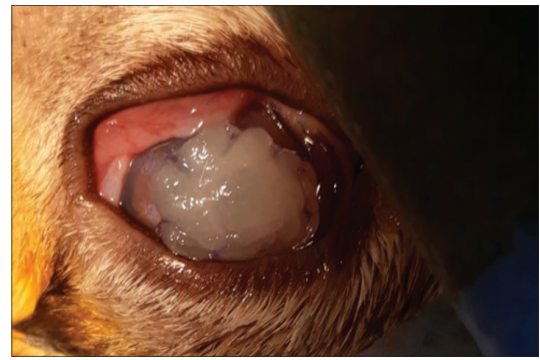


Fig 2. The PRF membrane graft immediately after surgery of the first case. The immobilization of the PRF membrane over the defective zone of the cornea with 8-absorbable suture

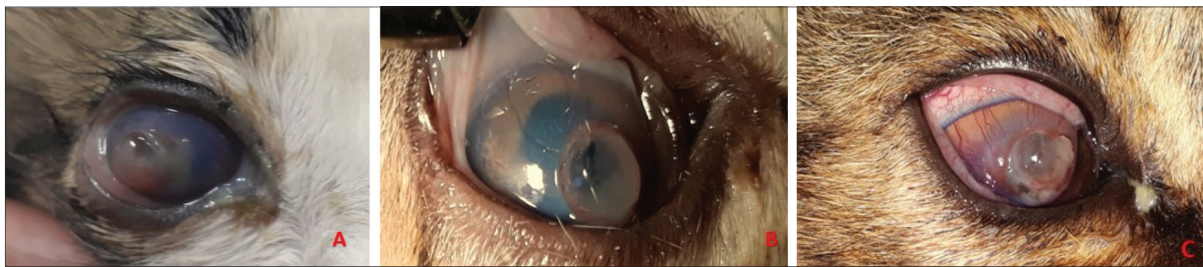


Fig 3. A- The initial ophthalmic examination (a) in case 1, B- Central desmatocoele in the third case of the right eye (a), C- Photo 5 of the case before the operation, desmatocoele and surrounding corneal vascularization

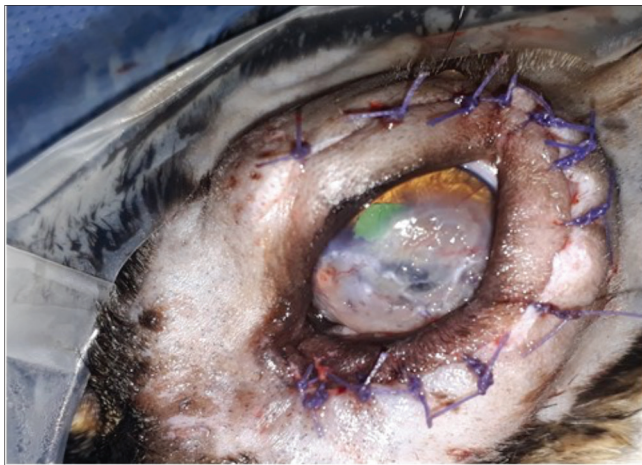

Fig 4. The left eye of case 2, 10 days post surgery, with corneal neo-vascularization and the remodeling of stroma. Correction of entropion with the modified Hotz-Celsus technique

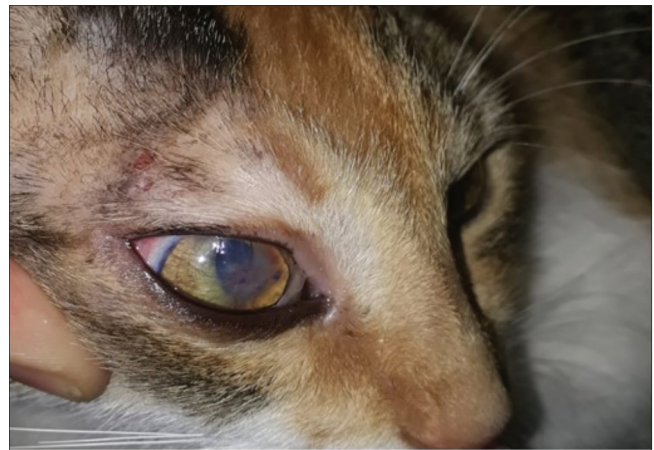

Fig 5. The surgical results 2 weeks postoperatively in case 14, moderate corneal neo-vascularization and fibrosis

Germany) at 0.1-0.2 mg/kg/day PO and ceftriaxone (Novosef, Sanofi, Turkey) at 20-25 mg/kg IM once daily was administered for five days. Topical ofloxacin (Exocin, Abdi Ibrahim, Turkey) and sodium hyaluronate (Eyestil, Sifi, Turkey) were applied hourly as one to two drops for the first three days, followed by five times a day for ten days. After the NMF sutures were removed, the drops were applied four times a day for two weeks. Topical artificial tear lubricant carbomer (Thilo tears, Alcon, Turkey) was applied three times a day for about three weeks to moisten

the ocular surface. Topical dexamethasone (Tobradex, Alcon, Turkey) was applied three times a day for 10 days, followed by two times for one week, and once a week; once the fibrin membrane dissolved, granulation tissue formed, and epithelialization was initiated. The topical lubricant gel was continued to be used twice a day for at least one more month.

Follow-up

NMF sutures were removed after 10 days in all cats. Ten and fourteen days after the operation, the changes in the

ocular surface, fibrin membrane, corneal vascularization, and granulation tissue were evaluated. Corneal transparency was scored on a scale of 1 to 4 (1: clear; 2: hazy; 3: moderate opacity; 4: severe opacity hampering inspection of the inner ocular structures from that site). The patients were followed up for about 8 months in terms of any recurrence, corneal perforation, increased opacity, loss of vision, and pigmentation in the ulcer region.

RESULTS

Animals

All the affected cats were of domestic shorthair breed: fourteen intact males (one castrated), two spayed, and three intact females. The mean age at treatment was 1.1 year (ranging from 3 months to 5 years).

The Findings of the Preoperative Ophthalmological Examination

The lesion was unilateral in all cats with deep corneal ulcers accompanied by a descemetocoele (n = 19) (Fig. 2; Fig. 3-A,B,C; Fig. 4; Fig. 5), affecting the right cornea in 10 cats, and the left cornea in nine. The width and time course of the corneal ulcer differed in each animal; therefore, the graft sizes varied from 2 to 11 mm. Bullous keratopathy was present in 6 of 19 eyes, accompanied by corneal vascularization, edema and keratomalacia (no: 1,4,5,6,15,20). There was simultaneous keratomalacia in 4

eyes (no: 7,11,12,17), and diffuse hyphema was also noted in the anterior chamber in a single case. Based on the visual evaluation results, only 7 eyes (no: 2,3,7,10,11,12,16) (7/19 eyes, 36.84%) showed a clear presence of visual function before surgery. The menace response was negative in 10 eyes (no: 1,6,8,9,13,14,15,17,18,19), (10/19 eyes, 52.63%), and the visual function was considered uncertain in a single case (1/23 eyes; 5.26%). The dazzle reflex and pupillary light reflex were indistinct in twelve affected eyes while present in the other healthy eye. Indirect ophthalmoscopic examination of the affected eyes was achieved merely three cases (no: 3, 7,16), revealing no fundus abnormalities (Table 2).

Short-Term Follow-Up: Up to 30 Days Postoperative Clinical Findings

All surgeries were performed without complications. The patients' pain, ocular discharge, and clinical complaints were determined to have decreased a few days after the operation. At the initial control visit 10 days after surgery, NMF was removed in all animal patients and no complications were observed. Vascular response to the corneal injury, edema, and epithelial proliferation, indicating an integrated cornea-PRF membrane, were prominent in all cases (Fig. 6). Marked superficial and deep peripheral corneal neovascularization were noted, extending to the graft edges. Corneal vascularization was

Table 2. Preoperative ophthalmological examination findings

Case No	Menace Response	Dazzle Reflex	Pupillary Light Reflex	Palpebral Reflex	Intraocular Pressure	Fluorescein Dye	Schirmer Tear Test	Fundus Evaluation
1	A	UN	UN	N	10	+	17	A
2	N	N	N	N	15	+	14	A
3	N	N	N	N	14	-	20	N
4	UN	UN	UN	N	12	+	15	A
5	A	UN	UN	N	16	+	16	A
6	A	UN	UN	N	A	+	12	A
7	N	N	N	N	17	+	22	N
8	A	UN	UN	N	12	+	18	A
9	A	UN	UN	N	16	-	16	A
10	N	N	N	N	12	+	18	A
11	N	N	N	N	18	+	24	A
12	N	N	N	N	16	+	22	A
13	A	UN	UN	N	A	+	14	A
14	A	UN	UN	N	8	-	15	A
15	A	UN	UN	N	7	-	18	A
16	N	N	N	N	10	-	16	N
17	A	UN	UN	N	8	+	18	A
18	A	UN	UN	N	12	-	20	A
19	A	UN	UN	N	18	-	15	A

A: Absent, N: Normal, P: Partial. UN: Uncertain

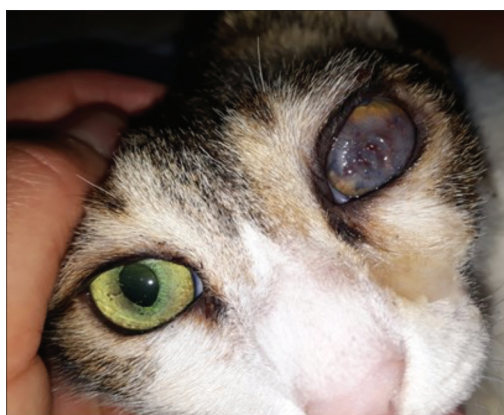


Fig 6. Anterior view of the left eye at 2 weeks after surgery

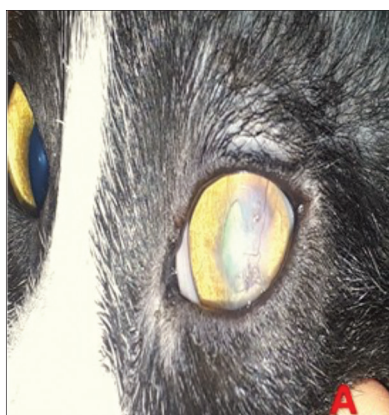


Fig 7. A- Appearance of the eye 3 weeks after surgery in case 15, B- Appearance 3 weeks after surgery in case 1

Table 3. Postoperative ophthalmological examination findings

Case No	Postoperative (2 weeks)								Postoperative (4 weeks)							
	MR	DR	PLR	PR	IP	FD	STT	FE	MR	DR	PLR	PR	IP	FD	STT	FE
1	N	N	N	N	11	+	14	A	N	N	N	N	13	-	16	N
2	N	N	N	N	14	+	15	A	N	N	N	N	16	-	18	P
3	N	N	N	N	12	-	17	N	N	N	N	N	17	-	18	N
4	N	N	N	N	11	-	15	A	N	N	N	N	18	-	16	N
5	UN	UN	UN	N	13	+	17	A	N	N	N	N	17	-	20	N
6	N	N	N	N	15	-	15	A	N	N	N	N	15	-	15	N
7	N	N	N	N	12	+	18	A	N	N	N	N	14	-	20	N
8	N	N	N	N	16	-	17	N	N	N	N	N	16	-	18	N
9	A	UN	UN	N	13	+	15	A	N	N	N	N	15	-	16	N
10	N	N	N	N	15	-	18	A	N	N	N	N	17	-	20	N
11	N	N	N	N	12	+	20	A	N	N	N	N	12	-	18	N
12	N	N	N	N	10	-	27	A	N	N	N	N	14	-	27	N
13	N	N	N	N	11	-	20	A	N	N	N	N	12	-	16	N
14	N	N	N	N	10	-	18	A	N	N	N	N	15	-	18	N
15	UN	UN	UN	N	11	+	15	A	N	N	N	N	14	-	20	N
16	N	N	N	N	12	-	18	N	N	N	N	N	12	-	15	N
17	A	UN	UN	N	14	+	20	A	N	N	N	N	15	-	17	N
18	A	UN	UN	N	11	+	17	A	A	A	A	N	14	-	20	P
19	A	UN	UN	N	12	+	16	A	N	N	N	N	16	-	18	N

A: Absent, N: Normal, P: Partial. UN: Uncertain, MR: Menace Response, DR: Dazzle Reflex, PLR: Pupillary Light Reflex, PR: Palpebral Reflex, IP: Intraocular Pressure, FD: Fluorescein Dye, STT: Schirmer Tear Test, FE: Fundus Evaluation

mild in three eyes, moderate in five eyes, and severe in eleven eyes. Fluorescein staining on the graft was positive in most of the cases (10/19 eyes, 52.63%). The epithelization was monitored to have started 10 days after the operation and continued until the 3rd week. The existing corneal edema around the cornea and the suture line was maintained until 21-30 days of the surgical procedure. The menace reflex and pupillary light reflex could not be precisely evaluated due to the corneal edema and

vascularization, particularly in the cases with central and large lesions (6/19 eyes, 31.57%), and fundus examination could not be performed (16/19 eyes, 84.21%).

An inflammatory reaction with superficial inflammatory granulomas around the sutures and the proliferation of the granulation tissue on the PRF membrane developed within the postoperative two weeks (Fig.7-A,B). Corneal edema and vascularization were still present yet decreased,



Fig 8. A- The appearance of the 5th case 1 month after the operation and mild corneal opacity, B- Three months postoperative view of the left eye of cat 3 showing moderate corneal scar, C- Note severely opaque cornea

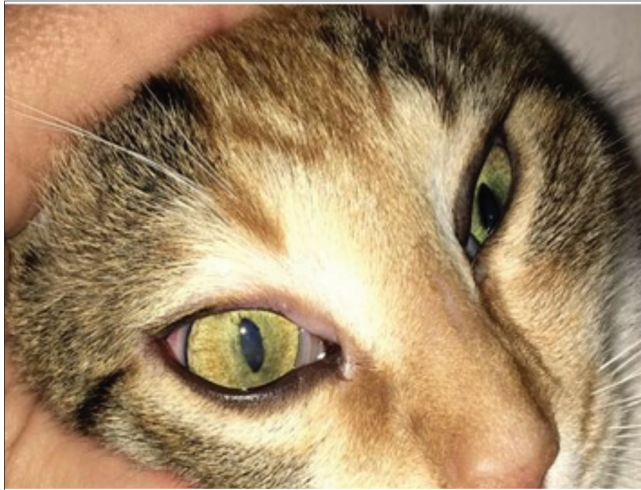

Fig 9. Ninety-days postoperative, appearance of the left eye

and fluorescein staining was negative except for ten cases which showed a minor epithelial defect on the graft. The menace response was present even though the PRF membrane trans-plantation site and surrounding corneas were edematous (13/19 eyes, 68.42%). Other ophthalmological examinations, apart from the fundus evaluation, could be performed, and the visual status of the patients, which could not be determined before the operation, could be more easily evaluated (*Table 3*).

The complete integration of the PRF membrane graft with re-epithelialization and moderate corneal neovascularization was present in all eyes three weeks after surgery (*Fig. 8-A,B,C; Fig. 9*). In the following weeks, the corneal cleaning phase was observed, in which epithelialization was completed in the cornea, and pre-existing corneal vascularization and granulation tissue began to be absorbed. Fluorescein staining negative in all cases. Corneal edema and vascularization next to the suture line decreased significantly and even completely disappeared in some cases. Fundus examination was successfully performed after the 3rd postoperative week in all cases, in which it failed to be performed, and preoperative vision could not be determined (17/19 eyes, 89.47%). The thinness of the wound site of the cornea increased significantly at 10, 14, 21 and 30 days postoperatively compared to pre-operatively.

Long-Term Follow-up: Up to 8 Months Postoperative Clinical Findings

At the 60th day-ophthalmic follow-up control, the morpho-anatomical outcome was favorable, and visual function was observed in all eyes; however, visual function status was relatively low in 2/19 eyes. Good cosmetic and visual results were provided in a very short time. Fundus was fully visible in 17/19 eyes, while fundoscopy could be partially performed in 2/19 eyes due to corneal opacity and anterior synechia sequelae (*Table 3*). The eyeball integrity was maintained, and eyeball loss was prevented in both cases. However, there was limited vision due to the extended central corneal opacity even after the postoperative medical treatment (as assessed by threat responses performed at various visual fields). The degree of corneal opacity was severe in two eyes (10.5%), moderate in another two eyes (10.5%), blurry in 8 eyes (42.1%), and there was complete transparency in six eyes (31.5%). No improvement was observed in the wound appearance of the patients during the postoperative 1-8 months. The success of in this study was defined as complete corneal repair and integrity (100%) and the presence of significant visual acuity at final re-assessment (89.4%). Corneal defects were repaired in all patients, and a good vision was achieved in seventeen (89.4%) of 19 patients.

DISCUSSION

Deep corneal ulcers associated with descemetocelles are noteworthy ocular diseases, with serious complications, such as sudden corneal perforation and eye loss requiring urgent intervention [6]. Aggressive treatment is required to minimize these complications, stop the progression of the lesion, which can be ruptured at any time, prevent the formation of corneal perforation, repair the thin cornea, and allow it to heal. Providing integrity and transparency for the cornea should be provided with surgical treatment [17]. Ideally, since many corneal ulcers affect the central or paracentral cornea, the surgical outcomes followed should be not only tectonic but also visual, and corneal opacities that may interfere with the patient's vision should be avoided [6,16]. In recent years, there has been growing interest in regenerative medicine, which aims to repair, replace and renew damaged tissues [18]. In the current study, we aimed to use and evaluate the PRF membrane, which

is accepted as a new method in humans, in veterinary ophthalmology as an alternative option with low biological risk and easy access to ocular surface reconstruction.

In our study, the PRF membrane, a new (second)-generation, autologous, thrombocyte concentrate developed by Choukroun et al.^[12] for jaw-facial surgery applications, repaired deep defects. This grafting method used in hard and soft tissue surgery was initially tested by Alio et al.^[18] in corneal perforation in humans and then by Can et al.^[5] in descemetocoele cases. The PRF membrane transplantation generated successful results in their use in human corneal reconstruction due to the membrane's anti-inflammatory properties and minimal scarring^[5]. In addition to the usual phenomena, the authors noted that the membrane could be obtained relatively quickly, was easy to apply, cost-effective, and provided good corneal integration^[5]. Its use in descemetocoele cases in humans led us to consider applying it to cats due to its roughly similar composition^[5]. The presented study aimed to confirm its usefulness in corneal reconstruction in felines considering other reconstruction techniques that have been confirmed for use in the treatment of deep ulcers in veterinary ophthalmology. In this study, autologous PRF membrane transplantation was performed in 19 eyes of 19 cats in the surgical treatment of descemetocoele-related deep corneal ulcers. Before the preparation of the graft, necrotic, infected corneal tissues required complete ablation. Ablation of these lesions was performed systematically to enable the graft's positioning and accelerate and facilitate the operation. The graft was larger in size than the diameter of the corneal defect, which provided a stable position in the defect and minimized the risk of tearing the biomaterial when suturing. The fibrin transformed into a membrane graft is Alio et al.^[18] and Can et al.^[5] planted on a healthy cornea as described.

The PRF membrane graft is effective in stabilizing a markedly worsening disease process. The membrane clinically formed by a clot is cheap, easy-to-use, and mechanically robust, and its elasticity facilitates and maintains the stability of the surgical suture application^[5]. These biomaterials, which are used as an alternative to bone grafts in humans as clot plugs in cavities, graft material at the implantation sites, and bone defects, can be sutured to the wound in the lesions with soft tissue deficiency, enabling increased tissue consistency. Based on the indication, three different surgical techniques can be used for PRF membrane transplantation: inlay, overlay, and combined^[5,19]. Shukla et al.^[20] compared the results of these three techniques in myringoplasty in humans and achieved higher success rates in the combined method. Tayşi et al.^[21] deduced that the double-layered PRF membrane is a better barrier to bone healing than the single-layer membrane, and the monolayer membrane does not provide sufficient

stabilization. In some recent reports in which this biomaterial was used for human corneal reconstruction, the PRF technology revealed biological properties similar to the amniotic membrane (AM), with its regenerative, anti-inflammatory, antifibrotic and anti-microbial properties. It has been stated that the PRF can be used as an inlay-graft, overlay-patch, or in the combined techniques like the AM application previously mentioned for descemetocoeles for similar conditions depending on the lesion's size and depth^[22]. In the inlay technique, the PRF membrane can be applied as a single or double layer. A single-layer graft can be placed without suturing with AM and therapeutic bandage contact lens (TBCL). In the multilayer membrane application, the thicker PRF membrane is placed directly onto the descemetocoele area to fill the stromal defect (similar to AM's inlay application). A thinner membrane is placed on top to cover the cornea (similar to AM's overlay application). Likewise, Sanchez-Avila et al.^[23] reported the usage of fibrin membrane alone in combination with membranes such as AM or Tutopatch, a collagen patch derived from the bovine pericardium. While investigating the effect of AM on corneal ulcers, which is reported to be structurally similar to the PRF membrane, Khokhar et al.^[24] suggested the use of multilayer AM for the treatment of deep corneal ulcers. Based on this, Can et al.^[5] applied the double-layer technique by placing a deliberately thicker PRF membrane filling the stromal ulcer, similar to the inlay-graft technique previously used for AM in the descemetocoele area, and placing the thinner membrane covering a particular corneal area on top of the first following the overlay-patch technique described for AM. In the present report, a single-layer sutureless PRF membrane graft (inlay graft) with TBCL was also applied in descemetocoele cases. The PRF membrane graft was conveniently placed as a filling in the descemetocoele area and served as a scaffold for the defect and epithelial cells. Alio et al.^[18] simultaneously used the PRF membrane and the clot. The patch's fibrin threads contribute to the defect's filling by binding to the clot and the stromal collagen fibers of the cornea. Ali et al.^[18] suggested that the combined use of autologous fibrin membrane and E-PRP clot is a safe and effective alternative for the repair of corneal perforations. In our study, we applied a thicker PRF graft adjusted to the size of the defect by the inlay technique within the borders of the ulcerated corneal area to support the descemetocoele and compensate for the stromal loss. Then, we utilized the onlay-patch technique by applying the thinner second layer on top to cover the ulcerated area and the graft and provide a scaffold for the epithelial cells, facilitating the underlying epithelium's healing. Applying a double layer PRF membrane was noted to have stabilized the course of the disorder in these lesions.

Kim et al.^[25] indicated that application of biomaterials such as AM, equine renal capsule, equine pericardium,

porcine small intestinal submucosa (PSIS), and porcine urinary bladder graft (UBM) targeted to sustain moisture, avoid dehydration, and provide structural support to scar tissue during nictitating membrane flapping in managing various corneal disorders such as deep corneal ulceration, corneal perforation, corneal sequestrum, and descemotecel. In addition, it has been reported that the combination of AM and NMF application accelerates healing in corneal reconstruction in dogs [16]. Chow and Westermeyer [11] reported that, like a contact lens applied in human patients, the NMF provides mechanical protection to the healing cornea against trauma and eyelid friction. An NMF was temporarily fixed to the upper eyelid for 15 days by Laguna et al. [26] to protect the frozen lamellar corneal graft from flashing movements and help maintain pressure on the graft surface; for 18 days to protect the UBM graft by Balland et al. [10]; for three weeks to prevent drying and shedding of the porcine SIS graft by Gouille [27]. Alio et al. [18] suggested a 7-day-long partial tarsorrhaphy instead of NMF followed by the PRF membrane application to restrict eyelid movements, enable wound healing, and stabilize the fibrin membrane and clotting adhered to the ocular surface, while Can et al. [5] preferred a 10-day-long TBCL application, supporting the PRF membrane to avoid corneal perforation. We performed a 10-day-long NMF fixation instead of applying contact lenses, followed by the double-layer PRF membrane technique. The NMF membrane applied to 19 eyes was removed to examine graft integration, corneal integrity, and corneal infection status after a follow-up of ten days. We showed that NMF application protected the PRF membrane and prevented dehydration. Complications such as premature loss of biomaterial, drying, and graft failure were experienced in none of the cases, and ten days were considered sufficient for the application period.

There are three crucial stages in the PRF membrane's integration into the cornea: corneal neovascularization and proliferation of epithelial and stromal tissue, producing corneal transparency and maintaining corneal integrity, and remodeling the extracellular matrix (ECM) [5,28]. Corneal neovascularization is a crucial phase of corneal healing and the first step of PRF in the corneal stroma. Providing nutrition for corneal cells in different pathological conditions is a reaction that occurs to support the healing process [19]. PRF membrane-induced corneal neovascularization and epithelization in human descemotecel cases are prominent within 10-14 days [11,18]. In our study, corneal vascularization was observed in all cases during the healing process, and it increased gradually from the tenth to the 14th postoperative day. Epithelialization was completed quickly within the same period as reported in previous studies [5,11]. Thus, the cornea regained its former transparent structure, and epithelization was generally completed by the third week.

This corneal neovascularization, which is part of the desired healing response, is almost always present at the time of corneal ulceration and is induced by surgery. Chow and Westermeyer [11] applied Acell Vet in corneal reconstruction in cats and dogs. After the graft was epithelialized or entirely vascularized, they used dexamethasone and cyclosporine topically for 2-3 months, until the desired improvement has been achieved, to stimulate regression of corneal vessels and reduce corneal fibrosis. Dulaurent et al. [29] used topical dexamethasone for dogs and topical indomethacin for cats for two weeks to minimize remaining corneal vessels once the epithelial barrier has been restored following a bovine pericardium graft application. Nevertheless, even if topical steroids maintain corneal clarity, they may cause other serious problems, as was recently reported in several Persian cats with corneal sequestra. Steroids can increase the lytic effect of corneal collagenase and are contraindicated in feline herpes virus infection [26]. They should be administered cautiously as suspensions to reduce corneal neovascularization, excessive granulation tissue, and scarring, except for cats suspected of a herpes virus infection. Gouille [27] suggests that topical dexamethasone should be administered with caution, usually for one to four weeks, depending on the intensity of scarring and corneal neovascularization. Thus, they administered dexamethasone initially once a day or every other day for about two weeks and then twice a day in some cases. However, cats treated with topical corticosteroids may be at risk of developing corneal ulcers due to reactivation of the latent herpes virus since up to 50% of asymptomatic cats have FHV1 DNA in the cornea [27]. Likewise, after the epithelialization of the PRF graft was completed, we administered topical steroidal drugs with care to reduce postoperative corneal vascularization, inflammation, formation of granulation tissue, and pain and to manage visual acuity, depending on the severity of corneal neovascularization and fibrosis. Unlike the previously reported data, no signs of infection were observed even in patients with suspected FHV-1. Likewise, no recurrence was noted during the follow-up period and steroid application.

Postoperative corneal clarity is achieved by the absence of blood vessels, pigmentation, and the regular arrangement of collagen fibrils in the stroma [30]. Serafini et al. [31] reported that type 3 collagen was synthesized at the lesion site during the normal stromal healing process, and this structure was relatively less regular, emerging as corneal scarring, potentially rendering visual impairment. The clinical reports indicate that the PRF membrane sutured to the corneal ulcer site provides corneal repair, similar to that obtained with conjunctival autografts, yet with fewer postoperative complications [5,18]. It was observed that the PRF membrane was completely dissolved, merging into the host cornea, and no permanent abnormal tissue islands

were noted, yet the corneal tissue was prone to scarring [32]. The results were reported to be quite successful in two different reports concerning the PRF membrane graft applications in corneal reconstruction in humans [5]. Our study revealed that epithelialization started on day ten and was completed in the third week. Satisfactory transparency with no recurrence was achieved in the lesion area, followed by the fibrovascular invasion of the membrane during the 3-month-follow-up period. Corneal edema was detected in almost all cats until the 21st or 25th to 30th days postoperatively, and then it started to fade. Corneal defects were repaired, corneal integrity and vision were restored in all 19 patients; however, the healing process was relatively limited in two patients. Compared to other surgical techniques recommended for descemetocoeles in cats in the literature, PRF can be considered among the techniques with a quite successful outcome (89.4%) [18]. Furthermore, none of the cases showed bacterial contamination after the PRF membrane application in our study.

We deduced that the PRF membrane graft is a reproducible, cost-effective eligible biomaterial compared to other corneal grafts rendering a rapid application, and it provides favorable morphoanatomical and visual outcomes with relatively less scarring in the patients. It has been very effective in the early migration of vessels to the ulcerated area, which is crucial in repairing severe stromal loss, such as descemetocoele, requiring urgent surgical treatment and thus accelerating healing. It provided good tectonic support during the healing process and eliminated the risk of perforation in ulcers in which the corneal tissue was significantly thinned.

In conclusion, the PRF membrane grafting successfully managed deep corneal ulcers in cats (89.4%), emerging as an excellent alternative to other corneal reconstruction methods that often cause severe corneal scarring and visual defects.

AVAILABILITY OF DATA AND MATERIALS

The authors declare that the data supporting the study findings were obtained from the corresponding author A. Demir).

ACKNOWLEDGEMENTS

The authors thank the surgical team for their assistance during the conduct of this study, both in the follow-up of anesthesia and in the collection of post-operative data.

FUNDING SUPPORT

There is no specific source of funding.

COMPETING INTERESTS

The authors declare no conflict of interest regarding this report.

AUTHOR CONTRIBUTIONS

AD and DOE made the design of the study. AD made the writing of the article, the treatment and controls, and the revision of the manuscript. YA and ZTS provided data collection, article writing, revision of the article draft, submission of the article and entry of subsequent revisions into the system.

REFERENCES

1. Lin CT: Surgical repair of deep corneal ulcer, descemetocoele, and perforation by conjunctival flap in dogs and cats. *Taiwan Vet J*, 28 (3): 168-174, 2002. DOI: 10.7009/TVJ.200209.0168
2. Ding ZY, Tan Y, Peng Q, Zuo J, Li N: Novel applications of platelet concentrates in tissue regeneration. *Exp Ther Med*, 21 (3): 226, 2021. DOI: 10.3892/etm.2021.9657
3. Martin de Bustamante MG, Good KL, Leonard BC, Hollingsworth SR, Edwards SG, Knickelbein KE, Cooper AE, Thomasy SM, Maggs DJ: Medical management of deep ulcerative keratitis in cats: 13 cases. *J Feline Med Surg*, 21 (4): 387-393, 2019. DOI: 10.1177/1098612X18770514
4. Rose L, Cheung R, Bunya V, Syed ZA: Management of Descemetocoele and Corneal Perforation. https://eyewiki.aao.org/Management_of_Descemetocoele_and_Corneal_Perforation; Accessed: 11.02.2021.
5. Can ME, Can GD, Cagil N, Cakmak HB, Sungu N: Urgent therapeutic grafting of platelet-rich fibrin membrane in descemetocoele. *Cornea*, 35 (9): 1245-1249, 2016. DOI: 10.1097/ICO.0000000000000917
6. Abreu WU, Philippsen C: Ceratoplastia com recobrimento de terceira pálpebra em felino doméstico para o tratamento de descemetocoele com perfuração de córnea. *Acta Sci Vet*, 45 (Suppl. 1): 205, 2017.
7. Scagliotti RH: Tarsconjunctival island graft for the treatment of deep corneal ulcers, desmetocoeles, and perforations in 35 dogs and 6 cats. *Semin Vet Med Surg Small Anim*, 3 (1): 69, 1988.
8. Sandmeyer LS, Bauer BS, Grahn BH: Diagnostic ophthalmology. *Can Vet J*, 57 (9): 995-997, 2016.
9. Dorbandt DM, Moore PA, Myrna KE: Outcome of conjunctival flap repair for corneal defects with and without an acellular submucosa implant in 73 canine eyes. *Vet Ophthalmol*, 18 (2): 116-122, 2015. DOI: 10.1111/vop.12193
10. Balland O, Poinard AS, Famose F, Goulle F, Isard PF, Mathieson I, Dulaurent T: Use of a porcine urinary bladder acellular matrix for corneal reconstruction in dogs and cats. *Vet Ophthalmol*, 19 (6): 454-463, 2016. DOI: 10.1111/vop.12326
11. Chow DWY, Westermeyer HD: Retrospective evaluation of corneal reconstruction using ACell Vet™ alone in dogs and cats: 82 cases. *Vet Ophthalmol*, 19 (5): 357-366, 2016. DOI: 10.1111/vop.12294
12. Choukroun J, Diss A, Simonpieri A, Girard MO, Schoeffler C, Dohan SL, Dohan JJ, Mouhyi J, Dohan DM: Platelet-rich fibrin (PRF): A second-generation platelet concentrate. Part IV: Clinical effects on tissue healing. *Oral Surg Oral Med Oral Pathol Oral Radiol Endod*, 101 (3): e56-e60, 2006. DOI: 10.1016/j.tripleo.2005.07.011
13. Dohan DM, Choukroun J, Diss A, Dohan SL, Dohan AJJ, Mouhyi J, Gogly B: Platelet-rich fibrin (PRF): A second-generation platelet concentrate. Part I: Technological concepts and evolution. *Oral Surg Oral Med Oral Pathol Oral Radiol Endod*, 101 (3): e37-e44, 2006. DOI: 10.1016/j.tripleo.2005.07.008
14. Dohan DM, Choukroun J, Diss A, Dohan SL, Dohan AJJ, Mouhyi J, Gogly B: Platelet-rich fibrin (PRF): A second-generation platelet concentrate. Part II: Platelet-related biologic features. *Oral Surg Oral Med Oral Pathol Oral Radiol Endod*, 101 (3): e45-e50, 2006. DOI: 10.1016/j.tripleo.2005.07.009
15. Dohan Ehrenfest DM, De Peppo GM, Doglioli P, Sammartino G: Slow release of growth factors and thrombospondin-1 in Choukroun's platelet-rich fibrin (PRF): A gold standard to achieve for all surgical platelet concentrates technologies. *Growth Factors*, 27 (1): 63-69, 2009. DOI: 10.1080/08977190802636713

16. **Costa D, Leiva M, Sanz F, Espejo V, Esteban J, Vergara J, Diaz C, Huguet E, Cairo M, Rios J, Peña MT:** A multicenter retrospective study on cryopreserved amniotic membrane transplantation for the treatment of complicated corneal ulcers in the dog. *Vet Ophthalmol*, 22 (5): 695-702, 2019. DOI: 10.1111/vop.12643
17. **Preeja C, Arun S:** Platelet-rich fibrin: Its role in periodontal regeneration. *SJODR*, 5 (2): 117-122, 2014. DOI: 10.1016/j.ksujds.2013.09.001
18. **Alio JL, Rodriguez AE, Martinez LM, Rio AL:** Autologous fibrin membrane combined with solid platelet-rich plasma in the management of perforated corneal ulcers: A pilot study. *JAMA Ophthalmol*, 131 (6): 745-751, 2013. DOI: 10.1001/jamaophthalmol.2013.2474
19. **Roffi A, Di Matteo B, Krishnakumar GS, Kon E, Filardo G:** Platelet-rich plasma for the treatment of bone defects: From pre-clinical rational to evidence in the clinical practice. A systematic review. *Int Orthop*, 41 (2): 221-237, 2017. DOI: 10.1007/S00264-016-3342-9
20. **Shukla A, Kaurav YS, Vatsyayan R:** Novel use of platelet rich fibrin membrane in transcanal myringoplasty: A prospective study. *Indian J Otolaryngol Head Neck Surg*, 72 (3): 355-362, 2020. DOI: 10.1007/S12070-020-01851-8
21. **Tayşi M, Atalay B, Çankaya B, Yıldırım S:** Effects of single-and double-layered resorbable membranes and platelet-rich fibrin on bone healing. *Clin Oral Investig*, 22 (4): 1689-1695, 2018. DOI: 10.1007/S00784-017-2259-Z
22. **Agarwal R, Nagpal R, Todi V, Sharma N:** Descemetocoele. *Surv Ophthalmology*, 66 (1): 2-19, 2021. DOI: 10.1016/j.survophthal.2020.10.004
23. **Sanchez-Avila RM, Merayo-Llones J, Riestra AC, Berisa S, Lisa C, Sánchez JA, Muruzabal F, Orive G, Anitua E:** Plasma rich in growth factors membrane as adjuvant treatment in the surgery of ocular surface disorders. *Medicine*, 97 (17):e0242, 2018. DOI: 10.1097/MD.0000000000010242
24. **Khokhar S, Natung T, Sony P, Sharma N, Agarwal N, Vajpayee RB:** Amniotic membrane transplantation in refractory neurotrophic corneal ulcers: A randomized, controlled clinical trial. *Cornea*, 24 (6): 654-660, 2005. DOI: 10.1097/01.icc.0000153102.19776.80
25. **Kim Y, Kang S, Nam S, Yun S, Seo K:** Surgical treatment of corneal sequestrum with porcine urinary bladder submucosa extracellular matrix (ACeLL Vet® Corneal Disc) in two cats. *J Vet Clin*, 37 (4): 213-216, 2020. DOI: 10.17555/jvc.2020.08.37.4.213
26. **Laguna F, Leiva M, Costa D, Lacerda R, Peña Gimenez T:** Corneal grafting for the treatment of feline corneal sequestrum: A retrospective study of 18 eyes (13 cats). *Vet Ophthalmol*, 18 (4): 291-296, 2015. DOI: 10.1111/vop.12228
27. **Gouille F:** Use of porcine small intestinal submucosa for corneal reconstruction in dogs and cats: 106 cases. *J Small Anim Pract*, 53 (1): 34-43, 2012. DOI: 10.1111/j.1748-5827.2011.01149.x
28. **Vanore M, Chahory S, Payen G, Clerc B:** Surgical repair of deep melting ulcers with porcine small intestinal submucosa (SIS) graft in dogs and cats. *Vet Ophthalmol*, 10 (2): 93-99, 2007. DOI: 10.1111/j.1463-5224.2007.00515.x
29. **Dulaurent T, Azoulay T, Gouille F, Dulaurent A, Mentek M, Peiffer RL, Isard PF:** Use of bovine pericardium (Tutopatch®) graft for surgical repair of deep melting corneal ulcers in dogs and corneal sequestra in cats. *Vet Ophthalmol*, 17 (2): 91-99, 2014. DOI: 10.1111/vop.12047
30. **Meek KM, Knupp C:** Corneal structure and transparency. *Prog Retin Eye Res*, 49, 1-16, 2015. DOI: 10.1016/j.preteyeres.2015.07.001
31. **Serafini G, Lopreiato M, Lollobrigida M, Lamazza L, Mazzucchi G, Fortunato L, Mariano A, d'Abusco AS, Fontana M, De Biase A:** Platelet rich fibrin (PRF) and its related products: Biomolecular characterization of the liquid fibrinogen. *J Clin Med*, 9 (4):1099, 2020. DOI: 10.3390/jcm9041099
32. **Can ME, Çakmak HB, Dereli Can G, Ünverdi H, Toklu Y, Hücemenoğlu S:** A novel technique for conjunctivoplasty in a rabbit model: Platelet-rich fibrin membrane grafting. *J Ophthalmol*, 2016:1965720, 2016. DOI: 10.1155/2016/1965720