

CASE REPORT

Biceps Tendon Rupture in Two Beetal Goats

Muhammad SHAHID ^{1,a (*)} Ahmad ALI ^{2,b} Yasir Razzaq KHAN ^{2,c} Omer NASEER ^{2,d}
Ameer Hamza RABBANI ^{1,e} Kashif HUSSAIN ^{2,f} Abdullah Saghir AHMAD ^{3,g}
Muhammad SAAD ^{4,h} Muhammad Luqman SOHAIL ^{2,i} Kashif PRINCE ^{2,j}

¹ Department of Surgery, Faculty of Veterinary Science, Cholistan University of Veterinary and Animal Sciences, 63100, Bahawalpur, PAKISTAN

² Department of Medicine, Faculty of Veterinary Science, Cholistan University of Veterinary and Animal Sciences, 63100 Bahawalpur, PAKISTAN

³ Department of Parasitology, Faculty of Veterinary Science, Cholistan University of Veterinary and Animal Sciences, 3100 Bahawalpur, PAKISTAN

⁴ Department of Theriogenology, Faculty of Veterinary Science, Cholistan University of Veterinary and Animal Sciences, 63100 Bahawalpur, PAKISTAN

ORCID: ^a 0000-0002-9443-8462; ^b 0000-0002-2639-606X; ^c 0000-0002-9031-0306; ^d 0000-0002-5388-4917; ^e 0000-0001-7105-7694

^f 0000-0002-0594-8023; ^g 0000-0002-8901-2280; ^h 0000-0002-7965-0986; ⁱ 0000-0001-8017-346X; ^j 0000-0003-3503-713X

Article ID: KVFD-2021-26483 Received: 02.09.2021 Accepted: 28.12.2021 Published Online: 01.01.2022

Abstract

Biceps tendon rupture is a rare condition that has been previously reported in athletic animals. In the present case study, biceps tendon rupture was diagnosed in two Beetal goats. Tendon rupture was indicated by performing a biceps test while diagnostic confirmation was achieved by arthrography and ultrasonography. Bicep tendon appeared hyperechoic but it was noted with disruption and swollen (slightly hypoechoic). Moreover, it was moderately in-homogenous fibrillar structure. While some parts of the tendon has normal echo structure. Tenotomy was performed to mitigate the aforementioned rupture. The follow-up of cases were done for six weeks after the surgery, whereby both goats demonstrated complete recovery. Despite the infrequency of biceps tendon rupture in pasture animals, analysis of diagnostic procedures and surgical stabilization was undertaken for its mitigation is imperative for the clinical understanding of the affection.

Keywords: Arthrography, Biceps tendon rupture, Tendon fixation, Caprine, Ultrasonography

İki Beetal Keçisinde Biceps Tendon Rupturu

Öz

Biceps tendon rupturu, daha önce atletik hayvanlarda bildirilen nadir bir durumdur. Bu vaka çalışmasında iki Beetal keçisinde biceps tendon rupturu teşhis edildi. Tendon rupturu biceps testi ile belirlendi ve artrografi ve ultrasonografi ile tanı doğrulandı. Biceps tendonu hiperekoik görünümdeydi ve kopma ve şişkinlik (hafif hipoekoik) dikkat çekiyordu. Ayrıca orta derecede homojen olmayan fibriller yapıdaydı. Tendonun bazı kısımları normal eko yapısına sahipti. Tendon rupturunu redükte etmek için tenotomi yapıldı. Ameliyattan sonra altı hafta boyunca olguların takibi yapıldı, bu sayede her iki keçide de tam iyileşme görüldü. Mera hayvanlarında biceps tendon rupturu nadir olmasına rağmen, hastalığın hafifletilmesi için gerçekleştirilen tanı prosedürleri ve cerrahi stabilizasyonun analizi, hastalığın klinik olarak anlaşılması için zorunludur.

Anahtar sözcükler: Artrografi, Biceps tendon rupturu, Tendon fiksasyonu, Keçi, Ultrasonografi

INTRODUCTION

Biceps tendon originates from the supraglenoid tubercle and passes distally at the cranio-medial side of the humeral head between the inter-tubercular grooves. Humerus glides

proximally and distally along the biceps tendon after flexion and extension of the shoulder joint. Shoulder joint instability as a consequence of biceps tendon rupture can cause grade 4 lameness. Moreover, any trauma to biceps tendon sheath rupture is frequently associated with

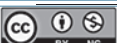How to cite this article?

Shahid M, Ali A, Khan YR, Naseer O, Rabbani AH, Hussain K, Ahmad AS, Saad M, Sohail ML, Prince K: Biceps tendon rupture in two Beetal goats. *Kafkas Univ Vet Fak Derg*, 28 (1): 149-153, 2022. DOI: 10.9775/kvfd.2021.26483

(*) Corresponding Author

Tel: +92 332 7877096

E-mail: mshahid@cuvas.edu.pk (M. Shahid)



This article is licensed under a Creative Commons Attribution-NonCommercial 4.0 International License (CC BY-NC 4.0)

rupture of biceps brachii tendon [1], bicipital tenosynovitis, avulsion fracture, partial or complete tendon tear, trans-humeral ligament rupture [2], and medial displacement of the tendon. Such cases have been well reported in dogs [1], cats [3], and humans [4]. However, literature is scarce about biceps tendon rupture (partial or complete) in goats. The aim of this report is to describe the diagnostic and surgical procedure for biceps tendon rupture encountered in two Beetal goats.

CASE HISTORY

CASE 1

A 3-year-old, female Beetal goat weighing 29 kg was presented to the Veterinary Teaching Hospital, Cholistan University of Veterinary and Animal Sciences, Bahawalpur with grade 4/5 right leg posture shown in (Fig. 1). Anamnesis revealed that the animal had been lame for



Fig 1. Beetal goat with non-weight bearing grade 4 lameness on the right forelegæ

the last three months following an unknown trauma. The goat was treated with non-steroidal anti-inflammatory drugs to relieve symptoms. Yet, severe lameness persisted. A general clinical examination was conducted. The patient was observed to be active and attentive. The capillary refill time was 1 second. Chest auscultation was normal (no crackles sound) and breathing rate was 25 breaths/min. The heart rate was 80 beats/min and no heart murmurs were noted. Rectal temperature was 38.4°C. Blood samples were collected from jugular vein in vacuum blood collection tubes. Blood was analyzed for hemato-biochemical parameters. Values for these parameters have been given in Table 1. Orthopedic examination revealed severe pain in the shoulder joint upon hyperextension, hyper-flexion, and palpation of shoulder joint on the medial side. Hyperflexion test for the biceps tendon was positive whereby the limb was observably straight instead of exhibiting a natural retro-curvatum (Fig. 2-A,B). Neurological examination showed no abnormalities. Radial and ulnar nerves were found with normal reflexes. Before contrast radiography, shoulder joint ultrasonography was performed to view different shoulder joint structures. Ultrasound examination showed partial rupture of the biceps tendon (Fig. 3-A). Medio-lateral radiographs of right and left shoulder joints were taken. Firstly, performed plain radiographic examination but we could not rule out without contrast radiograph. For that iohexol contrast radiographic media was used with dose rate 4 mL per animal. Positive contrast radiography of the right shoulder was done as well. Partial rupture of the biceps tendon was noted due to unequal percolation of contrast medium.

CASE 2

A 34 kg, 4-year-old female Beetal goat with a good body condition was presented to the Veterinary Teaching Hospital, Cholistan University of Veterinary and Animal Sciences,

Table 1. Values of Hematology and Blood Chemistry analysis of goat cases

Parameters		Case 1	Case 2	Reference Values
Hematology	Hemoglobin (Hb) (g/dL)	7.91	8.16	8.0-12.0
	Erythrocytes (RBC) ($\times 10^6/\mu\text{L}$)	13.2	14.6	8.0-18.0
	Total leucocytic count (TLC) ($\times 10^3/\mu\text{L}$)	11	12.5	4.0-13.0
	Packed cell volume (PCV) (%)	33.71	37.04	22.0-38.0
	Mean corpuscular Hb concentration (MCHC) (pg)	30.01	35.61	30.0-36.0
	Platelets ($/\mu\text{L}$)	271.5	275.09	300-600
	Mean corpuscular volume (MCV) (fL)	12.9	14.7	16.0-25.0
Blood Chemistry	Aspartate transaminase (AST) (IU/L)	92.6	97.33	66-230
	Alkaline phosphatase (ALP) (IU/L)	173.19	179.3	61-283
	Alanine transaminase (ALT) (IU/L)	40.16	45.21	15-52
	Gamma-glutamyl transferase (GGT) (IU/L)	42.94	46.12	20-50
	Albumin (ALB) (IU/L)	3.06	3.92	2.7-3.9
	Total bilirubin (mg/dL)	0.1	0.1	0.1-0.2
	Cholesterol (mg/dL)	77.86	111.46	65-136
	Urea Nitrogen (mg/dL)	17.83	18.7	13-28
Creatinine (mg/dL)	0.562	0.163	0.7-1.5	



Fig 2. Biceps test was performed on right (A) and left forelegs (B). An imaginary line was drawn from the head of the humerus to radius ulna and from radius ulna to carpal joint. The biceps tendon ruptured foreleg did not show any curve formation at the elbow joint (A) but there was clear curved formation at the elbow joint in healthy biceps tendon foreleg (B)

Fig 3. Longitudinal ultrasound scan of the medial aspect of the shoulder joint (A and B) demonstrating partial rupture of the biceps tendon. Disruption of normal fibrillar pattern is indicated by non-homogenous margins of tendon stump (arrows). The following structures were identified including hyperechoic line of scapula (SC), anechoic articular cartilage (AC), joint recess (R), hyperechoic humerus bone (HU) and supraspinatus muscle (M)

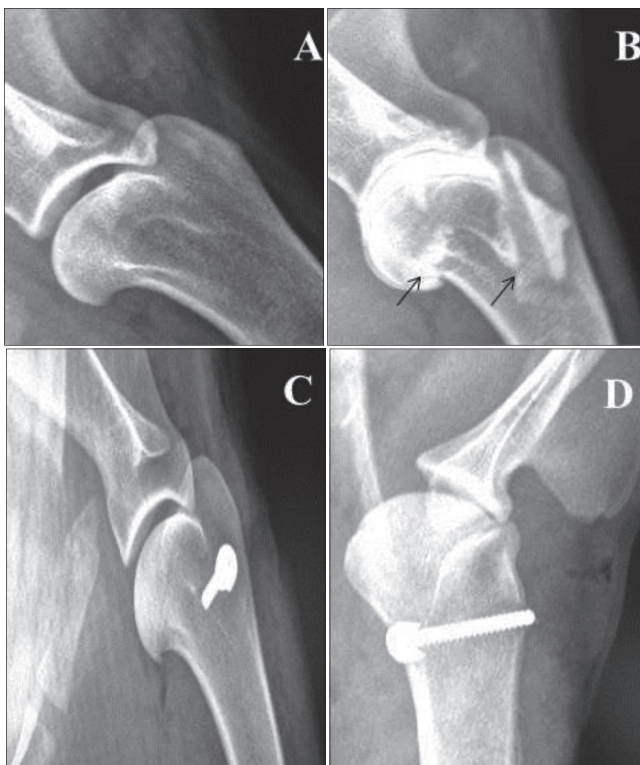
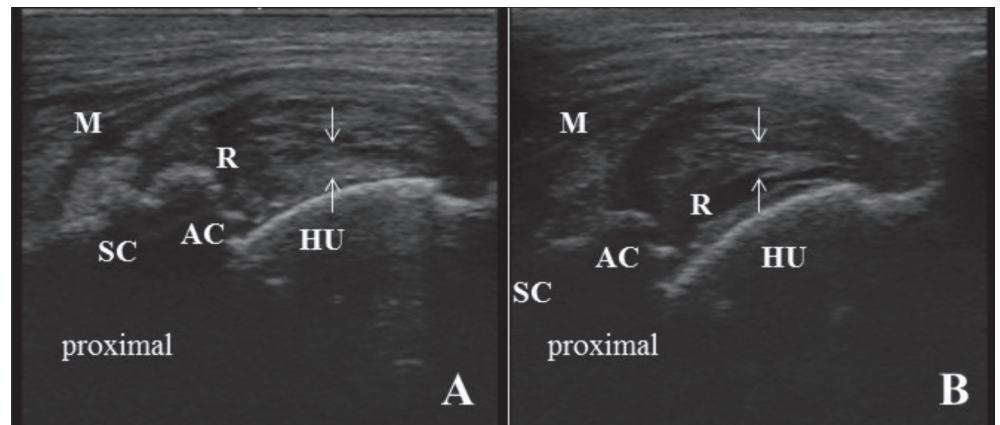


Fig 4. Medio-lateral positive contrast arthrography of the left shoulder joint (A) demonstrating moderate irregularity and insufficient filling of the biceps tendon sheath (arrows), Medio-lateral radiograph of the contra-lateral right shoulder joint demonstrating normal joint (B), Post-operative medio-lateral radiograph of the left foreleg showing nail position (C), Cranio-caudal radiographic view demonstrating nail length and position at humeral head after biceps tendon tenotomy (D)

Bahawalpur with severe left foreleg lameness (Grade 4/5). The goat had suffered severe trauma after a collision with another animal. Lameness could not subside, despite one week of analgesic therapy. Clinical exam was conducted whereby the patient was found to be active and attentive. Capillary refill time was less than 1 second. Chest auscultation was normal (no crackles sound) and breathing rate was 27 breaths/min. Heart rate was 76 beats/min and no heart murmurs were noted. Rectal temperature was 38.6°C. Venous blood sample analysis showed no abnormalities in complete blood cell count and blood chemistry (Table 1). Orthopedic examination demonstrated severe pain in the shoulder region when the limb was hyperextended or hyper-flexed. The hyper-flexion test was positive and straight leg was noticed instead of natural curvature in the limb. Neurological examination showed no abnormalities. Radial and ulnar nerve reflexes were normal. Before radiography, ultrasonography of the biceps tendon was performed and showed distorted structure of the tendon (Fig. 3-B). Mediolateral radiographs of the right and left shoulder joints were done. The left shoulder positive contrast radiograph was also done (Fig. 4-A). Rupture of the biceps tendon was noted due to unequal distribution of contrast medium.

Surgical Procedure

For both goats the day after admission, the patients were scheduled for surgical stabilization of the biceps tendon. Food was withdrawn for 24 h but water was allowed until 30 min before anaesthesia. Before anesthetic induction,

amoxycillin 15 mg/kg body weight (Injection Amoxycillin 500 mg by Yanzhou Xier Kangtai Pharma. Co., Ltd. China) was administered intravenously and ketoprofen 1.1 mg/kg body weight (Injection KetoJect 100 mg/mL by Selmore Pharma Pvt. Ltd. Pakistan) was injected intramuscularly. The goat was administered midazolam 0.2 mg/kg IV (Injection Midazolam 1 mg/mL by Akhai Pharma. Pakistan) as pre-anesthesia. After ten minutes, anesthesia was induced with ketamine hydrochloride B.P. 1 mg/kg IV (Injection Ketazol 100 mg/2 mL by Indus Pharma. Pakistan) and Propofol 1 mg/kg IV (Injection Propofol 10 mg/mL by Abbott Laboratories Pakistan) [5]. Once sedated, goat was positioned in sternal recumbency and intubated with an 8 mm internal diameter, cuffed endotracheal tube. After that, isoflurane 1-2 L/min (Isoflurane liquid 2% W/V by Akhai Pharma Pakistan) oxygen inhalation anesthesia was maintained. The concentration of isoflurane was maintained to achieve sufficient aesthetic depth after assessing ventro-medial positioning of eyeball and absence of blinking reflexes. Cardio-pulmonary system was regularly monitored. Throughout the surgical procedure, patient received an intravenous solution of 0.9% NaCl at 10-mL/kg/h (Unisol-NS^R UNISA Pharmaceutical Industry Limited Pakistan). Electrocardiogram lead II, respiration rate, pulse rate, oxygen concentration, and end-tidal partial pressure of carbon dioxide was monitored throughout the surgical procedure [6]. Normothermia was maintained by placing a heating pad underneath the patient.

After preparation, the patient underwent surgical stabilization of the biceps tendon. A tenotomy was performed to relieve strain on the shoulder joint after fixing the biceps tendon with the humeral head. Incision was made along the cranio-medial aspect of the shoulder joint over the greater tubercle. The incision was extended medially until it reached mid-humeral diaphysis. The fascia was incised at the lateral border of the brachiocephalic muscle. Superficial and deep pectoral muscles from the humerus were incised and retracted medially. While the supraspinatus muscle retraction was done laterally. Coracobrachialis muscle was resected to expose the subscapularis muscle tendon. After that, supra-scapularis muscle was incised as well. Furthermore, the transverse humeral ligament was incised to expose the biceps tendon. The joint capsule was nicked while the tendon was freed and moved medially. A bone screw and spiked washer were used with a boring machine to secure the biceps tendon with the humerus bone. The joint capsule and muscles were sutured with absorbable Poliglecaprone 25 monofilament (Monocryl Suture 2/0 Allumer Medical Pvt. Ltd. Pakistan) suture material. Skin was sutured with nNylon (Ethilon 2/0 Allumer Medical Pvt. Ltd. Pakistan) suture material. The suturing was performed in simple interrupted pattern.

After general anesthesia recovery, postoperative pain was evaluated by the gentle palpation of the surgical site. Though the goat did not show any sign of pain yet, the leg was flexed to assess normal shoulder joint curve

formation. There was a normal joint curve formation after surgery. The postoperative radiographs were captured to check nail position at the humeral head (Fig. 4-C,D) Anti-inflammatory treatment was administered with ketoprofen 1.1 mg/kg body weight (Injection KetoJect 100 mg/mL by Selmore Pharma Pvt. Ltd. Pakistan) intramuscularly in 24 h for 5 days. Amoxycillin 15 mg/kg body weight (Injection Amoxycillin 500 mg by Yanzhou Xier Kangtai Pharma. Co., Ltd. China) was injected IM 2 times a day for 7 days.

The next day normal diet plan was started; however, the movement of the patient was restricted for one week. The follow-up was carried out in both cases for 6 weeks. After 6 weeks, the goats showed normal walking and running patterns. No postoperative complications were recorded in both cases.

DISCUSSION

Biceps tendon rupture happens less frequently both in humans [4] and dogs [7]. The biceps tendon rupture either partial or complete was not reported before in the goat. Although, biceps brachii tendon and sheath rupture were reported in dogs [1,8]. Both of the cases here were reported in Beetal goats. Previously, prepubic tendon rupture was reported in Beetal goats [9]. Now, bicep tendon rupture is diagnosed in Beetal goats. In fact, Beetal goat is reared for meat purposes. It may be the reason of tendon rupture due to over body weight. Secondly, population of Beetal goats in Punjab is more as compared to other goat breeds.

The biceps test that is explained in German literature [10] was positive in both cases. Biceps test is very helpful to diagnose biceps tendon rupture. When the foreleg is flexed caudally by holding the carpal joint, there is a curve formation in normal joint. While in the ruptured case, there is no curve formation at the level of humerus bone, but it showed straight and upward leg movement. An imaginary line was sketched from shoulder joint to elbow joint and from elbow joint to carpal joint. A curved imaginary line formed in healthy joint while it was straight-line formation in biceps tendon ruptured case.

Previously, canine shoulder joint ultrasonography was considered less sensitive than arthroscopy. Research showed that ultrasonography with a 7.5 MHz linear transducer depicts a very good visualization of the biceps tendon and its related structures [11,12]. Here, ultrasonography of the biceps tendon with a 7.5 MHz linear transducer was performed in both goats. Longitudinal ultrasound images showed disruption of the normal fibrillar pattern. Previously, it was explained that pathological changes either of tendon sheath or tendon could be examined through ultrasonography. Ultrasonography, a best tool and technique, can diagnose tendon diseases including biceps tendon rupture (partial or complete), tendon luxation, tendo-vaginitis, corpora libera in tendon sheath [11,13]. Partial rupture of the biceps tendon was diagnosed in

seven dogs^[11]. In both goats, partial rupture of the biceps tendon was noticed at the region of the supraglenoid tubercle where the biceps tendon originates. Bicep tendon appeared hyperechoic but it was noted with disruption and swollen (slightly hypoechoic). Moreover, it was moderately in-homogenous fibrillar structure. While some parts of the tendon have normal echo structure. Those findings were concurrent with the previous study that was performed on dogs^[11].

Before and after surgery, radiographic images were captured. The positive contrast arthrography revealed the irregular contrast material margin at the anatomical site of the biceps tendon. After surgery, the position of bone screw was checked through radiographic image for its position and length. Contrary to plain radiography, contrast radiography has been considered the best additional technique to diagnose biceps tendon diseases. The most common finding after contrast radiography is the irregular distribution of contrast radiograph agents^[1,14]. Positive contrast agent showed irregular distribution at the side of the biceps tendon in goat's biceps tendon. But it should not be neglected that false-negative results are detected after arthrography^[14]. So, it's better to perform firstly biceps tendon test to confirm the diagnosis. Arthrography is less sensitive than ultrasonography to show the extent of tendon pathology^[15].

In conclusion, biceps tendon rupture is a rare condition that requires surgical intervention in goats. The best way to diagnose biceps tendon rupture is the biceps tendon test, ultrasonography and arthrography examination. Tenotomy of biceps tendon remains the best choice to address biceps tendon rupture also in goats.

STUDY LIMITATION

The absence of arthroscopy findings is a study limitation.

AVAILABILITY OF DATA AND MATERIALS

The authors declare that data supporting the study findings are also available to the corresponding author.

ETHICAL STATEMENT

This study was approved by the Ethical Review Committee Cholistan University of Veterinary and Animal Sciences, Bahawalpur.

CONFLICT OF INTEREST

There was no conflict of interest in regard to authors reporting their findings.

ACKNOWLEDGEMENT

The authors would like to thank and acknowledge the owners of animals.

FINANCIAL SUPPORT

This research did not receive any specific grants.

AUTHOR CONTRIBUTIONS

MS planned, designed, and supervised all procedure. Ultrasonography was done by MS and AA. X-ray was performed by MS and AHR. Hematology and blood chemistry analysis was performed by YRK and ON. Surgery was performed by MS, AA and AHR. Data was arranged by KH and ASA. X-ray and ultrasonographic images were evaluated by MS. For draft, images and tables were prepared by MS, MLS and KP. Original draft was written by MS. All authors have contributed to the revision and final proof-reading of the manuscript.

REFERENCES

- Innes JF, Brown G:** Rupture of the biceps brachii tendon sheath in two dogs. *J Small Anim Pract*, 45 (1): 25-28, 2004. DOI: 10.1111/j.1748-5827.2004.tb00191.x
- Jang HY, Lee BR, NamKung MH, Yoon HY, Han HJ, Kim JY, Jeong SW:** Surgical stabilization of traumatic medial luxation of scapulohumeral joint and scapular fracture in a dog. *J Vet Clin*, 26 (3): 276-278, 2009.
- Stokes R, Dycus D:** The shoulder joint and common abnormalities. *Vet Clin North Am Small Anim Pract*, 51 (2): 323-341, 2021. DOI: 10.1016/j.cvsm.2020.11.002
- Völk C, Siebenlist S, Kirchoff C, Biberthaler P, Buchholz A:** Rupture of the distal biceps tendon. *Unfallchirurg*, 122 (10): 799-811, 2019. DOI: 10.1007/s00113-019-00717-1
- Singh J, Singh S, Tyagi RPS:** Ruminant Surgery: A Textbook of the surgical Diseases of Cattle, Buffaloes, Camels, Sheep and Goats. 2nd ed., CBS Publishers, New Delhi, India, 2020.
- Nannarone S, Bellezza E, Moens YP, Menzies LP:** Vertebral subluxation repair in a pet goat. *Vet Surg*, 46 (1): 81-88, 2017. DOI: 10.1111/vsu.12586
- Longo UG, Forriol F, Candela V, Tecce SM, Salvatore SD, Altonaga JR, Wallace AL, Denaro V:** Arthroscopic tenotomy of the long head of the biceps tendon and section of the anterior joint capsule produce moderate osteoarthritic changes in an experimental sheep model. *Int J Environ Res Public Health*, 18 (14): 7471, 2021. DOI: 10.3390/ijerph18147471
- Wiemer P, van Ryssen B, Gielen I, Taeymans O, van Bree H:** Diagnostic findings in a lame-free dog with complete rupture of the biceps brachii tendon. *Vet Comp Orthop Traumatol*, 20 (1): 73-77, 2007. DOI: 10.1055/s-0037-1616592
- Aleem M, Ijaz A, Khan MIR:** Rupture of the prepubic tendon in a beetal goat. *Indian Vet J*, 87 (1): 63-64, 2010.
- Brunnberg L, Waibl H, Lehmann J:** Lahmheit beim Hund: untersuchen-erkennen-behandeln. Procane Claudio Brunnberg. 2014. <https://www.iberlibro.com/Lahmheit-Hund-Untersuchen-Erkennen-Behandeln-Brunnberg/30338937544/bd>, Accessed: 9/2/2021
- Kramer M, Gerwing M, Sheppard C, Schimke E:** Ultrasonography for the diagnosis of diseases of the tendon and tendon sheath of the biceps brachii muscle. *Vet Surg*, 30 (1): 64-71, 2001. DOI: 10.1053/jvet.2001.20336
- Kofler J:** Ultrasonography as a diagnostic aid in bovine musculoskeletal disorders. *Vet Clin North Am Food Anim Pract*, 25 (3): 687-731, 2009. DOI: 10.1016/j.cvfa.2009.07.011
- Piórek A, Adamiak Z:** Ultrasonography of the canine shoulder joint and its pathological changes. *Pol J Vet Sci*, 13 (1): 193-200, 2010.
- Barthez PY, Morgan JP:** Bicipital tenosynovitis in the dog - Evaluation with positive contrast arthrography. *Vet Radiol Ultrasound*, 34 (5): 325-330, 1993. DOI: 10.1111/j.1740-8261.1993.tb02013.x
- Rodríguez CG, López CGP, Del Olmo Hernández T, Marco SM, Edo OJ, Lafuente JLÁ:** Distal biceps tendon rupture: Diagnostic strength of ultrasonography and magnetic resonance. *Rev Esp Cir Ortop Traumatol (Engl Ed)*, 64 (2): 77-82, 2020. DOI: 10.1016/j.recot.2019.11.004