

## CASE REPORT

# Subcutaneous Cavernous Cervicofacial Lymphangioma and It's Surgical Treatment in a Calf

Yesari ERÖKSÜZ <sup>1,a</sup> (\*) Emine ÜNSALDI <sup>2,b</sup> Murat TANRISEVER <sup>2,c</sup>  
Canan AKDENİZ İNCİLİ <sup>1,d</sup> Hatice ERÖKSÜZ <sup>1,e</sup>

<sup>1</sup> Department of Pathology, Faculty of Veterinary Medicine, Firat University, TR-23119 Elazığ - TURKEY

<sup>2</sup> Department of Surgery, Faculty of Veterinary Medicine, Firat University, TR-23119 Elazığ - TURKEY

ORCID: <sup>a</sup> 0000-0001-5962-8810; <sup>b</sup> 0000-0003-1320-0709; <sup>c</sup> 0000-0003-3815-8543; <sup>d</sup> 0000-0003-1893-7531; <sup>e</sup> 0000-0002-8407-5792

Article ID: KVFD-2021-26330 Received: 26.07.2021 Accepted: 04.11.2021 Published Online: 04.11.2021

## Abstract

A 20-day-old, Simmental male calf showed a subcutan mass locating left side of chin, buccal and neck regions. The mass covering the 70% of left side of the face consisted of cystic structures under the skin. It was surgically excised and no recurrence occurred three months after the excision. The cut surfaces of mass were measured by 20×15×8 cm in size. Histologically, the mass was diagnosed as cavernous lymphangioma which composed of thin-walled cystically dilated spaces which were lined with one or rarely more layers of flat endothelial cells. Mitotic figures were not present. The channels did not contain red blood cells in contrast to, endothelial cells lining adjacent blood vessels. The endothelial cells of cystic dilated spaces gave positive cytoplasmic immunoreaction for podoplanin. In conclusion, this report presents clinical, pathological, immunohistochemical features and surgical treatment of cervicofacial lymphangioma in a calf.

**Keywords:** Bovine, Calf, Lymphangioma, Pathology, Immunohistochemistry, Surgical treatment

## Bir Buzağıda Subkutan Kavernöz Servikofasiyal Lenfangiom ve Cerrahi Tedavisi

### Öz

Yirmi günlük Simental erkek bir buzağının çene, yanak ve boyun bölgesinin sol tarafında düzensiz şekilli bir kitle mevcut olup, yüzün %70'ini kaplayan kitle, cilt altında kistik yapılardan oluşuyordu. Cerrahi olarak eksize edilen kitlenin postoperatif olarak üç ay sonrasında nüks etmediği saptandı. Kitlenin kesit yüzeyi 20×15×8 cm boyutlarında ölçüldü. Histolojik olarak kitleye bir veya nadiren daha fazla düz endotelial hücre tabakasıyla döşeli olduğu, ince duvarlı, kistik genişlemiş boşluklardan oluştuğu saptandı ve kavernöz lenfangiom tanısı konuldu. Mitotik figürler mevcut değildi. Kanallar, bitişik kan damarlarını kaplayan endotel hücrelerinin aksine eritrositleri içermiyordu. Kistik boşlukları döşeyen endotel hücreleri podoplaninle pozitif sitoplazmik immünoreaksiyon gösterdi. Sonuç olarak, bu raporda bir buzağıda servikofasiyal lenfangiomaun klinik, patolojik, immünohistokimyasal özellikleri ve cerrahi tedavisi sunulmaktadır.

**Anahtar sözcükler:** Sığır, Buzağı, Lenfangjom, Patoloji, İmmünohistokimya, Cerrahi tedavi

## INTRODUCTION

Lymphangiomas are rare benign congenital cystic lesions originating from the lymphatics. In human pathology, it is enigmatic whether these cysts are hamartomas or tumors of lymphatic system <sup>[1]</sup>. However, World Health Organization favors this lesion in animals as a congenital malformation (hamartoma) which appears most commonly in newborn animals <sup>[2]</sup>. Few authors stressed that controversy of this

dilemma is impractical because of the benign nature of the lesion <sup>[1]</sup>. Four theories are supposed to elucidate the origin of lymphangioma. The first one suggested the failure of the connection between lymphatic system-venous system, the second theory directed attention to abnormal budding from the vein to form lymphatics, the third one is the lymphatic obstructions caused by trauma, infections, and chronic inflammations <sup>[1]</sup>, the last theory is that lymphangiomas originate from single lymphatic

### How to cite this article?

**Eröksüz Y, Ünsaldı E, Tanrısever M, Akdeniz İncili C, Eröksüz H:** Subcutaneous cavernous cervicofacial lymphangioma and it's surgical treatment in a calf. *Kafkas Univ Vet Fak Derg*, 27 (6): 811-814, 2021.  
DOI: 10.9775/kvfd.2021.26330

### (\*) Corresponding Author

Tel: +90 424 237 0000-4045 Fax: +90 424 238 8173

E-mail: [yeroksuz@firat.edu.tr](mailto:yeroksuz@firat.edu.tr) (Y. Eröksüz)



This article is licensed under a Creative Commons Attribution-NonCommercial 4.0 International License (CC BY-NC 4.0)

with a neoplastic proliferative behavior [3]. Based on the depth and the size of these abnormal lymph vessels, the lymphangiomas are classified into three subtypes including microcystic (capillary lymphangiomas), macrocystic (cavernous lymphangiomas) and cystic hygromas [1]. The cavernous or macrocystic form occurs on surfaces of the body where the lesion can expand freely such as the areas containing loose connective tissue and the anatomical areas where do not pressure on the cyst [4].

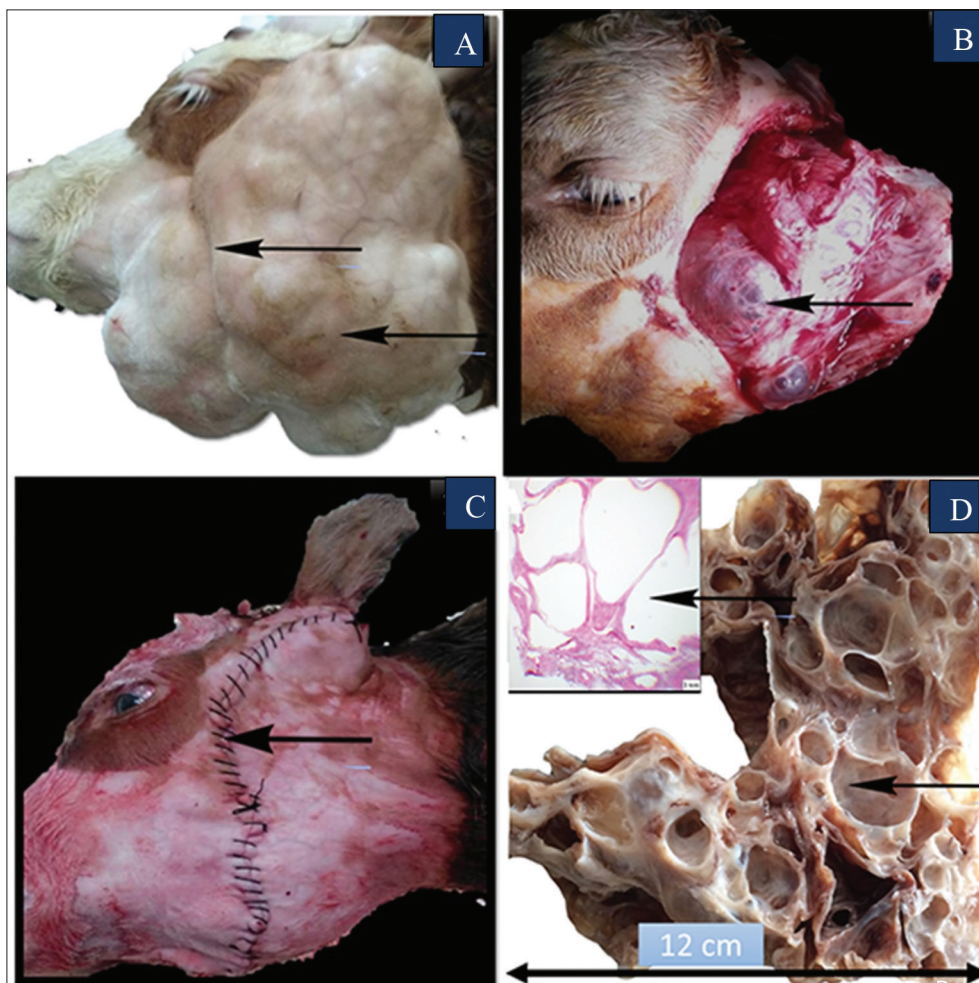
Incidence rate of lymphangioma in man is 1.2-2.8 per 100.000, and more than 50% and 90% are diagnosed at birth and 2-year-old children, respectively [4]. However, in animal species, this malformation is substantially less evaluated with reference to incidence, morphological features and treatment [5-9].

The aim of this report is to emphasize the infrequency of lymphangioma in cattle and to characterize the clinical, pathological and immunohistochemical findings in subcutaneous lymphangioma in head and neck in a calf.

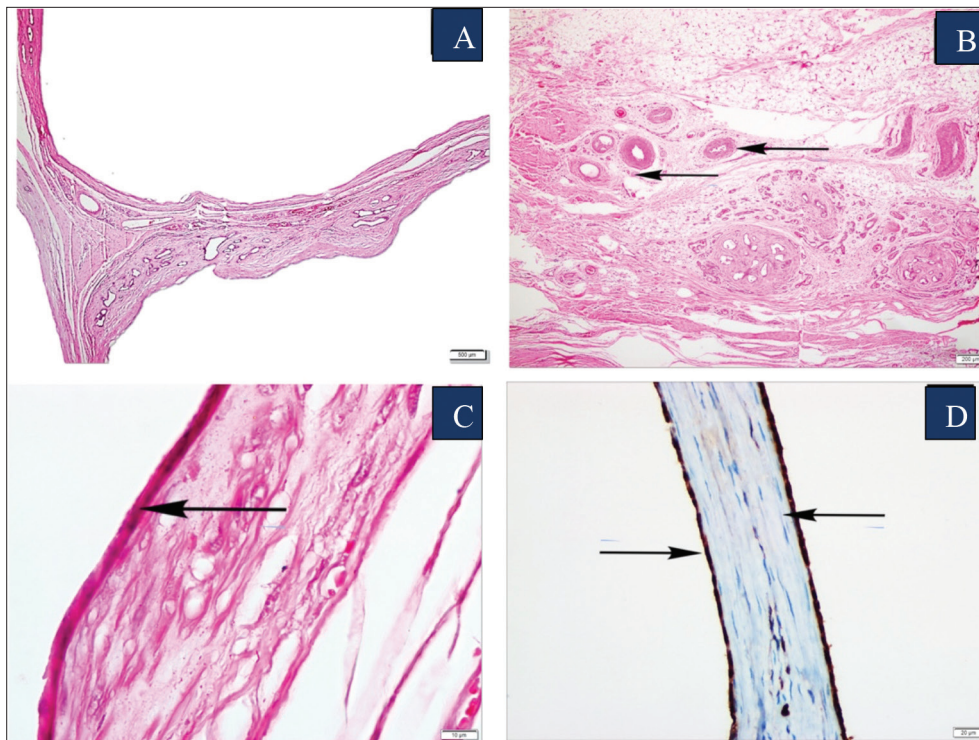
## CASE HISTORY

A 10-day-old Simmental male calf was referred to our clinic with an irregular swelling beneath the skin of left chin, buccal and neck regions (Fig. 1-A). According to the history, the mass was present at birth, however it increased in size gradually over the past 20 days and caused the distortion. The main clinical signs were difficulty in breathing and sucking due to the mass lesion. Clinical examination did not show any abnormality in the organ system. Covering the face of 70% of the left side of, the mass consisted of vesicular structures under the skin (Fig. 1-B). It was spongy like in appearance and elevated in 15 cm with no peduncle. The cut surfaces had lobular structure measured 20×15×8 cm in size. The owner of the calf was informed about the surgical procedures to be performed and an informed consent letter was signed by the owner.

To excise totally the mass, the calf was sedated by intramuscular solution of xylazine hydrochloride (Rompun, Bayer,



**Fig 1.** A: Grossly, the limits of tumor started under the ear in the left facial region and extended downwards from the edge of the mandible and extended back to the neck area covering approximately 70% of the left face, the tumor contained blisters (arrows) on the outer surface, B: Intraoperative gross appearance of tumor containing vesicular cystic spaces (arrow), C: Postoperatively, the calf with the surgical sutures in operation line (arrow), D: Subgross (inset) and gross appearance of empty cystic spaces (arrows) thin interstitial tissue



**Fig 2. A:** Histologically, the mass composed of dilated empty lymphatic spaces, (H&E), **B:** Stromal tissue containing vascular structures, fibrous connective tissue and subcutaneous fat tissue, (H&E), **C:** Single layer of flat endothelial cells lined the lymphatic channels (arrow), (H&E), **D:** Positive staining of endothelial cells with podoplanin (arrows)

Turkey) in the dose of 0.1 mg/kg and operated under local anesthesia with lidocaine HCl (Vilcain, Vilsan, Turkey). Under aseptic conditions, it was exposed through medial incision and totally extirpated by passing the skin and subcutaneous connective tissue (Fig. 1-B). After the total extirpation, the skin was closed with simple sutures (Fig. 1-C). Although the mass was not encapsulated and attached the underlying tissue, special attention was taken to completely clean the mass from the subcutaneous tissues and not to leave any residual tissue mass behind. No involvement in trachea and esophagus was present.

Postoperatively, intramuscular procaine penicillin G + dihydrostreptomycin (Sanovel, Turkey) was administered in the dose of 3 mL/100 kg/day for 7 days and sub-cutaneous analgesic/anti-inflammatory meloxicam (Meloxicam, Bavet, Turkey) in the dose of 0.2 mg/kg/day. The operation line was cleaned with antiseptic solution (0.1% lugol solution) for 1 week. In phone interviews with the owner, no local recurrence was observed within 3 months postoperatively.

### Gross Findings

Macroscopically; the mass composed of multiple cystic-cavernous spaces measuring 1 to 5 cm (Fig. 1-D). These vesicles contain serous fluid and look like frog eggs.

### Histopathological and Immunohistochemical Studies

Tissue samples were fixed in a 10% solution of phosphate-

buffered formalin before being routinely processed and stained with hematoxylin and eosin (H&E) for light microscopic examination. Selected sections were stained with Masson's trichrome stain and immuno-histochemical stain for podoplanin, desmin and smooth muscle actin. Immuno-histochemical staining was performed using Ventana NexES system.

The mass was sharply circumscribed, but not encapsulated. It composed of thin-walled cystically dilated spaces (Fig. 2-A). They were lined with one or rarely more layers of flat endothelial cells which were elongated or flat in appearance. Their cytoplasm contained elongate to irregular hyperchromatic nuclei and had scant, pale basophilic cytoplasm. The cell borders were indistinct showing minimal anisocytosis and anisokaryosis. Mitotic figures were not present. Moderate number of lymphocytes and plasma cells often form small discrete aggregates around blood vessels. Scant interstitial tissue contained blood vessels, connective tissue, muscular arteries and focal lymphocytic infiltrates (Fig. 2-B). The endothelial cells of cystic spaces were elongated or flat in appearance (Fig. 2-C), and they gave positive cytoplasmic immunoreaction for podoplanin (Fig. 2-D). The channels did not contain red blood cells in contrast to endothelial cells lining adjacent blood vessels.

### DISCUSSION

This report highlights the clinical, pathological and immuno-



histochemical findings of cervicofacial lymphangioma in a calf. This lesion may occur anywhere on the skin, subcutaneous tissue or mucous membranes <sup>[1]</sup>. Cervicofacial lymphangioma is most commonly reported in children (70% to 80%). At this anatomic site; primordial lymphatics or also known as the lymph sacs are formed embryologically <sup>[1,4]</sup>. Therefore, the development of lymphangiomas is closely related to the genesis of lymph vessels <sup>[1]</sup>.

Differential list for lymphangiomas includes lymphangiomatosis, lymphangiosarcoma, branchial cleft cyst, thyroglossal duct cyst, tumors of salivary gland, hematoma, carotid body tumors, actinobacillosis, actinomycosis, soft tissue sarcomas and thyroid masses <sup>[1,5]</sup>.

A number of treatment alternative methods in humans includes surgical excision, sclerotherapy, electrocoagulation, liquid nitrogen therapy and carbon dioxide laser therapy. The recurrence of lymphangioma in man is at the rate of 10-15% unless completely excised surgically <sup>[10]</sup>. As the large volume of the mass is considered, the methods other than the surgical option was not feasible in the present case. In human medicine, various substances, such as sodium morrhuate, dextrose, tetracycline, doxycycline, ethanol, bleomycin, ethibloc and OK-432 were used as sclerotherapeutic agents. Apart from OK-432, the other agents cause perilesional fibrosis and complicate surgical excision. Doxycycline can cause neural damage and, OK-432 may be associated with sepsis, shock, myalgia, and bleomycin might be cause of pulmonary fibrosis. Ethanol is an effective sclerosant, however might cause a series of complications including the pain and nerve injury <sup>[4]</sup>. Although the operation was problematical in regard to large volume and anatomical location, the calf was delivered to the owner without complication.

In conclusion, this report presents clinical, pathological, immunohistochemical features and surgical treatment of cervicofacial lymphangioma in a calf. Lymphangioma might also be added to the differential diagnosis list for cystic lesions in the head and neck region in cattle.

#### AVAILABILITY OF DATA AND MATERIALS

The datasets during and/or analyzed during the current study available from the corresponding author on reasonable request.

#### FUNDING SUPPORT

None

#### COMPETING INTERESTS

Authors declared that there is no conflict of interest in this study

#### AUTHORS' CONTRIBUTIONS

Conceptualization, Y.E. and H.E.; methodology, E.Ü., M.T., and C.A.İ.; writing-original draft preparation, Y.E., H.E., and C.A.İ.; writing, review and editing, Y.E. and H.E.

#### REFERENCES

1. **Wiegand S, Eivazi B, Barth PJ, Rautenfeld DB, Folz BJ, Mandic R, Werner JA:** Pathogenesis of lymphangiomas. *Virchows Arch*, 453, 1-8, 2008. DOI: 10.1007/s00428-008-0611-z
2. **Hendrick MJ, Mahaffery EA, Moore FM, Vos JH, Walder EJ:** Histological Classification of Mesenchymal Tumors of Skin and Soft Tissues of Domestic Animals. 2<sup>nd</sup> ed., 22-25, Washington D.C. Armed Forces Institute of Pathology, American Registry of Pathology, 1998.
3. **Colangeli W, Facchini V, Kapitonov A, Zappalà M, Bozza F, Becelli R:** Cystic lymphangioma in adult: A case report and a review of the literature. *J Surg Case Rep*, 7, 179, 2020. DOI: 10.1093/jscr/rjaa179
4. **Zhou Q, Zheng JW, Mai HM, Luo QF, Fan XD, Su LX, Wang YA, Qin ZP:** Treatment guidelines of lymphatic malformations of the head and neck. *Oral Oncol*, 47 (12): 1105-1109, 2011. DOI: 10.1016/j.oraloncology.2011.08.001
5. **Ginn PE, Mansell JEKL, Rakich PM:** Skin and appendages. In: Maxie MG (Ed): Jubb, Kennedy and Palmers Pathology of Domestic Animals. 5<sup>th</sup> ed., 768, Elsevier, Philadelphia, PA, 2007.
6. **Lawler DF, Evans RH:** Multiple hepatic cavernous lymphangioma in an aged male cat. *J Comp Pathol*, 109 (1): 83-87, 1993. DOI: 10.1016/s0021-9975(08)80242-3
7. **Driessen F, Cushing T, Baines SJ:** Retroperitoneal lymphatic malformation in a dog. *Acta Vet Scand*, 62:8, 2020. DOI: 10.1186/s13028-020-0506-9
8. **Espinosa J, Ferreras MC, García D, Vallejo R, Pérez V:** Case report: Multiple cavernous pericardial lymphangioma (pericardial lymphangiomatosis) in a captive peregrine falcon (*Falco peregrinus brookei*). *Front Vet Sci*, 8:662157, 2021. DOI: 10.3389/fvets.2021.662157
9. **Junginger J, Rötting A, Staszyc C, Kramer K, Hewicker-Trautwein M:** Identification of equine cutaneous lymphangioma by application of a lymphatic endothelial cell marker. *J Comp Pathol*, 143 (1): 57-60, 2010. DOI: 10.1016/j.jcpa.2009.11.005
10. **Fliegelman LJ, Friedland D, Brandwein M, Rothschild M:** Lymphatic malformation: Predictive factors for recurrence. *Otolaryngol Head Neck Surg*, 123, 706-710, 2000. DOI: 10.1067/mhn.2000.110963