

## RESEARCH ARTICLE

## Growth, Hematological and Histopathological Responses to Guar (*Cyamopsis tetragonoloba*) and Salinomycin Sodium for Ameliorating Deleterious Effects of Coccidiosis in Broiler Chicken

Omer NASEER <sup>1,a (\*)</sup> Jawaria Ali KHAN <sup>2,b</sup> Muhammad SHAHID <sup>3,c</sup> Ameer Hamza RABBANI <sup>3,d</sup>  
Abdullah Saghir AHMAD <sup>4,e</sup> Muhammad Luqman SOHAIL <sup>1,f</sup> Junaid NASEER <sup>5,g</sup> Muhammad BILAL <sup>6,h</sup>  
Waqas ABBAS <sup>7,i</sup> Muhammad Usman SALEEM <sup>8,j</sup> Yasir Razzaq KHAN <sup>1,k</sup> Ahmad ALI <sup>1,l</sup> Kashif HUSSAIN <sup>1,m</sup>

<sup>1</sup> Department of Medicine, Faculty of Veterinary Sciences, Cholistan University of Veterinary and Animal Sciences, 63100, Bahawalpur, PAKISTAN; <sup>2</sup> Department of Medicine, University of Veterinary and Animal Sciences, 54000, Lahore, PAKISTAN; <sup>3</sup> Department of Surgery, Faculty of Veterinary Sciences, Cholistan University of Veterinary and Animal Sciences, 63100, Bahawalpur, PAKISTAN; <sup>4</sup> Department of Parasitology, Faculty of Veterinary Sciences, Cholistan University of Veterinary and Animal Sciences, 63100, Bahawalpur, PAKISTAN; <sup>5</sup> Department of Forestry Range & Wildlife Management, The Islamia University, 63100, Bahawalpur, PAKISTAN; <sup>6</sup> Poultry Research Institute, Livestock & Dairy Development Department, Punjab, 46000, Rawalpindi, PAKISTAN; <sup>7</sup> Feed tech Division, Ghazi Brothers (Pvt) limited, 54920, Lahore, PAKISTAN; <sup>8</sup> Department of Biosciences, Faculty of Veterinary Sciences, Bahauddin Zakriya University, 60800, Multan, PAKISTAN  
ORCID: <sup>a</sup> 0000-0002-5388-4917; <sup>b</sup> 0000-0002-9443-8462; <sup>c</sup> 0000-0001-7105-7694; <sup>d</sup> 0000-0002-8901-2280; <sup>e</sup> 0000-0001-8017-346X  
<sup>f</sup> 0000-0002-2594-6746; <sup>g</sup> 0000-0001-7999-8130; <sup>h</sup> 0000-0001-8067781X; <sup>i</sup> 0000-0003-1610-5248; <sup>j</sup> 0000-0002-3352-1481; <sup>k</sup> 0000-0002-9031-0306  
<sup>l</sup> 0000-0002-2539-606X; <sup>m</sup> 0000-0002-0594-8023

Article ID: KVFD-2021-26216 Received: 30.06.2021 Accepted: 19.10.2021 Published Online: 20.10.2021

### Abstract

Coccidiosis is a preeminent threat to productivity in broiler industry. This prospective study was undertaken to evaluate the anti-coccidial efficacy of guar (*Cyamopsis tetragonoloba*) and salinomycin sodium in broiler Chicken. One hundred and twenty broiler chicks were divided into four groups with each having 30 birds. Group A had salinomycin sodium supplementation, group B received Guar (*Cyamopsis tetragonoloba*) whereas groups C and D were positive and negative controls respectively. Salinomycin and guar (*Cyamopsis tetragonoloba*) were administered following oral inoculation of 50.000 oocysts of *Eimeria* specie in all birds except the ones inducted into negative control group. Weight gain, feed conversion ratio, Fecal oocysts and blood profile of these birds were determined weekly. When histopathology was performed only a couple of coccidian parasites were identified in the intestinal caeca of birds treated with guar, whereas none were seen in birds treated with salinomycin sodium. It was concluded that results in terms of weight gain and feed conversion ratio were more favorable in case of salinomycin supplementation. However, guar exhibited greater efficacy as an antiprotozoal agent with significant reduction in fecal shedding of oocysts. In contrast to groups receiving salinomycin, severity of bloody diarrhea and mortality rates amongst infected birds subjected to guar were appreciably lower as well.

**Keywords:** Age, Blood profile, Hemoglobin, Infection, Oocysts, Broiler chicken, Guar

## Etlik Piliçlerde Koksidiyozun Zararlı Etkilerinin İyileştirilmesi İçin Kullanılan Guar (*Cyamopsis tetragonoloba*) ve Salinomisin Sodyuma Karşı Büyüme, Hematolojik ve Histopatolojik Tepkiler

### Öz

Koksidiyoz, broiler endüstrisinde üretkenlik için önde gelen tehditlerden birisidir. Bu prospektif çalışmada, broiler tavuklarda guar (*Cyamopsis tetragonoloba*) ve salinomisin sodyumun antikoksidiyal etkinliği değerlendirildi. Yüzyirmi broier civivi, her birinde 30 hayvan olacak şekilde dört gruba ayrıldı. A grubuna salinomisin sodyum ve B grubuna guar (*Cyamopsis tetragonoloba*) verilirken, C ve D grupları sırasıyla pozitif ve negatif kontrolleri oluşturdu. Negatif kontrol grubu hariç diğer gruplardaki tüm hayvanlara *Eimeria* türüne ait 50.000 oocist ağız yoluyla verildikten sonra, salinomisin ve guar (*Cyamopsis tetragonoloba*) uygulandı. Civivlerin, haftalık ağırlık artışı, yemden yararlanma oranı, dışkı oocistleri ve kan profilleri belirlendi. Histopatolojik analizde, guar uygulanmış hayvanların sekumunda sadece birkaç koksidiyal etken tespit edilirken, salinomisin sodyum uygulanan hayvanların hiçbirinde etken saptanmadı. Salinomisin ilavesinin, hayvanlarda ağırlık artışı ve yemden yararlanma oranı açısından daha olumlu sonuçlar verdiği saptandı. Bununla birlikte, guar, oocistlerin dışkı ile saçılmalarında önemli bir azalma ile antiprotozoal bir ajan olarak daha fazla etkinlik gösterdi. Salinomisin uygulanan grubun aksine, kanlı ishalin şiddeti ve enfekte kuşlar arasındaki ölüm oranları guar uygulanan grupta kayda değer ölçüde daha düşüktü.

**Anahtar sözcükler:** Yaş, Kan profili, Hemoglobin, Enfeksiyon, Oocist, Broiler tavuklar, Guar

### How to cite this article?

Naseer O, Khan JA, Shahid M, Rabbani AH, Ahmad AS, Sohail ML, Naseer J, Bilal M, Abbas W, Saleem MU, Khan YR, Ali A, Hussain K: Growth, hematological and histopathological responses to gaur (*Cyamopsis tetragonoloba*) and salinomycin sodium for ameliorating deleterious effects of coccidiosis in broiler chicken. *Kafkas Univ Vet Fak Derg*, 28 (1): 19-26, 2022. DOI: 10.9775/kvfd.2021.26216

### (\*) Corresponding Author

Tel: +92 321 640 8956

E-mail: [omernaseer@cuvas.edu.pk](mailto:omernaseer@cuvas.edu.pk) (O. Naser)



This article is licensed under a Creative Commons Attribution-NonCommercial 4.0 International License (CC BY-NC 4.0)

## INTRODUCTION

Productivity in Pakistani broiler sector has become stagnant in recent years due to a myriad of bacterial, viral, fungal and parasitic diseases causing devastating economic losses [1,2]. *Eimeria* species (phylum Apicomplexa) being a protozoan parasite, is believed to be the root cause of Coccidiosis in broiler [3], infecting upto 70% commercialized broiler production systems [4], in developing countries [5]. Seven subspecies of *Eimeria* have been isolated from chicken i.e. *E. acervulina*, *E. maxima*, *E. tenella*, *E. brunette*, *E. necatrix*, *E. mitis* and *E. praecox* [4,6,7]. However, in Pakistan *E. tenella* has been observed as the most prevalent pathogenic species [8]. Coccidiostats have been employed all over the world for efficient control of avian coccidiosis but their repeated and inefficient usage has produced several drug resistant strains [4]. This dilemma has promoted a search for plant based anti-microbial nutraceutical agents [9].

Guar legume (*Cyamopsis tetragonoloba*), grown for gum, produces guar hulls as a by-product containing high level of antiprotozoal Saponins [10] whereas Salinomycin is a tricyclic spiroketal hexagonal ring system possessing ionophoric properties [11]. Hematology values indicate the physiological profile of birds [11] and are used as an important diagnostic tool in many anemic disorders [12]. It has been reported that erythrocytes (RBC), leukocytes (WBC), hematocrit (hct) and hemoglobin (Hb) levels increase with age and their values change significantly in diseased birds [13,14]. As coccidial oocysts are ingested and intestinal mucosae of birds are colonized by *Eimeria* species, impaired food conversion ratio (FCR) leads to reduced productivity [9,15]. Furthermore, coccidiosis also destroys natural intestinal microflora namely Enterobacteriaceae, that assist in feed digestion. This creates favorable condition for the progenation of microbes such as *Lactobacillales* spp. thereby further deteriorating overall gut health. Poor feed conversion causes depressed immune system which eventually enhances the probability of secondary bacterial infections [16,17].

So the current study was designed to examine the anti-coccidial efficacy of guar and salinomycin sodium in broilers chicken. Efficiency of these drugs in diseased broiler chickens was to be evaluated based on production, hematological profile and histopathological changes.

## MATERIAL AND METHODS

### Ethical Considerations

Ethical approval of this study was obtained from University of Veterinary and Animal Sciences, Lahore, Ethical Committee. The animals were treated in compliance with ethical standards.

### Grouping of Birds

The study was conducted on 120 birds which were deemed

free from any coccidial infection by fecal examination. Day old chicks were sourced from local market. They were weighed and randomly assigned into four (4) groups namely A, B, C and D. Each group had 30 birds. Group A (GA) and Group B (GB) were treatment groups whereas group C was positive control (PC) and group D was negative control (NC). The experimental birds were vaccinated against Newcastle and Infectious Bursal Disease. All birds inducted into the study were offered an experimental feed. Nutritional composition of the aforementioned feed has been presented in Table 1.

Group A had salinomycin sodium supplementation; group B had Guar (*Cyamopsis tetragonoloba*) supplementation whereas groups C and D were positive and negative control respectively.

### Infection and Medication

Broiler chicken suspected with coccidiosis were collected from different broiler farms. Postmortem examinations were performed and samples were collected from suspected *Eimeria tenella* infections. Collected specimens were evaluated with PCR analysis to confirm presence of aforementioned coccidial specie. A suspension containing *E. tenella* oocysts was prepared by using Clorox digestion procedure [21]. Coccidial eggs were isolated and 1 mL inoculum containing 50,000 sporulated oocysts was introduced directly into the crop of each bird of groups A, B and C on day 21. Medication was started when clinical signs of coccidiosis appeared after 7 days of infection [18]. All birds were fed the same experimental diet details of which are given in Table 1. In addition to that GA was offered salinomycin sodium 5 gms/10 kg of feed [19] and GB was offered guar at 5% of feed [20].

### Drug Efficacy and Blood Profile

Mortality rates and weight gain were determined on weekly basis in the birds of all groups. The feed conversion ratio (FCR) was determined as described by Tanweer et al. [6] and oocysts per gram (OPG) were counted as described by Velkers et al. [21] to determine the efficacy of the drug. Complete blood count (CBC) included, Total Red blood cell count, Total leucocyte count, Blood hemoglobin, Mean corpuscular volume, Packed cell volume and Mean

**Table 1.** Nutritional composition of experimental feed offered to broilers

Composition	%, Unless Indicated
Moisture	9.8
Dry matter	90.2
Crude protein	18.4
Crude fiber	4.8
Ether extract	8.9
Crude ash	2.5
Nitrogen-free extract	55.6
Metabolizable energy (K Cal/kg)	2896

corpuseular hemoglobin were measured by using an automatic hematology analyzer (Hematology Analyzer, Abacus Junior Vet, Austria) as described by Odunitan-Wayas et al.<sup>[22]</sup> to determine the effects of guar and salinomycin sodium on the blood profile of the birds every week.

### Histopathological Examination

Birds were slaughtered by Halal method as described by Abdullah et al.<sup>[23]</sup> and 3 cm intestinal segments at midpoints were collected from all the groups preserving them in 4% paraformaldehyde solution. Samples were dehydrated and histological sectioning was performed after embedding in paraffin. Slides were stained with haematoxylin and eosin (HE)<sup>[9]</sup>.

### Statistical Analysis

Statistical analysis was done using Statistical Package for Social Science (SPSS for windows version 17.0, SPSS Inc, Chicago, IL). Normal distribution of the data was tested with Shapiro-Wilk test<sup>[24]</sup>. Analysis of data was done by multiple analyses of variance (MANOVA). Significant differences among the groups were analyzed by Duncan's Multiple Range test (Duncan 1955), ( $P < 0.05$ ).

## RESULTS

No dead birds were observed in GA, GB and NC till 28<sup>th</sup> day post infection, but several birds of PC group died by

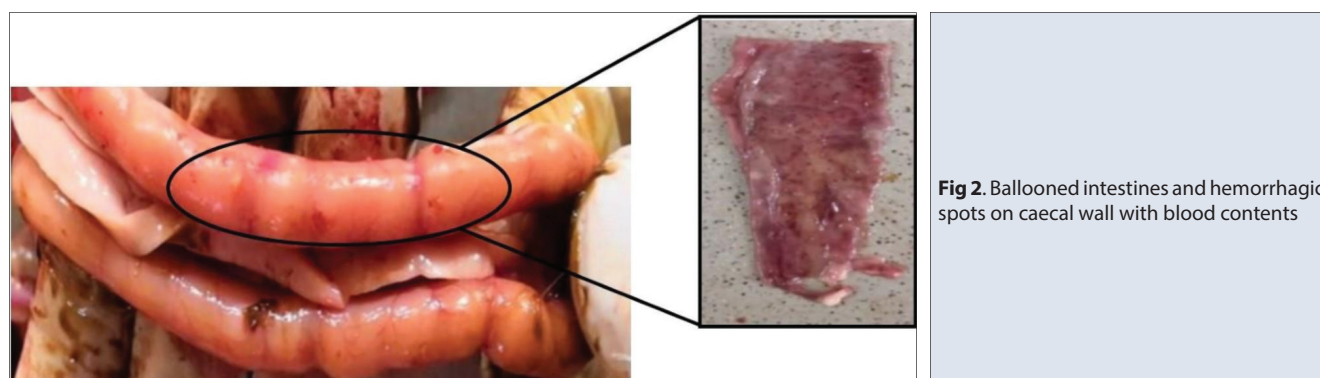
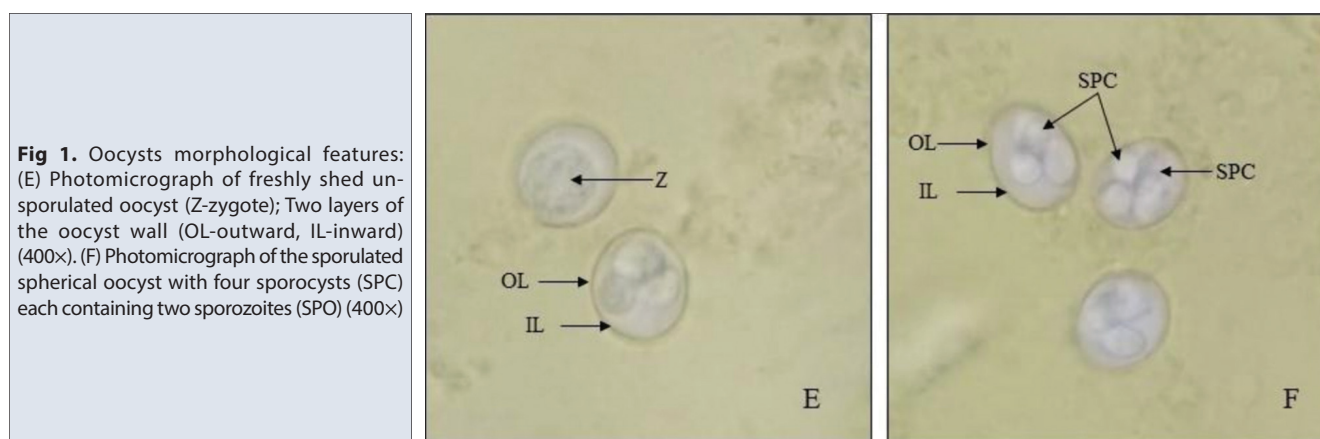
28<sup>th</sup> day. No mortality was observed in NC throughout the duration of trial. However, all birds induced into Positive Control group died by 42<sup>nd</sup> day (Fig. 1).

Higher mortality was observed in GA as compared to GB showing that guar reduces mortality in coccidiosis more efficiently as compared to salinomycin sodium (Fig. 2).

Significant results were observed for weight gain, FCR and OPG between weeks. Weight gain and FCR increased with increasing age and was found to be most in 6<sup>th</sup> week. However, oocyst per gram (OPG) decreased gradually with time in GA and GB but increased in PC (Table 2).

Erythrocyte count amplified as birds aged in NC but plummeted in groups infected with coccidiosis. Similarly, TLC increased in NC with age whereas decreased in the rest of experimental groups as infection became severe. A significant difference ( $P < 0.05$ ) was observed for PCV, hemoglobin, MCV and MCH throughout the duration of study (Table 3).

NC had the highest values for TEC and TLC followed by GB and GA whereas as PC had the least values for TEC and TLC. NC had the most values for hemoglobin and PCV followed by GB and GA, as PC had least values for PCV and hemoglobin. GA and GB showed no significance for MCH and MCV during 5<sup>th</sup> week while NC had lowest values for MCV and MCH. However, during the 4<sup>th</sup> week group B had the lowest value for MCH (Table 3). Postmortem lesions



**Table 2. Effects of guar and salinomycin sodium supplementation on production of broilers post infection**

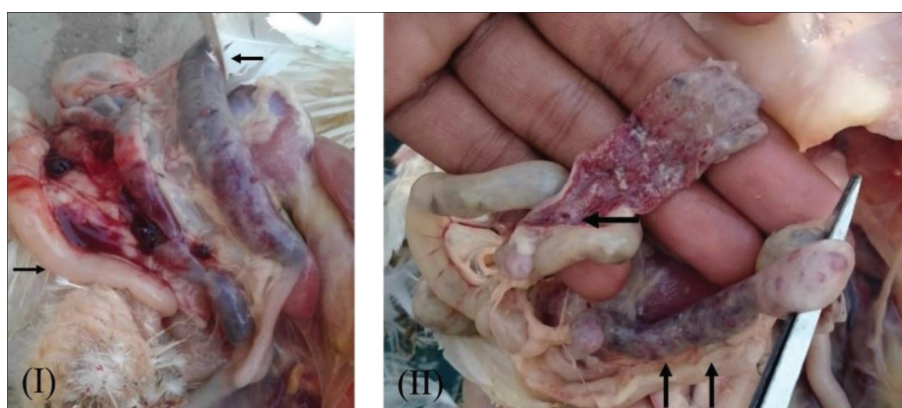Variables	Weight Gain (gms)						FCR <sup>+</sup>			OPG <sup>ψ</sup>		
	Weeks						Weeks			Weeks		
	4 <sup>th</sup>	5 <sup>th</sup>	6 <sup>th</sup>	4 <sup>th</sup>	5 <sup>th</sup>	6 <sup>th</sup>	4 <sup>th</sup>	5 <sup>th</sup>	6 <sup>th</sup>	4 <sup>th</sup>	5 <sup>th</sup>	6 <sup>th</sup>
Salinomycin Sodium	1148.0±11.56 <sup>A,c</sup>	1750.23±11.77 <sup>B,c</sup>	2351.94±10.59 <sup>C,b</sup>	1.47±0.01 <sup>A,a</sup>	1.65±0.01 <sup>B,b</sup>	1.67±0.01 <sup>C,b</sup>	7153.76±35.29 <sup>C,b</sup>	4168.61±3.86 <sup>B,b</sup>	2146.27±18.01 <sup>A,b</sup>			
Guar ( <i>Cyamopsis tetragonoloba</i> )	1079.66±14.19 <sup>A,b</sup>	1641.25±13.04 <sup>B,b</sup>	2068.47±11.02 <sup>C,a</sup>	1.56±0.02 <sup>A,b</sup>	1.78±0.01 <sup>B,c</sup>	1.88±0.01 <sup>C,c</sup>	6269.23±25.84 <sup>C,a</sup>	3297.29±17.23 <sup>B,a</sup>	1147.65±16.98 <sup>A,a</sup>			
Positive Control	881.60±18.52 <sup>A,a</sup>	1000.94±13.37 <sup>B,a</sup>	ABD <sup>∞</sup>	1.92±0.04 <sup>A,c</sup>	2.92±0.03 <sup>B,d</sup>	ABD <sup>∞</sup>	7766.44±17.82 <sup>A,c</sup>	8950.17±349.97 <sup>B,c</sup>	ABD <sup>∞</sup>			
Negative Control	1147.50±9.97 <sup>A,c</sup>	1808.83±14.42 <sup>B,d</sup>	2539.50±13.15 <sup>C,c</sup>	1.47±0.01 <sup>A,a</sup>	1.52±0.01 <sup>B,a</sup>	1.53±0.01 <sup>C,a</sup>	N.O <sup>b</sup>	N.O <sup>b</sup>	N.O <sup>b</sup>			

<sup>+</sup>FCR = feed conversion ratio, <sup>ψ</sup>OPG = oocysts per gram, <sup>∞</sup>ABD = all birds died, <sup>b</sup>N.O = no oocysts. Results are written as Mean ± Standard Deviation. Superscripts <sup>A-C</sup> within a row indicates that values are statistically significant (P<0.05). Superscripts <sup>a-d</sup> within a column indicates that values are statistically significant (P<0.05)

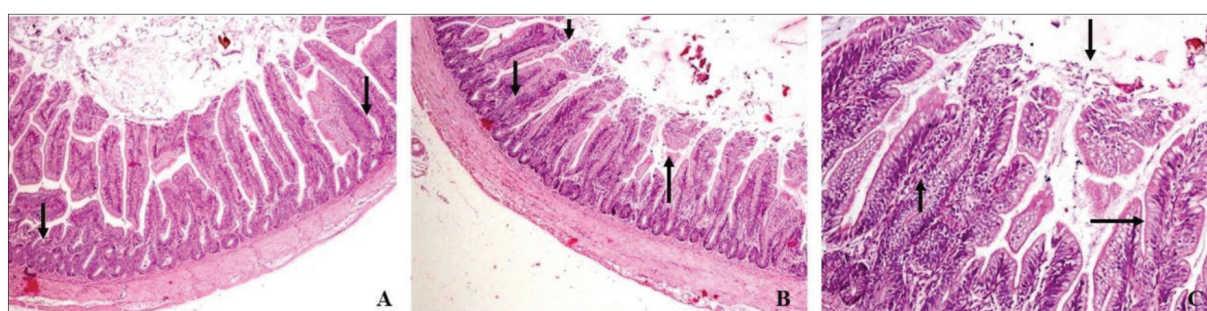
**Table 3. Effects of guar and salinomycin sodium supplementation on blood profile of broilers post infection**

Variables	TEC <sup>x</sup> X 10 <sup>3</sup> /μL						TLC <sup>w</sup> X 10 <sup>3</sup> /μL						Hb <sup>z</sup> (gm %)						PCV <sup>v</sup> (%)						MCV <sup>v</sup> (fl)						MCH <sup>v</sup> (pg)					
	Weeks						Weeks						Weeks						Weeks						Weeks						Weeks					
	4 <sup>th</sup>	5 <sup>th</sup>	6 <sup>th</sup>	4 <sup>th</sup>	5 <sup>th</sup>	6 <sup>th</sup>	4 <sup>th</sup>	5 <sup>th</sup>	6 <sup>th</sup>	4 <sup>th</sup>	5 <sup>th</sup>	6 <sup>th</sup>	4 <sup>th</sup>	5 <sup>th</sup>	6 <sup>th</sup>	4 <sup>th</sup>	5 <sup>th</sup>	6 <sup>th</sup>	4 <sup>th</sup>	5 <sup>th</sup>	6 <sup>th</sup>	4 <sup>th</sup>	5 <sup>th</sup>	6 <sup>th</sup>	4 <sup>th</sup>	5 <sup>th</sup>	6 <sup>th</sup>	4 <sup>th</sup>	5 <sup>th</sup>	6 <sup>th</sup>						
Salinomycin Sodium	3.17±0.01 <sup>C,b</sup>	3.07±0.01 <sup>B,b</sup>	3.02±0.01 <sup>A,a</sup>	8.54±0.02 <sup>C,b</sup>	8.47±0.01 <sup>B,b</sup>	8.42±0.01 <sup>A,a</sup>	8.67±0.01 <sup>C,b</sup>	8.62±0.01 <sup>B,b</sup>	8.56±0.01 <sup>A,a</sup>	25.51±0.03 <sup>C,b</sup>	25.36±0.03 <sup>B,b</sup>	25.20±0.04 <sup>A,a</sup>	80.44±0.35 <sup>A,c</sup>	82.56±0.40 <sup>B,c</sup>	83.18±0.37 <sup>C,c</sup>	27.35±0.12 <sup>A,c</sup>	27.35±0.12 <sup>A,c</sup>	28.07±0.13 <sup>B,c</sup>	27.35±0.12 <sup>A,c</sup>	27.35±0.12 <sup>A,c</sup>	28.07±0.13 <sup>B,c</sup>	27.35±0.12 <sup>A,c</sup>	27.35±0.12 <sup>A,c</sup>	28.07±0.13 <sup>B,c</sup>	27.35±0.12 <sup>A,c</sup>	27.35±0.12 <sup>A,c</sup>	28.07±0.13 <sup>B,c</sup>	27.35±0.12 <sup>A,c</sup>	27.35±0.12 <sup>A,c</sup>	28.07±0.13 <sup>B,c</sup>						
Guar ( <i>Cyamopsis tetragonoloba</i> )	3.25±0.03 <sup>C,c</sup>	3.16±0.02 <sup>B,c</sup>	3.13±0.01 <sup>A,b</sup>	8.93±0.03 <sup>C,c</sup>	8.85±0.03 <sup>B,c</sup>	8.67±0.02 <sup>A,b</sup>	8.85±0.02 <sup>C,c</sup>	8.80±0.02 <sup>B,c</sup>	8.75±0.02 <sup>A,b</sup>	26.05±0.06 <sup>C,c</sup>	25.89±0.07 <sup>B,c</sup>	25.75±0.07 <sup>A,b</sup>	79.10±0.82 <sup>A,b</sup>	82.20±0.73 <sup>B,c</sup>	82.72±0.29 <sup>C,b</sup>	26.89±0.28 <sup>A,a</sup>	26.89±0.28 <sup>A,a</sup>	27.95±0.25 <sup>B,c</sup>	26.89±0.28 <sup>A,a</sup>	26.89±0.28 <sup>A,a</sup>	27.95±0.25 <sup>B,c</sup>	26.89±0.28 <sup>A,a</sup>	26.89±0.28 <sup>A,a</sup>	27.95±0.25 <sup>B,c</sup>	26.89±0.28 <sup>A,a</sup>	26.89±0.28 <sup>A,a</sup>	27.95±0.25 <sup>B,c</sup>	26.89±0.28 <sup>A,a</sup>	26.89±0.28 <sup>A,a</sup>	27.95±0.25 <sup>B,c</sup>						
Positive Control	3.09±0.01 <sup>B,a</sup>	3.01±0.01 <sup>A,a</sup>	ABD <sup>∞</sup>	8.44±0.02 <sup>B,a</sup>	8.35±0.01 <sup>A,a</sup>	ABD <sup>∞</sup>	8.58±0.02 <sup>B,a</sup>	8.22±0.01 <sup>A,a</sup>	ABD <sup>∞</sup>	25.25±0.07 <sup>B,a</sup>	24.19±0.07 <sup>A,a</sup>	ABD <sup>∞</sup>	80.19±0.66 <sup>A,d</sup>	81.62±0.45 <sup>B,b</sup>	ABD <sup>∞</sup>	27.26±0.22 <sup>A,d</sup>	27.26±0.22 <sup>A,d</sup>	27.75±0.15 <sup>B,b</sup>	27.26±0.22 <sup>A,d</sup>	27.26±0.22 <sup>A,d</sup>	27.75±0.15 <sup>B,b</sup>	27.26±0.22 <sup>A,d</sup>	27.26±0.22 <sup>A,d</sup>	27.75±0.15 <sup>B,b</sup>	27.26±0.22 <sup>A,d</sup>	27.26±0.22 <sup>A,d</sup>	27.75±0.15 <sup>B,b</sup>	27.26±0.22 <sup>A,d</sup>	27.26±0.22 <sup>A,d</sup>	27.75±0.15 <sup>B,b</sup>						
Negative Control	3.41±0.04 <sup>A,d</sup>	3.55±0.02 <sup>B,d</sup>	3.65±0.03 <sup>C,c</sup>	8.90±0.05 <sup>A,d</sup>	9.04±0.04 <sup>B,d</sup>	9.33±0.08 <sup>C,c</sup>	8.88±0.04 <sup>A,d</sup>	9.07±0.03 <sup>B,d</sup>	9.11±0.03 <sup>C,c</sup>	26.14±0.13 <sup>A,d</sup>	26.68±0.08 <sup>B,d</sup>	26.79±0.09 <sup>C,c</sup>	76.46±0.84 <sup>C,a</sup>	74.98±0.70 <sup>B,a</sup>	73.32±0.79 <sup>A,a</sup>	26.96±0.69 <sup>C,b</sup>	26.96±0.69 <sup>C,b</sup>	27.05±1.14 <sup>B,a</sup>	26.96±0.69 <sup>C,b</sup>	26.96±0.69 <sup>C,b</sup>	27.05±1.14 <sup>B,a</sup>	26.96±0.69 <sup>C,b</sup>	26.96±0.69 <sup>C,b</sup>	27.05±1.14 <sup>B,a</sup>	26.96±0.69 <sup>C,b</sup>	26.96±0.69 <sup>C,b</sup>	27.05±1.14 <sup>B,a</sup>	26.96±0.69 <sup>C,b</sup>	26.96±0.69 <sup>C,b</sup>	27.05±1.14 <sup>B,a</sup>						

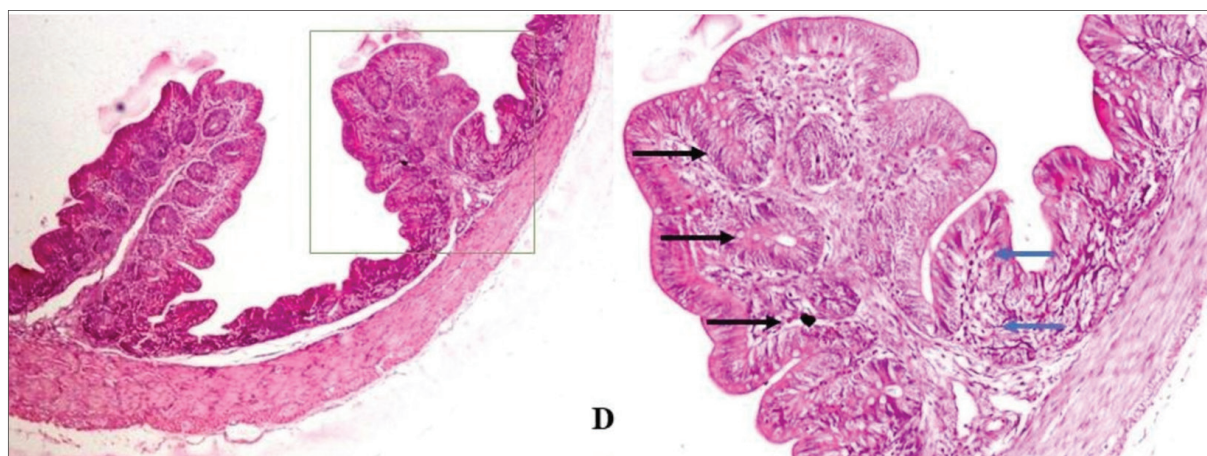
<sup>x</sup>TEC = total erythrocyte count, <sup>w</sup>TLC = total leucocyte count, <sup>z</sup>Hb = hemoglobin, <sup>v</sup>PCV = packed cell volume, <sup>∞</sup>ABD = all birds died. Results are written as Mean ± Standard Deviation. Superscripts <sup>A-C</sup> within a row indicates that values are statistically significant (P<0.05). Superscripts <sup>a-d</sup> within a column indicates that values are statistically significant (P<0.05)



**Fig 3.** (I) *Eimeria tenella* infected broiler chicken caeca, (II) Opened caecum is filled with blood



**Fig 4.** Progressive cytopathic changes observed in intestinal histopathological slides as a consequence of coccidiosis in group C. (A) Intestinal villi preserved with few trophozoites whereby arrows mark the inflammatory infiltration by heterophils and mononuclear cells (H.E. staining, 200×), (B) Desquamation of enterocytes and fibrosis in muscularis marked by arrows indicate proliferation of meronts (H.E. staining, 200×), (C) Degradation of sub-mucosal glandular epithelium, edema and fibrosis along with shedding of oocysts in the glandular lumen (arrow) (H.E. staining, 400×)



**Fig 5.** Photomicrographs of intestinal mucosa of birds having guar supplementation (D) Mitigation of inflammatory process between crypts. Intestinal villi exhibit recovery after experiencing hypoplasia and sloughing (indicated by presence of fibrinous proliferation in lamina propria) (H.E. staining, 400×)

pathognomonic to *Eimeria* infection were evident in clinical cases (Fig. 3).

Histopathology of caecal coccidiosis showed epithelial tissue destruction and vascular congestion along with presence of hyperplastic lymphoid cells in the lumen. Caecum and intestine of birds were full of *Eimeria* oocyst. Progressive

cytopathic changes were observed in intestinal histopathological slides as a consequence of coccidiosis in group C (Fig. 4).

Whereas birds supplemented with guar supplementation exhibited prompt recovery of Intestinal villi after experiencing mucosal sloughing (Fig. 5).

## DISCUSSION

Birds of Group A treated with salinomycin sodium exhibited greater weight gains as compared to other groups. Similar findings were reported by Rychen et al.<sup>[25]</sup> and Hassan<sup>[26]</sup>, whereby administration of synthetic ionophores reduced coccidiosis-related mortalities while concurrently acted as growth promoters. These observations were attributed to the innate ability of salinomycin sodium to neutralize certain Gram-positive bacteria responsible for intestinal maladies<sup>[27]</sup>. In several studies salinomycin sodium (SAL) has been hailed as an immensely efficacious anticoccidial agent. However, Demirulus et al.<sup>[28]</sup> thoroughly contradicted with prior suggestions and reported negative effects of SAL on weight gain in broiler birds. Concurrently certain studies indicated favorable outcomes when guar was administered to mitigate coccidiosis in broiler birds. However, poor weight gains were observed again which were rationalized by the presence of anti-nutritional factors such as saponins in guar based feeds<sup>[25,29]</sup> 1983. Reyer et al.<sup>[30]</sup> justified improved FCR in guar fed broiler birds by hypothesizing the emulsifying effects of saponins thereby improving membrane permeability and nutrient absorption of diet. Furthermore, a recent study of guar in broiler birds has indicated elevated digestibility of both essential and non-essential amino acids<sup>[31]</sup>. But present study could not corroborate these findings as birds which received SAL supplementation observably gained greater weight than the ones that fed with guar. Yet in certain cases, supplementation of feed with phyto-genic additives has been judiciously warranted by experimental trials<sup>[32-34]</sup>.

Oral-fecal route has been a primary device for the spread of coccidiosis throughout modern broiler farming systems<sup>[35,36]</sup>. Authors have reported an increase in OPG with age of PC after inoculation. This has been previously reported by Rambozzi et al.<sup>[37]</sup> who suggested that oocysts increase with age in coccidiosis provided that birds received no therapeutic treatment. We observed marked reduction in OPG in all treatment groups whereby Guar showed better anticoccidial activity when compared with salinomycin sodium. Efficacy of guar supplementation has been attributed to the presence of saponins which elicited anticoccidial activity by binding with the sterol molecules that are present on the protozoan cell membranes<sup>[20,38]</sup> because they do not result to tissue residue and drug resistance. In order to evaluate the effects of herbal extracts to control avian coccidiosis, 180 one-day-old broiler chickens were randomly divided into nine equal groups, as follows: (1. Consistent with previous reports, the number of fecal oocysts in birds challenged with coccidia were effectively reduced in response to the phyto-genic products having saponins<sup>[6,35,39,40]</sup>.

Similar to prior findings<sup>[14]</sup>, it was observed that TEC, TLC, hemoglobin and percentage of PCV increased as birds continued to age whereas MCV and MCH decreased

in ageing birds that were infected with *Eimeria* spp. (Table 2)<sup>[14]</sup>. Patra et al.<sup>[41]</sup> has also reported overall reduction in TEC and hemoglobin of infected birds due to hemorrhagic cecal lesions. GA had the lowest TLC values than NC and GB as salinomycin caused fragility of red blood cells which ultimately led to their lysis<sup>[42]</sup>. TLC was reportedly lowest in GA as compared to NC and GB validating prior findings<sup>[43]</sup>, which suggested that salinomycin significantly decreased size of bursa leading to a reduction of white blood cell count<sup>[43]</sup>. In our study, decrease in PCV and relative increase of MCV and MCH values were comparable to that of published data<sup>[44]</sup>. Lower TEC for GA relative to GB indicated that PCV and hemoglobin levels would be depressed as well (Table 2). Likewise, MCV and MCH decreased more so in GB than in GA due to comparative difference in TEC as it affected MCV and MCH<sup>[45]</sup>.

Histological sections of necrosed cecal epithelia in birds infected with *Eimeria tenella* oocyst was illustrated by Wasae<sup>[46]</sup> and other researchers<sup>[47-50]</sup> to exhibit deterioration of intestinal epithelium and caeca in broiler birds. Fewer cecal coccidian sporozoites were observed birds treated with guar, while multiple developmental stages were seen in the infected and untreated groups<sup>[38]</sup>. Salinomycin sodium was effective in eliminating parasitic infestation but histopathological evidence of cecal destruction was still evident<sup>[38]</sup>.

In context of present study, we concluded that although both salinomycin sodium and guar (*Cyamopsis tetragonoloba*) exhibited adequate anticoccidial properties but guar was considerably more efficacious in controlling manifestation of clinical signs and oocyte shedding through feces. Whereas, Salinomycin sodium supplementation resulted in better body weight and FCR gains.

## AVAILABILITY OF DATA AND MATERIALS

The authors declare that data supporting the study findings are also available to the corresponding author.

## ACKNOWLEDGEMENT

Author is very much thankful to Ghazi Brothers (pvt) Ltd for providing Salinomycin Sodium for this research.

## FINANCIAL SUPPORT

This research did not receive any specific grant from funding agencies in the public, commercial, or not-for-profit sectors.

## DECLARATION OF CONFLICT OF INTEREST

There was no conflict of interest in regards to authors reporting their findings.

## AUTHOR CONTRIBUTIONS

Experimental Design was conceived by ON, JAK and MS. Data was collected by AHR, ASA, YRK, AA and KH. Statistical

analysis was conducted by JN, MLS and US. Original draft was written by MB and MW. All authors have contributed to the revision and final proof-reading of the manuscript.

## REFERENCES

1. Van TTH, Yidana Z, Smooker PM, Coloe PJ: Antibiotic use in food animals worldwide, with a focus on Africa: Pluses and minuses. *J Glob Antimicrob Resist*, 20, 170-177, 2020. DOI: 10.1016/j.jgar.2019.07.031
2. Bera AK, Bhattacharya D, Pan D, Dhara A, Kumar S, Das SK: Evaluation of economic losses due to coccidiosis in broiler industry in India. *Agric Econ Res Rev*, 23 (1): 91-96, 2010. DOI: 10.22004/ag.econ.92156
3. Erdoğan ŞZ, Gülmez N, Findik A, Hüseyin ŞAH, Gülmez M: Efficacy of probiotics on health status and growth performance of *Eimeria tenella* infected broiler chickens. *Kafkas Univ Vet Fak Derg*, 25 (3): 311-320, 2019. DOI: 10.9775/kvfd.2018.20889
4. Khater HF, Ziam H, Abbas A, Abbas RZ, Raza MA, Hussain K, Younis ES, Radwan IT, Selim A: Avian coccidiosis: Recent advances in alternative control strategies and vaccine development. *Agrobiol Rec*, 1, 11-25, 2020. DOI: 10.47278/journal.abr/2020.004
5. Al-Gawad AA, Mahdy OA, El-Massry AAN, Al-Aziz MSA: Studies on coccidia of Egyptian Balady breed chickens. *Life Sci J*, 9 (3): 568-576, 2012.
6. Tanweer AJ, Chand N, Khan S, Qureshi MS, Akhtar A, Niamatullah M: Impact of methanolic extract of *Peganum harmala* on the weight gain, feed conversion ratio, feed cost and gross return of broiler chicks. *J Anim Plant Sci*, 22 (2): 264-267, 2012.
7. Kim DK, Lillehoj H, Min W, Kim CH, Park MS, Hong YH, Lillehoj EP: Comparative microarray analysis of intestinal lymphocytes following *Eimeria acervulina*, *E. maxima*, or *E. tenella* infection in the chicken. *PLoS One*, 6 (11): e27712, 2011. DOI: 10.1371/journal.pone.0027712
8. Bachaya HA, Raza MA, Khan MN, Iqbal Z, Abbas RZ, Murtaza S, Badar N: Predominance and detection of different *Eimeria* species causing coccidiosis in layer chickens. *J Anim Plant Sci*, 22 (3): 597-600, 2012.
9. Yong T, Chen M, Li Y, Song X, Huang Y, Chen Y, Jia R, Zou Y, Li L, Yin L, He C, Lv, C, Liang X, Ye G, Yin Z: Anticoccidial effect of *Fructus meliae toosendan* extract against *Eimeria tenella*. *Pharm Biol*, 58 (1): 636-645, 2020. DOI: 10.1080/13880209.2020.1784234
10. Lee JT, Connor-Appleton S, Bailey CA, Cartwright AL: Effects of guar meal by-product with and without beta-mannanase Hemicell on broiler performance. *Poult Sci*, 84 (8): 1261-1267, 2005. DOI: 10.1093/ps/84.8.1261
11. Elhassan MMO, Khaier MAM, Elamin EA: The efficacy of salinomycin against experimentally infected broiler chickens with field isolates of *Eimeria tenella* in Khartoum State, Sudan. *Anim Vet Sci*, 8 (4): 71-75, 2020. DOI: 10.11648/j.avs.20200804.11
12. Velguth KE, Payton ME, Hoover JP: Relationship of hemoglobin concentration to packed cell volume in avian blood samples. *J Avian Med Surg*, 24 (2): 115-121, 2010. DOI: 10.1647/2008-042.1
13. Trela J, Kierończyk B, Hautekiet V, Józefiak D: Combination of *Bacillus licheniformis* and salinomycin: Effect on the growth performance and GIT microbial populations of broiler chickens. *Animals*, 10 (5): 889, 2020. DOI: 10.3390/ani10050889
14. Livingston ML, Cowieson AJ, Crespo R, Hoang V, Nogal B, Browning M, Livingston KA: Effect of broiler genetics, age, and gender on performance and blood chemistry. *Heliyon*, 6 (7): e04400, 2020. DOI: 10.1016/j.heliyon.2020.e04400
15. Tian E, Zhou B, Wang X, Zhao J, Deng W, Wang H: Effect of diclazuril on intestinal morphology and SIgA expression in chicken infected with *Eimeria tenella*. *Parasitol Res*, 113, 4057-4064, 2014. DOI: 10.1007/s00436-014-4074-7
16. Lei X, Piao X, Ru Y, Zhang H, Péron A, Zhang H: Effect of *Bacillus amyloliquefaciens*-based direct-fed microbial on performance, nutrient utilization, intestinal morphology and cecal microflora in broiler chickens. *Asian Australas J Anim Sci*, 28 (2): 239-246, 2015. DOI: 10.5713/ajas.14.0330
17. Macdonald SE, Nolan MJ, Harman K, Boulton K, Hume DA, Tomley FM, Stabler RA, Blake DP: Effects of *Eimeria tenella* infection on chicken caecal microbiome diversity, exploring variation associated with severity of pathology. *PLoS One*, 12 (9): e0184890, 2017. DOI: 10.1371/journal.pone.0184890
18. Haq IU, Pasha TN, Khaliq A: Comparative efficacy of herbal and allopathy drugs against coccidiosis in broiler. *Ital J Anim Sci*, 10 (1): e3, 2011. DOI: 10.4081/ijas.2011.e3
19. Tipu MA, Pasha TN, Ali Z: Comparative efficacy of salinomycin sodium and neem fruit (*Azadirachta indica*) as feed additive anticoccidials in broilers. *Int J Poult Sci*, 1 (4): 91-93, 2002. DOI: 10.3923/ijps.2002.91.93
20. Hassan SM, El-Gayar AK, Cadwell DJ, Bailey CA, Cartwright AL: Guar meal ameliorates *Eimeria tenella* infection in broiler chicks. *Vet Parasitol*, 157 (1-2): 133-138, 2008. DOI: 10.1016/j.vetpar.2008.07.005
21. Velkers FC, Blake DP, Graat EAM, Vernooij JCM, Bouma A, De Jong MCM, Stegeman JA: Quantification of *Eimeria acervulina* in faeces of broilers: Comparison of McMaster oocyst counts from 24 h faecal collections and single droppings to real-time PCR from cloacal swabs. *Vet Parasitol*, 169 (1-2): 1-7, 2010. DOI: 10.1016/j.vetpar.2010.01.001
22. Odunitan-Wayas F, Kolanisi U, Chimonyo M: Haematological and serum biochemical responses of Ovambo chickens fed provitamin A biofortified maize. *Braz J Poult Sci*, 20 (3): 425-434, 2018. DOI: 10.1590/1806-9061-2016-0444
23. Abdullah FAA, Borilova G, Steinhäuserova I: Halal criteria versus conventional slaughter technology. *Animals*, 9 (8): 530, 2019. DOI: 10.3390/ani9080530
24. Razali NM, Wah YB: Power comparisons of shapiro-wilk, kolmogorov-smirnov, lilliefors and anderson-darling tests. *J Stat Model Anal*, 2 (1): 21-33, 2011.
25. Hassan SM: Effects of guar meal, guar gum and saponin rich guar meal extract on productive performance of starter broiler chicks. *Afr J Agric Res*, 8 (21): 2464-2469, 2013.
26. Rychen G, Aquilina G, Azimonti G, Bampidis V, Bastos M de L, Bories G, Chesson A, Flachowsky G, Gropp J, Kolar B, Kouba M, López-Alonso M, Puente SL, Mantovani A, Mayo B, Ramos F, Rychen G, Saarela M, Villa RE, Wallace RJ, Wester P: Safety and efficacy of Hemicell® HT (endo-1, 4-β-d-mannanase) as a feed additive for chickens for fattening, chickens reared for laying, turkey for fattening, turkeys reared for breeding, weaned piglets, pigs for fattening and minor broiler and porcine sp. *EFSA J*, 16 (5): e05270, 2017. DOI: 10.2903/j.efsa.2018.5270
27. El-Sadek SE, Tohamy MA, A El-Badry A, Fouad NAM, El-Gendy AAM: Some pharmacodynamic interactions between salinomycin and vitamin E or selenium in chickens. *J Vet Med Res*, 19 (2): 24-32, 2009. DOI: 10.21608/jvmr.2009.77814
28. Demirulus H, Eratak S, Kara K: Effect of salinomycin on broiler performance. *Pakistan J Biol Sci*, 9 (1): 104-106, 2006. DOI: 10.3923/pjbs.2006.104.106
29. Carvalho A, Tavares-Dias M: Diversity of parasites in *Cichlasoma amazonarum* Kullander, 1983 during rainy and dry seasons in eastern Amazon (Brazil). *J Appl Ichthyol*, 33 (6): 1178-1183, 2017. DOI: 10.1111/jai.13451
30. Graczyk M, Reyer H, Wimmers K, Szwaczkowski T: Detection of the important chromosomal regions determining production traits in meat-type chicken using entropy analysis. *Br Poult Sci*, 58 (4): 358-365, 2017. DOI: 10.1080/00071668.2017.1324944
31. Al-Harathi MA, Attia YA, El-Shafey AS, Elgandy MF: Impact of phytase on improving the utilisation of pelleted broiler diets containing olive by-products. *Ital J Anim Sci*, 19 (1): 310-318, 2020. DOI: 10.1080/1828051X.2020.1740896
32. Amad AA, Wendler KR, Zentek J: Effects of a phytogenic feed additive on growth performance, selected blood criteria and jejunal morphology in broiler chickens. *Emirates J Food Agric*, 25 (7): 549-554, 2013. DOI: 10.9755/ejfa.v25i7.12364
33. Cho JH, Kim HJ, Kim IH: Effects of phytogenic feed additive on growth performance, digestibility, blood metabolites, intestinal microbiota, meat color and relative organ weight after oral challenge with *Clostridium perfringens* in broilers. *Livest Sci*, 160, 82-88, 2014. DOI:

10.1016/j.livsci.2013.11.006

- 34. Weber GM, Michalczuk M, Huyghebaert G, Juin H, Kwakernaak C, Gracia MI:** Effects of a blend of essential oil compounds and benzoic acid on performance of broiler chickens as revealed by a meta-analysis of 4 growth trials in various locations. *Poult Sci*, 91 (11): 2820-2828, 2012. DOI: 10.3382/ps.2012-02243
- 35. Alhotan RA, Abudabos A:** Anticoccidial and antioxidant effects of plants derived polyphenol in broilers exposed to induced coccidiosis. *Environ Sci Pollut Res*, 26, 14194-14199, 2019. DOI: 10.1007/s11356-019-04615-2
- 36. Geetha M, Palanivel KM:** A review on broiler coccidiosis. *Int J Curr Microbiol Appl Sci*, 7 (6): 3345-3349, 2018. DOI: 10.20546/ijcmas.2018.706.392
- 37. Rambozzi L, Renna M, Cornale P, Perona G, Malfatto V, Mimosi A:** Effect of the granulometric characteristics of monensin sodium on controlling experimental coccidiosis in broiler chickens. *Rev Bras Parasitol Vet*, 21 (1): 60-64, 2012. DOI: 10.1590/S1984-29612012000100012
- 38. Habibi H, Firouzi S, Nili H, Razavi M, Asadi SL, Daneshi S:** Anticoccidial effects of herbal extracts on *Eimeria tenella* infection in broiler chickens: *In vitro* and *in vivo* study. *J Parasit Dis*, 40 (2): 401-407, 2016. DOI: 10.1007/s12639-014-0517-4
- 39. Abudabos AM, Hussein EOS, Ali MH, Al-Ghadi MQ:** The effect of some natural alternative to antibiotics on growth and changes in intestinal histology in broiler exposed to Salmonella challenge. *Poult Sci*, 98 (3): 1441-1446, 2019. DOI: 10.3382/ps/pey449
- 40. Lan L, Zuo B, Ding H, Huang Y, Chen X, Du A:** Anticoccidial evaluation of a traditional chinese medicine-*Brucea javanica*-in broilers. *Poult Sci*, 95 (4): 811-818, 2016. DOI: 10.3382/ps/pev441
- 41. Patra G, Ali MA, Chanu KV, Jonathan L, Joy LK, Prava M, Ravindran R, Das G, Devi LI:** PCR based diagnosis of *Eimeria tenella* infection in broiler chicken. *Int J Poult Sci*, 9 (8): 813-818, 2010. DOI: 10.3923/ijps.2010.813.818
- 42. Yoshinaga T, Im HJ, Nishida S, Ogawa K:** *In vitro* and *in vivo* efficacies of ionophores against *Cryptocaryon irritans*. *Aquaculture*, 321 (3-4): 167-172, 2011. DOI: 10.1016/j.aquaculture.2011.08.028
- 43. Hussein MSH, Abd-El-Rahman AH:** Hematological, biochemical, immunological and histopathological changes caused by salinomycin in chicken. *Egypt J Nat Toxins*, 2, 13-38, 2005.
- 44. Ellakany HF, Abuakkada SS, Oda SS, El-Sayed YS:** Influence of low levels of dietary aflatoxins on *Eimeria tenella* infections in broilers. *Trop Anim Health Prod*, 43, 249-257, 2011. DOI: 10.1007/s11250-010-9685-0
- 45. Kayiran SM, Özbek N, Turan M, Gürakan B:** Significant differences between capillary and venous complete blood counts in the neonatal period. *Clin Lab Haematol*, 25 (1): 9-16, 2003. DOI: 10.1046/j.1365-2257.2003.00484.x
- 46. Wasae A:** A preliminary study on possible effect of Plectranthus spp. extract on histopathology and performance of broiler chicken infected by *Eimeria tenella* in Taiz city, Yemen. *Egypt Poult Sci J*, 37 (3): 761-777, 2017. DOI: 10.21608/epsj.2017.7575
- 47. Islam MM, Ali MH, Islam MN, Akther M, Rahman MG:** Clinico-pathological investigation of chicken coccidiosis at different upazila in Bogura district. *Res Agric Livest Fish*, 7 (2): 267-274, 2020. DOI: 10.3329/ralf.v7i2.48867
- 48. Olabode VB, Gunya DY, Alsea UM, Choji TPP, Barde IJ:** Histopathological lesions of coccidiosis natural infestation in chickens. *Asian J Res Anim Vet Sci*, 5 (2): 41-45, 2020.
- 49. Gogoi C, Sarma J, Barua CC, Tamuly S, Upadhyaya TN, Islam S, Sonowal J, Borthakur U, Banerjee DK, Barkathullah N:** Evaluation of nano-curcumin on experimentally induced coccidiosis in broiler chicks. *Int J Chem Stud*, 7 (3): 4514-4520, 2019.
- 50. Kim DK, Lillehoj HS, Lee SH, Jang SI, Lillehoj EP, Bravo D:** Dietary *Curcuma longa* enhances resistance against *Eimeria maxima* and *Eimeria tenella* infections in chickens. *Poult Sci*, 92 (10): 2635-2643, 2013. DOI: 10.3382/ps.2013-03095