

## CASE REPORT

# Optimal Management to Improve Quality of Life for an Injured Baby Elephant: Thailand Multidisciplinary Care Team

Siriphan KONGSAWASDI <sup>1,a</sup> Kittichai WANTANAJITTIKUL <sup>2,b</sup> Warangkhan LANGKAPHIN <sup>3,c</sup> Busaba CHUATRAKOON <sup>1,d</sup>  
Kittikul NAMWONGPROM <sup>3,e</sup> Paphawee PRUPETKAEW <sup>1,f</sup> Taweepoke ANGKAWANISH <sup>3,g (\*)</sup>

<sup>1</sup> Department of Physical Therapy, Faculty of Associated Medical Sciences, Chiang Mai University, Chiang Mai, 50200 THAILAND

<sup>2</sup> Department of Radiologic Technology, Faculty of Associated Medical Sciences, Chiang Mai University, Chiang Mai, 50200 THAILAND

<sup>3</sup> National Elephant Institute, Forest Industry Organization, Lamphang, 52190 THAILAND

ORCID: <sup>a</sup> 0000-0003-1022-0587; <sup>b</sup> 0000-0002-9111-8092; <sup>c</sup> 0000-0003-1760-5199; <sup>d</sup> 0000-0001-7880-797X; <sup>e</sup> 0000-0001-5762-0858  
<sup>f</sup> 0000-0002-2947-2998; <sup>g</sup> 0000-0002-2915-8122

Article ID: KVFD-2021-25927 Received: 22.04.2021 Accepted: 28.07.2021 Published Online: 01.08.2021

## Abstract

This article aimed to report the care, management, and monitoring of an injured female baby elephant. The collaboration among the multidisciplinary team included veterinary medicines, elephant handling, engineering, and physical therapy in the 3-year-old elephant with its left forelimb phalanges amputated through being caught in a snare trap. The management comprised medical wound care, nutrition and applying a prosthetic shoe. The kinematic parameters and vital sign monitoring were analysed. The results show that biomechanics gait analysis and physiological responses revealed promising benefit of the prosthetic shoe by reflecting a greater symmetrical gait pattern without dyspnea and no sign of exertion during daily life activity.

**Keywords:** Amputation, Artificial shoe, Elephant, Gait analysis, Prosthesis

## Yaralı Yavru Bir Filin Yaşam Kalitesini Artırmak İçin Optimal Yönetim: Tayland Multidisipliner Bakım Ekibi

### Öz

Bu makalede, yaralı bir dişi yavru filin bakım, yönetim ve izlenmesinin bildirilmesi amaçlanmıştır. Multidisipliner ekip arasındaki işbirliği, kapana yakalanarak sol ön ayak falanksları kesilen 3 yaşındaki bir fil için veteriner ilaçları, filin bakımı, mühendislik ve fizik tedaviyi içeriyordu. Yönetim, tıbbi yara bakımı, beslenme ve protez ayakkabı uygulanması şeklindeydi. Kinematik parametreler ve vital bulgu takibi analizleri gerçekleştirildi. Sonuçlar, biyomekanik yürüyüş analizi ve fizyolojik tepkilerin, dispne ve günlük yaşam aktivitesi sırasında hiçbir efor belirtisi olmaksızın daha simetrik bir yürüyüş modelini yansıtarak protez ayakkabının umut verici faydasını ortaya koyduğunu göstermektedir.

**Anahtar sözcükler:** Amputasyon, Fil, Protez, Yapay ayakkabı, Yürüyüş analizi

## INTRODUCTION

In Thailand, elephant poaching is illegal, and in most cases a “snare trap” is used. This often results in an injured baby being left behind with lack of its mother’s milk. It would then develop severe ailments, for instance, mental health and major musculoskeletal problems and sometimes die from infectious diseases such as elephant endotheliotropic herpesvirus (EEHV) <sup>[1]</sup>. This report described collaborative health care management, introduced a guideline for

elephants with amputated forelimb phalanges and monitored the consequences on walking characteristics after wearing a prosthetic shoe, by using motion analysis to evaluate the elephant’s quality of life (QOL).

## CASE HISTORY

A 3-month-old wild-born female elephant was referred from a private tourist camp to the National Elephant Institute (NEI). She was trapped at the left carpal joint by a

### How to cite this article?

**Kongsawadi S, Wantanajittikul K, Langkaphin W, Chuatrakoon B, Namwongprom K, Prupetkaew P, Angkawanish T:** Optimal management to improve quality of life for an injured baby elephant: Thailand multidisciplinary care team. *Kafkas Univ Vet Fak Derg*, 27 (5): 655-659, 2021. DOI: 10.9775/kvfd.2021.25927

### (\*) Corresponding Author

Tel: +66 54829331

E-mail: [taweepoke@gmail.com](mailto:taweepoke@gmail.com) (T. Angkawanish)



This article is licensed under a Creative Commons Attribution-NonCommercial 4.0 International License (CC BY-NC 4.0)

snare when she was 1 year old, and developed a clinical fever and fetid smell. Trans-metacarpal, partial foot amputation was performed as primary treatment by the veterinarian at the tourist camp, and antibiotics, skin flap and wound management were administered. She was then transferred to the NEI for appropriate management.

**Health Care and Management**

She was fed mainly with grass (protein of around 4-5%) and fruit supplements, while staying in a barn (4x4 m with sand bedding) at night and spending daytimes in natural forest. Minerals and vitamin C were provided daily and walking exercise for 1 h twice per day. Contagious diseases such as EEHV were monitored monthly.

adequate stability, but not excessively, to the point of risking tissue breakdown. Therefore, a prototype shoe was designed by the mechanical engineer team at the Faculty of Engineering, Chiang Mai University in collaboration with the Rubber Authority of Thailand. The prototype shoe was developed from latex foam, using 2 layers of fabric for the coating liners. The insole (shoe floor) density was 508 kg/m<sup>3</sup>, rubber hardness unit of 73 Shore OO and side density of 250-260 kg/m<sup>3</sup> with hardness of 41 Shore OO, which enabled the qualification mentioned (Fig. 3).

**Walking with the Prosthetic Shoe and Vital Sign Monitoring**

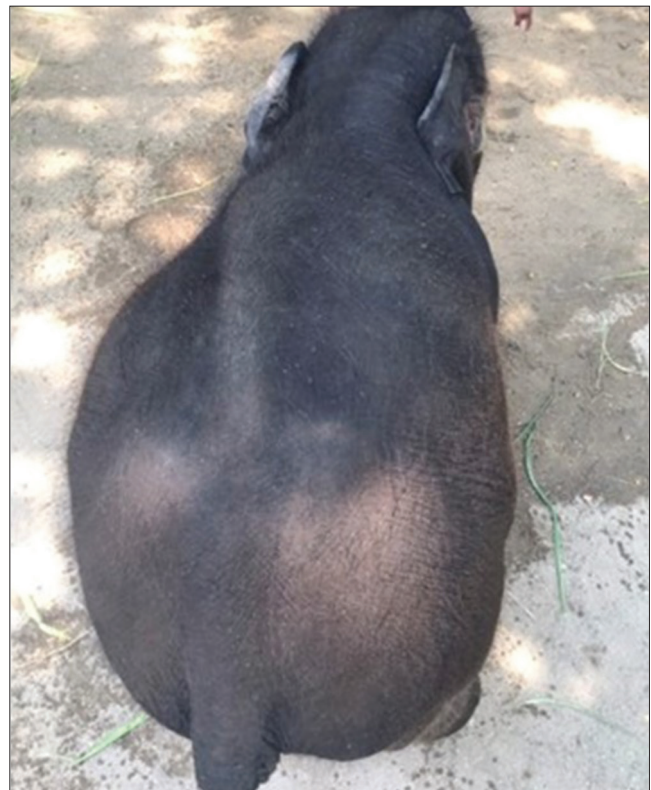The elephant was given the prosthetic shoe for the time

**Fig 1.** Development of abnormal alignment of the right forelimb before the shoe was applied

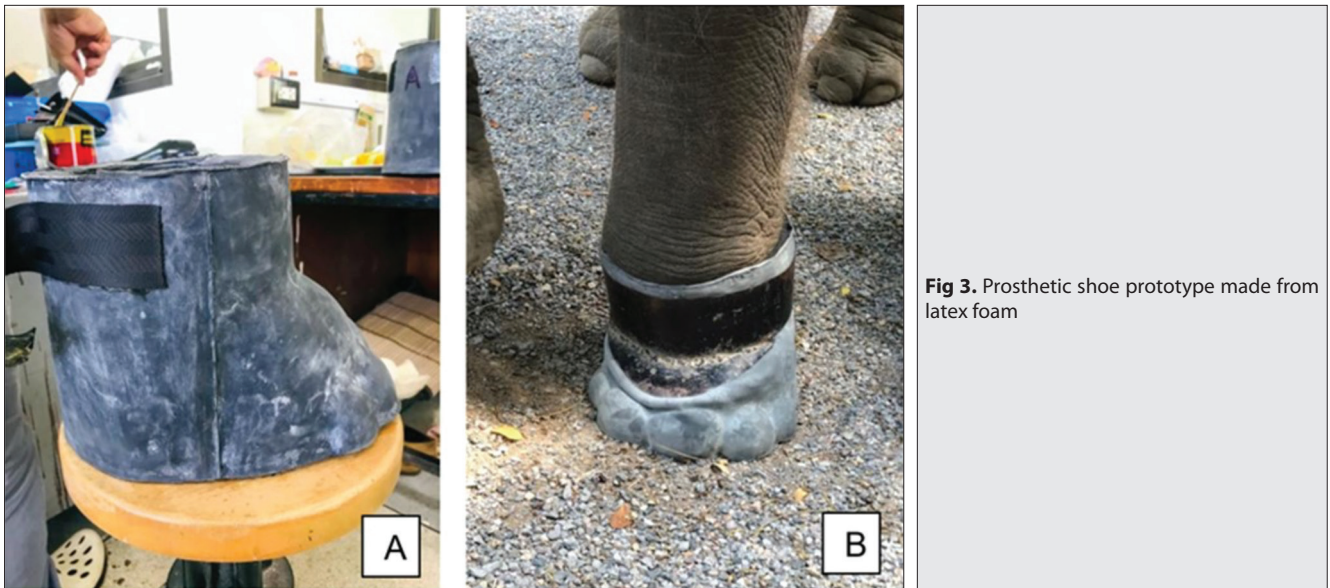


**Development of a Prosthetic Shoe**

Initially, the length of discrepancy between right and left forelimbs was 4 cm (right or intact side was 139 cm, and left or amputated limb 135 cm). As she was unable to bear weight on her left forelimb, non-used atrophy of the left muscles occurred. Malalignment of the right shoulder and elbow joint also was observed in the frontal plane (Fig. 1), which was caused by the need to shift more weight onto the right side. Her head was at a lower level when compared to the vertebrae and pelvis. Consequently, from the imbalance of weight distribution between the forelimbs and hindlimbs, a sideways twist of the thoracic and lumbar spine developed, forming an S-shaped vertebra (Fig. 2). These deformities might progress further and affect her long-term QOL. Therefore, a prosthetic shoe was used to replace the missing parts of her leg and regain functionality. As this was probably a rare case of a young elephant with limb amputation in Thailand, this project established a multidisciplinary team that worked together to develop an appropriate prototype model. Integral components of prosthetic prescription included a socket, interface and joint unit [2]. Regarding the elephant, the materials used for the socket were important, with concern about adequate mechanical coupling between the soft tissues and supporting device. The materials should be able to manage the heavy load and provide



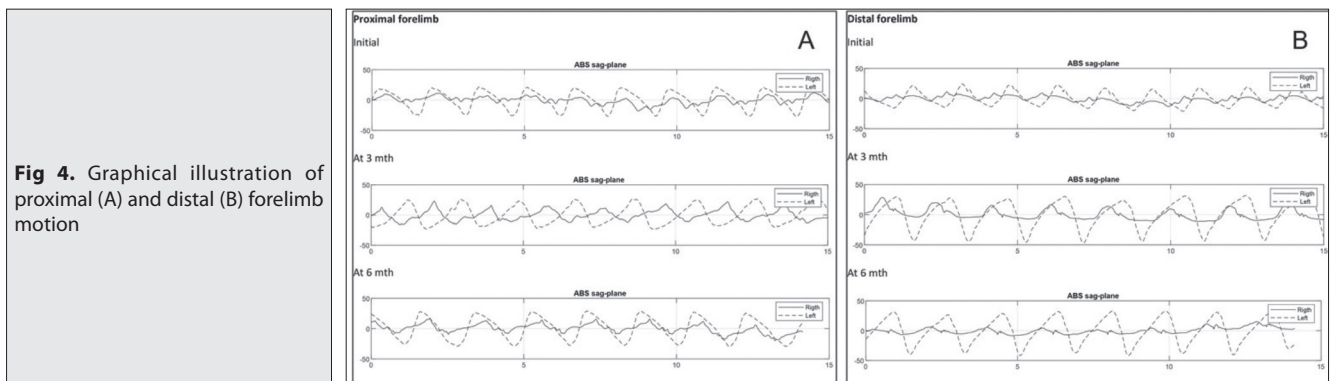
**Fig 2.** S-shaped scoliosis as a result of uneven weight distribution



**Fig 3.** Prosthetic shoe prototype made from latex foam

**Table 1.** Vital sign monitoring during daytime with the prosthetic shoe

Parameters	Normal Range	Minute				
		0	15	30	45	60
Body temperature (°C)	36-37 <sup>[4]</sup>	36.4	N/A	N/A	36.8	N/A
Respiratory rate (breath/min)	4-12 <sup>[5]</sup>	8	10	8	8	8
O <sub>2</sub> Saturation (%)	95-100	97	98	92	94	98
Pulse rate (beat/min)	25-30 <sup>[6]</sup>	50	54	57	61	61
Systolic blood pressure/Diastolic blood pressure (mmHg)	178.6±2.94/118.7±3.10 <sup>[7]</sup>	133/82	127/93	129/78	130/88	127/88
Mean blood pressure (mmHg)	144.6±2.9 <sup>[7]</sup>	95	103	90	101	98



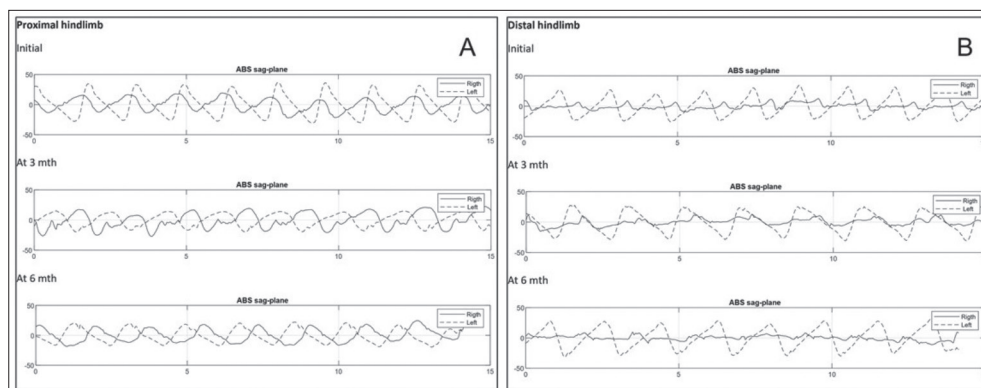
**Fig 4.** Graphical illustration of proximal (A) and distal (B) forelimb motion

she spent in the forest, which was 3-4 h per day, and the veterinarian team monitored changes of vital signs over 60 min of walking with it (Table 1). All the vital sign parameters, except for high pulse rate, were kept at the normal range, indicating that the elephant had no dyspnea and could maintain pulmonary gas exchange well. However, the heart rate in a young elephant is higher than that in an adult and this elephant could maintain a comparable heart rate from the start to finish of the 60-min walk. Therefore, it could be claimed that her overall physiological responses verified that wearing a prosthetic shoe for 60 min was no burden on her daily living.

### Biomechanics Gait Analysis

To quantify walking mobility while wearing the shoe, the biomechanics parameters of gait were analyzed using novel technology of three-dimensional (3D) inertial measurement units with wifi sensors<sup>[3]</sup>. Data were obtained after applying the shoe for three and six months. The elephant was guided to walk normally at a comfortable speed.

Graphical data demonstrated changes of absolute rotation angle over time, which enabled the movement of each joint segment of the forelimbs and hindlimbs to be



**Fig 5.** Graphical illustration of the proximal (A) and distal (B) hindlimb motion



**Fig 6.** The level of head and pelvis after applying the shoe for 6 months

monitored. *Fig. 4-A,B* demonstrates the forelimb motion, and illustrates that in the initial period, both the proximal and distal part of the left forelimb moved to a greater extent than the right one, showing a nonreciprocal pattern (shown in initial phase, *Fig. 4-A,B*). After 3 months, the proximal part seemed to move more symmetrically and synchronize with the right side. Nevertheless, after 6 months a synchronized pattern between left and right forelimbs occurred, and the left proximal part showed a wider range of movement than the right one.

Analysis of the hindlimb movement (*Fig. 5-A,B*) indicated that both proximal and distal parts of the right hindlimb moved in a very similar manner to the forelimb in the initial period. However, at 3 months, the proximal hindlimb moved more symmetrically and the magnitude of both sides was comparable. After 6 months, the magnitude of the left and right proximal hindlimbs was similar, but not reciprocal, whereas the distal part moved very closely to the forelimb in all movements of the gait cycle. For six-month period of wearing the artificial shoe, it showed promising potential benefits on structural changes. The S-shape twist of the back was to a lesser degree of scoliosis and the head was aligned more symmetry with the pelvis level (*Fig. 6*).

## DISCUSSION

Earlier evidence [8-10] and the authors' previous study [11] revealed that elephants use a lateral sequence footfall pattern and an inverted pendulum mechanism while walking in order to modulate the center of mass and conserve muscular activity. Even though, in this case, the gait cycle of the elephant was nonreciprocal in the initial period (*Fig. 4-A,B*), it should transit rhythmically between the two phases of footfall pattern. It was postulated that the elephant did not feel comfortable with the artificial limb, and thus moved the right forelimb faster, in order to distribute weight from the left side during the mid-stance period. The right proximal and distal parts of the hindlimb were found to move in a similar manner to the forelimb during the initial period. This might be a consequence of the coordination pattern of the interlimb, from which the elephant tries to conserve the lateral sequence footfall pattern of gait, providing the greatest stability and energy saving. In the three-month period, the proximal hindlimb movement pattern became better, as she familiarized herself with the prosthetic shoe. The proximal part moved more symmetrically and the magnitude of both sides was comparable. Nevertheless, after 6 months, asynchronized pattern between left and right forelimbs occurred again. The left proximal part showed a greater range of movement than the right one, whereas the distal part of the right side demonstrated less movement than the left one. The elephant was trying to keep the right limb rigid and comparable to the left one. Gate deviation could be due to a weathered shoe and increased body weight. Vital signs monitoring when walking with the shoe for at least 60 consecutive minutes indicated normal physiological responses, with no signs of exertion. During six months of wearing the shoe, no observable pressure ulcers on the soft tissue pad or uncomfortable behavior occurred. These findings demonstrated the quality of the shoe, which can restore basic lower-limb functions, i.e., stable support, energy storage and propulsion, and shock absorbance.

In conclusion, although the elephant is an important animal of Thailand, some of them suffer from injuries through many causes such as road accidents, and special care is needed afterwards. This report revealed the health and

QOL of an injured female baby elephant when a prosthetic shoe was applied. The ultimate goal of the prosthesis was to restore the elephant's walking capabilities and support its body weight in a comfortable manner as well as distribute mechanical stresses properly throughout the prosthetic and residual limb. Biomechanics analysis of gait using novel 3D motion analysis revealed promising benefits from wearing the shoe, with an asymmetrical to a more symmetrical gait pattern. Malalignment of the back was decreased to the degree of twist shape and the head was aligned with the pelvis level (Fig. 6). Nevertheless, the team will continue work in optimizing the prosthetic shoe, as many factors, i.e., materials with good quality of shock absorption and pressure distribution, should be taken into further consideration. Furthermore, intrinsic factors of the elephant should be concerned with rapid growth of the juvenile, thus bone density, blood calcium level monitoring and proper nutrition are required. Behavioral and emotional change, such as social behavior and sex interaction also should be observed closely.

#### CONFLICT OF INTEREST

The authors declared no conflict of interest.

#### ACKNOWLEDGEMENTS

The authors would like to acknowledge the Faculty of Engineering, Chiang Mai University and the Rubber Authority of Thailand for establishment of the shoe prototype. We also acknowledge the Department of Physical Therapy, Faculty of Associated Medical Sciences, Chiang Mai University for equipment support and extend gratitude to M.L.Pipattanachart Diskul, D.V.M. Royal Elephant Stable for the valuable suggestions and advice.

#### AUTHOR CONTRIBUTIONS

Conceptualization, S.K. and T.A.; methodology, S.K., K.W.

and T.A.; software, K.W.; resources, W.L., K.N., B.C. and P.P.; writing-original draft preparation, S.K. and B.C.; writing-review and editing, T.A. and K.W.

#### REFERENCES

- Perera VP, Silva-Flecher A, Jayawardena S, Kumudini N, Prasad T:** Rehabilitation of orphaned asian elephant (*Elephas maximus*) calves in Sri Lanka. *J Wildl Rehabil*, 38 (2): 13-24, 2018.
- Isaacs-Itua A, Sedki I:** Management of lower limb amputations. *Br J Hosp Med*, 79 (4): 205-210, 2018. DOI: 10.12968/hmed.2018.79.4.205
- Peansukmanee S, Thawinchai N, Khanproa P, Khaminluang P:** Feasibility study of inertial sensor technology on ponies for equine-assisted therapy (EAT). *Kafkas Univ Vet Fak Derg*, 23 (6): 871-878, 2017. DOI: 10.9775/kvfd.2017.17833
- Elder WH, Rodgers DH:** Body temperature in the African elephant as related to ambient temperature. *Mammalia*, 39, 395-399, 1975.
- Schmitt DL:** Proboscidea (Elephants). In: Fowler ME, Miller RE (Eds): Zoo and Wild Animal Medicine. 541-550, Elsevier Science, New York, 2003.
- Kock MD, Martin RB, Kock N:** Chemical immobilization of free-ranging African elephants (*Loxodonta africana*) in Zimbabwe, using etorphine (M99) mixed with hyaluronidase, and evaluation of biological data collected soon after immobilization. *J Zoo Wildl Med*, 24 (1): 1-10, 1993.
- Honeyman VL, Pettifer GR, Dyson DH:** Arterial blood pressure and blood gas values in normal standing and laterally recumbent African (*Loxodonta africana*) and Asian (*Elephas maximus*) elephants. *J Zoo Wildl Med*, 23 (2): 205-210, 1992.
- Genin JJ, Willems PA, Cavagna GA, Lair R, Heglund NC:** Biomechanics of locomotion in Asian elephants. *J Exp Biol*, 213 (5): 694-706, 2010. DOI: 10.1242/jeb.035436
- Ren L, Butler M, Miller C, Paxton H, Schwerda D, Fischer MS, Hutchinson JR:** The movements of limb segments and joints during locomotion in African and Asian elephants. *J Exp Biol*, 211 (17): 2735-2751, 2008. DOI: 10.1242/jeb.024364
- Hutchinson JR, Schwerda D, Famini DJ, Dale RHI, Fischer MS, Kram R:** The locomotor kinematics of Asian and African elephants: Changes with speed and size. *J Exp Biol*, 209 (19): 3812-3827, 2006. DOI: 10.1242/jeb.02443
- Kongsawasdi S, Mahasawangkul S, Pongsopawijit P, Boonprasert K, Chuatrakoon B, Thonglorm N, Kanta-In R, Tajareramuang T, Nganvongpanit K:** Biomechanical parameters of Asian elephant (*elephas maximus*) walking gait. *Kafkas Univ Vet Fak Derg*, 23 (3): 357-362, 2017. DOI: 10.9775/kvfd.2016.16653