

## CASE REPORT

# Treatment of a Post-Operative Infected Wound of a Cat with Maggot Debridement Therapy

Uğur USLU<sup>1,a</sup> Onur CEYLAN<sup>2,b(\*)</sup> Abdullah KÜÇÜKYAĞLIOĞLU<sup>3,c</sup> Hüseyin Koray AKDENİZ<sup>4,d</sup><sup>1</sup> Selçuk University, Faculty of Medicine, Department of Medical Microbiology, TR-42100 Konya - TURKEY<sup>2</sup> Selçuk University, Veterinary Faculty, Department of Parasitology, TR-42100 Konya - TURKEY<sup>3</sup> Selçuklu Municipality, TR-42100 Konya - TURKEY<sup>4</sup> Umutvet Veterinary Clinic, TR-42100 Konya - TURKEYORCID: <sup>a</sup> 0000-0003-3456-312X; <sup>b</sup> 0000-0002-3514-5221; <sup>c</sup> 0000-0002-4673-2480; <sup>d</sup> 0000-0003-4570-0353

Article ID: KVFD-2021-25861 Received: 06.04.2021 Accepted: 08.07.2021 Published Online: 11.07.2021

## Abstract

Maggot debridement therapy (MDT), which is an ancient remedy, has been reintroduced and commonly used to promote wound healing in humans. However, its use in the veterinary field has still remained limited. The aim of this case study was to evaluate the effectiveness of MDT on a non-healing post-operative infected wound covering the abdominal and inguinal regions of a 3-year-old male cat. For MDT, sterile first and second stage larvae of *Lucilia sericata* were applied to the infected wound for the first time on the 10th day after laparotomy. A total of five larva applications were performed during the MDT process. From the first to the last MDT application, the large and infected wound gradually shrank and healed. Sterile *L. sericata* larvae were successfully used in the treatment of a chronic and infected wound that did not respond to antibiotics in a cat in this case study. It is considered that the use of MDT for promoting healing in chronic necrotic and infected wounds will increase because of supplying effective, cost-efficient and simple wound care in future.

**Keywords:** Biotherapy, Cat, *Lucilia sericata*, Maggot, Wound

## Maggot Debridman Tedavi İle Bir Kedinin Post-operatif Enfekte Yarasının Sağaltımı

### Öz

Eskiden tedavi amacıyla kullanılan maggot debridman tedavisi (MDT) yeniden gündeme gelmiş ve insanlarda yara iyileşmesini teşvik etmek amacıyla kullanılmaya başlanmıştır. Ancak, bu yöntemin veteriner hekimlik alanında kullanımı sınırlıdır. Bu vaka sunumu, 3 yaşındaki erkek bir kedinin abdominal ve inguinal bölgelerini kapsayan, iyileşmeyen postoperatif enfekte bir yarada MDT'nin etkinliğini değerlendirmek amacıyla hazırlandı. MDT için ilk uygulama laparotomiden sonraki 10. günde yapıldı. Bu amaçla *Lucilia sericata* türü sineklerin steril birinci ve ikinci dönem larvaları kullanıldı. MDT sürecinde toplam beş adet larva uygulaması yapıldı. İlk MDT uygulamasından son MDT uygulamasına kadar, büyük ve enfekte olmuş yara yavaş yavaş küçülerek iyileşti. Steril *L. sericata* larvaları ile bir kedinin antibiyotiklere yanıt vermeyen kronik ve enfekte yarası başarılı bir şekilde sağaltıldı. Gelecekte etkili, uygun maliyetli ve basit yara bakımı sağlanması nedeniyle kronik, nekrotik ve enfekte yaralarda iyileşmeyi teşvik etmek amacıyla MDT kullanımının artacağı düşünülmektedir.

**Anahtar sözcükler:** Biyoterapi, Kedi, *Lucilia sericata*, Larva, Yara

## INTRODUCTION

*Lucilia sericata* (*Phaenicia sericata*) (Diptera: Calliphoridae) fly larvae have been known to remove necrotic tissues from wounds and accelerate wound healing for many years. The use of calliphorid fly larvae for the treatment

of chronic wounds is known as larval treatment, maggot debridement therapy (MDT), biosurgery or biotherapy<sup>[1,2]</sup>. *Lucilia sericata* flies can be grown in special laboratories where appropriate space, temperature and humidity are provided, and sterile maggots can be obtained when necessary<sup>[3]</sup>.

### How to cite this article?

**Uslu U, Ceylan O, Küçükyağlıoğlu A, Akdeniz HK:** Treatment of a post-operative infected wound of a cat with maggot debridement therapy. *Kafkas Univ Vet Fak Derg*, 27 (4): 539-542, 2021.  
DOI: 10.9775/kvfd.2021.25861

### (\*) Corresponding Author

Tel: +90 332 223 3598

E-mail: [onurceylan@selcuk.edu.tr](mailto:onurceylan@selcuk.edu.tr) (O. Ceylan)



This article is licensed under a Creative Commons Attribution-NonCommercial 4.0 International License (CC BY-NC 4.0)

Medicinal maggots have various beneficial effects on wounds. These can be listed as debridement, disinfection of the wound through microbial killing and promotion of wound healing [2,4].

Maggot debridement therapy was firstly used successfully in a patient with chronic osteomyelitis in 1931 [5]. Although MDT was used frequently in those times, the number of MDT applications decreased due to the widespread use of antibiotics and intensive surgical treatments. However, MDT has been started to reapply in countries such as the USA, Germany, Austria, England, Israel and Sweden to treat non-healing chronic wounds and has become popular again from the late 20<sup>th</sup> century [1,6]. Although MDT has been used to treat chronic wounds in humans for many years [7-9], its use in veterinary medicine is limited. However, it has also been widely applied in the field of veterinary medicine in recent years, and different types of wounds can be treated by MDT in animals [10-15].

This case study was conducted to evaluate the effectiveness of MDT in the treatment of a non-healing post-operative infected wound in a cat, despite an antibiotic treatment for a long time. Maggot debridement therapy has been used in the wound of humans for many years, but there is no study on the application of MDT in animals in Turkey.

## CASE HISTORY

The material of this case study consisted of a 3-year-old male cat with a post-operative infected wound covering the abdominal and inguinal region as a result of laparotomy performed for cryptorchitis. Systemic antibiotics such as ceftriaxone (Unacefin® 1 g IM Flakon, Yavuz İlaç San. Tic. A.Ş., İstanbul, Turkey) and enrofloxacin (Baytril-K® 5% 50 mL, Injectable solution Bayer) were used for wound care, but no improvement was observed. Thereupon, it was decided to benefit from MDT, which has commonly been used in human medicine in recent years. For this purpose, the approval of the owner of the cat was also obtained. Sterile I. and II. instars of *L. sericata* used in the case study (Fig. 1) were supplied from Selçuk University, Faculty of Veterinary Medicine, Maggot Production Unit.

On the 10<sup>th</sup> day after laparotomy, the first application of sterile I. and II. instars of *L. sericata* was applied to the infected wound. A light surgical debridement to prepare the wound was used before application. The size of the wound was determined (7-8 x 10-12 cm), and the wound edges were demarcated after shaving and disinfecting. The wound was washed with physiological saline solution and a total of almost 1000 sterile I. and II. instars of *L. sericata* were left on the wound. Approximately 8 to 10 maggots per square centimeter were used. Then, the wound was covered with a gauze patch, and the edges of the wound were pasted to prevent the escape of maggots from the wound. The second and third maggot applications were

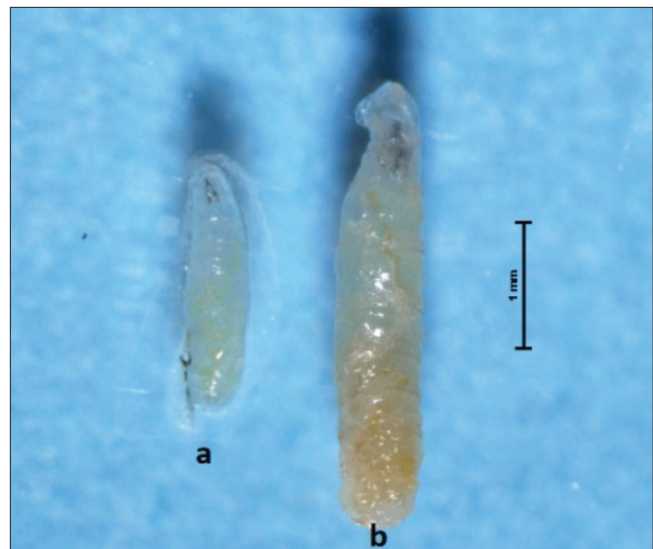


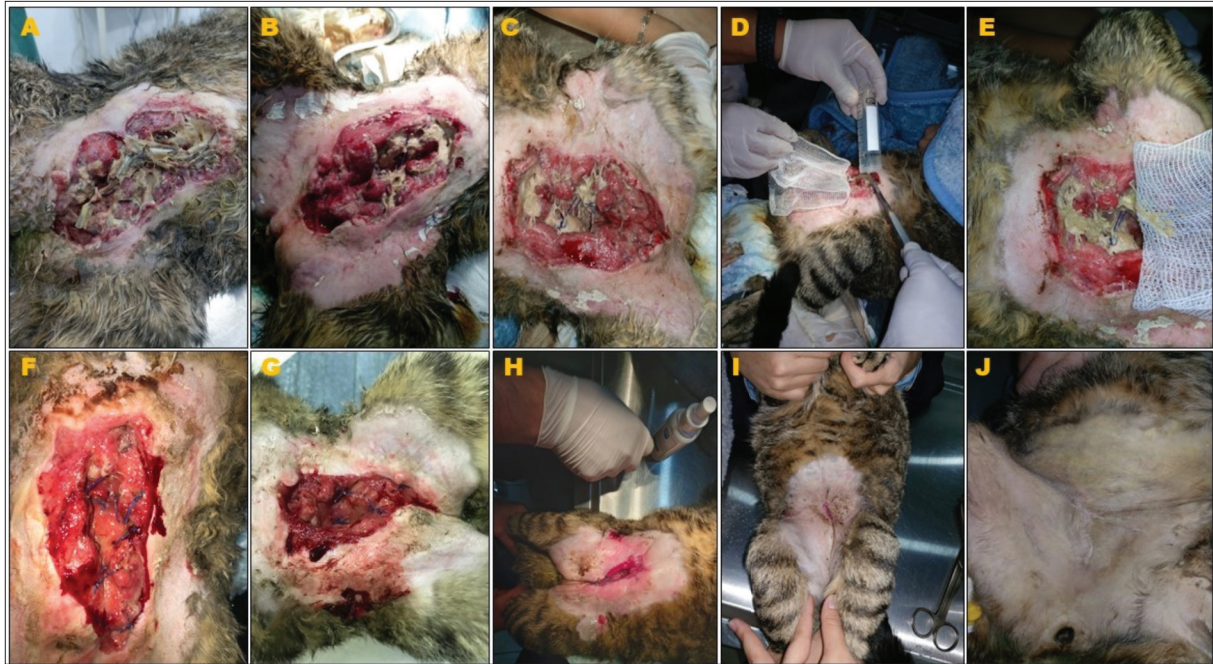Fig 1. First and second stage larvae of *L. sericata*

made by repeating the same procedures at the 24<sup>th</sup> and 48<sup>th</sup> h after the first maggot application. Later, the MDT application was paused for a week, and the fourth and fifth maggot applications were made at one-day intervals. Systemic antibiotic (ceftriaxone and enrofloxacin) administrations continued during the MDT procedures. The large and infective wound of the cat gradually shrank and healed during the process of MDT applications. After the last MDT application, there was a tiny opening in the wound, and this opening completely closed after one and a half months. During the treatment, the cat was supported every day with liquid electrolytes and vitamin, mineral and amino acid complexes. Moreover, some sprays such as Dr. Animal (Farmaso İlaç San. Tic. A.Ş., İstanbul/Turkey) and Acto® Vet Solution (Acto Pharma Hijyen San. Tic. A.Ş., İstanbul/Turkey) were daily used for wound care. The status of the wound and the maggot applications are indicated in Fig. 2.

## DISCUSSION

The fly larvae have been used to debride necrotic tissues since the beginning of civilisation. For this purpose, facultative calliphorids' larvae are the most commonly used fly larvae, with the sterile larvae of *L. sericata*, colloquially known as green bottle blowfly, being the most widely used fly species [7].

Freshly emerged germ-free maggots of *L. sericata* can be applied to a necrotic wound in two different ways: direct and indirect contact techniques. Free-range maggots (I. or II. instars of *L. sericata*) are deposited directly onto the wound's surface in the direct contact technique. In this technique, after the larvae are placed onto the surface of the wound, the wound is restricted with a nylon retention net or gauze bandage to prevent the escape of larvae from the wound. On the other hand, maggots are applied



**Fig 2.** A: The status of the wound before MDT, B and C: The appearance of the wound after the First and second maggot application, D and E: Steps of third maggot application, F: The appearance of the wound after the third maggot application, G: The appearance of the wound after the fourth maggot application, H: The appearance of the wound after the fifth maggot application, I and J: The appearance of the wound area after MDT

on the wound's surface within a bio bag in the indirect contact technique [16]. Mumucuoglu and Taylan Özkan [1] noted that the maggots within the bio bags could not thoroughly debride the necrotic tissues. Therefore, the direct contact technique was preferred considering the size of the wound and the condition of the necrotic tissues in the current case study.

Maggot debridement therapy is widely used in human medicine. Chan et al. [17] listed the types of wounds or lesions for which maggot therapy may be used in humans as follows; arterial/ischaemic ulcers, diabetic ulcers, neuropathic ulcers, venous ulcers, mixed arterial-venous ulcers, burns, excised abscess on malleolus, grossly infected toe, infected wound after forearm replantation, infected gunshot wound, infected wounds after breast surgery, osteomyelitis, malignant wounds, non-healing surgical wounds, subacute mastoiditis, Methicillin resistant *Staphylococcus aureus*-infected wounds, necrotising fasciitis, pilonidal sinus, pyoderma gangrenosum, post traumatic wounds/ulcers, pressure sores, thromboangiitis obliterans, wound of exposed knee prostheses. MDT has been used in the treatment of various types of wounds, especially chronic wounds caused by diabetes in humans in Turkey [7-9,18]. MDT has also successfully been applied in veterinary medicine, but the number of MDTs applied in veterinary medicine is lower than that of human medicine [19]. In the veterinary field, studies have reported that MDT has been used for the treatment of panniculitis in donkeys [10], laceration of the limbs, soft tissue abscess and wounds, fistulous withers, dehiscence of *linea alba*, and other musculoskeletal

infections, laminitis and other foot pathology in horses [12,14,15], foot root and foot scald in sheep [11], pressure ulcer and gunshot wound in dogs [13], necrotic tumour and multiple bite wound in cats [13]. As a result of the literature search, MDT application in animals has not been encountered in Turkey. In the present study, MDT was used in a cat with a post-operative infected wound covering the abdominal and inguinal region, and the wound almost completely healed after five maggot applications. Sherman et al. [13] stated that MDT provides debridement of wounds of cats and dogs, which are expected to be amputated or euthanized, and these animals regained their health. This case study demonstrates once again that the cat with a chronic infected wound can be successfully treated with MDT. It should not be forgotten that MDT is an important alternative treatment option to be used to treat such wounds in the veterinary field.

Maggot debridement therapy can be supported with different additional applications by different researchers. Arshadniya et al. [20] stated that the combination of MDT with topical or oral antibiotics effectively provided the elimination of infected tissues and the regeneration of new tissues. Therefore, antibiotics and various supportive treatments were used to contribute to the healing process of the infected wound in the present study.

In conclusion, maggot debridement therapy is an effective, fast, and safe method for the debridement of wounds. Considering the increase in antibiotic resistance to infections, MDT is one of the most important and cost-effective



treatment options. It is thought that MDT will be used more for the treatment of non-healing chronic wounds of animals in Turkey in the future.

### CONFLICT OF INTEREST

The authors declare that there is no conflict of interest.

### ACKNOWLEDGMENTS

This case report has not previously been presented at any scientific meeting, either in whole or in part, and no financial support has been received. All applications in the study were carried out with the approval of the Experimental Animals Production and Research Center Ethics Committee of Selçuk University, Faculty of Veterinary Medicine (SÜVDAMEK-2021/31).

### STATEMENT OF AUTHOR CONTRIBUTIONS

UU designed to apply maggot debridement therapy. OC and AK produced the sterile maggots for application. OC and HKA applied maggots to the wound. UU and OC wrote the manuscript. All authors read and approved the final form of the manuscript.

### REFERENCES

- Mumcuoğlu KY, Taylan Özkan A:** The treatment of suppurative chronic wounds with maggot debridement therapy. *Türkiye Parazitoloj Derg*, 33 (4): 307-315, 2009.
- Nair HKR, Ahmad NW, Teh CH, Lee HL, Chong SSY:** Maggot debridement therapy in Malaysia. *Int J Low Extrem Wounds*, 2020: 1534734620932397: 1-9, 2020. DOI: 10.1177/1534734620932397
- Gasz NE, Harvey ML:** A new method for the production of sterile colonies of *Lucilia sericata*. *Med Vet Entomol*, 31, 299-305, 2017. DOI: 10.1111/mve.12232
- Kenawy MA, Abdel-Hamid YM:** Maggot therapy "Use of fly larvae for treatment of wounds"- A review. *Egypt Acad J Biol Sci*, 12 (2): 1-10, 2020. DOI: 10.21608/eajbse.2020.104166
- Bazalinski D, Kozka M, Karnas M, Wiech P:** Effectiveness of chronic wound debridement with the use of larvae of *Lucilia sericata*. *J Clin Med*, 8:1845, 2019. DOI: 10.3390/jcm8111845
- Baer WS:** The treatment of chronic osteomyelitis with the maggot (larva of the blow fly). *J Bone Joint Surg*, 13, 438-475, 1931.
- Nigam Y, Bexfield A, Thomas S, Ratcliffe NA:** Maggot therapy: The science and implication for CAM part I-History and bacterial resistance. *Evid Based Complement Alternat Med*, 3 (2): 223-227, 2006. DOI: 10.1093/ecam/nel021
- Tanyüksel M, Koru Ö, Araz RE, Kılbaş HZG, Yıldız Ş, Alaca R, Ay H, Şimşek K, Yıldız C, Yurttaş Y, Demiralp B, Devenci M, Beşirbellioğlu BA:** Applications of sterile larva of *Lucilia sericata* for the treatments of chronic wounds. *Gülhane Tıp Derg*, 56, 218-222, 2014. DOI: 10.5455/gulhane.173024
- Yıldız Ş, Tanyüksel M, Araz E, Taner ÖT, Coşkun Ö, Yurttaş Y, Uzun G:** Biological debridement with maggots in chronic wounds: A case series. *TAF Prev Med Bull*, 15 (4): 336-341, 2016.
- Bell NJ, Thomas S:** Use of sterile maggots to treat panniculitis in an aged donkey. *Vet Rec*, 149, 768-770, 2001. DOI: 10.1136/vr.149.25.768
- Kocisova A, Pistl J, Link R, Conkova E, Goldova M:** Maggot debridement therapy in the treatment of Footrot and Foot Scald in sheep. *Acta Vet Brno*, 75, 277-281, 2006. DOI: 10.2754/avb200675020277
- Sherman RA, Morrison S, Ng D:** Maggot debridement therapy for serious horse wounds - A survey of practitioners. *Vet J*, 174 (1): 86-91, 2007. DOI: 10.1016/j.tvjl.2006.05.012
- Sherman RA, Stevens H, Ng D, Iversen E:** Treating wounds in small animals with maggot debridement therapy: A survey of practitioners. *Vet J*, 173, 138-143, 2007. DOI: 10.1016/j.tvjl.2005.11.006
- Morrison S:** Maggot debridement therapy for laminitis. *Vet Clin North Am Equine Pract*, 26 (2): 447-450, 2010. DOI: 10.1016/j.cveq.2010.06.002
- Lepage OM, Doumbia A, Perron-Lepage MF, Gangl M:** The use of maggot debridement therapy in 41 equids. *Equine Vet J*, 44 (S43): 120-125, 2012. DOI: 10.1111/j.2042-3306.2012.00609.x
- Fleischmann W, Grassberger M, Sherman R:** Maggot therapy: A handbook of maggot-assisted wound healing. 85, Georg Thieme Verlag, Stuttgart, 2004.
- Chan DCW, Fong DHF, Leung JYY, Patil NG, Leung GKK:** Maggot debridement therapy in chronic wound care. *Hong Kong Med J*, 13, 382-386, 2007.
- Taylan Özkan A, Mumcuoğlu KY:** Maggot debridement therapy for the treatment of a venous stasis ulcer. *Türk Hij Den Biyol Derg*, 64 (1): 31-34, 2007.
- Gul E, Nurullazade Y, Kaya E:** Larva treatment from past to present in chronic wounds. *IJTCMR*, 1 (3): 154-161, 2020.
- Arshadniya I, Ranganna K, Yousefipour Z:** A case report of the at-home application of maggot in treatment of infected wound in a diabetic patient. *Int J Complement Alt Med*, 8 (1): 00250, 2017. DOI: 10.15406/ijcam.2017.08.00250