

## CASE REPORT

# A Case of Ventral Abdominal Hernia Associated with an Ectopic Egg in an Albino Budgerigar and Evaluation by Infrared Thermography

Buse ERSENAL<sup>1,a</sup>(\*) Serhat ÖZSOY<sup>2,b</sup>

<sup>1</sup> Department of Obstetrics and Gynecology, Faculty of Veterinary Medicine, Istanbul University-Cerrahpaşa, TR-34320 Avcılar, Istanbul - TURKEY

<sup>2</sup> Department of Wild Animal Diseases and Ecology, Faculty of Veterinary Medicine, Istanbul University-Cerrahpaşa, TR-34320 Avcılar, Istanbul - TURKEY  
ORCID: <sup>a</sup> 0000-0003-2404-2988; <sup>b</sup> 0000-0003-0988-7691

Article ID: KVFD-2020-25113 Received: 28.10.2020 Accepted: 02.02.2021 Published Online: 03.02.2021

## Abstract

A four-year-old albino budgerigar was presented to Department of Wild Animal Diseases and Ecology clinic, Faculty of Veterinary Medicine, Istanbul University-Cerrahpaşa, with complaints of abdominal swelling. An ectopic egg and abdominal hernia were diagnosed as a result of radiographic evaluation, and then the hairless, swollen abdominal surface area was evaluated by infrared thermography. In a budgerigar, an abdominal hernia case with ectopic egg was presented for the first time and evaluated for the first time by thermography. In thermographic imaging, the maximum temperature was obtained from the skin surface area on the right side of the hernia sac corresponding to the area where the egg was found on the radiograph. It is thought that heat increase has occurred due to inflammatory fibrin formation process around the ectopic egg. Clinical parameters of the patient were in normal range so the surgical operation was successfully performed under general anesthesia, and the ectopic egg was removed and the abdominal hernia was repaired.

**Keywords:** Thermography, Budgerigar, Ectopic egg, Abdominal hernia

## Bir Albino Muhabbet Kuşunda Ektopik Yumurta İle İlişkili Ventral Abdominal Fıtık Olgusu ve Kızılötesi Termografi İle Değerlendirilmesi

### Öz

Dört yaşındaki albino muhabbet kuşu, İstanbul Üniversitesi-Cerrahpaşa, Veteriner Fakültesi Yabani Hayvan Hastalıkları ve Ekoloji Anabilim Dalı kliniğine karın şişliği şikayeti ile getirildi. Radyografik değerlendirme sonucu ektopik yumurta ve ventral abdominal fıtık varlığı teşhis edildi ve daha sonra kızılötesi termografi ile tüysüz, şişmiş karın yüzeyi değerlendirildi. Muhabbet kuşunda, ektopik yumurta ile birlikte görülen abdominal fıtık olgusu ilk kez sunuldu ve termografi ile ilk kez değerlendirildi. Termografik görüntülemeye, yumurtanın röntgende bulunduğu alana karşılık gelen, fıtık kesesinin sağ tarafındaki deri bölgesi yüzeyinden maksimum sıcaklık elde edildi. Ektopik yumurta çevresindeki enflamatuvar fibrin oluşum süreci nedeniyle ısı artışının meydana geldiği düşünülmektedir. Hastanın klinik parametreleri normaldi, bu nedenle cerrahi operasyon genel anestezi altında başarıyla uygulandı, ektopik yumurta uzaklaştırıldı ve karın fıtığı onarıldı.

**Anahtar sözcükler:** Ektopik yumurta, Karın fıtığı, Muhabbet kuşu, Termografi

## INTRODUCTION

Egg production, together with the complex structure of the female sex organs, causes reproductive diseases<sup>[1]</sup>. Eggs called "ectopic eggs" or "internal laying", they become extraoviductal due to reverse peristalsis in the infundibulum or rupture of the oviduct and fall into the abdominal cavity<sup>[2,3]</sup>. Therefore, egg binding and ectopic

egg reproductive diseases may show similar clinical signs in birds such as abdominal enlargement, soiled feathers at the vent and base of the tail, retention of droppings and tail pumping<sup>[2,4]</sup>. An abdominal hernia appears in relation with egg laying and weak abdominal muscles in Psittacine species especially budgerigars with clinical signs of abdominal swelling and skin surface changes<sup>[5,6]</sup>.

### How to cite this article?

**Ersenal B, Özsoy S:** A case of ventral abdominal hernia associated with an ectopic egg in an albino budgerigar and evaluation by infrared thermography. *Kafkas Univ Vet Fak Derg*, 27 (2): 265-269, 2021.  
DOI: 10.9775/kvfd.2020.25113

### (\*) Corresponding Author

Tel: +90 507 338 9119

E-mail: [buse\\_ersenal@hotmail.com](mailto:buse_ersenal@hotmail.com) (B. Ersenal)



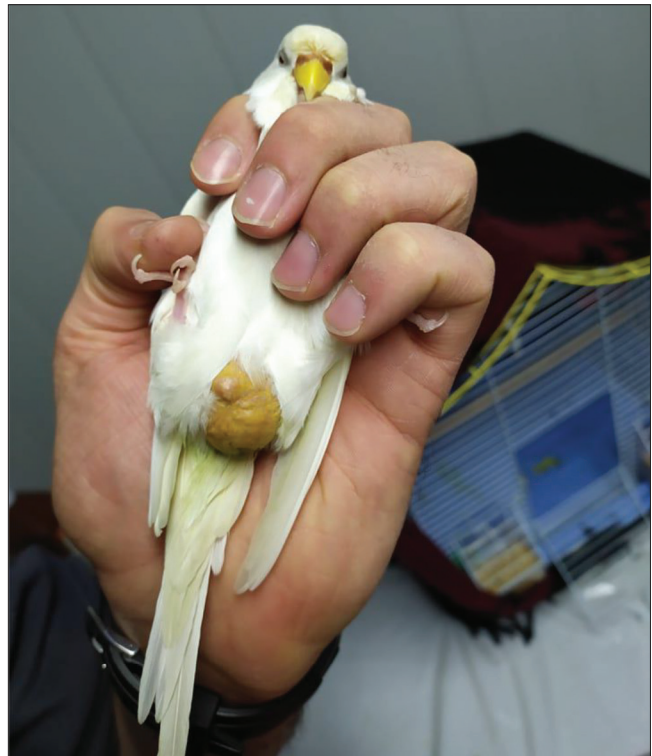
This article is licensed under a Creative Commons Attribution-NonCommercial 4.0 International License (CC BY-NC 4.0)

Egg-binding, ectopic egg, ectopic egg yolk and peritonitis cases require application of female reproductive system surgery for urgent intervention; and also hernia also requires the hernioraphy, after radiological diagnosis [1,6-10]. Radiological diagnosis shows where the egg is located in the abdominal cavity and what the hernial content is [3,11]. Infrared thermography is a complementary diagnostic method that can evaluate temperature changes on the body surface and in many animal species it is becoming more and more important in the diagnosis of various types of diseases [12-15]. Also, in avian research, there have been many studies involving the welfare and physiological thermal images of birds [16-20]. In this study, the presence of a ventral abdominal hernia simultaneously with an ectopic egg in a budgerigar and its evaluation by thermography is presented for the first time.

### CASE HISTORY

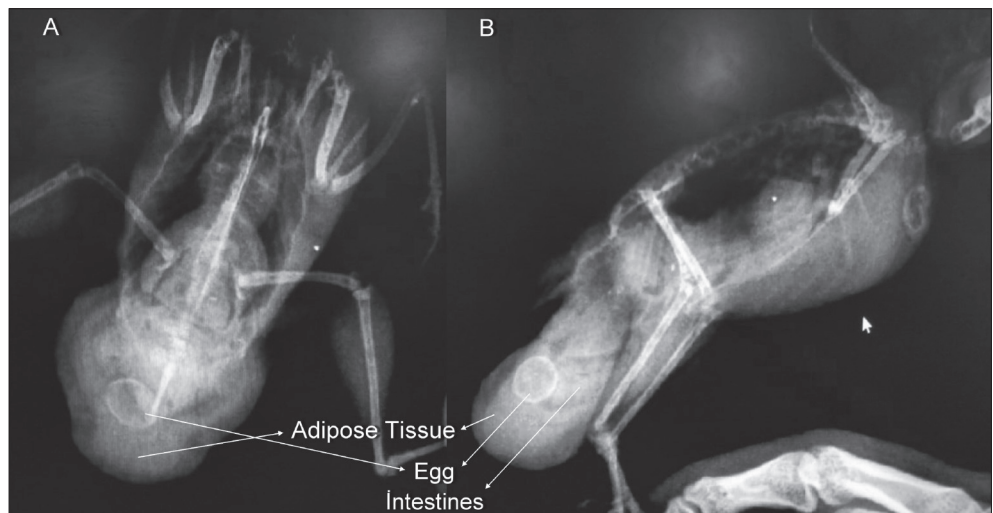
A four-year-old albino budgerigar was referred with one month history of abdominal swelling. On physical examination; pulse rate (272 beats/min), respiratory rate (65 breaths/min) and general state of the bird were in normal ranges but spherical swelling was located in the ventral abdomen and pericloacal region (Fig. 1). Her diet consisted of a commercially available food rich for seeds, and her appetite and defecation were normal and she was not laying for two years according to anamnesis. After physical examinations, radiographic and then thermographic evaluation by FLIR Series E50 (FLIR Systems AB) were obtained. According to the radiograph findings, intestines and an egg were detected in the hernia sac (Fig. 2). Thermography detects the points that give the maximum and minimum temperature in the scanned area. In thermograms, the warmest areas appear as white, the coldest areas as blue and black [13]. In this case, when the entire hernia sac was scanned by thermography (Fig. 3), it was found that the area was wider and white in color (warmer) at the right side, and also red spot showed the

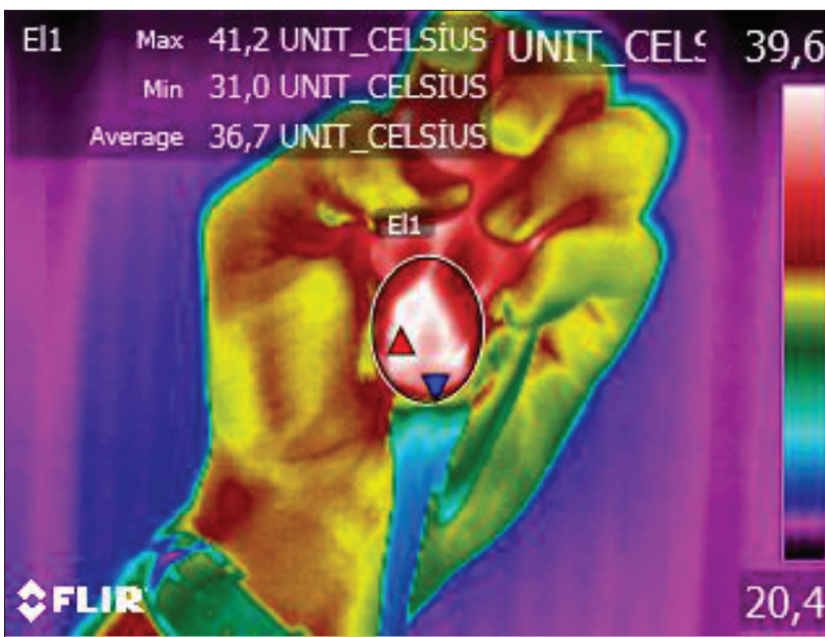
maximum temperature (41.2°C), which corresponded to the area where the egg was radiographically determined. The thermal image was taken at a distance of 40 cm from the un-feathered swollen area and the emission rate was taken from 0.96. Based on the clinical and radiographic examinations, it was decided that surgical application should be performed. Antibiotic (Amoklavin Ped. 100 mg/kg PO, for 2 days, Deva, Turkey) was provided before surgery. A bird was restrained in dorsal recumbency under the 2% isoflurane anesthesia and oxygen 2L through a breathing mask. Serum supplementation was applied during the operation (%5 Dekstroz Laktatlı Ringer 1 mL SC, PF, Turkey). The skin was prepared for an aseptic operation



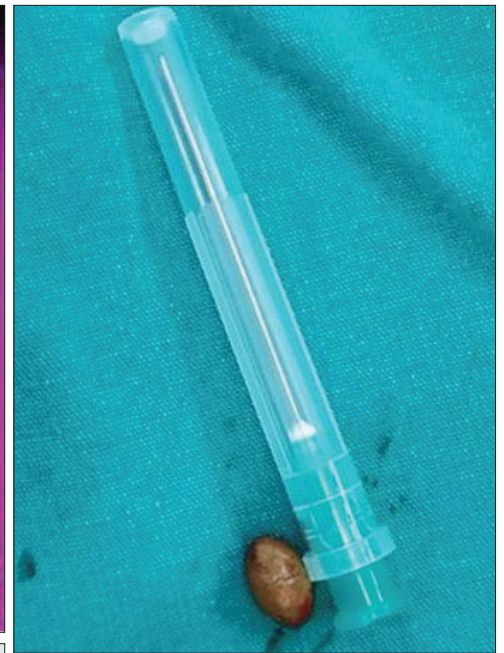**Fig 1.** An albino budgerigar with abdominal swelling

**Fig 2.** On the ventrodorsal (A) and right laterolateral radiographs (B); intestines and egg are visible in the hernia sac






**Fig 3.** Thermographic evaluation of abdominal hernia. Red spot shows the maximum temperature for egg region.\*Color should be used for this figure in print



**Fig 4.** Ectopic egg removed from the coelomic cavity



**Fig 5.** Bird stood up half an hour after surgery

and surgical intervention with transabdominal incision through the skin and abdominal muscles ensured. After the incision, the ectopic egg surrounded by the fibrin mesh first appeared in the hernia sac, and the intestines were behind it. The egg (Fig. 4) and fibrin mesh were first removed, then all the contents were returned to the abdominal cavity, the size of the swollen hernia sac reduced by incisions for normal size and the abdominal wall closure was successfully performed. Both the abdominal muscles

and the incision line were sutured by a simple continuous suture pattern using No. 4/0 monocryl. Pain reliever meloxicam (Meloxicam 0.5 mg/kg SC, Bavet, Turkey) was given and the bird stood up half an hour after surgery (Fig. 5). Amoxicillin clavulanic acid (Amoklavin Ped. 100 mg/kg PO, for 5 days, Deva, Turkey), multivitamin and calcium supplements were prescribed. Vegetables were added to the diet and movement restriction recommended. Five days after the operation, her general condition improved and she regained her health.

## DISCUSSION

The presence of an ectopic egg is vital in small birds [4]. Ectopic eggs may easily move around the abdomen or the egg yolk may enter the abdominal cavity and cause yolk peritonitis [3,9]. Chronic laying, oviductal trauma, or oviductal infection are common causes for ectopic eggs, egg-binding and egg-related coelomitis [2]. Poor breeding conditions and stress, especially hypocalcemia, systemic diseases, oviduct muscle weakness, genetic predisposition may also predispose factors [3,21]. Clinical signs include broody or egg-laying behavior without egg production, abdominal distention, soiled feathers at the vent and base of the tail, tail wagging, imbalance, sit on the floor, obturator paresis, oxygen deficiency and at the end death [2,22]. Good prognosis depends on the correct treatment done in time [22]. Abdominal hernias in birds can be congenital or acquired and often associated with reproduction, egg binding or straining, endocrine imbalances, hormonal effects, other causes such as hepatic lipidosis, malnutrition, coelomic masses, and urate concretion [23,24]. In this case, the ectopic egg, which was perceived as a mass in the coelomic cavity,

was thought to trigger hernia development. Abdominal hernias in birds are not true hernias because there is no opening in the aponeurosis of abdominal muscles so skin was the only hernia sac structure holding the content of abdominal organs [24]. Radiographic and ultrasonographic examinations are used to visualize the hernia content and egg to confirm the diagnosis [11,25]. Infrared thermography, which is a developing diagnostic method of assessing surface emitted temperature, is in the field of obstetrics and gynecology, in different races, in the evaluation of different pathological and physiological conditions such as mastitis, mammary tumors, detection of oestrus, pregnancy and omphalitis [13-15,26-30]. However, according to our research thermography has not been studied in avian reproductive diseases. Because the well feathered areas are closer to the ambient temperature, the region that gives the most accurate surface temperature in avian species is the unfeathered regions [16]. In this case, the image was easily taken, as the enlarged sac was unfeathered. Infrared thermography is able to discover changes that have not yet caused clinical signs in apparently healthy subjects and provides significant advantages thanks to its ability to measure surface temperature remotely, non-invasively and quickly in crowded bird populations [16,31]. For normal tissue repair due to peritoneal injury, an inflammatory reaction is initiated that produces fibrous exudates and causes fibrin formation [10,32]. In the formed fibrin, erythrocytes, leukocytes and platelets make a network that accumulates, thereby forming a blood clot [33]. In this case, the ectopic egg appears to be perceived as a foreign body causing irritation in the coelom and initiated the inflammatory fibrin formation process as a result of immune response. It is thought that due to these active reactions in the region, there is an increase in temperature at that point compared to other hernia sac skin areas and is reflected as maximum temperature in the thermographic image obtained. The reason why the detected temperature is not higher; It may be because it is in the process of chronic inflammation, not acute. It is concluded that by reporting this case in birds, ectopic egg can trigger hernia development and can be successfully treated with surgical intervention. Infrared thermography, may have the potential to detect pathological changes in the abdominal cavity, such as ectopic eggs, as a complementary diagnostic tool. But this study is the first study in the field of avian obstetrics and gynecology to evaluate a pathological condition by infrared thermography so more studies on this issue are needed to speak more clearly.

### CONFLICT OF INTEREST

The authors report no conflicts of interest.

### AUTHOR CONTRIBUTIONS

The authors alone are responsible for the content and writing of this case report.

### REFERENCES

- Hasholt J:** Diseases of the female reproductive organs of pet birds. *J Small Anim Pract*, 7 (4): 313-320, 1966. DOI: 10.1111/j.1748-5827.1966.tb04448.x
- Jenkins JR:** Surgery of the avian reproductive and gastrointestinal systems. *Vet Clin North Am Exot Anim Pract*, 3 (3): 673-692, 2000. DOI: 10.1016/s1094-9194(17)30069-5
- McMillan MC:** Imaging of avian urogenital disorders. *AAV Today*, 2 (2): 74-82, 1988. DOI: 10.2307/30134405
- Gorham SL, Akins M, Carter B:** Ectopic egg yolk in the abdominal cavity of a cockatiel. *Avian Dis*, 36 (3): 816-817, 1992. DOI: 10.2307/1591792
- Harrison GJ, Harrison LR:** Clinical Avian Medicine and Surgery. 225, WB Saunders, Philadelphia, 1998.
- Parrah JD, Dar KH, Athar H, Qureshi B:** Surgical management of abdominal hernia in a duck (*Anas Platyrhynchos*). *Mathews J Vet Sci*, 1 (1): 002, 2016.
- Gunduz MC, Toydemir S, Enginler SÖA, Yılmaz ÖT, Yigit F, Ucmak M:** Hysterectomy operation for the treatment of the egg binding in the Lovebird (*Agapornis comprise*): Case report. *J Fac Vet Med Istanbul Univ*, 35 (1): 43-48, 2009.
- Mans C, Sladky KK:** Clinical management of an ectopic egg in a Timneh African grey parrot (*Psittacus erithacus timneh*). *J Am Vet Med Assoc*, 242 (7): 963-968, 2013. DOI: 10.2460/javma.242.7.963
- Harrison GJ:** Reproductive medicine. In, Harrison GJ and Harrison LR (Eds): Clinical Avian Medicine and Surgery. 620-634, WB Saunders, Philadelphia, 1986.
- Smolec O, Kos J, Vnuk D, Babic T, Bottegaro NB:** Abdominal ventral hernia in a pigeon (*Columba livia*): A case report. *Vet Med*, 54 (6): 291-294, 2009. DOI: 10.17221/89/2009-vetmed
- Amer MS, Hassan EA, Torad FA:** Radiographic and ultrasonographic characteristics of ventral abdominal hernia in pigeons (*Columba livia*). *J Vet Med Sci*, 80 (2): 292-296, 2018.
- Rekant SI, Lyons MA, Pacheco JM, Artz J, Rodriguez LL:** Veterinary applications of infrared thermography. *Am J Vet Res*, 77 (1): 98-107, 2016. DOI: 10.2460/ajvr.77.1.98
- Durrant BS, Ravida N, Spady T, Cheng A:** New technologies for the study of carnivore reproduction. *Theriogenology*, 66 (6-7): 1729-1736, 2006. DOI: 10.1016/j.theriogenology.2006.02.046
- Colak A, Polat B, Okumus Z, Kaya M, Yanmaz LE, Hayirli A:** Short communication: Early detection of mastitis using infrared thermography in dairy cows. *J Dairy Sci*, 91 (11): 4244-4248, 2008. DOI: 10.3168/jds.2008-1258
- Cebulj-Kadunc N, Frangež R, Kruljč P:** Infrared thermography in equine practice. *Vet Stanica*, 51 (2): 109-116, 2020. DOI: 10.46419/vs.51.2.1
- McCafferty DJ:** Applications of thermal imaging in avian science. *Ibis*, 155 (1): 4-15, 2013. DOI: 10.1111/ibi.12010
- Edgar JL, Lowe JC, Paul ES, Nicol CJ:** Avian maternal response to chick distress. *Proc R Soc B*, 278, 3129-3134, 2011.
- Soroko M, Zaborski D:** Investigation of the effects of probiotic, *Bacillus subtilis* on stress reactions in laying hens using infrared thermography. *Plos One*, 15(6): e0234117, 2020. DOI: 10.1371/journal.pone.0234117
- Giloh M, Shinder D, Yahav S:** Skin surface temperature of broiler chickens is correlated to body core temperature and is indicative of their thermoregulatory status. *Poult Sci*, 91, 175-188, 2012. DOI: 10.3382/ps.2011-01497
- Wilcox CS, Patterson J, Cheng HW:** Use of thermography to screen for subclinical bumblefoot in poultry. *Poult Sci*, 88, 1176-1180, 2009. DOI: 10.3382/ps.2008-00446
- Yaqoob AB, Rashid DR, Omer D, Kipjen SL, Ajaz A, Abhishek K, Kishan PJ, Kumar GS:** Egg binding in female Budgerigar (*Melopsittacus undulatus*): Case report. *SKUAST J Res*, 21 (1): 112-113, 2019.
- Reddy BS, Sivajothi S:** Egg binding in Budgerigar (*Melopsittacus undulatus*)-an emergency condition. *Int J Avian Wildl Biol*, 3 (5): 352-

## Case Report

353, 2018. DOI: 10.15406/ijawb.2018.03.00119

**23. Bennet R.A:** Soft tissue surgery. In, Ritchie BW, Harrison GJ, Harisson LR (Eds): Avian Medicine: Principles and Application. 1097-1136, Lake Worth FL, Wingers Publishing; 1994.

**24. Jahromi AR, Nazhvani SD, Haddadi S:** Ventral abdominal hernia in a common Myna (*Acridotheres tristis*) - A case report. *Vet Arhiv*, 79 (6): 621-625, 2009.

**25. Rosen LB:** Avian reproductive disorders. *J Exot Pet Med*, 21 (2): 124-131, 2012. DOI: 10.1053/j.jepm.2012.02.013

**26. Topalidou A, Ali N, Sekulic S, Downe S:** Thermal imaging applications in neonatal care: A scoping review. *BMC Pregnancy Childbirth*, 19:381, 2019. DOI: 10.1186/s12884-019-2533-y

**27. Shecaira CL, Seino CH, Bombardelli JA, Reis GA, Fusada EJ, Azedo MR, Benesi FJ:** Using thermography as a diagnostic tool for omphalitis in newborn calves. *J Therm Biol*, 71, 209-211, 2018.

**28. Pavelski M, Silva DM, Leite NC, Junior DA, De Sousa RS, Guérios SD, Dornbusch PT:** Infrared thermography in dogs with mammary tumors and healthy dogs. *J Vet Intern Med*, 29 (6):1578-1583, 2015. DOI:

10.1111/jvim.13597

**29. Talukder S, Kerrisk KL, Ingenhoff L, Thomson PC, Garcia SC, Celi P:** Infrared technology for estrus detection and as a predictor of time of ovulation in dairy cows in a pasture-based system. *Theriogenology*, 81 (7): 925-935, 2014.

**30. Bowers S, Gandy S, Anderson B, Ryan P, Willard S:** Assessment of pregnancy in the late-gestation mare using digital infrared thermography. *Theriogenology*, 72 (3): 372-377, 2009. DOI: 10.1016/j.theriogenology.2009.03.005

**31. Pampariene I, Veikutis V, Oberauskas V, Zymantiene J, Zelvyte R, Stankevicius A, Marciulionyte D, Palevicius P:** Thermography based inflammation monitoring of udder state in dairy cows: Sensitivity and diagnostic priorities comparing with routine California mastitis test. *J. Vibroengineering*, 18 (1): 511-521, 2016.

**32. Holmdahl L:** The role of fibrinolysis in adhesion formation. *Eur J Surg Suppl*, (577), 24-31, 1997.

**33. Lasne D, Jude B, Susen S:** From normal to pathological hemostasis. *Can J Anaesth*, 53, S2-S11, 2006. DOI: 10.1007/BF03022247