

Impact of Temperature and the Length of Exposure on Morphological Characteristics of Erythrocytes in Antemortem and Postmortem Analysis: Experimental Study on Wistar Rats

Emina SPAHIĆ ^{1,a} Muhamed KATICA ^{2,b} Anes JOGUNČIĆ ^{3,c} Aida KATICA ^{4,d} Sabaheta HASIĆ ^{5,e}

¹ Department of Forensic Medicine, Faculty of Medicine, University of Sarajevo, Sarajevo, BOSNIA AND HERZEGOVINA

² Department of Pathological Physiology of Domestic Animals, Veterinary Faculty, University of Sarajevo, BOSNIA AND HERZEGOVINA

³ Department of Epidemiology, Public Health Institute of Canton Sarajevo, Sarajevo, BOSNIA AND HERZEGOVINA

⁴ Department of Pathological Physiology of Domestic Animals, Veterinary Faculty, University of Sarajevo, BOSNIA AND HERZEGOVINA

⁵ Department of Medical Biochemistry, Faculty of Medicine, University of Sarajevo, Sarajevo, BOSNIA AND HERZEGOVINA

ORCID: ^a 0000-0001-8429-0508; ^b 0000-0002-8184-0065; ^c 0000-0001-6926-0079; ^d 0000-0001-9157-6942; ^e 0000-0002-4193-9837

Article ID: KVFD-2020-24352 Received: 21.04.2020 Accepted: 18.08.2020 Published Online: 19.08.2020

How to Cite This Article

Spahić E, Katica M, Jogunčić A, Katica A, Hasić S: Impact of temperature and the length of exposure on morphological characteristics of erythrocytes in antemortem and postmortem analysis: Experimental study on Wistar rats. *Kafkas Univ Vet Fak Derg*, 26 (6): 771-776, 2020. DOI: 10.9775/kvfd.2020.24352

Abstract

Changes in red blood cell morphology can be induced by various stimuli. In order to investigate the effects of different temperature intensities (37°C, 41°C, and 44°C) and exposure time (20 min and until the time of death) on erythrocyte morphology, heat stress was used on a rat model. Thirty-five Wistar rats were divided into three groups: 37°C as control group, 41°C and 44°C as trial groups. The trial groups were classified into antemortem the exposure time of 20 min and postmortem groups exposure time until fatal outcome. The anaesthetised rats were exposed to preheated water using the water bath. May-Grünwald-Giemsa colouring technique was applied on blood samples taken from the abdominal aorta. The light microscopy was performed (Motic Type 102M) to detect poikilocytes. Target cells and anulocytes were predominant in antemortem groups, while anulocytes and spherocytes in postmortem groups 41°C and 44°C, respectively. No difference in poikilocyte number was found between antemortem and postmortem groups 41°C and 44°C. Spherocyte number was significantly higher in postmortem than antemortem group 41°C (P=0.001) and dacryocytes with spherocytes in postmortem group 44°C (P=0.002, P=0.017, respectively). Poikilocytosis is associated with the exposure length and temperature intensity. Spherocytosis and anulocytosis are the most frequent in postmortem groups while target cells and anulocytes in antemortem groups. Following a fatal outcome, spherocytes at 41°C and dacryocytes with spherocytes at 44°C were significantly more than in corresponding antemortem groups.

Keywords: Heat, Poikilocytosis, Antemortem, Postmortem, Rats

Antemortem ve Postmortem Analizlerde Sıcaklığın ve Sıcaklığa Maruz Kalma Süresinin Eritrositlerin Morfolojik Özellikleri Üzerine Etkisi: Wistar Ratlarda Deneysel Çalışma

Öz

Kırmızı kan hücresi morfolojisindeki değişiklikler çeşitli uyarılarla indüklenebilir. Farklı sıcaklık yoğunluklarının (37°C, 41°C ve 44°C) ve maruz kalma süresinin (20 dakika ve ölüm zamanına kadar) eritrosit morfolojisi üzerindeki etkilerini araştırmak için ısı stresi uygulanan bir rat modelinde kullanıldı. Otuz beş Wistar sıçanı üç gruba ayrıldı: kontrol grubu olarak 37°C, deneme grubu olarak 41°C ve 44°C. Deney grupları antemortem 20 dakikalık maruziyet süresi ve postmortem gruplar ölüme kadar maruziyet süresi olarak sınıflandırıldı. Anestezi uygulanan sıçanlar su banyosu kullanılarak önceden ısıtılmış suya maruz bırakıldı. Abdominal aorttan alınan kan örneklerine May-Grünwald-Giemsa boyama tekniği uygulandı. Poikilositleri saptamak için ışık mikroskobu kullanıldı (Motic Tip 102M). Antemortem gruplarında hedef hücreler ve anülositler predominant iken, postmortem gruplarda, 41°C ve 44°C'de sırasıyla anülositler ve sferositler şeklindeydi. Antemortem ve postmortem gruplar arasında 41°C ve 44°C'deki poikilosit sayısında fark bulunmadı. Sferosit sayısı postmortem grubunda, antemortem 41°C grubuna göre (P=0.001) ve dakryositler sferositlere göre postmortem 44°C grubunda (sırasıyla P=0.002, P=0.017) daha yüksekti. Poikilositozun, sıcaklık yoğunluğu ve maruz kalma süresi ile ilişkili olduğu belirlendi. Postmortem gruplarda en sık sferositoz ve anülositoz görülürken, antemortem gruplarda hedef hücreler ve anülositler görülmekteydi. Ölümcul bir sonucu takiben 41°C'de sferositler ve 44°C'de sferositli dakryositler, kendilerine karşılık gelen antemortem gruplarından önemli ölçüde daha fazlaydı.

Anahtar sözcükler: Isı, Poikilocytosis, Antemortem, Postmortem, Rat



Correspondence



+387 61 031191; +387 33 666545; Fax: +387 33 666545



emina.spahic@mf.unsa.ba; spahica@hotmail.com

INTRODUCTION

Evaluation of haematological parameters enables quick detection of changes in body's homeostasis. It has been known that the original biconcave shape of erythrocytes can be influenced by some unfavourable endogenic and exogenic factors such as exposure to toxic aluminium compounds [1-3], microelements, nutritional deficiency [4], implants placement during surgical interventions [5] as well as effects of electromagnetic field of weak power [6]. Detection of erythrocyte shape abnormality, known as poikilocytosis, in peripheral blood smear reveals the pathophysiology of disease and facilitates patients' early diagnosis and treatment. In forensic medicine, time of death has an extreme importance in homicide or any other instance of un-witnessed death investigation. Despite many researches it remains one of the most challenging variables to establish [7]. Moreover, can some specific or non-specific changes in red blood cell shape be detected under various environmental conditions? It has been known that exposure to higher temperatures for a longer period causes a variety of pathological changes accompanied by multi-organ failure and fatal outcome [8]. The mortality rate associated with high temperature exposure is in the range from 33% to 80% [9,10]. The effects of the body exposure to higher temperature can be identified easily by analysis of biochemical and physiological parameters especially haematological parameters [11]. The changes in blood cell morphology between cadaveric blood collected from corpses at 4°C, stored in test tubes, and blood collected directly from corpses at room temperature, have been studied as a way to determine the post mortem interval [12-15]. Literature data that refer to the correlation between the high temperature effects and the length of body exposure to high temperature with the occurrence of poikilocytic shapes is scarce [16,17].

The aim of the study was to investigate the influence of different water temperatures and length of exposure using heat stress model by water on morphology of erythrocytes.

MATERIAL and METHODS

Ethics Committee Approval

This study was approved by the Ethical Committee of Medical Faculty University of Sarajevo under registration number 02-3-4-1253/20, Bosnia and Herzegovina.

The Study Design and Animals

Prospective, controlled, experimental study has been conducted by using the animal model. The total number of 35 adult, albino Wistar rats, of both sexes and body mass from 250 g to 300 g has been included in the experiment. Animals were kept in polypropylene cages under optimal environmental conditions (temperature $24\pm 2^\circ\text{C}$, relative humidity of 45% to 65% and a light: dark cycle of 12:12

h), acclimatised for 7 days before the experiment and observed constantly for signs of illness; Commercial food and drinking water were given to animals *ad libitum*.

The Animal Groups

The anaesthetised thirty-five rats were exposed to preheated water using the water bath. The rats were divided into three groups: control group (n=7) exposed to 37°C water temperature, and two trial groups such as group exposed to 41°C water temperature (n=14), and another group exposed to 44°C water temperature (n=14). Each of the trial groups exposed to 41°C and 44°C water temperature was further classified according to the time of analysis, as antemortem group (n=7) that exposure time of 20 min and postmortem group (n=7) that exposure until time of death (n=7).

Experimental Protocol and Sample Collection

Rats were anaesthetised using combination of Ketamine (90 mg/kg of body weight (bw); Ketamine Hydrochloride Injection USP Rotexmedica-Germany) and Xylazin (5 mg/kg bw; 2% Xylazin, Cp Pharma, Bergdorf, Germany) once in dose of 1.2 mL/kg bw +/- 10% before being exposed to specified temperature for the specified time of exposure [18]. Water bath (Memmert GmbH + Co. KG, model size WPE 22) equipped with electronic temperature control was filled with water that was preheated to specified temperature. Experimental protocol was performed for each anaesthetised rats sequentially. Each of them was immersed into preheated water with their heads above the surface. Rats of antemortem groups were sacrificed after the expiration of the designated time of 20 min.

Microscopic Examination and Cell Counting

Blood samples have been collected from abdominal aorta with the objective of making at least two blood smears by using the standard laboratory procedure of May-Grünwald-Giemsa colouring technique. The analysis of coloured blood smears relied on the standard morphology was conducted by two independent researchers; the counting was conducted on representative one-layered visual fields where blood corpuscles just touched one another with their edges and did not overlap [19]. Two thousand erythrocytes were analysed on each coloured blood smear by using light microscope Motic Type 102M and magnification of 1000X in order to determine the possible presence of poikilocytic red blood cells. We took the average value of two independent measurements which has been previously described [19,20]. The most representative visual fields have been saved in the electronic form by using computer software Motic Images Plus 2.0.

The number and type of poikilocytes were recorded as percentages of RBC. Poikilocytosis was classified as semi-quantitatively according to similar research, following the criteria: non-existing (0%), rare (0.05-0.5%), mild (>0.5-3%),

modest (>3-10%), or expressed (>10%)^[19].

Statistical Analysis

The normality of data distribution was tested by Shapiro-Wilk test. Categorical data were expressed as a percentage value. To test the differences in numerical values between groups, Kruskal Wallis test and Mann Whitney tests were used. P value <0.05 was considered as statistically significant. All statistical tests were performed using SPSS software version 25.0 (SPSS, Inc., Chicago, IL, USA).

RESULTS

Fig. 1 shows the results of the poikilocytic shapes frequency in peripheral blood smear of groups. Depending on the temperature to which rats were exposed, target cells and anulocytes were detected in antemortem groups.

In 1000 cell count, there was "mild" number of ovalocytes in Antemortem and Postmortem group at 44°C. "Modest" number of Dacryocytes was detected in Antemortem group at 41°C and in Postmortem groups. Anulocytes were in "mild" number in Control group. Furthermore "moderate" number of anulocytes was detected in Antemortem group at 41°C and in both Postmortem groups. They were "expressed" in Antemortem group at 44°C. Spherocytes were "expressed" in Postmortem groups. In postmortem groups of rats, the most frequent type of poikilocytosis found at 41°C was spherocyte, while anulocytosis with spherocytosis were detected in rats exposed to 44°C.

Table 1 shows the difference in numbers of poikilocytic shapes between analyzed groups.

Statistically significant differences between antemortem and control groups in number of ovalocytes, dacryocytes,

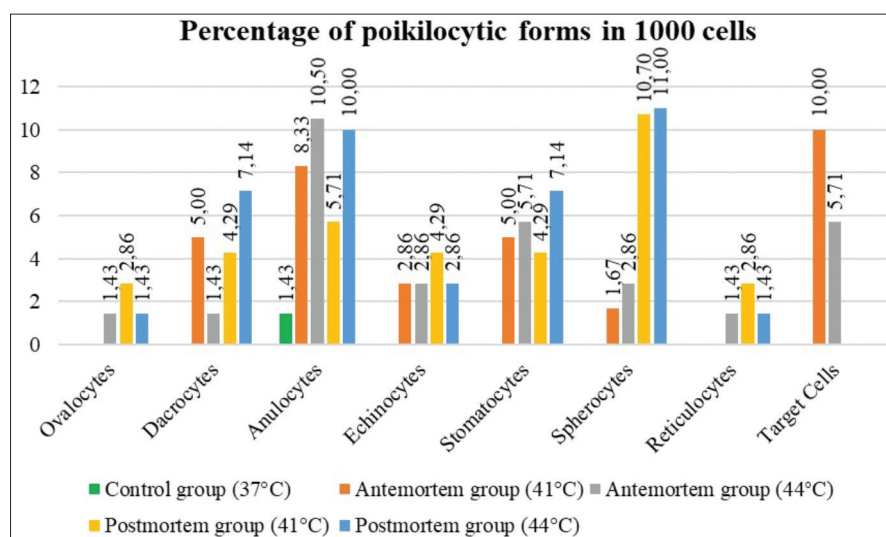


Fig 1. Frequency and types of poikilocytic forms in peripheral blood smear in control and experimental groups. The readings stand for percentage representation of individual poikilocytic types in 1000 cells

Table 1. Types of poikilocytosis in antemortem and control groups of Wistar rats

| Types of Poikilocytosis | A: Control Group (37°C) | B: Antemortem Group (41°C) | C: Antemortem Group (44°C) | D: Postmortem Group (41°C) | E: Postmortem Group (44°C) |
|-------------------------|----------------------------|----------------------------|----------------------------|----------------------------|----------------------------|
| | Median (IQ range) | Median (IQ range) | Median (IQ range) | Median (IQ range) | Median (IQ range) |
| Ovalocytes | 1 (0-2) ^{B,C,D,E} | 3.5 (1-6) ^A | 3 (2-3) ^A | 9 (4-13) ^A | 3 (1-10) ^A |
| Dacryocytes | 1 (0-2) ^{B,C,D,E} | 8.5 (1-12) ^A | 5 (2-9) ^{A,E} | 7 (5-26) ^A | 16 (8-19) ^{A,C} |
| Anulocytes | 1 (0-3) ^{B,C,D,E} | 39.5 (31-55) ^A | 47 (25-74) ^A | 50 (3-55) ^A | 100 (28-123) ^A |
| Echinocytes | 0 (0-1) ^{B,C,D,E} | 2.5 (0-38) ^A | 0 (0-15) ^A | 8 (4-59) ^A | 7 (1-13) ^A |
| Stomatocytes | 1 (0-2) ^{B,C,D,E} | 10 (4-22) ^A | 17 (6-35) ^A | 10 (2-51) ^A | 15 (8-26) ^A |
| Drepanocytes | 0 (0-0) | 0 (0-0) | 0 (0-0) | 0 (0-0) ^A | 0 (0-1) |
| Schizocytes | 0 (0-2) | 1 (1-6) | 1 (1-2) | 1 (1-2) | 1 (1-2) |
| Leptocytes | 0 (0-0) | 0 (0-0) | 0 (0-0) | 0 (0-0) | 0 (0-1) |
| Acantocytes | 0 (0-0) | 0 (0-1) | 0 (0-0) | 0 (0-1) | 0 (0-1) |
| Spherocytes | 1 (0-2) ^{B,C,D,E} | 1 (1-8) ^{A,D} | 2 (1-15) ^{A,E} | 47 (40-84) ^{A,B} | 46 (25-54) ^{A,C} |
| Reticulocytes | 1 (1-1) ^{B,C,D,E} | 1.5 (0-2) ^A | 1 (1-4) ^A | 8 (3-11) ^A | 4 (1-10) ^A |
| Target cells | 1 (0-1) ^{B,C,D,E} | 24.5 (20-34) ^A | 12 (3-24) ^A | 2 (1-4) ^A | 1 (1-2) |

Data were presented as median with 25th-75th range (IQ); p - probability with level of significance P<.05, ^A sig. different than A, ^B sig. different than B, ^C sig. different than C, ^D sig. different than D, ^E sig. different than E

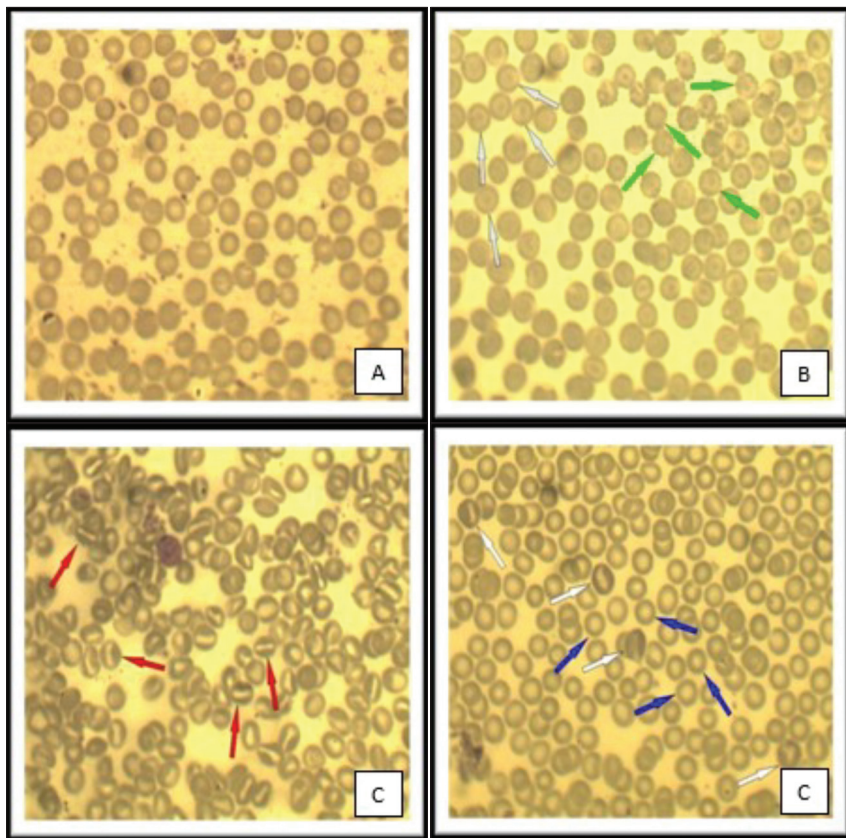


Fig 2. Poikilocytic forms of RBC, peripheral blood smear, magnification 1000x,

A- Normal red blood cells; B- Green arrow: Echinocytes, C- Red arrow: Stomatocytes, D- White arrow: Reticulocytes, Blue arrow: Anulocytes

anulocytes, echinocytes, stomatocytes, spherocytes, reticulocytes and Target cells were detected ($P < 0.05$). The ovalocyte, dacryocyte, anulocyte, echinocyte, stomatocyte, spherocyte, reticulocyte and Target cell median values were significantly higher in rats exposed to 41°C than in the control ($P < 0.05$). The difference between the control and antemortem group exposed to water temperature of 44°C was in the median number of ovalocytes, anulocytes, spherocytes, reticulocytes and Target cells ($P < 0.05$). There was no difference in number of specific types of poikilocytic cells between antemortem groups.

Results featured in *Table 1* point towards insignificant difference in the number of abnormally shaped erythrocytes between postmortem groups ($P > 0.05$).

Comparison of the antemortem and postmortem groups of rats exposed to water temperature of 41°C showed a significant difference in the presence of spherocytes ($P = 0.001$). When we compared the rats from antemortem and postmortem groups exposed to water at 44°C, a significant difference in the number of dacryocytes ($P = 0.02$) and spherocytes was observed ($P = 0.017$).

Fig. 2 shows poikilocytic forms of red blood cells. Control group is with non-existing or rare poikilocytotic form. Echinocytes and Target cells are marked in the antemortem group 41°C. Stomatocyte is expressed in the postmortem group 41°C. Anulocytes and reticulocytes are expressed in the postmortem group of 44°C

DISCUSSION

In this study, we investigated the effects of exposures to normal and high water temperatures on erythrocyte morphology of rats blood. Twenty minutes exposure of Wistar rats to water of 41°C and 44°C induced poikilocytosis. Poikilocytosis was associated with the exposure length and temperature intensity. The most distinct shapes of poikilocytes found in the postmortem groups of rats were “expressed” spherocytosis and “expressed” anulocytosis with spherocytosis. In the antemortem group on 41°C poikilocytosis for Target cells was found; while in antemortem group on 44°C anulocytosis was identified. Their presence was “expressed” in our study. In antemortem groups and control group statistically significant difference was in almost all poikilocytic shapes, which indicated that high temperature induces poikilocytosis following 20 min exposure to the high temperature. The present finding was as results of Lucijanović et al.^[20], pointing that poikilocytosis was associated with the temperature to which rats were exposed, but also with the length of exposure. Median value in spherocyte number was significantly higher in postmortem than in antemortem group 41°C. Dacryocytes and spherocytes numbers were significantly higher in postmortem than in antemortem group 44°C. The high temperature causes protein denaturation with cell malfunction, loss of membrane integrity and finally cell death. Abnormal erythropoiesis and damage of red blood cells following their formation can result

in poikilocytosis [21]. Among extrinsic factors that affect red blood cell morphology are drugs, chemicals, toxins, heat and abnormal mechanical forces. Poikilocytes of specific shapes suggest different etiologic factors [22,23]. Phagocytes play a significant role in the modulation of local or extended inflammation. In Djaldetti et al. [24] study, a temperature of 40°C significantly increased the number of phagocytic cells, as compared to cells incubated at 37°C. The increased phagocytic capacity of peripheral blood monocytes at high temperature further enlightens the immunomodulatory effect of fever in the immune responses during inflammation [24].

Specific poikilocytes are associated with diseases and noted in the rat, but may also be observed during the evaluation of rat blood in toxicity studies. In these studies the most common forms of poikilocytes are echinocytes and acanthocytes. Acanthocytes also are commonly observed in the blood of rats with severe liver disease like in other species. Red blood cell fragments (schistocytes) are observed in hemolytic processes such as those associated with Heinz body formation, osmotic shock, and disseminated intravascular coagulation. Rarely, red cell shapes such as stomatocytes, target cells, ghost cells, spherocytes, and others were observed by Car et al. [25].

The body temperature elevation caused by body heat exposure, results in significant increase of structurally transformed erythrocytes (echinocytes) and vesicles in blood [24]. Echinocytosis is a morphologic change that is characteristic of thermally injured red blood cells [26]. The high temperature required for red cell fragmentation is an indicator of membrane abnormality [26]. Increased thermal sensitivity of red cell membrane has been demonstrated for pyropoikilocytes. Pyropoikilocytosis is distinguished by their substantially lower critical temperature of fragmentation. The lowest temperature at which normal red blood cells caused heat-induced fragmentation is 49°C, whereas pyropoikilocytes undergo morphologic changes or fragmentation on lower temperature. Fatality may occur at body temperature >42°C [27]. Our results are different from others, because the lowest temperature we pointed for poikilocytes was at 41°C, and fatality occurred at 41°C water temperature.

The increase in marrow activity is accompanied by a modest local increase in clonogenic marrow stem cells but it cannot be shown for certainty whether the phenomenon of Thermal Marrow Expansion is due to the local effect of elevated temperature on stem or stromal cells. The erythrocytes produced by Thermal Expansion appear normal *in vivo* fragility testing [28].

Hematopoietic stem cells are the only cells capable of producing all blood cell lineages throughout life. Within the bone marrow exists a tightly controlled local microenvironment, that regulates the proliferation and differentiation of stem cells. Regulatory signals emanate

from surrounding cells in the form of bound or secreted molecules and also from physical cues such as oxygen tension, stress, contractile forces, inflammation and temperature [29,30]. During homeostasis, the majority of cells in bone marrow can become activated to proliferate and differentiate in response to infectious stress and other extrinsic factors like ambient temperature. Shin et al. [31] has recently discovered intrinsic mechanisms, microenvironmental interactions and communication with surrounding cells involved in stem cells regulation during homeostasis and in regeneration after injury and discussed their implications for regenerative therapy.

It is known that increased body temperature could influence cell volume by direct modification of the transport systems such as Na-K⁺ ATP-ase that is sensitive to temperature. Metabolism and cell signalling is accomplished by temperature-sensitive reactions. An increase in body temperature leads to decrease of the erythrocytes volume and increase of phosphatidylserine (PS) exposure at the erythrocyte surface, common hallmarks of eryptosis, or the suicidal death of erythrocytes. Both events are accompanied by an increase of the cytosolic Ca²⁺ activity, which contributes to the cell shrinkage and cell membrane scrambling. The cell shrinkage is induced by activation of Ca²⁺-sensitive K⁺ channels with subsequent exit of K⁺ and Cl⁻ ions with the osmotically obliged water [32]. An increased cytosolic Ca²⁺ has an effect on the cytoskeleton architecture and activates several enzymes such as transglutaminase, phospholipases, calpain, protein kinases, and phosphatases. Calpain degrades cell membrane proteins and thus leads to membrane blebbing, a further hallmark of eryptosis. Erythrocytes that were exposed to PS may adhere to the vascular wall, which results in compromising the microcirculation in cases of body exposure to high temperature. Higher PS exposure may further activate macrophages to release proinflammatory cytokines such as interleukin-6 (IL-6) and tumour necrosis factor alpha which increase both prostaglandin formation and cortisol secretion [33]. In addition to eryptosis, a long body exposure to high temperature also stimulates haemolysis. However, unlike eryptosis, haemolysis is activated only during body exposure to the high temperatures.

Since there are more and more deaths that occur during bathing, especially in the bathroom or warm ambient in the summer months, the aim was to find out what happens to erythrocytes and their forms during life and after death as a result of high water temperature. We concluded that the length of exposure led to greater changes in erythrocytes morphology than just the 41°C or 44°C water temperature.

AUTHORS' CONTRIBUTIONS

E.S and M.K.gave substantial contribution to the conception or design of the article and in the acquisition and interpretation of data for the work. E.S and S.H. had a role in article drafting and in process of revision. A.J and A.K.

gave a substantial contribution to analysis of data for the work. All authors contributed to the critical revision of the manuscript for important intellectual content and have read and approved the final version.

FINANCIAL SUPPORT AND SPONSORSHIP

None

CONFLICT OF INTEREST

The authors declare no conflict of interest.

REFERENCES

- Vittori D, Nesse A, Pérez G, Garbossa G:** Morphological and functional alterations of erythroid cells induced by longterm ingestion of aluminium. *J Inorg Biochem*, 76 (2): 113-120, 1999. DOI: 10.1016/s0162-0134(99)00122-1
- Vittori D, Garbossa G, Lafourcade C, Perez G, Nesse A:** Human erythroid cells are affected by aluminium. Alteration of membrane band 3 protein. *Biochim Biophys Acta*, 1558: 142-150, 2002. DOI: 10.1016/S0005-2736(01)00427-8
- Katica M, Janković O, Tandir F, Gradašćević N, Dekić R, Manojlović M, Paraš S, Tadić-Latinović L:** The effects of calcium aluminate and calcium silicate cements implantation on haematological profile in rats. *Kafkas Univ Vet Fak Derg*, 26 (3): 427-434, 2020. DOI: 10.9775/kvfd.2019.23476
- Katica M, Gradasevic N:** Hematologic profile of laboratory rats fed with bakery products. *IJRG*, 5 (5): 221-231, 2017. DOI: 10.5281/zenodo.583912
- Katica M, Čelebičić M, Gradašćević N, Obhodžas M, Suljić E, Očuz M, Delibegović S:** Morphological changes in blood cells after implantation of titanium and plastic clips in the neurocranium - Experimental study on dogs. *Med Arch*, 71 (2): 84-88, 2017. DOI: 10.5455/medarh.2017.71.84-88
- Muharemovic Z, Katica M, Musanovic M, Hadzimusic N, Catic S, Caklova K, Korkut DŽ:** Effect of weak static magnetic fields on the number red blood cells into fattening turkey peripheral blood samples under *in vitro* and *in vivo* conditions. *HealthMED*, 24 (3): 689-697, 2010.
- Donaldson AE, Lamont IL:** Estimation of postmortem interval using biochemical markers. *Aust J Forensic Sci*, 46, 8-26, 2014. DOI: 10.1080/00450618.2013.784356
- Leon LR, Bouchama A:** Heat stroke. *Compr Physiol*, 5 (2): 611-647, 2015. DOI: 10.1002/cphy.c140017
- Al Mahri S, Bouchama A:** Heatstroke. *Handb Clin Neurol*, 157, 531-545, 2018. DOI: 10.1016/B978-0-444-64074-1.00032-X
- Palmiere C, Mangin P:** Hyperthermia and postmortem biochemical investigations. *Int J Legal Med*, 127, 93-102, 2013. DOI: 10.1007/s00414-012-0722-6
- Sieck GC:** Molecular biology of thermoregulation. *J Appl Physiol*, 92 (4):1365-1366, 2002. DOI: 10.1152/jappphysiol.00003.2002
- Dokgöz H, Arican N, Elmas I, Fincanci SK:** Comparison of morphological changes in white blood cells after death and *in vitro* storage of blood for the estimation of postmortem interval. *Forensic Sci Int*, 124 (1): 25-31, 2001. DOI: 10.1016/s0379-0738(01)00559-x
- Penttila A, Laiho K:** Autolytic changes in blood cells of human cadavers. II Morphological studies. *Forensic Sci Int*, 17, 121-132, 1981. DOI: 10.1016/0379-0738(81)90004-9
- Carter CM:** Alterations in blood components. **In**, Comprehensive Toxicology, 3rd ed., 249-293, 2018. DOI: 10.1016/B978-0-12-801238-3.64251-4
- Miller MA, Zachary JF:** Mechanisms and morphology of cellular injury, adaptation, and death. **In**, Zachary JF (Ed): Pathologic Basis of Veterinary Disease. 2-43, Mosby, 2017. DOI: 10.1016/B978-0-323-35775-3.00001-1
- Ivanov IT, Tolekova A, Chakaarova P:** Erythrocyte membrane defects in hemolytic anemias found through derivative thermal analysis of electric impedance. *J Biochem Biophys Methods*, 70 (4): 641-648, 2007. DOI: 10.1016/j.jbbm.2007.02.004
- Galluzzi L, Vitale I, Kroemer G:** Molecular mechanisms of cell death: Recommendations of the Nomenclature Committee on Cell Death 2018. *Cell Death Differ*, 25, 486-541, 2018. DOI: 10.1038/s41418-017-0012-4
- Režić-Mužinić N, Mastelić A, Benzon B, Markotić A, Mudnić I, Grković I, Grga M, Milat AM, Ključević N, Boban M:** Expression of adhesion molecules on granulocytes and monocytes following myocardial infarction in rats drinking white wine. *PLoS One*, 13 (5):e0196842, 2018. DOI: 10.1371/journal.pone.0196842
- Christopher MM, Hawkins MG, Burton AG:** Poikilocytosis in rabbits: Prevalence, type, and association with disease. *PLoS One*, 9 (11):e112455, 2014. DOI: 10.1371/journal.pone.0112455
- Lucijanić M:** Analiza gena i proteina signalnih puteva Wnt i Sonic Hedgehog u primarnoj i sekundarnoj mijelofibrozi (dissertation). 19 p, Medicinski Fakultet Sveučilišta u Zagrebu, Zagreb, 2017.
- Boes KM, Durham AC:** Bone marrow, blood cells, and the lymphoid/lymphatic system. **In**, Zachary JF (Ed): Pathologic Basis of Veterinary Disease. 6th ed., 724-804.e2, Mosby, 2017. DOI: 10.1016/B978-0-323-35775-3.00013-8
- Bain JB:** Blood cell morphology in health and disease. **In**, Bain JB, Bates I, Laftan MA, Lewis SM (Eds): Dacie and Lewis Practical Haematology. 11th ed., London: Churchill Livingstone, 2012.
- Katica M, Šeho-Alić A, Čelebičić M, Prašović S, Hadzimusic N, Alić A:** Histopathological and hematological changes by head abscess in rat. *Veterinaria*, 68 (3): 151-156, 2019.
- Djaldetti M, Bessler H:** High temperature affects the phagocytic activity of human peripheral blood mononuclear cells. *Scand J Clin Lab Invest*, 75 (6): 482-486, 2015. DOI: 10.3109/00365513.2015.1052550
- Car BD, Bounous DI:** Clinical Pathology of the Rat. **In**, The Laboratory Rat. 2th ed., 127-146, American College of Laboratory Animal Medicine, 2006.
- Choi JW, Pai SH:** Changes in hematologic parameters induced by thermal treatment of human blood. *Ann Clin Lab Sci*, 32 (4): 393-398, 2002.
- Ferrell JE, Lee KJ, Huestis WH:** Membrane bilayer balance and erythrocyte shape: A quantitative assessment. *Biochemistry*, 24, 2849-2855, 1985.
- Byfield JE, Klisak I, Bennett LR:** Thermal marrow expansion: Effect of temperature on bone marrow distribution. *Int J Radiat Oncol Biol Phys*, 10 (6): 875-883, 1984. DOI: 10.1016/0360-3016(84)90390-0
- Wang LD, Wagers AJ:** Dynamic niches in the origination and differentiation of haematopoietic stem cells. *Nat Rev Mol Cell Biol*, 12 (10): 643-655, 2011. DOI: 10.1038/nrm3184
- Adamo L, Naveiras O, Wenzel PL, McKinney-Freeman S, Mack PJ, Gracia-Sancho J, Suchy-Dacey A, Yoshimoto M, Lensch MW, Yoder MC, García-Cardeña G, Daley GQ:** Biomechanical forces promote embryonic haematopoiesis. *Nature*, 459 (7250): 1131-1135, 2009. DOI: 10.1038/nature08073
- Shin JW, Buxboim A, Spinler KR, Swift J, Christian DA, Hunter CA, Léon C, Gachet C, Dingal PCDP, Ivanovska IL, Rehfeldt F, Chasis JA, Discher DE:** Contractile forces sustain and polarize hematopoiesis from stem and progenitor cells. *Cell Stem Cell*, 14 (1): 81-93, 2014. DOI: 10.1016/j.stem.2013.10.009
- Suzuki J, Fujii T, Imao T, Ishihara K, Kuba H, Nagata S:** Calcium-dependent phospholipid scramblase activity of TMEM16 protein family members. *J Biol Chem*, 288, 13305-13316, 2013. DOI: 10.1074/jbc.M113.457937
- Foller M, Braun M, Qadri SM, Lang E, Mahmud H, Lang F:** Temperature sensitivity of suicidal erythrocyte death. *Eur J Clin Invest*, 40, 534-540, 2010. DOI: 10.1111/j.1365-2362.2010.02296.x