

# Intervention of Atrial Septal Defect Embolization Using Three-Dimensional Transesophageal Echocardiography-Guided Thoracotomy in a Yorkshire Terrier

Akiko UEMURA <sup>1,a</sup> Tomohiko YOSHIDA <sup>2,b</sup> Katsuhiko MATSUURA <sup>2,c</sup> Ryou TANAKA <sup>2,d</sup>

<sup>1</sup> Department of Veterinary Surgery, Division of Veterinary Research, Obihiro University of Agriculture and Veterinary Medicine, 2-11 Inadacho Nishi, Obihiro-Shi, Hokkaido, 080-8555, JAPAN

<sup>2</sup> Department of Veterinary Surgery, Faculty of Veterinary Medicine, Tokyo University of Agriculture and Technology, 3-5-8 Saiwaicho, Fuchu, Tokyo 183-8509, JAPAN

ORCID: <sup>a</sup> 0000-0003-2671-5074; <sup>b</sup> 0000-0003-4311-9311; <sup>c</sup> 0000-0002-6047-2865; <sup>d</sup> 0000-0001-9948-6490

Article ID: KVFD-2020-24301 Received: 09.04.2020 Accepted: 09.08.2020 Published Online: 10.08.2020

## How to Cite This Article

Uemura A, Yoshida T, Matsuura K, Tanaka R: Intervention of atrial septal defect embolization using three-dimensional transesophageal echocardiography-guided thoracotomy in a Yorkshire Terrier. *Kafkas Univ Vet Fak Derg*, 26 (6): 823-826, 2020. DOI: 10.9775/kvfd.2020.24301

## Abstract

Atrial septal defect (ASD) is a relatively rare congenital heart disease in dogs. A radical treatment is defect closure under open heart or occlusion by intervention. Small dogs face challenges with either treatment. This case was an 8-month-old female Yorkshire Terrier, weighing 2.4 kg. She suffered from dyspnea due to deterioration of circulatory dynamics caused by ASD. An Amplatzer was positioned under thoracotomy, guided by three-dimensional transesophageal echocardiography. Postoperative recovery was quick and uneventful. Clinical symptoms disappeared and circulatory dynamics were stable after growth. This method is considered to be a useful treatment option for small dogs with ASD.

**Keywords:** Atrial septal defect, Congenital heart defect, Small dog, Interventional cardiac procedures, 3D transesophageal echocardiography

## Bir Yorkshire Terrier'de Üç Boyutlu Transözofageal Ekokardiyografi Rehberli Torakotomi İle Atriyal Septal Defekt Embolizasyonuna Müdahale

## Öz

Atriyal septal defekt (ASD) köpeklerde nispeten seyrek görülen bir doğumsal kalp hastalığıdır. Radikal tedavi, açık kalp altında defektin kapatılması veya girişimsel bir müdahale ile tıkanmasıdır. Küçük köpeklerde her iki tedavide de zorluklarla karşılaşılır. Bu olgu, 2,4 kg ağırlığında, 8 aylık dişi Yorkshire Terrier idi. Olgu, ASD'nin neden olduğu dolaşım dinamiklerinin bozulması nedeniyle nefes darlığı yaşamaktaydı. Torakotomi altına, üç boyutlu transözofageal ekokardiyografi rehberliğinde bir Amplatzer yerleştirildi. Postoperatif iyileşme hızlı ve sorunsuz oldu. Büyümeden sonra klinik semptomlar kayboldu ve dolaşım dinamikleri stabil hale geldi. Bu yöntem, ASD'li küçük köpekler için faydalı bir tedavi seçeneği olarak dikkate alınabilir.

**Anahtar sözcükler:** Atriyal septal defekt, Kongenital kalp defekti, Küçük köpek, Girişimsel kardiyak prosedür, 3D transözofageal ekokardiyografi

## INTRODUCTION

Atrial septal defect (ASD) is a malformation that occurs in about 1% of congenital heart diseases in dogs <sup>[1,2]</sup>. The prognosis for a small, isolated ASD is usually good, but dogs with defects larger than 12 mm can have difficulty breathing, exercise intolerance, and poor growth <sup>[3]</sup>; these dogs therefore require treatment. The treatment for ASD

includes medical management with drugs or surgical closure of the defect <sup>[4]</sup>. In ASD that requires surgery, physical closure of the defect is necessary. Surgical approaches include direct visual closure of the obturator via open-heart surgery and the use of a cardiopulmonary bypass <sup>[4]</sup>, and defect obstruction using a device, via percutaneous endovascular treatment <sup>[3]</sup>. In cases where percutaneous endovascular treatment is not feasible, for



## Correspondence



+81-155-495376 (A. U.) +81-42-3675904 (R. T.) Fax: +81-155-495376 (A. U.) +81/42/3675904 (R. T.)



anco@vet.ne.jp (A. U.) ryo@vet.ne.jp (R. T.)

example if the diameter of the blood vessels is too small, a hybrid approach can be adopted, in which a device is inserted directly into the heart without opening, via a thoracotomy. The use of such a hybrid approach to treating heart defects was reported by Saunders and colleagues for a ventricular septal defect (VSD) in a small dog<sup>[5]</sup>, and we used this approach for a small dog with ASD (a Norfolk Terrier weighing 6.9 kg)<sup>[6]</sup>.

As is clear from the shape of heart-defect embolization devices currently on the market for use in humans, ASD occlusion plugs generally have a larger umbrella diameter compared with the umbrella diameter of VSD occlusion plugs. This is thought to be because the atrial wall is thinner than the ventricular fistula, and an obturator plug inserted into a defect cannot be fixed there unless it is firmly held in place with the large area associated with a large umbrella. However, using a large umbrella can partly inhibit intracardiac blood flow and valve movement. The authors have previously experienced the need to abandon the device, especially in the small hearts seen in small dogs because, even though the ASD may be occluded, the circulatory dynamics deteriorate when using a large device. It should therefore be taken into account that the same approach cannot be taken with VSD and ASD, even in small dogs of the same size.

## CASE HISTORY

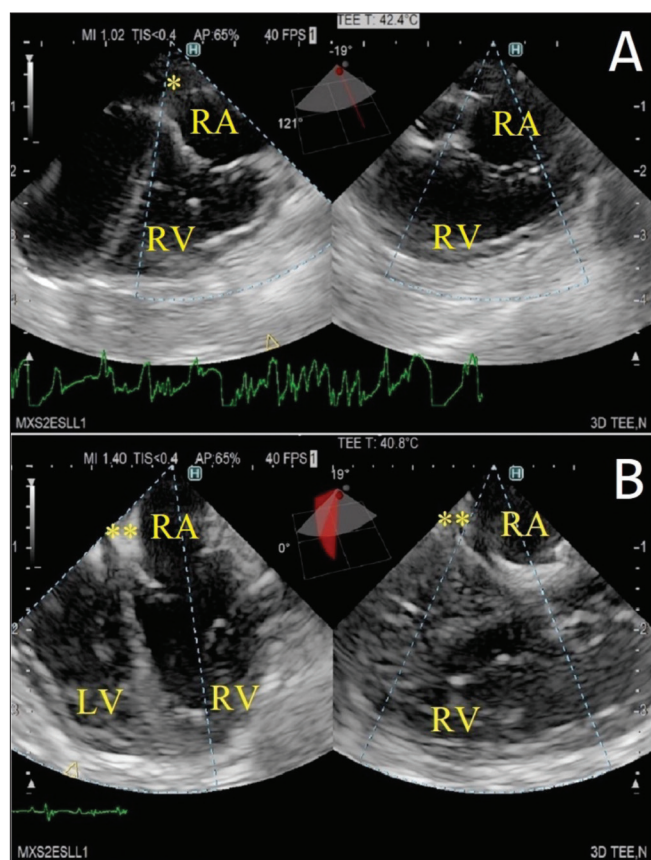
The case was a female Yorkshire Terrier, aged 8 months, and weighing 2.4 kg. She was admitted to the hospital for further examination and treatment because her home veterinarian suspected ASD. She had a breathing boost and persistent shortness of breath during exercise.

On day 1, physical examination revealed a heart murmur of Levine 1/6, blood pressure of 120/61 (85) (systolic/diastolic (mean)), and a heart rate of 95 bpm. A chest X-ray showed right ventricular enlargement. By transthoracic echocardiography (TTE), the ASD diameter was determined to be 5.7 mm, but the Qp/Qs was 2.97. Based on the location of the ASD, a diagnosis of secundum atrial septal defect was made. The clinical manifestations were suspected to be due to the deterioration of circulatory dynamics, therefore it was judged that physical closure of the defect was necessary. This case involved a small dog of low weight, and therefore at high risk of unsuccessful open-heart surgery, but percutaneous endovascular treatment was physically difficult because of the peripheral vessel diameter. Thus, the hybrid approach was planned, with the aim of inserting an occluder directly into the heart via thoracotomy, after gaining the owner's informed consent.

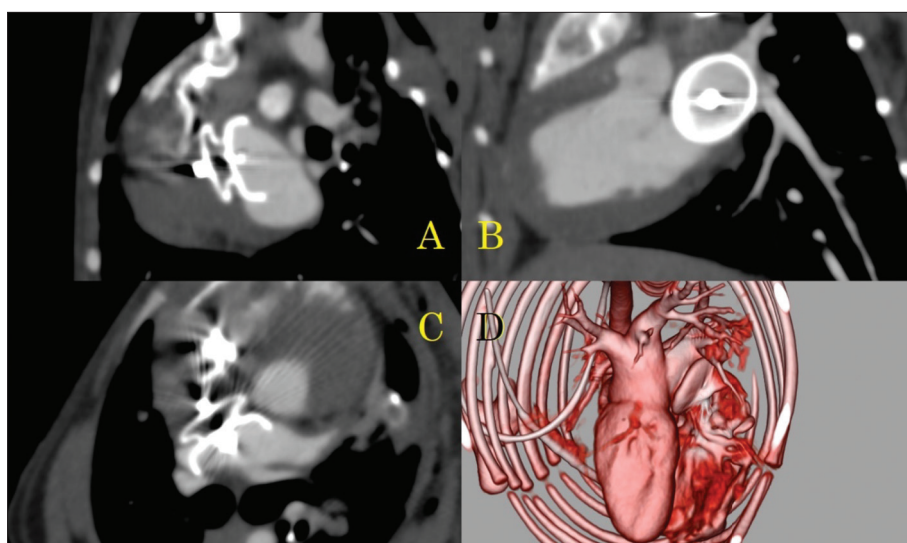
On day 25, anesthesia was induced with atropine (0.05 mg/kg, subcutaneous injection, sc), ampicillin (Ampicillin sodium injection 1 g, Kyoritsu-seiyaku Corporation, Tokyo, Japan) (30 mg/kg, intravenous injection, iv), butorphanol

(Vetorphale®, Meiji Seika Pharma Co Ltd., Tokyo, Japan) (0.3 mg/kg, iv), midazolam (Dormicum Injection 10 mg, Astellas Pharma Inc., Tokyo, Japan) (0.2 mg/kg, iv), meloxicam (Boehringer Ingelheim Animal Health Japan Co., Ltd., Tokyo, Japan) (0.2 mg/kg, sc), and propofol (Mylan Injection 1%, Mylan Inc., Tokyo, Japan) (to effect, iv). Anesthesia was maintained with isoflurane (Isoflurane for animals, Intervet K.K., Tokyo, Japan) (1.7%-2.2%).

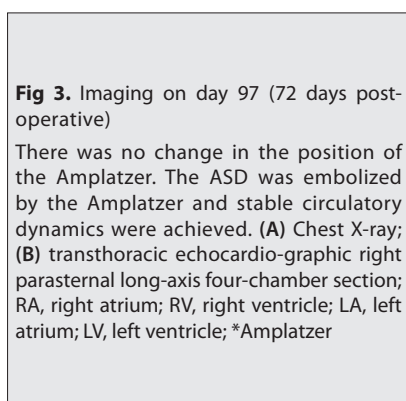
After induction of anesthesia, ECG-synchronized CT was performed prior to surgery to confirm the position and size of the defect. The left atrial appendage was sutured to the left atrial appendage by the left fourth intercostal thoracotomy. After applying a tourniquet, the left atrial appendage was incised several millimeters. After insertion of a 9Fr sheath (Medikit Sheath Introducer, Medikit Co. Ltd., Tokyo, Japan) via the incision, the sheath tip was positioned near the defect under the guidance of three-dimensional (3D) transesophageal echocardiography (TEE). An occluder (waist diameter 9 mm, disk portion 14 mm) (ACDO, Infiniti Medical LLC, Malibu, CA, USA) was inserted via the sheath into the defect. After confirming that stable placement was possible, under 3D TEE guidance, the occluder was released (Fig. 1). Once it was established that there was



**Fig 1.** Imaging of three-dimensional (3D) transesophageal echocardiography (TEE) on day 25. By using 3D-TEE, a device inserted into the heart can be confirmed from two directions at once. Because the device status can be confirmed from two directions, it can be placed once the device is stable. RA, right atrium; RV, right ventricle; LV, left ventricle; \*Amplatzer

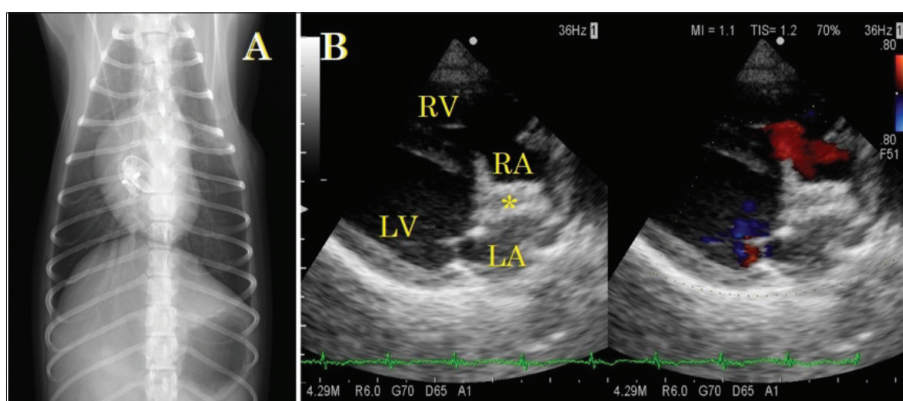


**Fig 2.** ECG-synchronized CT on day 25 Immediately after the operation of Amplatzer placed in the ASD. (A) Coronal plane; (B) sagittal plane; (C) axial plane; (D) 3D image



**Fig 3.** Imaging on day 97 (72 days post-operative)

There was no change in the position of the Amplatzer. The ASD was embolized by the Amplatzer and stable circulatory dynamics were achieved. (A) Chest X-ray; (B) transthoracic echocardiographic right parasternal long-axis four-chamber section; RA, right atrium; RV, right ventricle; LA, left atrium; LV, left ventricle; \*Amplatzer



no change in circulatory dynamics, the chest was closed according to the standard method.

After the operation, ECG-synchronized CT was again performed to confirm the position of the occluder (Fig. 2). The dog's arousal from anesthesia was good. On the day following the surgery, TTE showed a Qp/Qs of 1.01, indicating a marked improvement in circulatory dynamics.

She was discharged on day 27 (the day following her surgery). No arrhythmia was observed from the post-operative period until discharge.

On day 97 (72 days postoperative), periodic postoperative examinations and OHE were performed. There was no medical treatment required, there were no problems with the circulatory dynamics, including during anesthesia or from the positioning of the obstructive plug, and no clinical symptoms were observed (Fig. 3).

## DISCUSSION

The medical treatment for ASD in dogs is a coping therapy. There are no clear guidelines for the surgical reduction of defects. Cases with a defect pore size of 12 mm or more have dyspnea [3], and surgical reduction is performed if

there are signs of congestive heart failure [7,8].

The defect size in this case was 5.7 mm, as measured by TTE, but clinical symptoms thought to be caused by a deterioration in circulatory dynamics and congestive heart failure were observed. Medical management in this case may have improved the dog's clinical symptoms. However, even a small defect in the small heart found in a small dog can lead to a deterioration in circulatory dynamics, so it was determined that physical closure should be performed, based on the circulatory dynamics rather than the diameter of the defect. Previous study has described the usefulness of doppler echocardiography in confirming the pathogenesis of congenital heart disease [9]. In the present case, doppler echocardiography with TTE and TEE was utilized in this case as well.

By inserting an occluder directly into the heart during a thoracotomy, the invasiveness of thoracotomy is present, but the perioperative risk is reduced compared with the risk associated with open-heart surgery. Also, it is physically very difficult to insert a 9Fr sheath into the peripheral blood vessels of a small dog, but this limitation due to the diameter of the blood vessels can be eliminated by inserting the device directly into the heart.

This method can be performed under a surgical fluoroscope as well as via a conventional intervention. However, 3D TEE can provide improved stereoscopic images of intracardiac structures. By using 3D TEE as a guide instead of a fluoroscopic device, delicate movements can easily be reflected directly on the image, making release determination after placement much easier. Furthermore, it is beneficial to eliminate the risk of exposure for both healthcare professionals and patients.

In ASD, the defect size may be larger than the measurement of diameter made preoperatively, due to the thinness of the wall and its extensibility. Unlike with percutaneous intervention, it is much easier to insert and remove devices using this method, so it is also easy to replace devices of multiple sizes based on their stability and hemodynamics during device insertion.

The weight of a dog's heart is reported to be between 0.61% and 0.94% of its total body weight<sup>[10,11]</sup>. Based on this, the heart weight is 6.9 kg (42.1 g to 64.9 g heart)<sup>[6]</sup> and 2.4 kg (14.6 g to 22.6 g heart) in this case. There will be a difference of about 1.9- to 4.4-times. Heart weight and intraventricular volume are not simply proportional. However, larger dogs are less prone to circulatory dynamic deterioration due to intracardiac structure inhibition by an intracardiac defect occluder, while the weight difference can be disadvantageous for defect obstruction in smaller dogs.

In this study, we treated ASD in a Yorkshire Terrier, which weighed even less than the dog described in our previous report<sup>[6]</sup>, and obtained good results. It was confirmed that there were no abnormalities in circulatory dynamics, even under anesthesia for a hysterectomy after growth.

We performed Amplatzer embolization using a 3D TEE-guided/thoracotomy approach for a case of ASD in a Yorkshire Terrier. The postoperative awakening was rapid, with no complications, and markedly improved postoperative circulatory dynamics and a disappearance of clinical symptoms. Based on the above, embolization using a 3D TEE-guided/thoracotomy approach for ASD is considered to be a useful radical treatment option, especially for ASD in small dogs.

#### AUTHOR CONTRIBUTIONS

AU was a surgeon in this case, wrote the manuscript, and

prepared all the figures. TY and KM were responsible for the patient's clinical examination. RT was a surgeon in this case and also the primary investigator.

#### ACKNOWLEDGMENTS

We have no sources of support in the form of grants, equipment, or drugs. We have no financial or other types of conflicts of interest. This work has not previously been presented at any scientific meeting, either in whole or in part.

#### REFERENCES

- Schrope DP:** Prevalence of congenital heart disease in 76,301 mixed-breed dogs and 57,025 mixed-breed cats. *J Vet Cardiol*, 17 (3): 192-202, 2015. DOI: 10.1016/j.jvc.2015.06.001
- Oliveira P, Domenech O, Silva J, Vannini S, Bussadori R, Bussadori C:** Retrospective review of congenital heart disease in 976 dogs. *J Vet Intern Med*, 25 (3): 477-483, 2011. DOI: 10.1111/j.1939-1676.2011.0711.x
- Gordon SG, Miller MW, Roland RM, Saunders AB, Achen SE, Drouff LT, Nelson DA:** Transcatheter atrial septal defect closure with the Amplatzer atrial septal occluder in 13 dogs: Short- and mid-term outcome. *J Vet Intern Med*, 23 (5): 995-1002, 2009. DOI: 10.1111/j.1939-1676.2009.0365.x
- Gordon SG, Nelson DA, Achen SE, Miller MM, Roland RM, Saunders AB, Drouff LT:** Open heart closure of an atrial septal defect by use of an atrial septal occluder in a dog. *J Am Vet Med Assoc*, 236 (4): 434-439, 2010. DOI: 10.2460/javma.236.4.434
- Saunders AB, Carlson JA, Nelson DA, Gordon SG, Miller MW:** Hybrid technique for ventricular septal defect closure in a dog using an Amplatzer (R) Duct Occluder II. *J Vet Cardiol*, 15 (3): 217-224, 2013. DOI: 10.1016/j.jvc.2013.06.003
- Uemura A, Tanaka R, Nakata TM, Matsuura K, Goya S, Shimada K, Chantawong P, Kitpipatkun P, Hamabe L:** Hybrid technique for closing an atrial septal defect using an Amplatzer® Canine Duct Occluder in a small breed dog. *Aust Vet Pract*, 48 (1): 19-21, 2018.
- Eyster GE, Anderson LK, Krehbeil JD, Whipple RD, Blanchard GL, Dickason J, Braden TD, Bohonowych R, Harris F:** Surgical repair of atrial septal defect in a dog. *J Am Vet Med Assoc*, 169 (10): 1081-1084, 1976.
- Sanders RA, Hogan DF, Green HW, Hoyer MH, Puppel DA:** Transcatheter closure of an atrial septal defect in a dog. *J Am Vet Med Assoc*, 227 (3): 430-434, 2005. DOI: 10.2460/javma.2005.227.430
- Yilmaz Z, Levent P, Saril A, Uemura A, Kocatürk M, Tanaka R:** Ventricular septal defect and pulmonic stenosis in a dog. *Kafkas Univ Vet Fak Derg*, 25 (5): 729-730, 2019. DOI: 10.9775/kvfd.2019.22616
- Bienvenu JG, Drolet R:** A quantitative study of cardiac ventricular mass in dogs. *Can J Vet Res*, 55 (4): 305-309, 1991.
- Queiroz LR, Moura LR, Moura VMBD:** Morphometric assessment of canine heart without macroscopically visible changes caused by cardiac disease. *Ciênc Anim Bras*, 19, 1-9, e43748, 2018. DOI: 10.1590/1809-6891v19e-43748