

Successful Treatment of Pyometra Concomitant with Diabetes Mellitus in a Bitch

Hande GÜRLER ^{1,a}

¹Ondokuz Mayıs University, Faculty of Veterinary Medicine, Department of Obstetrics and Gynecology, TR-55139 Samsun - TURKEY

^a ORCID: 0000-0001-7239-5388

Article ID: KVFD-2020-23865 Received: 02.01.2019 Accepted: 30.04.2020 Published Online: 30.04.2020

How to Cite This Article

Gürler H: Successful treatment of pyometra concomitant with diabetes mellitus in a bitch. *Kafkas Univ Vet Fak Derg*, 26 (4): 573-576, 2020. DOI: 10.9775/kvfd.2020.23865

Abstract

Pyometra, a diestrus period disorder with a long term of progesterone exposure to endometrium, is a common disease of nulliparous female dogs. Closed-cervix pyometra is an emergency medical condition that requires rapid intervention. The possibility of treatment is further limited when associated with a chronic disease such as diabetes. This case describes a closed cervix pyometra in a 4-year-old bitch with comorbid diabetes mellitus and long-term contraceptive therapy. Closed-cervix pyometra was diagnosed and confirmed by ultrasound examination typical of pyometra, vaginal smear indicating diestrus and serum progesterone level (52 ng/mL). Serum fructosamine level was 475 µmol/L, interpreting diabetes mellitus. Treatment included ovariohysterectomy and normoglycemia was achieved with glargine insulin. Although, reproductive hormones and diestrus are associated with Type II diabetes mellitus in bitches, there are no reports limited to our search, on pyometra concomitant with diabetes mellitus except Elkhounds. Since the situation has a vital clinical importance, this report aims to emphasize the insidious diabetes mellitus development potential and treatment in canine pyometra which is usually misdiagnosed or unconsidered in clinical practice.

Keywords: Dog, Diabetes mellitus, Pyometra

Dişi Bir Köpekte Piyometra ve Eşlik Eden Diyabetes Mellitus Olgusunun Başarılı Tedavisi

Öz

Piyometra hiç doğum yapmamış dişi köpeklerde sıklıkla görülen, endometriumun uzun süreli progesterona maruz kalması sonucunda şekillenen bir dioestrus dönemi hastalığıdır. Kapalı serviks piyometra ise prognozu zayıf, mortalite oranı yüksek hızlı müdahale gerektiren acil bir tıbbi durumdur. Diyabet gibi kronik bir hastalık ile ilişkili olduğunda tedavi olasılığı daha da sınırlıdır. Progesteron kaynaklı insülin direncinden dolayı köpeklerde diyabetes mellitusun eşlik ettiği piyometra vakalarına rastlanması olası bir durumdur. Bu olgu, uzun süre kontraseptif uygulanmış 4 yaşlı bir köpekte diyabetes mellitus eşlik eden kapalı serviks piyometrayı tanımlamaktadır. Tanı, kapalı serviks piyometra için tipik ultrason görüntüsü, diöstrusu işaret eden vajinal smear bulgusu ve yüksek (52 ng/mL) serum progesteron seviyesi ile doğrulandı. Eşlik eden diyabetes mellitus durumu, yüksek serum fruktozamin seviyesi (475 µmol/L) ile teşhis edildi. Tedavi amacıyla ovariohisterektomi operasyonu ve normoglisemi sağlamak için glarjin insülin uygulaması gerçekleştirildi. Bu rapor, klinik pratikte köpeklerde piyometra olgularında genellikle eksik tanıya neden olan ve dikkate alınmayan, sinsiy diyabetes mellitus gelişim potansiyelini vurgulamayı amaçlamaktadır.

Anahtar sözcükler: Köpek, Diyabetes mellitus, Piyometra

INTRODUCTION

Pyometra is the most common life-threatening uterine disorder of intact female dogs. Unlike most other female mammals, the female dog secretes ovarian progesterone for approximately 55-75 days after ovulation. It occurs

due to prolonged exposure of the endometrium to progesterone during diestrus. Pyometra is classified as closed cervix pyometra in which purulent substance accumulates in the uterus and open cervix pyometra in with presence of vulvar discharge ^[1-5]. Vaginal discharge, inflammation, abdominal distension in the genital tract



Correspondence



+90 362 3121919/1234



handeulusoy@gmail.com

together with systemic disease are observed in dogs with pyometra [2]. Sepsis is a result of an exaggerated systemic inflammatory response (SIRS) and may commonly be a result of canine pyometra [3,4]. Endotoxemia and SIRS are life threatening probable results of pyometra [2]. The safest and most effective treatment of closed cervix pyometra is ovariohysterectomy (OHE) [5]. After surgical removal of the uterus, some complications may occur such as sepsis, septic shock, diffuse bacterial infection, peritonitis and bleeding. Diabetic patients who need any major surgical procedures require careful medical management [6,7].

In cases of closed cervix pyometra with serious metabolic load and risk of complications, treatment process is very difficult to manage. It is known that closed cervix pyometra more dangerous than open cervix pyometra [8]. One major complication of pyometra is development of canine diabetes mellitus (CDM), due to the insulin resistance creating effect of long-term progesterone exposure. In addition, the excessive uterine inflammatory actions resulting with inflammatory substances inducing the release of catecholamines and hormones, such as growth hormone, cortisol, glucagon causing hyperglycemia must be considered [9]. This report describes a closed cervix pyometra in a 4-year-old bitch with comorbid diabetes mellitus and long-term contraceptive therapy, and aims to emphasize the insidious diabetes mellitus development potential in canine pyometra that is usually misdiagnosed or unconsidered in clinical practice.

CASE HISTORY

A 4-year-old intact female Cocker Spaniel dog was admitted to the Animal Hospital of Ondokuz Mayıs University Faculty of Veterinary Medicine. The dog was kept indoor, with complete vaccination and deworming program and had no previous serious medical situation. On arrival at the hospital, the dog was clinically depressive. According to the history, the estrus cycle was postponed with synthetic progestogen medroxyprogesterone acetate (MPA) three times at an epicenter clinic.

Clinical presentation included polydipsia, polyurea, lethargy, abdominal distention and dehydration, sinus tachycardia, tachypnea and body temperature of 39.3°C. Whole blood count was performed with Mindray BC5000 Vet® (Mindray, China), indicating severe leukocytosis with $WBC-67 \times 10^9 L^{-1}$ (reference interval $6-17 \times 10^9 L^{-1}$) and left shift. Serum biochemistry profile (total protein, albumin/globulin ratio, alanine aminotransferase, aspartate aminotransferase, gammaglutamyltransferase, urea, creatinine, glucose, lipase) was analyzed with Mindray BS 120® (Mindray, China) revealing severe hyperglycemia (520 mg/dL) and mild uremia ($17 \text{ mmol } L^{-1}$). Pyometra was suspected despite the absence of vaginal discharge regarding the laboratory data. Closed cervix pyometra was diagnosed and confirmed by

ultrasound (USG) examination (Esaote MyLab FiveVET® Esoate, Genoa). The vaginal smear and history indicated that the dog was in diestrus. Serum progesterone (P4) level was determined with ELISA, as 52 ng/mL. USG examinations of the abdominal viscera did not reveal any abnormal findings. Pancreas was also in normal clinical view, 6.5 mm thick with a pancreatic ductal diameter of 0.5 mm and normal echogenicity, as expected. Fructosamine level was analyzed by ELISA (Canine FTA ELISA Kit®, MyBiosource®, UK) in order to determine the etiology of hyperglycemia and demonstrated as $475 \mu\text{mol/L}$ (reference range: 200 to 375 $\mu\text{mol/L}$) indicating CDM and eliminating a pyometra-induced transient hyperglycemia.

The dog was hospitalized and treated presurgically with intravenous fluids and a subcutaneous injection of insulin glargine (Lantus Solostar®, Sanofi, China) 1 U/kg. Aggressive intravenous antibiotic therapy was started with metronidazole (Flagyl® i.v., Sanofi, Turkey) 10 mg/kg, BID and cefepime hydrochloride (Unisef® 1 mg IM/IV, Mustafa Nevzat, Turkey) 20 mg/kg BID, 14 days.

An OHE was performed the next day and the ovaries and uterus, which was severely distended with purulent material, was removed (Fig. 1). Presence of corpus luteum on the right ovary was observed in post-operative ovary check. Normoglycemia was achieved during and after the operation, due to successful diabetes management. Regression of inflammatory process was achieved in 7 days with normal blood count, but normalizing blood glucose lasted longer with labile glucose curve and confusing

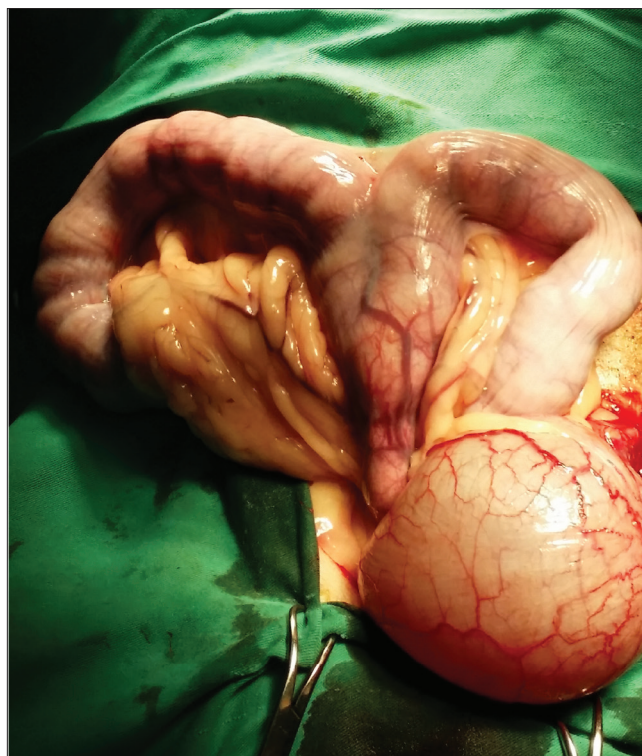


Fig 1. The image of uterus with closed cervix pyometra in OHE

resistance, but 16 U of glargine insulin (1 U/kg) at noon and total 10 U of glargine insulin at midnight, with the appropriate diet was determined as the ideal regimen for this individual patient. Blood urea level regressed following the operation. Follow up visits for 2 weeks demonstrated a fast-wound healing and recovery. Follow up for CDM after achieving the ideal regimen was carried out with monthly intervals and three months fructosamine measurements were back in reference levels within 6 months, indicating a successful CDM management.

DISCUSSION

It is reported that the incidence of pyometra is increased in nulliparous dogs older than 4 years^[10]. The present bitch was a four years old nulliparous Cocker Spaniel.

Pyometra is defined as purulent fluid collection within the uterus with variable amounts of inflammatory cells in the uterine wall, that may or may not be preceded by cystic endometrial hyperplasia^[11] associated with diestrus. Insulin resistance mediated by progesterone is well documented^[1]. Fall et al.^[12] described a diagnostic prevalence of 17% for pyometra with concomitant CDM during diestrus. The last report is concordant with our clinical observations and also the present case.

Arena et al.^[9] reported 33% pyometra prevalence in dogs with CDM, although with limited subjects. Pöppel et al.^[13] reported remission of CDM in 6 dogs, from 57 intact dogs with CDM after spaying. In the present case, CDM was not in a transient etiology, and insulin treatment continued in order to maintain normoglycemic status. As serum fructosamine concentration is not affected by acute increases in the blood glucose concentration, as occurs with stress- or excitement, measurement of a single serum fructosamine concentration demonstrates preceding 2-3 weeks status, high fructosamine concentration of the present dog shows a preceding CDM disorder^[14], in which a regression would not be expected.

Moreover, increased risk of developing pyometra has been associated with hormone administration (estrogen and progestogen compounds)^[2]. Progestagen contraceptives are predisposing for pyometra development which unfortunately is a frequent application in practice^[6]. It is stated that dogs may have diabetes mellitus associated with progesterone intake^[13,14]. It is thought that progesterone intake, as a contraceptive, may be effective in the formation of both pyometra and diabetes. In the present case, the etiology of CDM in a young dog is more likely to be due to this iatrogenic intervention of triple usage of progestogen to postpone of estrus.

Sepsis is a common condition in closed cervix pyometra presented with depression, leukocytosis, neutrophilia and monocytosis, with poor prognosis^[8]. In the present case, a very fast wound healing process and clinical recovery, to a

large extent due to an appropriate metabolic management, especially CDM, was achieved. Fructosamin level evaluation of the insulin-treated diabetic dog provides information on the status of glycemic control during the month prior to the evaluation and follow up checks in this case revealed the proper management of CDM^[14,15]. Satisfactory metabolic equilibrium and tissue glucose feeding gives major contribution to healing processes.

Blood glucose levels under 300 mg/dL are generally neglected by the practitioner, but high fructosamine levels may be present in which urgent insulin therapy is indicated. Therefore, in similar cases of pyometra, fructosamin level analyze will be beneficial for diagnosing diabetes development due to high progesterone levels and must be included in conventional protocol in practice^[16].

Although reproductive hormones and diestrus are associated with Type II diabetes mellitus in bitches, there are no reports limited to our search, on pyometra concomitant with diabetes mellitus except Elkhounds^[12]. This case emphasizes the importance of blood glucose monitoring and if present, CDM management in the prognosis of canine pyometra, together with insidious diabetes mellitus development potential in canine pyometra, which is usually misdiagnosed or unconsidered in clinical practice.

REFERENCES

- Batista PR, Blanco PG, Gobello C:** Treatment of canine pyometra with the gonadotropin-releasing hormone antagonist acyline: A case series. *Top Companion Anim Med*, 30 (1): 25-27, 2015. DOI: 10.1053/j.tcam.2015.01.005
- Hagman R:** Clinical and molecular characteristics of pyometra in female dogs. *Reprod Domest Anim*, 47 (Suppl. 6): 323-325, 2012. DOI: 10.1111/rda.12031
- Sant'Anna MC, Giordano LGP, Flaiban KKMC, Muller EE, Martins MIM:** Prognostic markers of canine pyometra. *Arq Bras Med Vet Zootec*, 66 (6): 1711-1717, 2014. DOI: 10.1590/1678-6859
- Rautela R, Katiyar R:** Review on canine pyometra, oxidative stress and current trends in diagnostics. *Asian Pac J Reprod*, 8 (2): 45-55, 2019.
- Jitpean S, Ström-Holst B, Emanuelson U, Höglund OV, Pettersson A, Alneryd-Bull C, Hagman R:** Outcome of pyometra in female dogs and predictors of peritonitis and prolonged postoperative hospitalization in surgically treated cases. *BMC Vet Res*, 10:6, 2014. DOI: 10.1186/1746-6148-10-6
- Wheaton LG, Johnson AL, Parker AJ, Kneller SK:** Results and complications of surgical-treatment of pyometra- a review of 80 cases. *J Am Anim Hosp Assoc*, 25 (5): 563-568, 1989.
- Schaer M:** Surgery in the diabetic pet. *Vet Clin North Am Small Anim Pract*, 25 (3): 651-660, 1995. DOI: 10.1016/S0195-5616(95)50060-9
- Jitpean S, Ambrosen A, Emanuelson U, Hagman R:** Closed cervix is associated with more severe illness in dogs with pyometra. *BMC Vet Res*, 13:11, 2016. DOI: 10.1186/s12917-016-0924-0
- Arena MN, Albino MVC, Botelho FA, Luchi RAS, Ponce FG, Severo JS:** Evaluation of blood glucose in dogs with pyometra. In, *World Small Animal Association, World Congress*, Sao Paulo, Brazil, 21-24 July 2009.
- Smith FO:** Canine pyometra. *Theriogenology*, 66 (3): 610-612, 2006. DOI: 10.1016/j.theriogenology.2006.04.023
- Feldman EC, Nelson RW:** Canine and Feline Endocrinology and Reproduction. 3rd ed., 486-538, Saunders, Missouri, 2004.

12. Fall T, Hedhammar A, Wallberg A, Fall N, Ahlgren KM, Hamlin HH, Lindblad-Toh K, Andersson G, Kämpe O: Diabetes mellitus in elkhounds is associated with diestrus and pregnancy. *J Vet Intern Med*, 24 (6): 1322-1328, 2010. DOI: 10.1111/j.1939-1676.2010.0630.x

13. Pöppl AG, Mottin TS, González FHD: Diabetes mellitus remission after resolution of inflammatory and progesterone-related conditions in bitches. *Res Vet Sci*, 94, 471-473, 2013. DOI: 10.1016/j.rvsc.2012.10.008

14. Scott-Moncrieff JC: Feline hyperthyroidism. In, *Canine and Feline Endocrinology*. 4th ed., 136-196, Saunders Elsevier, St. Louis, Missouri, 2015.

15. Sloan JM, Path MRC, Oliver IM: Progestogen-induced diabetes in the dog. *Diabetes*, 24 (4): 337-344, 1975. DOI: 10.2337/diab.24.4.337

16. Fernoagă C, Codreanu MD, Cornilă M, Raluca Teodora NAE, Constantinescu R: Use of fructosamine in small animals with diabetes. *Scientific Works, Series C Vet Med*, 61 (2): 99-102, 2015.