

Geometric Morphometric Analysis of Cranium of Wolf (*Canis lupus*) and German Shepherd Dog (*Canis lupus familiaris*)^[1]

İftar GÜRBÜZ^{1,a} Ahmet İhsan AYTEK^{2,b} Yasin DEMİRASLAN^{1,c} Vedat ONAR^{3,d} Özcan ÖZGEL^{1,e}

^[1] This study was presented as a poster in 1st International Veterinary Anatomy Congress of Turkey (Xth National Anatomy Congress), 13-16 September 2017, Sandıklı/Afyonkarahisar, Turkey

¹ Burdur Mehmet Akif Ersoy University, Department of Anatomy, Faculty of Veterinary Medicine, TR-15030 Burdur - TURKEY

² Burdur Mehmet Akif Ersoy University, Department of Anthropology, Faculty of Arts and Science, TR-15030 Burdur - TURKEY

³ İstanbul University-Cerrahpaşa, Department of Anatomy, Faculty of Veterinary Medicine, TR-34320 İstanbul - TURKEY

ORCIDs: ^a 0000-0001-9460-0645; ^b 0000-0002-7620-2333; ^c 0000-0003-3612-6142; ^d 000-0002-8359-243X, ^e 0000-0003-0394-5678

Article ID: KVFD-2019-23841 Received: 27.12.2019 Accepted: 28.04.2020 Published Online: 28.04.2020

How to Cite This Article

Gürbüz İ, Aytek Aİ, Demiraslan Y, Onar V, Özel Ö: Geometric morphometric analysis of cranium of wolf (*Canis lupus*) and German shepherd dog (*Canis lupus familiaris*). *Kafkas Univ Vet Fak Derg*, 26 (4): 525-532, 2020. DOI: 10.9775/kvfd.2019.23841

Abstract

In the study, it was aimed to investigate by geometric morphometric analysis to shape of the skull and mandible in adult male wolf and German Shepherd Dog. The skulls and mandibles were photographed from left side. The shape of skulls and mandibles were optimized by using tpsDig programme with 20 landmarks (in skulls), and 13 landmarks (in mandibles) on 2-D images. The skulls and mandibles were superimposed via PAST software and the principale component analysis was conducted. How and where the shape changes occurs in the cranium was shown using MorphoJ software. Also, morphological differences of the cranium between two groups were determined. As a result, German Shepherd Dog's cranium were significantly seperated from the wolf's cranium in respect of cranium shapes. In skull and mandible, about 70% and 78% of the total shape variation, is reflected by the first three principal components, respectively. Shape differences were most distinct in parietal, occipital, zygomatic, temporal bone and posterior mandible between two groups. The findings of the study are important in terms of evaluating the materials to be extracted from the area of archeological excavation and creating a database that will provide to prominent information about the history of domestication.

Keywords: Wolf, German Shepherd Dog, Mandible, Skull, Geometric morphometry

Kurt ve Alman Çoban Köpeğinde Kafatasının Geometrik Morfometrik Analizi

Öz

Çalışmada Kurt ve Alman Çoban Köpeği'nin alt çene kemiği ve kafatası şeklinin geometrik morfometrik analiz yöntemi ile araştırılması amaçlandı. Bu amaçla kafatası ve mandibula sol taraftan fotoğraflandı. Kafatası ve alt çene kemiğinin şekli, 2D fotoğraf üzerinde 20 landmark (kafatasında) ve 13 landmark (alt çene kemiğinde) ile tpsDig programda optimize edildi. Kafatası ve mandibula'lar PAST yazılımı ile üst üste bindirildi ve temel bileşenler analizi yapıldı. Kafatası ve mandibula'daki şekil farklılıklarının nerede ve nasıl oluştuğu MorphoJ yazılımında görüntüldü. Ayrıca, iki grup arasında morfolojik şekil farklılıkları da belirlendi. Sonuç olarak, Alman çoban köpeği kafatasının şekilsel olarak kurt kafatasından önemli derecede ayrıldığı belirlendi. Kafatası ve alt çene kemiğinin ilk üç temel bileşeni toplam şekil varyasyonunun sırasıyla %70 ve %78'ini açıkladığı saptandı. İki grubun kafatasında şekil farklılıkları en fazla parietal, occipital, zygomatic, temporal kemiklerde ve mandibula'nın posterior'unda belirgindi. Çalışmanın bulguları arkeolojik kazı alanından çıkarılacak malzemelerin değerlendirilmesi ve evcilleştirme tarihi hakkında önemli bilgiler sağlayacak bir veri tabanı oluşturulması açısından önemlidir.

Anahtar sözcükler: Kurt, Alman Çoban Köpeği, Mandibula, Kafatası, Geometrik Morfometri

INTRODUCTION

Wolf (*Canis lupus* Linnaeus, 1758) is the first known animal to be domesticated as gray wolf or timber wolf^[1].

Although archeological and genetic data inform us that domestication of wolves took place 16 thousand years ago, current studies also indicate that this period may date back to 36 thousand years ago^[2]. The gray wolf (*Canis lupus*)



Correspondence



+90 248 2132166



iftargurbuz@mehmetakif.edu.tr

is a carnivore with a vast distribution range, occupying habitats in North America as well as in Europe and Asia [1]. Various subspecies of the gray wolf are identified due to morphological differences in color, size of body and bones, especially the skull, and behavior [3]. The German Shepherd dog is a breed of medium to large sized, slightly elongated, powerful and well-muscled with dry bone and firm overall structure and, originated from Germany [4].

The shape of the skull in dogs varies significantly among species and individuals in terms of its form and size [5]. The shape of the skull is the most important criteria in determining common dog breeds. Therefore, various researchers have examined the skulls of dog breeds anatomically [6]. Also, there are studies in which the skull and mandible of some dog breeds were examined using the classical morphometric method [7-10].

Geometric morphometric is a method of shape analysis defined as the analysis of all geometric information taken from Cartesian coordinates of anatomical points [11]. Geometric morphometry has also been proven to be a useful tool for the study of morphological evolution in mammals. This method is based on the analysis of data obtained from the anatomical points called landmark, which are identified in homologous regions which may reveal the shape and have reliability and reproducibility [11]. Many studies have been conducted on wolves and dogs using this method, which has been used extensively in scientific studies in recent years [12-16]. Also, there are geometric morphometric studies conducted on rodents [17], sheep [18], squirrels [19]. This study aimed to reveal similar or different aspects of wolf and German shepherd dog cranium, which are very similar in an external examination, with the geometric morphometric method.

MATERIAL and METHODS

Ethical Approval

The Local Ethics Committee for Animal Experiments of the Mehmet Akif Ersoy University has granted the required permission (Date: June 07, 2017; no: 299).

Animals

Cranium of the 5 adult male wolves and 5 adult male German shepherd dogs were used in the study. The study materials were obtained from the German shepherd dogs and the gray wolves collected from the Kars-Ardahan-lğdır (in Turkey) region. The age and gender of the wolves and German Shepherd dogs were previously determined in the study. The animals used in the study were already death prior to the study and therefore no euthanize was needed to be performed.

Geometric Morphometric Analysis

In the study, 2-dimensional photographs of the cranium

(18X205 Canon EOS 1000D with Sigma lens) were taken from the left side at a latero-lateral position for the geometric morphometric analysis.

The photographs were taken from a distance of 1 meter by a camera placed on a tripod with a water gauge. The landmarks were detected in two phases using Tps programs over 2-dimensional photographs. In the first phase, the photographs were introduced into the program named tpsUtil Version 1.60 [20] and were saved as tps files. In the second phase, the landmarks were marked on the photographs through tpsDig2 Version 2.18 program [21] and Cartesian coordinates were determined. Twenty landmarks were taken on the skull (Fig. 1) and 13 landmarks were taken on the mandible (Fig. 2).

To remove the effect of factors such as direction, position,

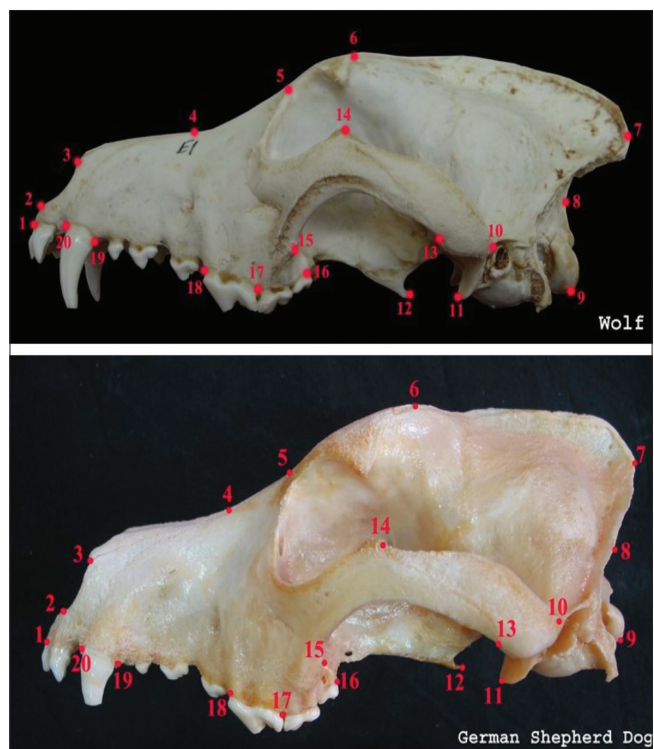


Fig 1. The points of landmarks on the cranium of the Wolf's and German Shepherd dogs

1. Anterior point of the incisive bone (*os incisivum*), 2. Anterior point of the nasal cavity (*cavitas nasalis*), 3. Anterior end of the suture between nasal bones (*os nasale*), 4. Suture between nasal bone and nasal branch of premaxilla, 5. Level of angulus oculi medialis, 6. Anterior point of external sagittal crest (*crista sagittalis externa*), 7. Posterior point of external sagittal crest and the ventral level of occipital condyle (*condylus occipitalis*), 9. Most posteroventral point of the occipital condyle, 10. Posterior point of the zygomatic process of temporal bone (*proc. zygomaticus ossis temporalis*), 11. Ventral point of retroarticular process (*proc. retroarticularis*), 12. Posterior end of the pterygoid process (*hamulus pterygoideus*), 13. The posterior point suture between the zygomatic process of temporal bone and temporal process of zygomatic bone (*proc. temporalis ossis zygomaticus*), 14. The superior point suture between the zygomatic process of temporal bone and temporal process of zygomatic bone, 15. Anteroventral point of zygomatic arch (*arcus zygomaticus*), 16. Posterior edge of 3rd molar alveolus, 17. Posterior edge of 1st molar alveolus, 18. Anterior edge of 1st molar alveolus, 19. Posterior edge of canine alveolus, 20. Anterior edge of canine alveolus

and size on variation over the Cartesian coordinates that were obtained by marking of the landmarks, the data were overlapped by Generalized Procrustes Analysis and PAST 3.21 program [22]. Principal Component Analysis was performed over the new coordinates that were obtained by overlapping, and the shape variation was revealed in

this way. Also, it was shown that the principal components caused what kind of shape changes on which landmarks using the MorphoJ 1.06 program [23]. The data on the landmarks were saved as a text file for statistical analyses.

RESULTS

Geometric Morphometric Values of the Skull

The first principal component explained to 42% of the total shape variation in this geometric morphometric study conducted on 10 skulls with 20 landmarks as shown in Table 1.

The skulls of wolves and German shepherd dogs were distinctly separated from each other for the first principal component according to the graph of principal component analysis in Fig. 3. When the groups were evaluated within themselves, German shepherd dogs showed a much greater variation than the wolves. Also, when all individuals were classified hierarchically, the individuals of both two groups were classified within their groups as indicated in Fig. 4.

Shape differences were the most distinct in os parietale, os zygomaticum, os temporale, and os occipitale in the analysis of the first principal component (Fig. 5). A significant shape difference, which is less distinct when compared with the other bones, was in os maxilla between

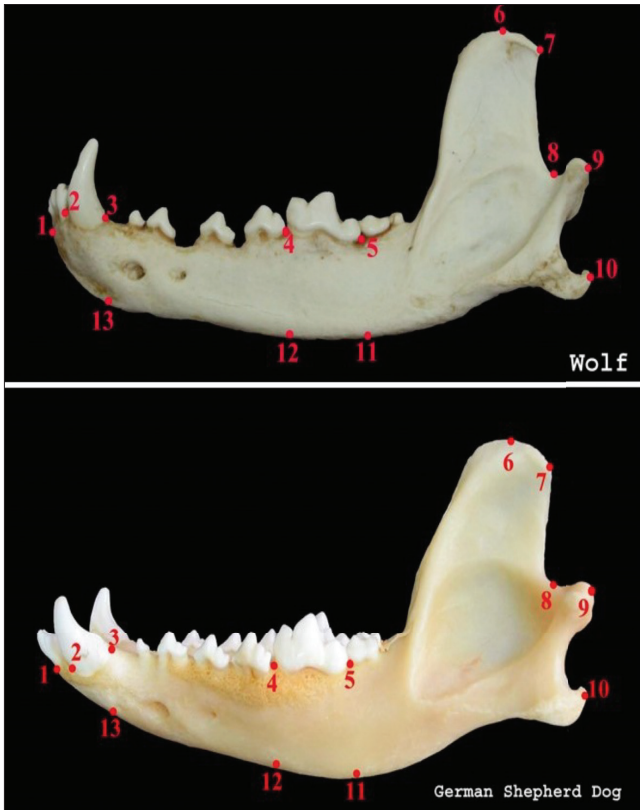


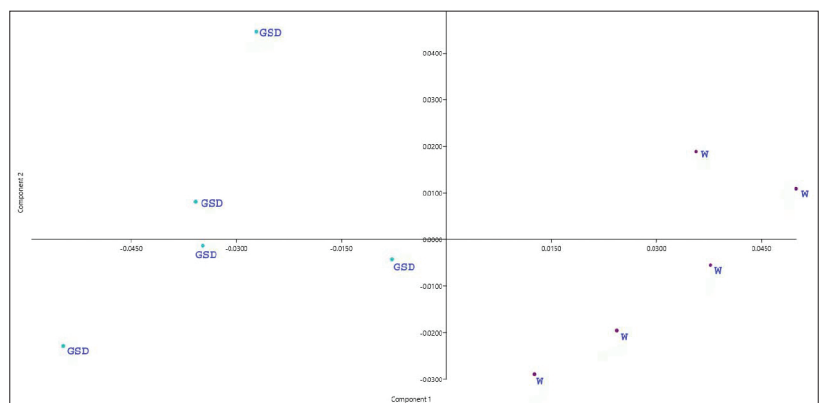
Fig 2. The points of landmarks on mandible of the Wolf's and German Shepherd dogs

1. Anterior end of the corpus mandibula, 2. Anterior edge of the canine alveolus, 3. Posterior edge of the canine alveolus, 4. Anterior edge of the 1st molar alveolus, 5. Posterior edge of the 1st molar alveolus, 6. Top of the coronoid process (*proc. coronoideus*), 7. Dorsocaudal end of the coronoid process, 8. Level of the mandibular incisura (*incisura mandibula*), 9. Caudal edge of the condylar process (*proc. condylaris*), 10. Caudal edge of the angular process (*proc. angularis*), 11. Level of ventral margin of the corpus mandibula at the level of posterior of the 1st molar alveolus, 12. Level of ventral margin of the corpus mandible at the level of anterior of the 1st molar alveolus, 13. Level of ventral margin of the corpus mandibula at the level of posterior of the canine alveolus

Table 1. The values of principal component analysis for the skull

PC	Eigenvalue	% Variation
1	0.00135799	42.376
2	0.000481068	15.012
3	0.000434587	13.561
4	0.000319461	9.9687
5	0.000208181	6.4962
6	0.000158723	4.9529
7	0.000129919	4.0541
8	7.66E+00	2.3888
9	3.82E+00	1.1906

Fig 3. The graphic of principal component analysis for skull (GSD: German Shepherd dog, W: Wolf)



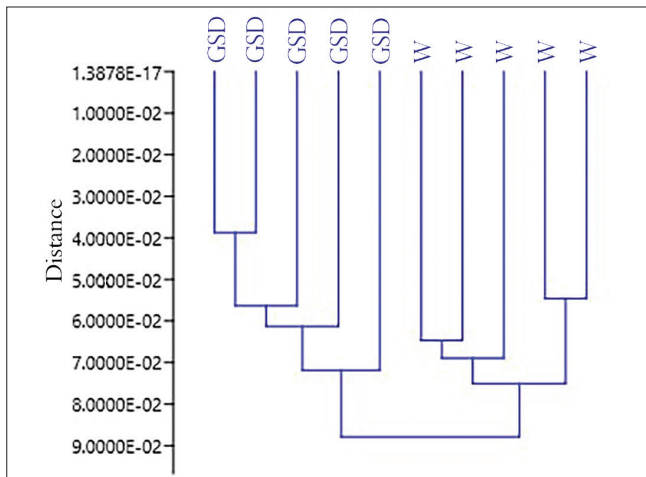


Fig 4. The graphic of hierarchical classification for skull (GSD: German Shepherd Dog, W: Wolf)

Table 2. The values of principal component analysis for the mandible

PC	Eigenvalue	% Variation
1	0.000973965	52.638
2	0.00029352	15.863
3	0.000228735	12.362
4	0.000172245	9.309
5	7.09E-02	3.8339
6	5.16E+00	2.7905
7	3.36E+00	1.8145
8	1.45E+00	0.7819
9	1.12E+00	0.60733

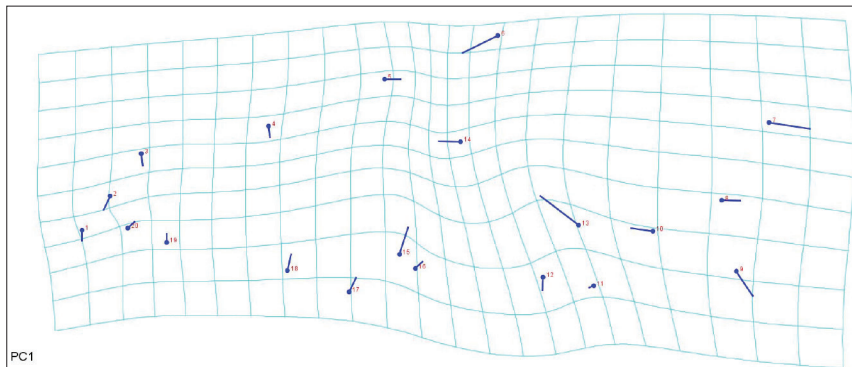


Fig 5. Landmark representation of shape differences of skull between wolf and German Shepherd Dog for the first principal component

Fig 6. Lineal representation of the shape differences of skull for the first principal component

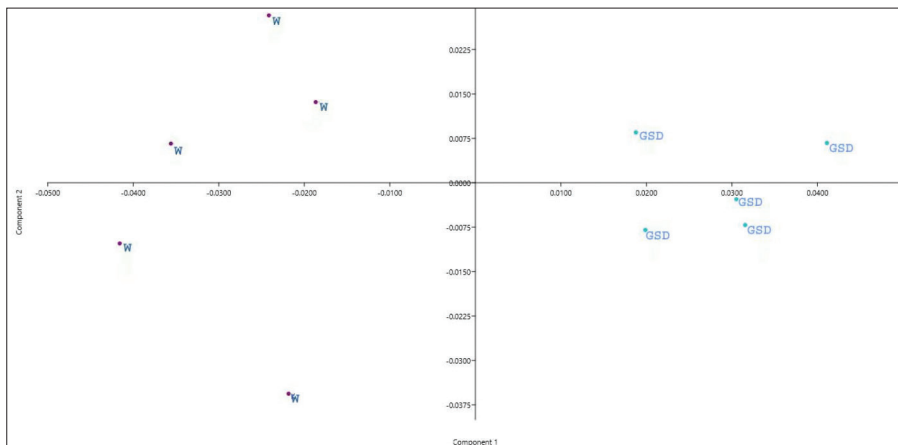
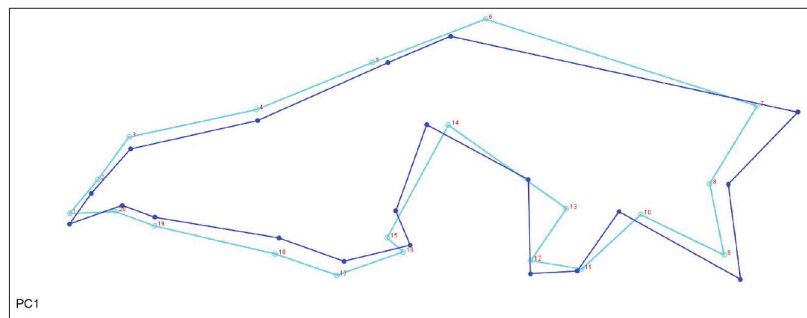


Fig 7. The graphic of principal component analysis for mandible (GSD: German Shepherd dog, W: Wolf)

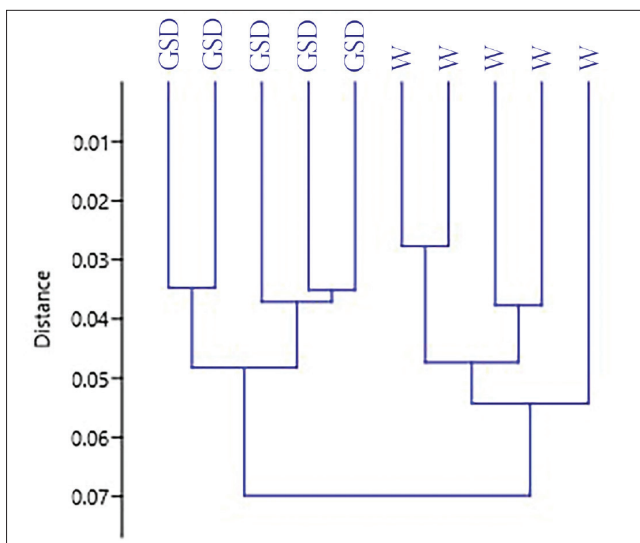


Fig 8. The graphic of hierarchical classification for mandibles (GSD: German Shepherd Dog, W: Wolf)

shape variation in this geometric morphometric study conducted with 13 landmarks as shown in [Table 2](#).

In consequence of the analysis regarding the first principal component, the mandibles of the wolves and German shepherd dogs were distinguished from each other distinctly, according to the [Fig. 7](#). When the groups were evaluated within themselves, in contrast to the skull, the mandible of wolves showed a much greater variation when compared with the German shepherd dogs. Also, when all individuals were classified hierarchically, the individuals of both two groups were classified within their groups ([Fig. 8](#)).

There were significant shape differences in all of the regions of mandible, but they were more distinct in posterior mandible in the analysis of the first principal component ([Fig. 9](#)).

[Fig. 10](#) lineally showed how the overall skull shape varied between the groups.

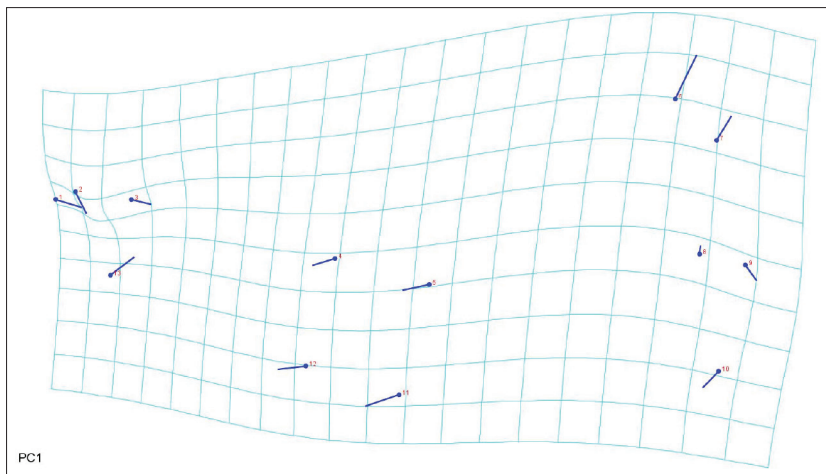


Fig 9. Landmark representation of shape differences of mandible between wolf and German Shepherd Dog for the first principal component

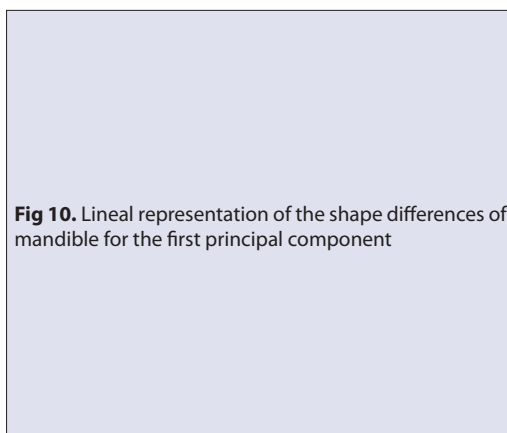
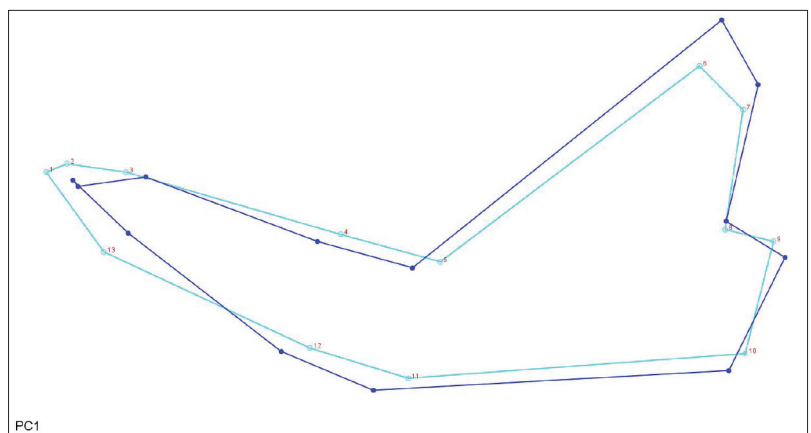


Fig 10. Lineal representation of the shape differences of mandible for the first principal component



the two groups. [Fig. 6](#) lineally showed how the overall skull shape varied between the groups.

The Geometric Morphometric Values of the Mandible

The first principal component explained to 53% of the total

Morphological Differences of the Skull

External sagittal crest (*crista sagittalis externa*) was observed to have a higher and caudoventral directional slope than os parietale in the wolves when compared with the German shepherd dogs at the level of landmark no. 6 and 7. The

caudal end of external sagittal crest reached occipital condyle (*condylus occipitalis*) with a concave curve in the wolves at the level of landmarks no.7 and 8. But the caudal end of external sagittal crest reached occipital condyle with a vertical slope in the German shepherd dogs (Fig. 1, Fig. 5, Fig. 6).

When the skull was placed on a flat ground, the *hamulus pterygoideus* was inclined towards to caudoventral in the wolves, but it was relatively parallel to the ground in the German shepherd dogs at the level of landmark no.12 (Fig. 1, Fig. 5, Fig. 6).

The concavity between the medial angle of the eye and frontal process of nasal congestion (*processus (proc.) frontalis ossis nasalis*) was relatively higher in the German shepherd dogs as shown in the landmark no.3, 4, 5 and 6 (Fig. 1, Fig. 5, Fig. 6).

At the zygomatic arc, the upper edge of the zygomatic process of temporal bone (*proc. zygomaticus ossis temporalis*) was inclined towards to caudoventral in the wolves, but it was relatively parallel to the ground in the German shepherd dogs at the level of the landmarks no.13 and 14 (Fig. 1, Fig. 5, Fig. 6).

Morphological Differences of the Mandible

The caudal end of the coronoid process was relatively inclined backwards in the wolf when compared with the German shepherd dog at the level of landmarks no. 7 and 8 (Fig. 2, Fig. 9, Fig.10).

The ventral margin of mandible (*margo ventralis mandibula*) was more convex in the German shepherd dog when compared with the wolf at the level of landmarks no. 11, 12 and 13 (Fig. 2).

The mental foramen (*foramen mentale*) in the caudal was placed at the ventral of 2nd and 3rd premolar tooth level in the wolves, but it was placed at the ventral of 3rd premolar tooth level in the German shepherd dogs (Fig. 2).

The landmark no.8 accounted for the fact that the mandibular notch (*incisura mandibula*) was relatively deeper in the wolves when compared with the German Shepherd dogs (Fig. 2, Fig. 9, Fig.10).

DISCUSSION

Wolves, which are used in hunting and for protection, have been transformed into dog breeds with different phenotypical characteristics in accordance with human needs with also the impact of artificial selection. Thanks to this transformation, it is known that 361 dog breeds, which have been defined by the World Canine Organization, exist today^[4]. In the study, the cranium of the wolf and the German shepherd dog, a dolichocephalic breed, which has a similar skull image, have been analyzed in terms of

their shapes. However, this study includes some limitations in terms of the number of wolf samples due to strict protection of this species by law, therefore the number of samples were kept minimum just to provide statistical meaning. However, in geometric morphometric studies, relatively small samples provide accurate results especially shape variation is in the case^[24].

The shape of the cranium is associated with the differences in nutritional behavior along with the environmental and genetic factors^[25]. The masticatory muscles, responsible for the feeding, form the main load of the skull and affect growth morphology^[26]. The activation and coordination of the masticatory muscles determine the direction of the movement of the chin and control the masticatory force. At the same time, the difference in the skull and mandible in terms of shape affects the cross-sectional area of the masticatory muscles and therefore biting power^[27].

External sagittal crest in carnivore is the anatomical structure which exists in the skull and constitutes a basis on the holding of especially masticatory muscles. Igado^[28] reported that a distinct external sagittal crest existed in 57.14% of the males and 66.67% of the females in at least 2-years-old Nigerian Local dogs, but either it did not exist or was more flattened in the other skulls. Therefore, it was difficult to determine which gender had more powerful masticatory muscles^[28]. However, the morphometric values of the skull increased with the age in the German shepherd dogs in the age group of 45-105 days was reported^[7]. Based on this information, it was considered that external sagittal crest may become more distinct depending on the age^[28]. Considering that the German shepherd dogs and the wolves that were employed in this study were adults, external sagittal crest was observed to have a higher than parietal bone and caudoventral directional slope in the wolves when compared with the German shepherd dogs at the level of the landmark no.6 and 7.

In a literature which examined the skulls and mandibles of Dinaric-Balkan and Carpathian grey wolves using the geometric morphometrics methods, it was reported that the difference in shape was statistically significant^[29]. In the same literature, the most distinct difference of shape in the skull between the genders was an anterior-posterior shifting of zygomatic arches^[29]. Milencovic et al.^[29] also indicated that shift of zygomatic arches might have affected jaw movement. Similarly, in this study, the zygomatic arch was found to be significantly different in shape between the two groups, at the levels of landmarks no. 13 and 14. The top edge of zygomatic arc was inclined with caudoventral direction in wolves and relatively parallel to the ground in German Shepherd dogs.

In the morphological study on wolf and dog skulls, Janssens et al.^[8] stated that canine tooth remained on dorsal position in wolves and ventral position in dogs when the skull was put on a flat ground in such a way that it contacted the

ground at the level of bulla tympanica and 1st premolar tooth. In this study, unlike the findings of the researchers [8], canine tooth remained in ventral position in the wolves and German Shepherd dogs. Also, Milencovic et al. [29] notified that the facial bone was in dorsoflexion position in Dinaric Balkan wolves, and in ventro-flexion position in Carpathian wolves. These changes in nonallometric cranial flexion are associated with the changes in the convexity or concavity of mandible [29].

Milencovic et al. [29] reported that combination of the 1st and the 2nd principal component of mandible explained to 64.7% of nonallometric shape variation in Dinaric Balkan wolves (female and male) and Carpathian wolves. In the literature, it was declared that mandible was more concave in Dinaric-Balkan wolves when compared with the Carpathian wolves [29]. In the present study, the first principal component in mandible explained to 53% of total shape variation and corpus mandible was determined to be more convex in German Shepherd dogs when compared with the wolves.

Olsen and Olsen [30] reported that the turned back morphological structure of dorsal part of ramus mandible was specific in domestic dogs and Chinese wolves (*Canis lupus chanco*) and did not exist in other dogs. On the other hand, Janssens et al. [31] stated that the coronoid process of mandibles of all dog species did not have a specific "turned back morphology" in consequence of their study on 384 dog skulls from 72 breeds and 60 wolf skulls from 4 wolf subspecies. Therefore, researchers [31] indicated that this feature could not be used in the distinction of dog or wolf species. In this study, at the levels of 7th and 8th landmarks, the caudal end of coronoid process was observed to be relatively "turn back morphology" in wolves when compared with German shepherd dogs.

In conclusion, it is a fact that the differences and data determined between the head bones of the wolf and the German shepherd dog will contribute to the interpretation of osteoarcheological remains excavated from archeological sites. Besides, it is considered that this study will support morphometric or geometric morphometric studies to be conducted on the other species of the family Canidae.

AUTHOR CONTRIBUTIONS

Gürbüz İ, Aytek Al and Demiraslan Y designed and directed the study, Aytek Al conducted geometric morphometric application. Gürbüz İ and Demiraslan Y provided wolf skulls and Onar V provided German Shepherd dog skulls. Gürbüz İ, Aytek Al, Demiraslan Y, Onar V and Özgel Ö co-wrote the overall paper.

CONFLICTS OF INTEREST

The authors declare no conflict of interest.

REFERENCES

- 1. Mech LD:** The Wolf: The Ecology and Behavior of An Endangered Species. 3rd ed., 644-647, Natural History Press, Doubleday Publishing Company, New York, 1970.
- 2. Perri A:** A wolf in dog's clothing: Initial dog domestication and Pleistocene wolf variation. *J Archeol Sci*, 68, 1-4, 2016. DOI: 10.1016/j.jas.2016.02.003
- 3. Wozencraft WC:** Order carnivora. In, Wilson DE, Reeder DM (Eds): Mammal Species of the World: A Taxonomic and Geographic Reference. 3rd ed., 532-628, Johns Hopkins University Press, Baltimore, 2005.
- 4. St-Federation Cynologique Internationale:** Federation Cynologique Internationale (AISBL), Secretariat General 13 Place Albert 1 B-6530 Thuin, Belgique, 2010.
- 5. Sisson S:** Carnivore osteology. In, Sisson S, Grossman JD (Eds): The Anatomy of Domestic Animals. Vol. 2, 5th ed., 1474-1479, Saunders, 1975.
- 6. Brehm VH, Loeffler K, Komeyli H:** Schädelformen beim Hund. *Anat Histol Embryol*, 14, 324-331, 1985. DOI: 10.1111/j.1439-0264.1985.tb00828.x
- 7. Onar V:** A Morphometric study on the skull of the German Shepherd Dog (Alsatian). *Anat Histol Embryol*, 28, 253-256, 1999. DOI: 10.1046/j.1439-0264.1999.00202.x
- 8. Janssens L, Perri A, Crombe P, Dongen SV, Lawler D:** An evaluation of classical morphologic and morphometric parameters reported to distinguish wolves and dogs. *J Archeol Sci Rep*, 23, 501-533, 2019. DOI: 10.1016/j.jasrep.2018.10.012
- 9. Onar V, Kahvecioğlu KO, Çebi V:** Computed tomographic analysis of the cranial cavity and neurocranium in the German shepherd dog (Alsatian) puppies. *Vet Arhiv*, 72 (2): 57-66, 2002.
- 10. Onar V, Kahvecioğlu O, Mutuş R, Alpak H:** Alman kurt köpeklerinde mandibula'nın morfometrik analizi. *Turk J Vet Anim Sci*, 23 (2): 329-334, 1999.
- 11. Slice DE:** Geometric morphometrics. *Annu Rev Anthropol*, 36, 261-281, 2007.
- 12. Drake AG, Coquerelle M, Kosintsev PA, Bachura OP, Sablin M, Gusev AV, Fleming LS, Losey RJ:** Three-dimensional geometric morphometric analysis of fossil canid mandibles and skulls. *Sci Rep*, 7, 9508, 2017. DOI: 10.1038/s41598-017-10232-1
- 13. Selba MC, Oechtering GU, Heng HG, Deleon VB:** The impact of selection for facial reduction in dogs: Geometric morphometric analysis of canine cranial shape. *Anat Rec (Hoboken)*, 303 (2): 330-346, 2020. DOI: 10.1002/ar.24184
- 14. Gieger M, Evin A, Sanchez-Villagra MR, Gascho D, Mainini C, Zollikofer CPE:** Neomorphosis and heterochrony of skull shape in dog domestication. *Sci Rep*, 7, 13443, 2017. DOI: 10.1038/s41598-017-12582-2
- 15. Curth S, Fischer MS, Kupczik K:** Can skull form predict the shape of the temporomandibular joint? A study using geometric morphometrics on the skulls of wolves and domestic dogs. *Ann Anat*, 214, 53-62, 2017. DOI: 10.1016/j.aanat.2017.08.003
- 16. Curth S, Fischer MS, Kupczik K:** Patterns of integration in the canine skull: An inside view into the relationship of the skull modules of domestic dogs and wolves. *Zoology*, 125, 1-9, 2017. DOI: 10.1016/j.zool.2017.06.002
- 17. Boroni NL, Lobo LS, Romano PSR, Lessa G:** Taxonomic identification using geometric morphometric approach and limited data: An example using the upper molars of two sympatric species of Calomys (Cricetidae: Rodentia). *Zoologia*, 34:e19864, 2017. DOI: 10.3897/zoologia.34.e19864
- 18. Yalçın H, Kaya MA, Arslan A:** Comparative geometrical morphometries on the mandible of Anatolian wild sheep (*Ovis gmelini anatolica*) and Akkaraman sheep (*Ovis aries*). *Kafkas Univ Vet Fak Derg*, 16 (1): 55-61, 2010. DOI: 10.9775/kvfd.2009.385
- 19. Lu X, Ge D, Xia L, Huang C, Yang Q:** Geometric morphometric study of the skull shape diversification in Sciuridae (Mammalia, rodentia). *Integr Zool*, 9, 231-245, 2014. DOI: 10.1111/1749-4877.12035
- 20. Rohlf FJ:** TpsUtil, Version 1.60. Department of Ecology and Evolution,

State University of New York, Stony Brook, NY, 2013.

21. Rohlf FJ: TpsDig2, Version 2.18. Department of Ecology and Evolution, State University of New York, at Stone Brook, USA, 2015.

22. Hammer Ø, Harper DAT, Ryan PD: PAST: Paleontological statistics software package for education and data analysis. *Palaeontol Electron*, 4 (1): 1-9, 2001.

23. Klingenberg CP: MorphoJ: An integrated software package for geometric morphometrics. *Mol Ecol Resour*, 11 (2): 353-357, 2011. DOI: 10.1111/j.1755-0998.2010.02924.x

24. Cardini A, Elton S: Sample size and sampling error in geometric morphometric studies of size and shape. *Zoomorphology*, 126, 121-134, 2007. DOI: 10.1007/s00435-007-0036-2

25. Figueirido B, Serrano-Alarcon FJ, Palmqvist P: Geometric morphometrics shows differences and similarities in skull shape between the red and giant pandas. *J Zool*, 286, 293-302, 2012. DOI: 10.1111/j.1469-7998.2011.00879.x

26. Russel AP, Thomason JJ: Mechanical analysis of the mammalian

head skeleton. **In**, Hanken J, Hall BK (Eds): *The Skull. Functional and Evolutionary Mechanisms*. Vol 3, 345-383, The University of Chicago Press, Chicago, Illinois, 1993.

27. Herring SW: Masticatory muscles and the skull: A comparative perspective. *Arch Oral Biol*, 52, 296-299, 2007. DOI: 10.1016/j.archoralbio.2006.09.010

28. Igado OO: Skull typhology and morphometrics of the Nigerian Local Dog (*Canis lupus familiaris*). *Niger J Physiol Sci*, 32, 153-158, 2017.

29. Milencovic M, Spedic VJ, Blagojevic J, Tatovic S, Vujosevic M: Skull variation in Dinaric-Balkan and Carpathian gray wolf populations revealed by geometric morphometric approaches. *J Mammal*, 91 (2): 376-386, 2010. DOI: 10.1644/09-MAMM-A-265.1

30. Olsen SJ, Olsen JW: The Chinese wolf, ancestor of new world dogs. *Science*, 197 (4303): 533-535, 1997. DOI: 10.1126/science.197.4303.533

31. Janssens L, Miller R, Dongen SV: The morphology of the mandibular coronoid process does not indicate that *Canis lupus chanco* is the progenitor to dogs. *Zoomorphology*, 135, 269-277, 2016.