

Mandibular Hypertrophic Osteodystrophy Fibrosa in a German Shepherd Puppy

Elham HASSAN ^{1,a} Faisal TORAD ¹ Ashraf ABU-SEIDA ^{1,b} Azza HASSAN ²

¹ Department of Surgery, Anesthesiology and Radiology, Faculty of Veterinary Medicine, Cairo University, Giza, PO: 12211, EGYPT

² Department of Pathology, Faculty of Veterinary Medicine, Cairo University, Giza, EGYPT

^a ORCID: 0000-0001-9873-144X; ^b ORCID: 0000-0001-5466-2016

Article ID: KVFD-2019-21884 Received: 29.01.2019 Accepted: 27.06.2019 Published Online: 30.06.2019

How to Cite This Article

Hassan E, Torad F, Abu-Seida A, Hassan A: Mandibular hypertrophic osteodystrophy fibrosa in a German shepherd puppy. *Kafkas Univ Vet Fak Derg*, 25 (6): 883-886, 2019. DOI: 10.9775/kvfd.2019.21884

Abstract

Hypertrophic osteodystrophy is a developmental disease of unknown etiology and affects primarily young rapidly growing large and giant breed dogs. The present study reports a case of mandibular hypertrophic osteodystrophy fibrosa in a 6-month-old male German shepherd puppy admitted with a history of one month decreased appetite, difficulty in chewing, and open mouth with continuous drooling. Clinical examination revealed thickened mandible and filling of the intermandibular space with hard tissue. Radiography revealed bone-like material filling the intermandibular space. Biopsy from the thickened mandibular mass demonstrated marked osteoclastic activity and resorption of bone trabeculae that were replaced by fibrous connective tissue. The marrow cavity was filled with massive fibrous tissue mixed with hemorrhage and osteoclasts. Hypertrophic osteodystrophy fibrosa should be taken into consideration in dogs with mandibular masses. Radiography and histologic evaluation are suitable tools to differentiate hypertrophic osteodystrophy fibrosa from mandibular neoplasms and cranio-mandibular osteopathy.

Keywords: Bone resorption, Dog, Hypertrophic osteodystrophy, Mandibular masses, Osteoclasts, Teeth

Bir Alman Çoban Köpeği Yavrusunda Mandibular Hipertrofik Fibröz Osteodistrofi Olgusu

Öz

Hipertrofik osteodistrofi, etiyolojisi bilinmeyen bir gelişim dönemi hastalığıdır ve birincil olarak genç ve hızlı büyüyen büyük ırk köpekleri etkiler. Bu çalışma ile, bir aydır süren iştahta azalma, çiğneme zorlanması, ağzın sürekli açık kalması ve salya birikimi semptomları olan 6 aylık bir erkek Alman çoban köpeğinde mandibular fibröz hipertrofik osteodistrofi vakası bildirildi. Klinik muayenede mandibulanın kalınlaştığı ve intermandibular boşluğun sert doku ile dolu olduğu belirlendi. Radyografide intermandibular boşluğun kemik benzeri materyal ile dolduğu görüldü. Kalınlaşmış mandibular kitleden alınan biyopside belirgin osteoklastik aktivite ile birlikte kemik trabeküllerinin rezorpsiyonu ve fibröz bağ dokusu ile yer değiştirdiği gözlemlendi. Kemik boşluğu, kanama ve osteoklastlarla karışık halde masif fibröz doku ile doluydu. Mandibular kitle belirlenen köpeklerde fibröz hipertrofik osteodistrofi dikkate alınmalıdır. Radyografi ve histolojik değerlendirme, fibröz hipertrofik osteodistrofiyi mandibular neoplazilerden ve kranio-mandibular osteopatiden ayırmak için uygun yöntemlerdir.

Anahtar sözcükler: Kemik rezorpsiyonu, Köpek, Hipertrofik osteodistrofi, Mandibular kitle, Osteoklastlar, Diş

INTRODUCTION

Canine hypertrophic osteodystrophy fibrosa is a developmental disease of unknown etiology affecting young growing large and giant breed dogs^[1]. It has been reported in Great Dane, Irish Wolfhound, Saint Bernard, Boxer, Dalmatian, Irish setter, Weimaraner, Doberman pinscher, German shep-

herd, Labrador retriever, Collie, Greyhound and even the Bassett hound and some Terrier types^[2-4]. It is characterized by extensive bone resorption, proliferation of fibrous connective tissues, and insufficient mineralization of the bones^[3,4]. The disease affects long bones as well as those with high rates of renovation such as the mandible and the maxilla that may develop gradual swollenness and deformities^[3,4].



İletişim (Correspondence)



+20 100 1997359 (Mobile)



ashrafseida@cu.edu.eg

This report records the clinical, laboratory, radiographic and histologic findings of a rare case of mandibular hypertrophic osteodystrophy fibrosa in a six-month-old German shepherd puppy.

CASE HISTORY

A six-month-old male German shepherd puppy was admitted to the clinic of the Department of Surgery, Anesthesiology and Radiology, Faculty of Veterinary Medicine, Cairo University, Egypt, with a history of one month decreased appetite, difficulty in chewing, and open-mouth with continuous drooling of saliva. The owner had declared no history of oral and mandibular trauma. The puppy was fed on a commercial dry food of high protein content (Protein; 27% fat; 12%, calcium; 1.85%, phosphorus; 1.27% and crude fiber; 5.7%) and completed its routine vaccination against Canine Distemper virus, Canine Adenovirus Type 2, Canine Parainfluenza virus, Canine Parvovirus, Corona virus, bacterin of *Leptospira canicola* and *L. icterohaemorrhagiae* (VANGUARD 5/VC-L®, Zoetis Ltd, Sandton, South Africa) and rabies vaccine (Defensor® 3, Zoetis Ltd, Sandton, South Africa) at 4 months of age.

Oral examination revealed a fixed, firm, painless mandibular mass filling the intermandibular space extending from the mandibular symphysis at the level of tooth 301 to tooth 310 (the left incisors to the left second mandibular molar tooth, Fig. 1).

The left mandibular teeth were loose when compared to the right ones. No detectable abnormalities were recorded when palpating the right mandibular body and ramus. Bilateral symmetric non-edematous firm swellings were also noticed over the distal extremity of radius and ulna of both fore limbs without obvious lameness. The rectal temperature was 37.8°C, the heart rate was 92 beat/min and the respiratory rate was 32 breath/min.

Open mouth ventro-dorsal mandibular radiograph revealed unilateral increased bone thickness and density of the

mandible, the left half of the intermandibular space was filled with radiopaque bone-like material compared to the right half. This radiopaque material was extending from the level of left mandibular first incisor tooth (tooth 301) to the level of left mandibular second molar tooth (tooth 310, Fig. 2).

Cranio-caudal and medio-lateral radiographic examinations of the swollen fore limbs revealed an increased bone thickness of the distal ulna of both fore limbs and irregular periosteal reactions with palisading extra-periosteal cuff of mineralization along the distal ulna. Sclerosis of the metaphysis adjacent to the growth plate parallel to the physis was also recorded (Fig. 3). Survey radiographs of the thorax and abdomen were unremarkable.

Ultrasonographic examination of the thyroid gland did not

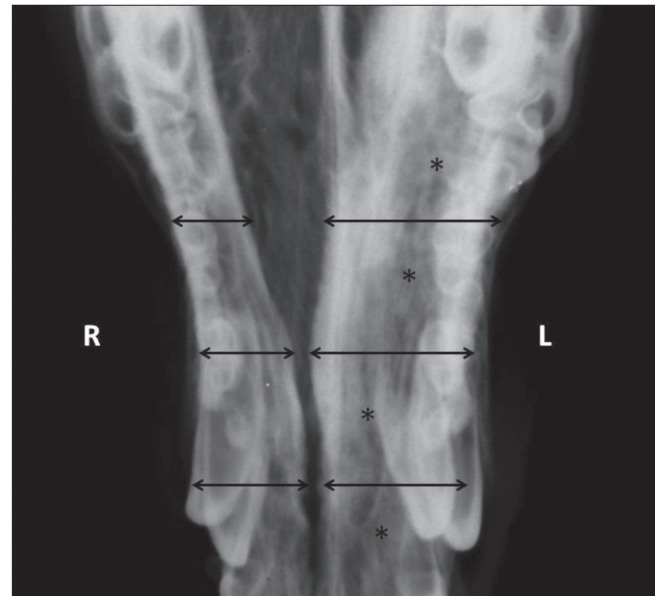


Fig 2. Intra oral ventro-dorsal radiograph of the mandible demonstrating thickening of the left mandible (arrows) with increased bone opacity of the left side of the mandible (asterisks)

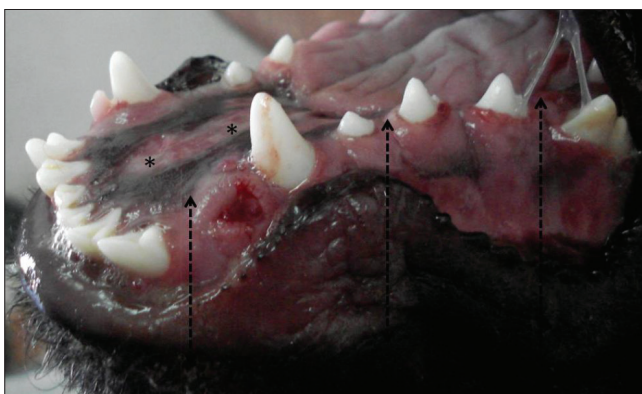


Fig 1. Photograph demonstrating the presence of profuse salivation, thickening of the mandible (arrows) and filling of the intermandibular space with firm tissue (asterisks) with loosening of left mandibular teeth

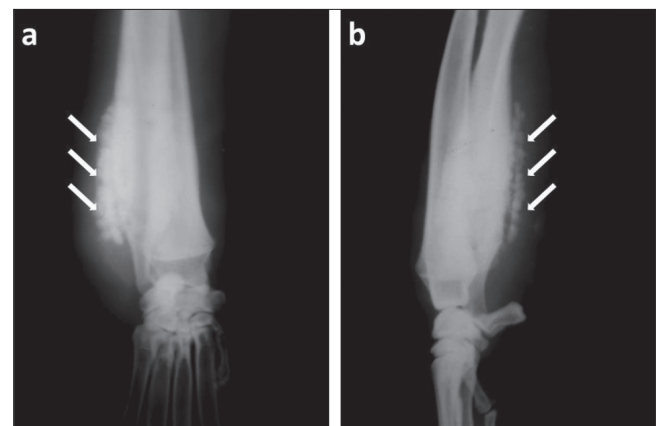
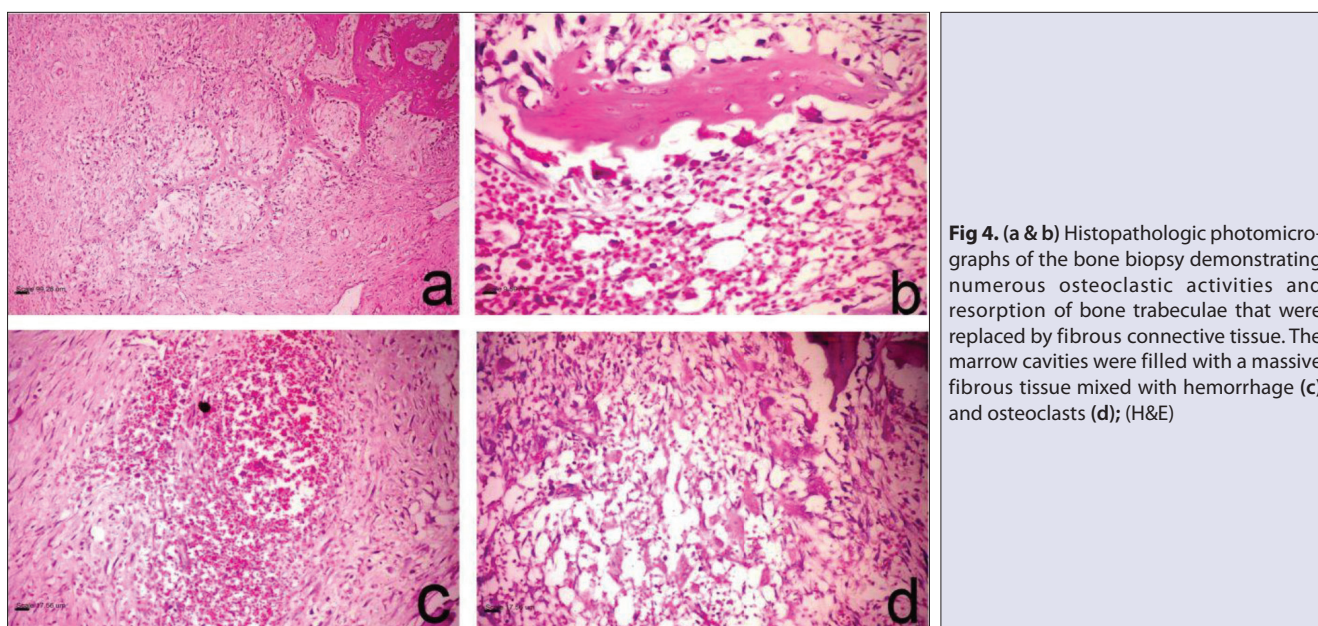


Fig 3. Cranio-caudal (a) and medio-lateral (b) radiographs of the distal radius and ulna demonstrating paraperiosteal mineralization (arrows) with sclerosis of the metaphysis adjacent to the growth plate



reveal any abnormalities. The thyroid gland was visualized as a homogenous bi-lobed hypoechoic fusiform structure surrounded by echogenic capsule located between the common carotid artery and trachea. The parathyroid glands could not be identified.

Complete hematologic and biochemical examinations were done including CBC, liver (ALT 35 IU/L, AST 55 IU/L, total protein 6.2 g/dL) and kidney function tests (urea 19 mg/dL, creatinine 1.7 mg/dL), thyroid function (T3 130 ng/dL, T4 2.1 µg/dL), parathyroid function (PTH 15 pg/dL), serum alkaline phosphatase (45 IU/L), serum calcium (9 mg/dL) and phosphorus (4.3 mg/dL) values. All of the laboratory findings were within normal reference range.

Intra-oral biopsy was obtained through deep incisional needle bone biopsy performed under strict aseptic precaution and general anesthesia as follows: The puppy was premedicated with Atropine sulphate (Atropine sulphate® 1%, ADWIA Co., Egypt) at a dose of 0.05 mg/kg body weight given SC and Xylazine HCl (Xylaject® 2%, ADWIA Co., Egypt) at a dose 1.1 mg/kg body weight given IM. Then the puppy was given Thiopental sodium (Thiopental sodium®, EPICO, Egypt) 2.5% at a dose of 25 mg/kg body weight given IV. Histopathological examination of the biopsy sample revealed resorption of the bone trabeculae that were replaced by fibrous connective tissue and were associated with numerous osteoclastic activities (Fig. 4-a,b). The marrow cavity was filled with massive fibrous tissue mixed with hemorrhage (Fig. 4-c) and osteoclasts (Fig. 4-d). Based on histopathologic examination, the diagnosis was confirmed that the puppy had mandibular hypertrophic osteodystrophy fibrosa.

Conservative management of the puppy was carried out. Oral Meloxicam at a dose of 0.2 mg/kg once daily for 7

days (Mobic®, 7.5 mg tablet, Boehringer Ingelheim International GmbH, Germany), vitamin C 1 g daily (Vita C®, Misr Pharmaceutical Co., Egypt) and vitamin D 5 mg daily (Devarol S®, Memphis Co. for Pharm. Chem. Ind., Egypt) were given to the puppy. One week later, the dog was completely off food, hypothermic (36°C), lethargic and reluctant to move with a tendency to lay down. The owner was advised to feed the dog soft diet through a feeding tube along with the fluid therapy. Maintenance fluid therapy was performed by intravenous administration of dextrose 5% solution at a dose of 5 mL/kg/h. The puppy was unresponsive to treatment and died as a result of severe cachexia and debility.

DISCUSSION

The present report describes the clinical, laboratory, radiographic and histopathologic findings of a case of mandibular hypertrophic osteodystrophy fibrosa in a six-month-old German shepherd puppy.

Similar to a previous report [5], the exact cause and pathogenesis of such a condition remain unknown. Proposed causes may include nutritional imbalance, vaccination, canine distemper virus and heritability in some dog breeds [6]. Puppies between 5-8 months of age are at the highest risk of disease progression [5]. Puppies are usually presented with multisystemic clinical signs including anorexia, depression with swollen painful metaphyses [7].

The recommended treatment for hypertrophic osteodystrophy is usually nonspecific and directed to alleviate the non-specific clinical signs. The use of nonsteroidal anti-inflammatories with supportive care is considered appropriate [2]. However, some dogs may fail to respond to nonsteroidal anti-inflammatories and necessitates switching to corticosteroids [8]. The exact cause of hyper-

trophic osteodystrophy remains unknown [2]. The disease was first believed to be due to vitamin C deficiency due to its similarity with infantile scurvy [2], and the decreased plasma levels of vitamin C in dogs with hypertrophic osteodystrophy [4]. So it was advised to include vitamin C in treatment plan. Previous studies recorded that dogs may recover from hypertrophic osteodystrophy whether supplemented with vitamin C or not [4]. On the contrary, other studies reported that vitamin C, D and mineral supplementation may accelerate the rate of dystrophic calcification and diminish the rate of bone remodeling [4]. Evidence suggests that all treatment plans are somewhat successful with correction of dietary imbalance with no proof of a uniform cure [4].

The decreased appetite and excessive salivary secretion reported in the present case was mainly attributed to severe pain, teeth loosening as well as swelling of mandibular symphysis which prevented effective prehension and chewing of food. The teeth of the affected left mandible were loose as a result of bone resorption and fibrous tissue replacement.

The radiographic findings of hypertrophic osteodystrophy should be differentiated from mandibular neoplasm, cranio-mandibular osteopathy and fibrous osteopathy [6]. Neoplastic bone growths could be differentiated by displaying lytic appearance and the locally aggressive behavior of oral and maxillofacial canine osteosarcomas [9]. Moreover, maxillofacial osteosarcoma is a disease of older ages; the mean age for diagnosing dogs with maxillofacial osteosarcoma is 9-10 years [9]. Cranio-mandibular osteopathy is a bilaterally non-neoplastic proliferation of bone on the mandibular body, ramus of the mandible and/or tympanic bulla without osteophyte growths in the mandibular symphysis [2-4]. The new bone is similar in appearance to the bone found in hypertrophic osteodystrophy and may result in lameness. Fibrous osteopathy is a metabolic disease associated with hyperparathyroidism (primary, secondary, or nutritional) with persistent hypercalcemia and hypophosphatemia. Disturbance in thyroid and parathyroid function was excluded in the presented puppy through ultrasonographic and biochemical examinations.

Radiographic changes of the distal ulna in both forelimbs are similar to previous reports describing hypertrophic osteodystrophy fibrosa [10]. These changes provided guidance that the mandibular swelling may be a mandibular form of hypertrophic osteodystrophy fibrosa. The presence of periosteal new bone formation separated from the underlying cortex has been reported in early stages of the disease. The newly formed bone begins at the metaphysis and may extend to the diaphysis in severe cases [11]. Radiographic changes of hypertrophic osteodystrophy

should be differentiated from hematogenous osteomyelitis and panostitis.

In the current case presentation, the diagnosis was confirmed by histopathological examination, which revealed osteoclastic resorption of bone trabeculae that were replaced by fibrous connective tissue.

In conclusion, hypertrophic osteodystrophy fibrosa should be taken into consideration in dogs with mandibular swellings and should be differentiated by radiography and histology from other mandibular masses including mandibular neoplasms and cranio-mandibular osteopathy. Histopathological examination provided a definite diagnosis of mandibular hypertrophic osteodystrophy fibrosa. The main limitation of the present study is the absence of long term follow up due to death of the animal.

CONFLICT OF INTEREST STATEMENT

All authors declare no conflict of interest for the presented case report.

REFERENCES

1. Demko J, McLaughlin R: Developmental Orthopedic Disease. *Vet Clin North Am: Small Anim Pract*, 35, 1111-1135, 2005. DOI: 10.1016/j.cvsm.2005.05.002
2. Miller C: Hypertrophic osteodystrophy in a Great Dane puppy. *Can Vet J*, 42, 63-66, 2001.
3. Franklin MA, Rochat MC, Broaddus KD: Hypertrophic osteodystrophy of the proximal humerus in two dogs. *J Am Anim Hosp Assoc*, 44, 342-346, 2008. DOI: 10.5326/0440342
4. Safra N, Johnson EG, Lit L, Foreman O, Wolf ZT, Aguilar M, Karmi N, Finno CJ, Bannasch DL: Clinical manifestations, response to treatment, and clinical outcome for Weimaraners with hypertrophic osteodystrophy: 53 cases (2009-2011). *J Am Vet Med Assoc*, 242, 1260-1266, 2013. DOI: 10.2460/javma.242.9.1260
5. Schwarz T, Störk CK, Megahy IW, Lawrie AM, Lochmüller EM, Johnston PEJ: Osteodystrophia fibrosa in two guinea pigs. *J Am Vet Med Assoc*, 219, 63-66, 2001. DOI: 10.2460/javma.2001.219.63
6. Gjeltema JL, MacLean RA, Cohen EB, De Voe RS: Hypertrophic osteodystrophy in two red wolf (*Canis rufus*) pups. *Case Rep Vet Med*, 2015:970742, 2015. DOI: 10.1155/2015/970742
7. Adagra C, Spielman D, Adagra A, Foster DJ: Metaphyseal osteopathy in a British Shorthair cat. *J Feline Med Surg*, 17, 367-370, 2014. DOI: 10.1177/1098612X14536422
8. Harrus S, Waner T, Aizenberg I, Safra N, Mosenco A, Radoshitzky M, Bark H: Development of hypertrophic osteodystrophy and antibody response in a litter of vaccinated Weimaraner puppies. *J Small Anim Pract*, 43, 27-31, 2002. DOI: 10.1111/j.1748-5827.2002.tb00006.x
9. Lenehan TM, Fetter AW: Hypertrophic osteodystrophy. In: Newton CD, Nunamaker DM (Eds): *Textbook of Small Animal Orthopedics*. Philadelphia: Lippincott, 597-601, 1985.
10. Farcas N, Arzi B, Verstraete FJM: Oral and maxillofacial osteosarcoma in dogs: A review. *Vet Comp Oncol*, 12, 169-180, 2014. DOI: 10.1111/j.1476-5829.2012.00352.x
11. Hill M, Scudder CJ, Glanemann B, Drees R: Hypertrophic osteodystrophy in a dog imaged with CT. *Vet Rec Case Rep*, 3:e000155, 2015. DOI: 10.1136/vetreccr-2014-000155