

Effect of Sugammadex and Rocuronium Combination on Cranial Neurotoxicity in Rats: Experimental Study

Öznur ULUDAĞ^{1,a}

¹ Anesthesiology and Reanimation Department, Adiyaman University, Medical School, TR-02100 Adiyaman - TURKEY

^a ORCID: 0000-0002-6017-5836

Article ID: KVFD-2019-21885 Received: 29.01.2019 Accepted: 27.05.2019 Published Online: 27.05.2019

How to Cite This Article

Uludağ Ö: Effect of sugammadex and rocuronium combination on cranial neurotoxicity in rats: Experimental study. *Kafkas Univ Vet Fak Derg*, 25 (6): 793-799, 2019. DOI: 10.9775/kvfd.2018.21885

Abstract

Sugammadex is frequently used in clinical anesthetic practice. In order to determine whether sugammadex has neurotoxic effect, histopathological evaluation and antioxidant status of brain and cerebellum tissues were investigated. Thirty-two adult sprague dawley rats were divided into four groups. Purine Control Group (Group 1, n=8) had no action. The control group (Group 2, n=8) received 16 mg/kg serum physiologic, the sugammadex group (Group 3, n=8) received 16 mg/kg sugammadex and the sugammadex+rocuronium group (Group 4, n=8) received 16 mg/kg sugammadex and 1 mg/kg rocuronium. After drug administration, brain and cerebellum tissues were evaluated histological and biochemically for oxidative damage. The overall structure of the brain and cerebellum tissues were normal in all groups. Images of the layers and the neurons contained there in were normal. No pathological findings were found. There had no statistically significant difference between the groups in terms of glutathione enzyme activity levels (GSH-Px) and the malondialdehyde (MDA) levels in rat brain. GSH-Px and MDA levels had a slight increase in sugammadex and sugammadex+rocuronium group in cerebellum tissues. These increases were statistically significant. But this increase did not cause any histopathological damage to the cerebellum tissue. The study demonstrates that sugammadex is safe for reversal of rocuronium effects in rats. Sugammadex in the dose ranges used in the studies, did not produce adverse effects in rats brain and cerebellum tissues.

Keywords: Rat, Neuromuscular Block, Sugammadex, Rocuronium, Brain tissues, Cerebellum tissues, Neurotoxicity

Ratlarda Sugammadex ve Rocuronium Kombinasyonunun Kraniyal Nörotoksisite Üzerine Etkisi: Deneysel Çalışma

Öz

Sugammadex klinik anestezi uygulamalarında sıklıkla kullanılır. Sugammadexin nörotoksik etkiye sahip olup olmadığını belirlemek için, beyin ve serebellum dokularının histopatolojik değerlendirilmesi ve antioksidan durumu araştırıldı. Otuz iki yetişkin sprague dawley sıçanı dört gruba ayrıldı. Purin Kontrol Grubuna (Grup 1, n=8) işlem yapılmadı. Kontrol grubuna (Grup 2, n=8) 16 mg/kg serum fizyolojik verildi. Sugammadex grubuna (Grup 3, n=8) 16 mg/kg sugammadex ve sugammadex+rocuronium grubuna (Grup 4, n=8) 16 mg/kg sugammadex ve 1 mg/kg rocuronium verildi. İlaç uygulamalarından sonra beyin ve beyincik dokuları histolojik ve oksidatif hasar açısından biyokimyasal olarak değerlendirildi. Beyin ve beyincik dokusunun genel yapısı tüm gruplarda normaldi. Katmanların ve içerdiği nöronların görüntüleri normaldi. Patolojik bulgu bulunamadı. Gruplar arasında sıçan beyinde glutatyon enzim aktivite düzeyleri (GSH-Px) ve malondialdehit (MDA) düzeyleri açısından istatistiksel olarak anlamlı bir fark yoktu. Serebellum dokularında GSH-Px ve MDA düzeyleri sugammadex ve sugammadex+rocuronium grubunda hafif bir artış gösterdi. Bu artışlar istatistiksel olarak anlamlıydı. Ancak bu artış, beyincik dokusunda histopatolojik hasara neden olmadı. Çalışma, sugammadexin sıçanlarda rocuronium etkisinin tersine çevrilmesinde güvenli olduğunu göstermektedir. Çalışmada kullanılan doz aralıklarında sugammadex sıçan beyni ve beyincik dokularında olumsuz etki oluşturmamıştır.

Anahtar sözcükler: Rat, Nöromusküler Blok, Sugammadex, Rocuronium, Beyin dokusu, Beyincik dokusu, Nörotoksisite

INTRODUCTION

In general anesthesia, muscle relaxant agents have used to facilitate surgical applications. Muscle relaxants are two types as depolarizing and non-depolarizing. Non-depolarizing muscle relaxants compete with acetylcholine (Ach) to bind

to nicotinic receptors at the neuromuscular junction^[1]. Rocuronium is the most commonly used steroid-building agent in non-depolarizing muscle relaxants. In order to regain the muscle functions of the patient and prevent residual neuromuscular block, it is necessary to remove the effect of the muscle relaxant agents temporarily^[2,3]. Classic



İletişim (Correspondence)



+90 416 2231690 Fax: +90 416 2231693



uludagoznur@gmail.com

reversal agents, such as neostigmine, implement their activity by raising the levels of Ach at the neuromuscular junction by competitive inhibition of Ach-esterase. Classic reversal agents may cause side effects owing to their nonselective potentiation of muscarinic Ach receptors [4]. Sugammadex is a recently developed γ -cyclodextrine, prepped to keep non-depolarising neuromuscular blocking agents. Sugammadex reverses the neuromuscular block of rocuronium. The agent does not bind to plasma proteins and biologically passive. It has no effectiveness on Ach-esterase or any receptor system in the body. Because of its ability to rapidly reverse neuromuscular block, reducing residual block formation and ensuring patient safety, its use is increasing day by day [5]. In animal and human studies, it has been proved that sugammadex reverses the muscle relaxant effect of rocuronium. Although the safety and efficacy were reported in the studies, the side effects were not clearly demonstrated [6,7].

In general, oxidative stress is considered to be an early marker of neurological disease, and therefore, early oxidative stress detection is considered to be of great preventive value [8]. Drugs can cause free radical damage with their metabolites. Free oxygen radicals on cell membrane fatty acids initiate lipid peroxidation. Oxidation of polyunsaturated fatty acids result in aldehydes. Malondialdehyde (MDA) is the best known aldehyde. MDA causes cross-linking and polymerization of membrane components. MDA neutralizes receptors and membrane-bound enzymes in membranes. It can also cause serious damage to membrane proteins. The most known glutathione peroxidase (GSH-Px) in live tissues is amongst antioxidants. Antioxidants repair oxidative damage and neutralize various reactive intermediates. Brain tissue is one of the most susceptible tissues of free radical-induced oxidative damage. MDA and GSH-Px are most commonly used to determine the oxidative damage caused by free radicals in tissues [9]. Although the penetration of sugammadex is minimal in the blood-brain barrier, studies have suggested that sugammadex may be neurotoxic [10]. Studies have shown that sugammadex activates mitochondria-dependent apoptosis. Depletion of neuronal cholesterol levels has been shown as a cause. Cholesterol homeostasis was associated with oxidative stress [11]. Therefore, we planned to study oxidative stress in brain and cerebellum tissue.

In this study it was evaluated neuropathological effects of sugammadex in rats by biochemical and histopathological methods. Additionally, this preclinical study compared the neurotoxic effects of sugammadex with sugammadex and rocuronium combination.

MATERIAL and METHODS

Ethics Approval

The study protocol was approved by the Local Ethics

Committee for Animal Experiments of Adiyaman University, Turkey (Approval no: ADYU-HADYEK: 2018-2).

Animals

All experiments were conducted according to our National Institute of Health Guide for the Care and Use of Laboratory Animals [12]. The study was conducted in Experimental Animal Laboratory (Adiyaman, Turkey) in 2018. Thirty-two pieces, adult Sprague-Dawley male rats weighing 300-350 g were fed with standard pellet diet and water *ad libitum*. Room temperature (22-25°C) and humidity (50-55%) were monitored daily. Lighting was provided using cool white fluorescent lamps, with 12-h light and dark cycles (06.00-18.00).

Experimental Groups

The animals were divided into four groups (n=8).

Group 1 (Purine Control Group): The rats were consisted of animals with maintenance conditions in accordance with routine ethical rules that were not performed surgical treatment.

Group 2 (Control Group): The rats were given 16 mg/kg intravenous (IV) 0.9% isotonic saline.

Group 3 (Sugammadex Group): The rats were given 16 mg/kg IV Sugammadex (Bridion®; Schering-Plough Corporation, Oss, Netherlands).

Group 4 (Sugammadex + Rocuronium Group): The rats were given 1 mg/kg IV rocuronium (Esmeron®; Organon, Istanbul, Turkey) and three min later 16 mg/kg IV sugammadex (Bridion®; Schering-Plough Corporation, Oss, Netherlands).

All drugs were administered intravenously over the tail vein. Three days after the appropriate action, the brain and cerebellum tissues under ketamine/xylazine anesthesia were atraumatically removed from the skull by dissection starting from the neck. Brain and cerebellum tissues were divided into interhemispheric incisions for biochemical and histological examinations.

Biochemical Evaluation

The removed brain and cerebellum tissue samples were washed with saline at a temperature of +4°C, were placed in ependorf tubes according to the cold chain principles and stored at -70°C until examined. In tissue samples, tissue homogenates for MDA and GSH-Px measurements were prepared in cold with 0.15 M KCl (10%, w/v) homogenizer.

Malondialdehyde; lipid peroxidation is an indirect indicator of the amount of free oxygen radical formed in the tissue. The tissue MDA concentration as a marker of lipid peroxidation is based on the method of Uchiyama [13] the supernatant extracted from the N-butanol phase of the pink colored product as a result of the MDA reacting with thiobarbituric

acid at 95°C was determined by spectrophotometer at 535 and 520 nm. Brain tissue was homogenized in 10% trichloroacetic acid and then centrifuged. After mixing the superficial liquid part with an equal volume of 0.67% thiobutyric acid, it was incubated in boiling water for 15 min at 90°C, then cooled and centrifuged. The tissue MDA concentrations were measured in nmol/g tissue under 532 nm absorbance.

Glutathyon peroksidaz; GSH-Px catalyzes the reduction of harmful peroxides such as lipid peroxide and hydrogen peroxide. During this reduction, the reduced glutathione is converted into oxidized glutathione. GSH-Px analysis was performed according to the method described by Ellman ^[14] Glutathione in the analysis tube reacted with 5i-dithiobis2-nitrobenzoic acid to give yellow-greenish color and the light intensity of this color was measured by spectrophotometer at a wavelength of 410 nm.

Histological Analysis

Other brain and cerebellum tissues were fixed with 10% formaldehyde at room temperature. Tissues were kept in this solution for ten days. After fixation, the tissues were washed in tap water to remove the fixation solution in the tissue. Then dehydration and polishing were performed according to routine histological tissue follow-up procedure. Finally, the completed tissues were made into paraffin blocks. 10 µm volume was calculated from the paraffin blocks with cavaliere method and 7 µm thick sections were taken for histological examination. For histopathological evaluation, sections were stained with cresyl violet (Merck, Cresyl violet acetate, FN 1107635, Germany). Cresyl violet staining is used in neurosciences to analyze neuron variations in various pathological cases. The images obtained by Carl Zeiss Axiocam ERc5 digital camera attachment microscope were examined and evaluated.

Statistical Analysis

The Statistical Package for the Social Sciences 22.0 program (SPSS Inc., Chicago, IL, USA) was used for the statistical study. The one sample Kolmogorov-Smirnov test was used to determine whether the datas was distributed normally. One Way ANOVA test was used to analyze the MDA and GSH-Px values of the groups. Kruskal-wallis test was used for data not showing normal distribution and Dunnet test for multiple comparisons. Mann-Whitney U test was used to compare the groups. The results were reported as mean±standart deviation (SD). Results were assessed at a 95% confidence interval, and P value <0.05 was accepted as statistically significant.

RESULTS

As a result of the statistical measurements of the rat brain GSH-Px levels: 2022.35±430.02 nmol/g in the purine control group, 2067.22±391.34 nmol/g in the control group, 1917.39±469.98 nmol/g in the sugammadex group, and 2041.58±263.02 nmol/g in the sugammadex + rocuronium group, were found as wet tissue (*Table 1*). Compared study data; There was no statistically significant difference between the groups in terms of GSH-Px level (P=0.881). MDA, which is defined as an indicator of free radical damage in tissues, did not show a significant difference with sugammadex application compared to control groups. In the purine control group 995.36±121.03 nmol/g, in the control group 1012.95±119.70 nmol/g, 886.91±145.05 nmol/g in the sugammadex group and 1090.00±307.35 nmol/g in the sugammadex + rocuronium group. No significant difference was found in MDA levels in brain tissue (P=0.223).

As a result of the statistical measurements of the rat brain GSH-Px levels: 1770.76±74.33 nmol/g in the purine control group, 1785.18±157.27 nmol/g in the control group, 1669.80±126.07 nmol/g in the sugammadex group, and

Table 1. Distribution of GSH-Px and MDA values in brain tissue of groups

Parameter	Brain Tissue				P value
	Purine Control	Control	Suggammadex	Suggammadex + Rocuronium	
GSH-Px (nmol/g)	2022.35±430.02	2067.22±391.34	1917.39±469.98	2041.58±263.02	0.881
MDA (nmol/g)	995.36±121.03	1012.95±119.7	886.91±145.05	1090.00±307.35	0.223

P<0.05

Table 2. Distribution of GSH-Px and MDA values in cerebellum tissue of groups

Parameter	Cerebellum Tissue				P value
	Purine Control (n=8)	Control (n=8)	Suggammadex (n=8)	Suggammadex+ Rocuronium (n=8)	
GSH-Px (nmol/g)	1770.76±74.33 ^{ab}	1785.18±157.27 ^{ab}	1669.8±126.07 ^b	1844.47±75.28 ^a	0.037*
MDA (nmol/g)	1086.65±118.9 ^{ab}	945.95±195.60 ^b	1363.86±375.21 ^a	1342.09±334.49 ^a	0.013*

* There is no statistically significant difference between the groups with the same letters and there is a statistically significant difference between the groups with different letters (P<0.05)

1844.47±75.28 nmol/g in the sugammadex+rocuronium group were found as wet tissue (Table 2). Compared study data; There was statistically significant difference between the groups in terms of GSH-Px level (P=0.037). Increase of GSH-Px is significant in sugammadex and sugammadex+rocuronium group.

Malondialdehyde, which is defined as an indicator of free radical damage in tissues, showed a significant difference with sugammadex application compared to control groups (P=0.013). In the purine control group 1086.65±118.92 nmol/g, in the control group 945.95±195.60 nmol/g, 1363.86±375.21 nmol/g in the sugammadex group and 1342.09±3334.49 nmol/g in the sugammadex+rocuronium group. There was a slight increase in sugammadex and sugammadex rocuronium group. This increase was statistically

significant. When examined with histo-pathological data, it was observed that the increases and decreases were at acute level. The free radical increase due to the increase in MDA did not cause any histopathological damage to the cerebellum tissue.

In the examined sections of the groups, the cortex was wrapped with a loose connective tissue piamater. The layers of the cerebral cortex could not be distinguished apart from the lamina moleculosa (Fig. 1-group 1a,1b,1c). The cells of the nerve tissue were distributed homogeneously to the entire cortex under the lamina moleculosa. The boundaries of the neurons were regular and the nuclei were prominent. Pyramidal neurons were also found between oval or rounded neurons. Cell extensions were prominent and smooth (Fig. 1-group 2a,2b,2c). The general

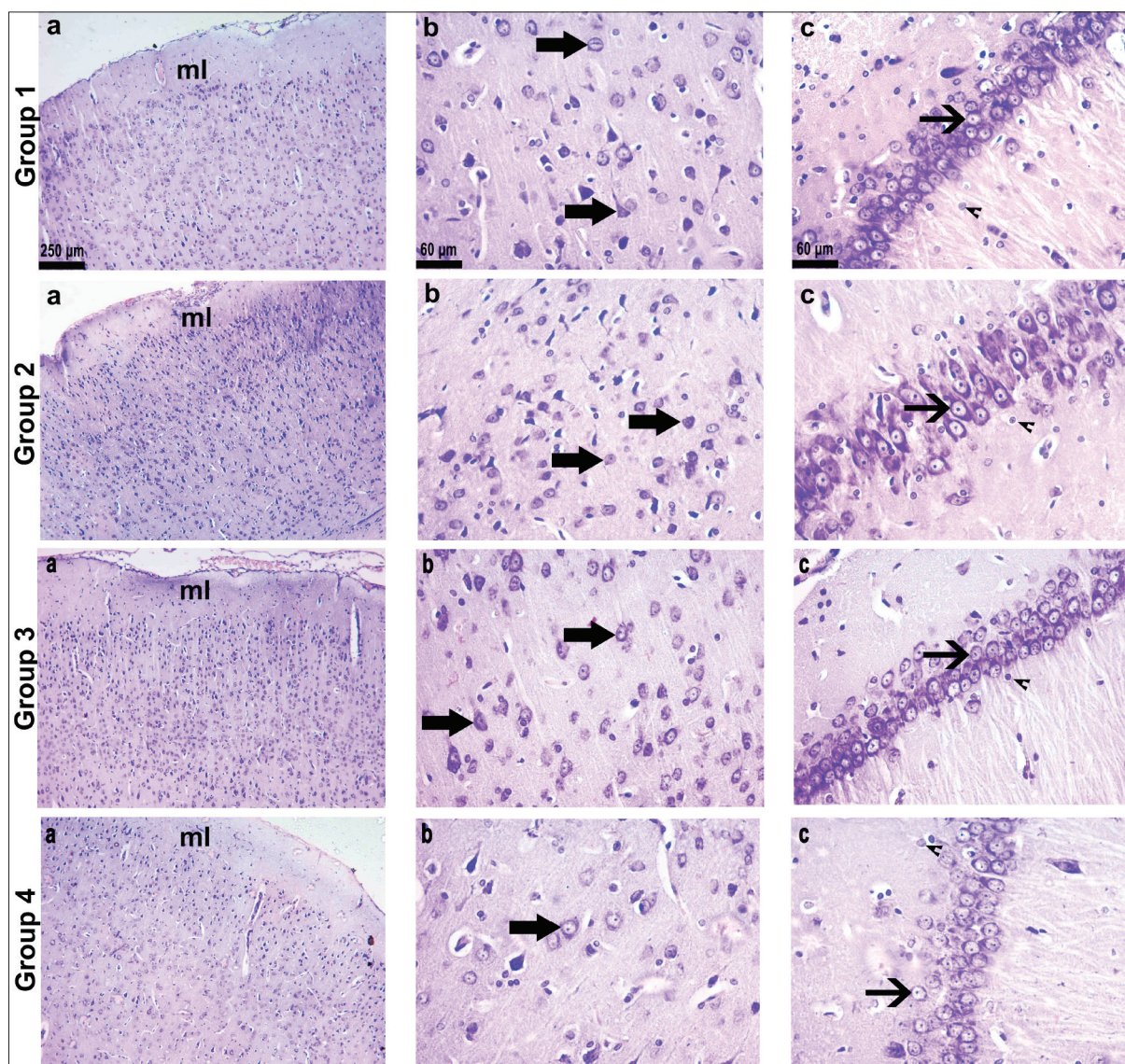


Fig 1. Histopathological evaluation of brain tissues

Light microscopic image of brain tissues belonging to group 1a, group 2a, group 3a and group 4a, respectively (x4, Krezil violet staining); Light microscopic image of group 1b, group 2b, group 3b and group 4b, respectively (x40, Krezil violet staining); Light microscopy of hippocampus belonging to group 1c, group 2c, group 3c and group 4c, respectively (x40, Krezil Violet Coloring); ml; molecular layer; Black thick arrow; pyramidal neurons; Black fine arrow; neurons in the hippocampus; Black arrow head; neuroglial cells

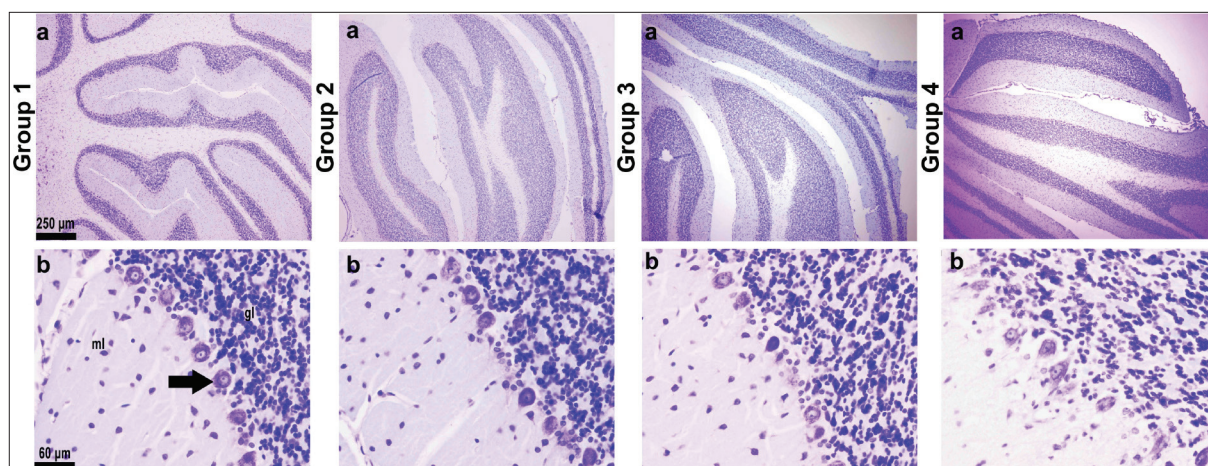


Fig 2. Histopathological evaluation of cerebellum tissues

Light microscopic appearance of cerebellum tissues of group 1a, group 2a, group 3a and group 4a, respectively (x4, Krezil violet staining); Light microscopic image of group 1b, group 2b, group 3b and group 4b, respectively (x40, Krezil violet staining); ml; Lamina moleculare; gl; granular layer; Black thick arrow; purkinje cell

structure of the hippocampus and neurons were normal. At the light microscopic examination, the pericardies of the neurons were well defined; pramidal. In addition, the nuclei of these cells were echromatic and distinctive nucleolus. Dendrites and axons, the extensions of the neurons, were of normal width. Neuroglia cells were also normal (Fig. 1-group 3a,3b,3c). The overall structure of the brain tissue was normal in all groups (Fig. 1-group 4a,4b,4c). Images of the layers and the neurons contained there were normal. No pathological findings were found.

The sections of the cerebellar cortex could be clearly distinguished in the sections examined. On the outermost side of the piamater-wrapped organ, the cortex was composed of lamina molecule, purkinje cell layer (ganglional layer) and granular layer from the outside (Fig. 2-group 1a,1b). The lamina molecule is a neuron-poor layer and the purkinje cells in the ganglional layer with the largest cells of the cerebellum were normal. In these cells, echromatic nucleus and a prominent nucleolus were seen. The dendrite from the top of the Purkinje cells was branched in the molecular layer. The granular layer was composed of multiple small diameter neurons (Fig. 2-group 2a,2b). The overall structure of the cerebellum was normal in all groups (Fig. 2-group 3a,3b; group 4a,4b). Images of the layers and the neurons contained there were normal. No pathological findings were found.

DISCUSSION

Cyclodextrins are chemical entities of natural origin, which are derived from bacterial. Sugammadex is a modified γ -cyclodextrin molecule. Only sugammadex received license for use in cyclodextrin molecules. Others did not pass drug phase tests. It has been understood that sugammadexin has a chemical interaction mechanism called encapsulation with neuromuscular agents [15]. Cyclodextrin molecules are employed to convert lipophilic agents to hydrophilic

forms. Most cyclodextrins affect receptor functions by altering the lipid structure in the cell membrane. In one a study, methyl- β -cyclodextrin has been reported to reduce neuronal excitability in the hippocampal area. Methyl β -cyclodextrin affects cholesterol levels in post-synaptic areas. N-methyl-D-aspartic acid receptor-dependent glutamate transmission may impair the transmission [16]. Neuroprotective effects have been demonstrated in studies with methyl- β -cyclodextrin and 2-hydroxypropyl- β -cyclodextrin [17-19]. A recently study was determined that sugammadex had a neuroprotective effect against transient cerebral ischemia. The study showed that treatment with 16 mg/kg and 100 mg/kg sugammadex had a neuroprotective effect in a transient cerebral ischemia/reperfusion injury rat model [20]. They reported that sugammadex had a protective effect against ischemia-reperfusion injury in brain. But a recent study showed that rocuronium has dose-related deleterious effects on the central nervous system and can produce dose-dependent excitatory effects and seizures [21]. Also it is known that rocuronium can permeate the CSF after intravenous injection [22].

Since sugammadex has a high molecular weight, it's passage from the blood brain barrier (BBB) and placenta is low. But, in cases where cholesterol plugs are formed in the cerebral arteries and hypoxia occurs due to insufficient blood flow, tissue damage occurs and BBB structure is broken. In addition, in the case neurodegenerative diseases and traumatic brain or spinal cord injury BBB transition is easier [23].

Experimental studies have shown the neuroprotective characteristics of cyclodextrins, however the adverse effect of sugammadex on neuronal cell cultures has led to debate on this topic. The study showed that sugammadex causes apoptosis and neuron death in primary cell cultures. Sugammadex has been reported to induce apoptotic

activation by leading to oxidative stress and cholesterol hemostasis. Sugammadex reduced membrane-related cholesterol levels. They reported that they were sensitive to oxidative stress among neuronal cell types [11]. We took this work as a reference. Although studies have been conducted on the brain, any article in the literature was not directly related to histopathological changes caused by rocuronium or sugammadex in rat cerebellum tissues. We evaluated the MDA and GSH-Px levels as indicators of oxidative stress and free radical injury in the brain and cerebellum tissue. Reversal of neuromuscular blockage induced by steroidal neuromuscular blocking agents such as rocuronium can be achieved using normal dose of sugammadex. Intravenous sugammadex demonstrates linear pharmacokinetic properties over the dose range of 1-16 mg/kg [24]. Therefore, 16 mg/kg sugammadex were given to rats in our study. Isotonic saline was applied to the control group at the same volume. Rats in Group 4 were given sugammadex after rocuronium application. It was determined the effects of sugammadex on the histopathological and biochemical structure of rat brain and cerebellum tissues after neuromuscular blockage. The overall structure of the brain and cerebellum tissues were normal in all groups. No pathological findings were found. There was no statistically significant difference between the groups in terms of glutathione enzyme activity levels and the MDA levels in rat brain. MDA and GSH-Px levels were altered in sugammadex and sugammadex rocuronium group in cerebellum tissue. MDA and GSH-Px levels remained at the acute level and did not show its effect at the pathological level in the tissue. The cerebellum is responsible for the purposeful execution of voluntary movements. The information is transmitted directly to the cerebellum via the proprioceptive receptors in the muscles [25]. Muscle relaxant rocuronium and antagonist sugammadex was effected to oxidative damage in cerebellum. However, the effect was acute and transient because it was not affected histopathologically. To the best of our knowledge although there are studies on the brain, its effect on the cerebellum has not been investigated. We think that this study will shed light on new studies in which the efficacy of the drug will be investigated. This current study, sugammadex and sugammadex-rocuronium applied in rats did not show any neurotoxic effect. Sugammadex in the dose ranges used in the study, did not produce adverse effects in animal study.

For clinicians, it is important to protect the patient's brain during surgery and in intensive care. For this purpose, selection of suitable agents is required. The results obtained in animal experiments provide reference to the use of drugs in humans. The aim of this study was to determine the effect of rocuronium and sugammadex on brain and cerebellum tissues in rats. As a result, rocuronium and sugammadex application had no negative effect on brain and cerebellum tissues. In our study, the neurotoxic effects of the drugs were not observed. For the antagonism of

both peripheral and central long-term residual rocuronium effects, it may be advisable to consider sugammadex.

FUNDING

Not applicable.

CONFLICTS OF INTERESTS

The author declare no conflicts of interests.

ACKNOWLEDGEMENTS

The author would like to thank for histopathological evaluation to Assist. Prof. Dr. Ebru Annaç, for biochemical evaluation to Assist. Prof. Dr. Zümrüt Doğan and the staff of the department of biostatistics and medical informatics at Adiyaman University Faculty of Medicine for statistical analysis.

REFERENCES

- Lien CA:** Development and potential clinical impairment of ultra-short-acting neuromuscular blocking agents. *Br J Anaesth*, 107 (1): i60-i71, 2011. DOI: 10.1093/bja/aer341
- de Boer HD, van Egmond J, van de Pol F, Bom A, Booij LHDJ:** Chemical encapsulation of rocuronium by synthetic cyclodextrin derivatives: Reversal of neuromuscular block in anaesthetized Rhesus monkeys. *Br J Anaesth*, 96 (2): 201-206, 2006. DOI: 10.1093/bja/aei306
- Türk R, Kaya S, Dönmez İ, Özyayın İ, Merhan O, Yayla S, Ertutlu ÇŞ, Kaçar C, Aydın U, Aksoy Ö, Hüseyinoğlu Ü:** The effect of rocuronium and sugammadex on progesterone levels in pregnant rabbits under general anesthesia. *Kafkas Univ Vet Fak Derg*, 25 (2): 179-184, 2019. DOI: 10.9775/kvfd.2018.20609
- Naguib M:** Sugammadex: Another milestone in clinical neuromuscular pharmacology. *Anesth Analg*, 104 (3): 575-581, 2007. DOI: 10.1213/01.ane.0000244594.63318.fc
- Hristovska AM, Duch P, Allingstrup M, Afshari A:** Efficacy and safety of sugammadex versus neostigmine in reversing neuromuscular blockade in adults. *Cochrane Database Syst Rev*, 8:CD012763, 2017. DOI: 10.1002/14651858.CD012763
- Cammu G, De Kam PJ, Demeyer I, Decoopman M, Peeters PA, Smeets JM, Foubert L:** Safety and tolerability of single intravenous doses of sugammadex administered simultaneously with rocuronium or vecuronium in healthy volunteers. *Br J Anaesth*, 100 (3): 373-379, 2008. DOI: 10.1093/bja/aem402
- Pühringer FK, Rex C, Sielenkämper AW, Claudius C, Larsen PB, Prins ME, Eikermann M, Khuenl-Brady KS:** Reversal of profound, high-dose rocuronium-induced neuromuscular blockade by sugammadex at two different time points: an international, multicenter, randomized, dose-finding, safety assessor-blinded, phase II trial. *Anesthesiology*, 109 (2): 188-197, 2008. DOI: 10.1097/ALN.0b013e31817f5bc7
- Marrocco I, Altieri F, Peluso I:** Measurement and clinical significance of biomarkers of oxidative stress in humans. *Oxid Med Cell Longev*, 2017:6501046, 2017. DOI: 10.1155/2017/6501046
- Srivastava KK, Kumar R:** Stress, oxidative injury and disease. *Indian J Clin Biochem*, 30 (1): 3-10, 2015. DOI: 10.1007/s12291-014-0441-5
- Mitchell C, Lobaz S:** An overview of sugammadex. *Anaesthesia Tutorial of the Week*. 1-6, 2016.
- Palanca JM, Aguirre-Rueda D, Granell MV, Aldasoro M, Garcia A, Iradi A, Obrador E, Mauricio MD, Vila J, Gil-Bisquert A, Valles SL:** Sugammadex, a neuromuscular blockade reversal agent, causes neuronal apoptosis in primary cultures. *Int J Med Sci*, 10 (10): 1278-1285, 2013. DOI: 10.7150/ijms.6254

- 12. Uludağ Ö:** Hayvan deneyi çalışmalarında etik kuralların tarihçesi ve önemi. *Adiyaman Üniv Sağlık Bil Derg*, 5 (1): 1401-1413, 2019. DOI: 10.30569/adiyamansaglik.482098
- 13. Uchiyama M, Mihara M:** Determination of malonaldehyde precursor in tissue by TBA test. *Anal Biochem*, 86 (1): 271-278, 1978. DOI: 10.1016/0003-2697(78)90342-1
- 14. Elman GL:** Tissue sulphhydryl groups. *Arch Biochem Biophys*, 82 (1): 70-77, 1959. DOI: 10.1016/0003-9861(59)90090-6
- 15. Kovac AL:** Sugammadex: The first selective binding reversal agent for neuromuscular block. *J Clin Anesth*, 21 (6): 444-453, 2009. DOI: 10.1016/j.jclinane.2009.05.002
- 16. Rufini S, Grossi D, Luly P, Tancredi V, Frank C, D'Arcangelo G:** Cholesterol depletion inhibits electrophysiological changes induced by anoxia in CA1 region of rat hippocampal slices. *Brain Res*, 1298, 178-185, 2009. DOI: 10.1016/j.brainres.2009.08.037
- 17. Frank C, Rufini S, Tancredi V, Forcina R, Grossi D, D'Arcangelo G:** Cholesterol depletion inhibits synaptic transmission and synaptic plasticity in rat hippocampus. *Exp Neurol*, 212 (2): 407-414, 2008. DOI: 10.1016/j.expneurol.2008.04.019
- 18. Abulrob A, Tauskela JS, Mealing G, Brunette E, Faid K, Stanimirovic D:** Protection by cholesterol-extracting cyclodextrins: A role for N-methyl-D-aspartate receptor redistribution. *J Neurochem*, 92 (6): 1477-1486, 2005. DOI: 10.1111/j.1471-4159.2005.03001.x
- 19. Rivers JR, Maggo SDS, Ashton JC:** Neuroprotective effect of hydroxypropyl- β -cyclodextrin in hypoxia-ischemia. *Neuroreport*, 23 (3): 134-138, 2012. DOI: 10.1097/WNR.0b013e32834ee47c
- 20. Ozbilgin S, Yılmaz O, Ergur BU, Hancı V, Ozbal S, Yurtlu S, Gunenc SF, Kuvaki B, Kucuk BA, Sisman AR:** Effectiveness of sugammadex for cerebral ischemia/reperfusion injury. *Kaohsiung J Med Sci*, 32 (6): 292-301, 2016. DOI: 10.1016/j.kjms.2016.05.002
- 21. Baykal M, Gökmen N, Doğan A, Erbayraktar S, Yılmaz O, Ocmen E, Erdost HA, Arkan A:** The effects of intra-cerebroventricular administered rocuronium on the central nervous system of rats and determination of its epileptic seizure-inducing dose. *Braz J Anesthesiol*, 67 (1): 1-5, 2017. DOI: 10.1016/j.bjane.2015.02.010
- 22. Savarese JJ, Caldwell JE, Lien CA, Miller RD:** Pharmacology of muscle relaxants and their antagonists. In, Miller RD (Ed): *Anesthesia*. 5th ed., 412-490, Churchill Livingstone, Philadelphia, 2000.
- 23. Lobaz S, Clymer M, Sammut M:** Safety and efficacy of sugammadex for neuromuscular blockade reversal. *Clin Med Insights Ther*, 6 (2): 1-14, 2014. DOI: 10.4137/CMT.S10241
- 24. Aldasoro M, Jorda A, Aldasoro C, Marchio P, Guerra-Ojeda S, Gimeno-Raga M, Mauricio MD, Iradi A, Obrador E, Vila J, Valles SL:** Neuronal effects of sugammadex in combination with rocuronium or vecuronium. *Int J Med Sci*, 14 (3): 224-230, 2017. DOI: 10.7150/ijms.17545
- 25. Guang H, Ji L:** Proprioceptive recognition with artificial neural networks based on organizations of spinocerebellar tract and cerebellum. *Int J Neural Syst*, 9:1850056, 2018. DOI: 10.1142/S0129065718500569