

The First Case of Anal Myiasis Caused by *Chrysomya albiceps* (Wiedemann, 1819) in a Dog Infested with *Rhipicephalus sanguineus* (Latreille, 1806) Ticks Suspected to Cause Paralysis in Turkey ^[1]

Onur CEYLAN ^{1,a} Bilal DİK ^{1,b} Ceylan İLHAN ^{1,c} Merve İDER ^{2,d} Erdem GÜLERSOY ^{2,e}

^[1] Presented as poster in 20th National Parasitology Congress, September 23-27, 2017, Eskişehir, Turkey

¹ Department of Parasitology, Faculty of Veterinary Medicine, University of Selcuk, TR-42250 Konya - TURKEY

² Department of Internal Medicine, Faculty of Veterinary Medicine, University of Selcuk, TR-42250 Konya - TURKEY

^a ORCID: 0000-0002-3514-5221; ^b ORCID: 0000-0002-7553-5611; ^c ORCID: 0000-0001-8072-2983; ^d ORCID: 0000-0003-2928-5452;

^e ORCID: 0000-0001-8511-0150

Article ID: KVFD-2018-21609 Received: 20.12.2018 Accepted: 17.04.2019 Published Online: 17.04.2019

How to Cite This Article

Ceylan O, Dik B, İlhan C, İder M, Gülersoy E: The first case of anal myiasis caused by *Chrysomya albiceps* (Wiedemann, 1819) in a dog infested with *Rhipicephalus sanguineus* (Latreille, 1806) ticks suspected to cause paralysis in Turkey. *Kafkas Univ Vet Fak Derg*, 25 (5): 721-724, 2019. DOI: 10.9775/kvfd.2018.21609

Abstract

A four-year-old Kangal dog with hundreds of ixodid ticks in the head and neck regions and a large number of myiasis larvae in the anal region were brought to Selcuk University, Faculty of Veterinary Medicine, Department of Internal Medicine. A paralysis covering the anterior and posterior extremities, except the head region was determined in the dog. It was suspected that the paralysis was caused by ticks on the dog after elimination of some other disease. However, no definitive diagnosis was made for paralysis. Collected ticks were identified as *Rhipicephalus sanguineus* (Latreille, 1806). The myiasis larvae collected from the anal region were identified as second and third instars of *Chrysomya albiceps* (Wiedemann, 1819). As a result, it is suggested that *C. albiceps* and *Rh. sanguineus* should be considered in the etiology of myiasis and tick paralysis cases, respectively.

Keywords: *Rhipicephalus sanguineus*, *Calliphoridae*, *Chrysomya*, *Paralysis*, *Myiasis*

Türkiye’de *Rhipicephalus sanguineus* (Latreille, 1806) Kenelerinin Paralize Sebep Olduğundan Şüphe Edilen Bir Köpekte *Chrysomya albiceps* (Wiedemann, 1819)’in Neden Olduğu İlk Anal Miyaz Olgusu

Öz

Baş ve boyun bölgesinde yüzlerce kene ve anal bölgesinde çok sayıda miyaz larvası bulunan dört yaşında kangal köpek Selçuk Üniversitesi Veteriner Fakültesi, İç Hastalıkları Anabilim Dalına getirilmiştir. Köpekte baş bölgesi dışında ön ve arka ekstremiteleri kapsayan bir paraliz tespit edilmiştir. Bu paraliz durumuna diğer bazı hastalıkların eliminasyonundan sonra kenelerin sebep olduğundan şüphe edilmiş, fakat kesin bir tanı konulamamıştır. Toplanan keneler *Rhipicephalus sanguineus* (Latreille, 1806) olarak teşhis edilmiştir. Anal bölgeden toplanan miyaz larvaları ise ikinci ve üçüncü dönem *Chrysomya albiceps* (Wiedemann, 1819) olarak teşhis edilmişlerdir. Sonuç olarak, *C. albiceps*’in miyaz vakalarının, *Rh. sanguineus*’un ise paraliz vakalarının etiolojisinde düşünülmesi gerektiği ileri sürülmüştür.

Anahtar sözcükler: *Rhipicephalus sanguineus*, *Calliphoridae*, *Chrysomya*, *Paraliz*, *Miyaz*

INTRODUCTION

The tick paralysis is caused by inoculation of neurotoxins found in the salivary glands of some tick species during the feeding by sucking blood. Inoculated neurotoxins act by blocking acetyl choline release at neuromuscular junctions and cause paralysis in hosts ^[1]. Paralysis caused by the ticks are commonly seen and sometimes cause deaths in dogs ^[2].

Myiasis is a larva infestation situation in which the fly larvae of the order Diptera are found on vertebrate host at least for a certain period of time and are fed with dead or live tissues, body fluids, and digested foods ^[3]. Although the species causing myiasis in the family of Calliphoridae are mostly found in the genera *Lucilia* and *Calliphora*, the other species in the other genera such as *Chrysomya*, *Cordylobia*, *Phormia* and *Cochliomyia* (*Callitroga*) can rarely cause myiasis. The greater part of the larvae in this genus-



İletişim (Correspondence)



+90 332 2232683



onurceylan@selcuk.edu.tr

related species, also known as hairy maggot, are fed with rotten organic matter and cause facultative wound myiasis. However, species that cause obligator myiasis such as *C. bezziana* are in this genus [3-5].

Chrysomya albiceps has a widespread distribution throughout the world, especially in the Mediterranean region, Transcaucasus, Middle East, Mid-Asia and a large part of Africa. It is reported that the species has a wider distribution compared to the first half of the 20th century and that the distribution has become cosmopolitan day by day [3,6,7]. There are some literatures about the existence of the species in Turkey [8,9].

The female *C. albiceps* lay eggs on rotten animal carcass, the first instar larvae newly hatched from the egg are fed exudate where they are left. The second and third instars become predators for the other Dipteran larvae. For this reason, the larvae usually cause myiasis in live mammals, thanks to predator effects, following myiasis cases initiated by *Lucilia* species. This behaviour possibly lead to a decline in the population numbers of native species [3,10,11].

This case was found worthy of publication due to the first detection of the anal myiasis caused by *C. albiceps* in a dog in Turkey. It also became more important because of the presence of intense *Rh.sanguineus* ticks infestation and paralysis suspected to be caused by these ticks.

CASE HISTORY

A four-year-old male Kangal dog was brought to the Clinic of Internal Medicine, Veterinary Faculty, with complaints of weakness, gait disorder, lying in a horizontal position for 15 days (Fig. 1) and decubitus injuries depending on this. Lethargy, hyperpnea, regurgitation, urinary incontinence and tetraplegia were detected as clinical symptoms. Due to lying in the lateral position continuously, rhabdomyolysis occurred in the dog, and an increase in aspartate aminotransferase (128 U/L) and creatine phosphokinase (2636 U/L) enzyme levels in serum biochemistry was detected. An increase in the level of pO₂ (52.1 mmHg) was observed in blood gases because of hyperpnea. No specific findings were observed in other blood gases, hemogram and serum biochemical parameters. In order to determine the ethiology of paralysis, some diseases and traumatic injuries were evaluated. Among these, snake poisoning was excluded

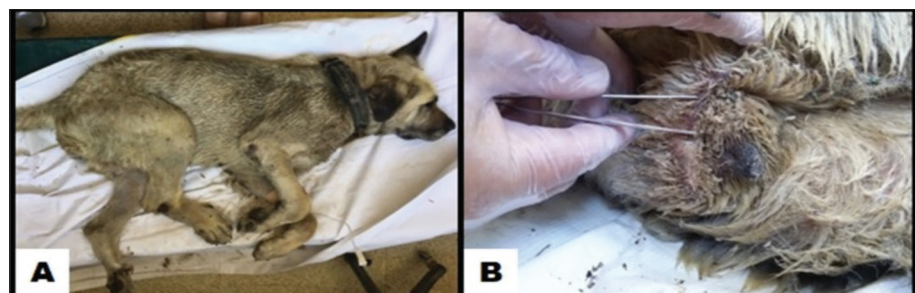
because of the absence of snake bite marks on dog's body. Spinal traumas were excluded because of the absence of trauma in patient's history. Myasthenia gravis was dismissed because of the lack of atrophy of the muscles of mastication and constant ptyalism in physical examination. Botulism was also excluded in the diagnosis. Tick paralysis was suspected because of the presence of hundreds of ixodid ticks in the head region of the dog. Etiology of the paralysis could not exactly determined, because the owner took away the dog in the same day. In addition, the dipteran larvae were found in the anal and perianal areas of the dog (Fig. 1). Collected ticks were stored in 70% ethanol, examined under a stereo zoom microscope and identified.

A few dipteran larvae washed in distilled water were transferred into 70% alcohol. Some of the remaining larvae were fed with chicken liver in a jar which it's tubulure covered with a cheesecloth to obtain pupae and adult flies. Then, some larvae were left to be transparent in 10% potassium hydroxide (KOH) for 48-72 h. They were rinsed in distilled water and taken into 70 and 99% alcohol, respectively. Later, they were examined under a stereo zoom microscope. Some of the larvae were dissected and mounted on the slides in Canada balsam. The larvae were identified as second and third instar larvae of *C. albiceps* according to their morphological characteristics such as cephalo-pharyngeal skeleton, anterior and posterior spiracles. It was determined that the second instar larvae (Fig. 2A, B) were white color and 5-10 mm in length (Fig. 2A), and the third instar larvae of *C. albiceps* were about 15 mm in length (Fig. 2C). Thorn-like fleshy projections which had setiferous apex were observed (Fig. 3B). These projections were found to be relatively longer in the dorsal and lateral parts in the third instars than the second instars. It was seen that anterior stigmas have 9-10 finger-shaped projections in the second instars, and this number is up to 11-12 in the third instars (Fig. 3A). No buttons on posterior stigma was observed (Fig. 2D). It was observed that the pupa were dark brown and found to be easily recognizable due to their projections (Fig. 3D). Adult *C. albiceps* was metallic green and 5-10 mm in length (Fig. 3C).

DISCUSSION

Tick paralysis is a neural syndrome caused by neurotoxins transmitted by ticks during blood-sucking on host [1]. The

Fig 1. Clinical appearance of dog. A- Tick paralysis, lying on a horizontal position, B- Myiasis larvae in the anal and perianal regions



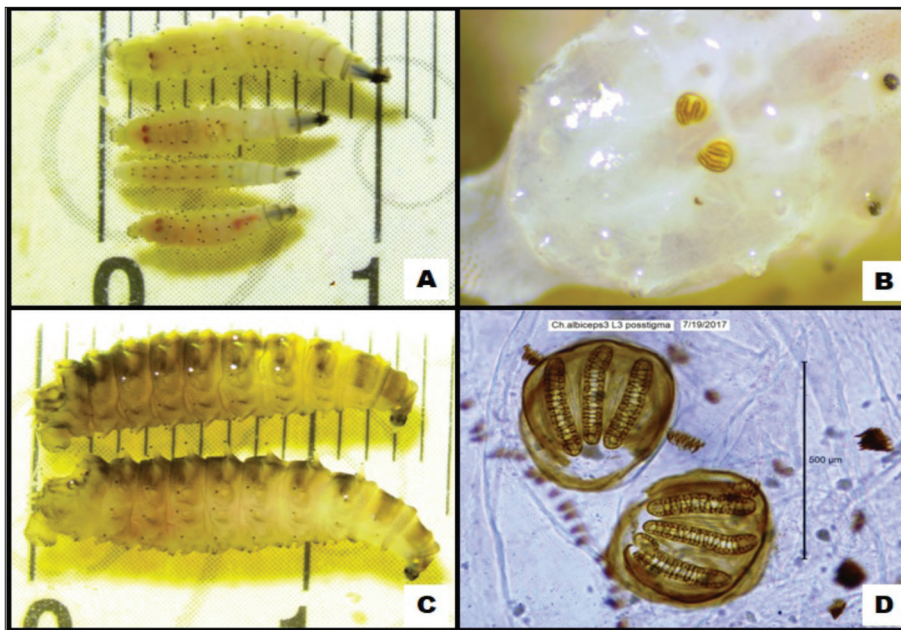


Fig 2. Second and third instars of *C. albiceps*
A- Second instars of *C. albiceps*, B- Posterior stigma of second instar, C- Third instars of *C. albiceps*, D- Posterior stigma of third instar




Fig 3. Morphological characteristics of third instar, adult and pupa of *C. albiceps*, A- Anterior stigma of third instar, B- Setiferous fleshy overhang on third instar, C- *C. albiceps*, adult, D- *C. albiceps*, pupa

cause of neurological changes in the dog have been suspected to be intensive tick infestation and possibly neurotoxins that inoculated by tick vectors during the blood sucking. Paralysis cases caused by the ixodid ticks are common in dogs and can cause deaths [2]. In Australia, it was reported that *Ixodes cornuatus* and *I. holocyclus* are the most common etiological agents of tick paralysis in dogs [12]. However, these species are not found in Turkey as well as in Europe. In the present study, it was thought that *Rh. sanguineus* was detected

as the possible causative agent of the tick paralysis in the dog. However, the etiology of paralysis has not been clearly revealed. Although, *Rh. sanguineus* has a wide distribution throughout the world, it has been reported that there are not enough studies on whether paralysis in dogs are caused by these ticks. Only one paralysis case originating from *Rh. sanguineus* in a dog was reported by Vilorio in Venezuela [13]. As a result of the literature search, tick paralysis case in dogs has not been encountered in Turkey.

Forty three tick species belonging to 10 genera, which were previously proven or suspected to cause tick paralysis, have been reported. *Rh. sanguineus* is one of them. There is little information about the toxicity of some of these species. The published studies on this issue is inadequate or some points have not been sufficiently clarified [14,15]. The number of studies related to tick paralysis have been found to be insufficient in Turkey. Eventhough no exact diagnosis was made in this study, tick paralysis was suspected due to the elimination of some of the diseases that could be confused with tick paralysis and the presence of a large number of ticks on the dog.

The anal myiasis phenomenon which we encounter in this study is thought to be the result of the lying in a horizontal position without movement for a long time due to paralysis. As a result of the literature search, many studies has been found related to several *Chrysomya* species. However, there are few studies on myiasis due to *C. albiceps* species. Forensic entomology studies related to *C. albiceps* were conducted in Turkey and various places in the world [16]. Kökdener and Polat [17] reported some Calliphorid species including *C. albiceps* in the north of the Turkey. In addition, they emphasized the importance of such regional faunistic studies in the future forensic studies. Açıkgöz et al. [16] focused on the predator effect of this species in the study conducted in Turkey. They claimed that the larvae of this species attacked to other larvae species on the wound and they have pointed out that there can be mistakes during the calculation of the time of death in the case of this larvae species involved. In a study conducted in Macedonia, *C. albiceps* was used for the calculation of the time between death and the discovery of the corpse [18]. Many cases were presented in the human and veterinary medicine fields related to *C. albiceps* in foreign countries. Sinha et al. [19] reported that *C. albiceps* and *C. megacephala* species were responsible for wound myiasis in the knee and ankle region of a patient. A case of myiasis originating from *C. albiceps* was reported in a deer in India [20]. Such a myiasis case caused by *C. albiceps* has not been encountered in the field of veterinary medicine up to date in Turkey. This is the first anal myiasis case report caused by *C. albiceps* in Turkey.

Dik et al. [4] encountered myiasis cases in the anal and perianal regions different kinds of animals and reported that *Eristalix tenax*, *Lucilia sericata* and *Wohlfartia magnifica* were responsible in these myiasis cases. Furthermore, they reported that the dominant species causing myiasis were *W. magnifica* and *L. sericata*. *C. albiceps*, a species different from the species that encountered in many cases, caused myiasis in this study. Schnur et al. [7] reported a myiasis case in which *L. sericata* and *C. albiceps* were seen together in a dog in Israel. In the present study, no other dipteran larvae except for *C. albiceps* were found.

In this case report, paralysis possibly originating from *Rh. sanguineus* ticks together with anal myiasis caused by *C.*

albiceps case is not a very common occurrence. Information on this topic was given and the obtained results were discussed in the light of related literatures.

REFERENCES

- Edlow JA, McGillicuddy DC:** Tick paralysis. *Infect Dis Clin North Am*, 22, 397-413, 2008. DOI: 10.1016/j.idc.2008.03.005
- Atwell RB, Campbell FE, Evans EA:** Prospective survey of tick paralysis in dogs. *Aust Vet J*, 79 (6): 412-418, 2001. DOI: 10.1111/j.1751-0813.2001.tb12986.x
- Zumt F:** Morphology, biology and pathogenesis of myiasis-producing flies in systematic order. In, Zumt F (Ed): Myiasis in man and animals in the Old World. 17-189, Butterworths, London, 1965.
- Dik B, Uslu U, Işık N:** Myiasis in animals and humanbeings in Turkey. *Kafkas Univ Vet Fak Derg*, 18 (1): 37-42, 2012. DOI: 10.9775/kvfd.2011.4654
- Saki CE:** Calliphoridae, sarcophagidae. In, Karaer Z, Dumanlı N (Eds): Arthropodoloji. 233-245, Medisan, Ankara, 2015.
- Verves YG:** Records of *Chrysomya albiceps* in the Ukraine. *Med Vet Entomol*, 18, 308-310, 2004. DOI: 10.1111/j.0269-283X.2004.00512.x
- Schnur HJ, Zivotofsky D, Wilamowski A:** Myiasis in domestic animals in Israel. *Vet Parasitol*, 161, 352-355, 2009. DOI: 10.1016/j.vetpar.2009.01.026
- Sevgili M, Şaki CE, Özkutlu Z:** Şanlıurfa yöresinde tespit edilen external myiasis sineklerinin yayılışı. *Türkiye Parazitoloj Derg*, 28 (3): 150-153, 2004.
- Coban E, Beyarslan A:** Identification of dipteran species of forensic entomology importance in summer season in Edirne. *Bitlis Eren Univ J Sci Technol*, 3, 18-21, 2013. DOI: 10.17678/beuscitech.47135
- Omar AH:** Cannibalism and predation behaviour of the blowfly, *Chrysomya albiceps* (Wiedemann) larvae. *J Egypt Soc Parasitol*, 25, 729-743, 1995.
- Madeira NG:** Would *Chrysomya albiceps* (Diptera: Calliphoridae) be a beneficial species? *Arq Bras Med Vet Zootec*, 53, 157-161, 2001. DOI: 10.1590/S0102-09352001000200004
- Jackson J, Beveridge I, Chilton NB, Andrews RH:** Distributions of the paralysis ticks *Ixodes cornuatus* and *Ixodes holocyclus* in southeastern Australia. *Aust Vet J*, 85, 420-424, 2007. DOI: 10.1111/j.1751-0813.2007.00183.x
- Walker JB, Keirans JE, Horak IG:** The Genus *Rhipicephalus* (Acari: Ixodidae). A Guide to the Brown Ticks of the World. Cambridge University Press, Cambridge, 1-655, 2000.
- Gothe R, Kunze K, Hoogstraal H:** The mechanisms of pathogenicity in the tick paralyses. *J Med Entomol*, 5, 357-369, 1979.
- Inci A, Yildirim A, Duzlu O, Doganay M, Aksoy S:** Tick-borne diseases in Turkey: A review based on one health perspective. *Plos Negl Trop Dis*, 10 (12): e0005021, 2016. DOI: 10.1371/journal.pntd.0005021
- Açıkgöz HN, Açıkgöz A, İşbaşı T:** İnsan cesetleri üzerinde bulunan *Chrysomya albiceps*'in (Fabricius) (Diptera: Calliphoridae) predatör davranışı. *Türkiye Parazitoloj Derg*, 35, 105-109, 2011. DOI: 10.5152/tpd.2011.26
- Kökdener M, Polat E:** Survey of forensically important Calliphoridae in Samsun. *J Bull Leg Med*, 21 (2): 67-71, 2016. DOI: 10.17986/blm.2016220390
- Klekovska D, Slavevska-Stamenkovic V, Smiljkov S, Hinic J, Rebok K, Janesca B:** Forensic use of *Chrysomya albiceps* (Wiedemann, 1819): the first cases indicating postmortem interval for human corpses in Republic of Macedonia. *J Entomol Zool Stud*, 5 (2): 320-323, 2017.
- Sinha SK, Mondal PC, Mahato S:** Person infected with maggots banded blowfly *Chrysomya albiceps* and Latrine fly *Chrysomya megacephala*. *Res Rev J Hosp Clin Pharm*, 2 (1): 13-14, 2016.
- Radhakrishnan S, Karapparambu Gopalan AK, Ravindran R, Rajagopal K, Sooryadas S, Promod K:** First record of *Chrysomya albiceps* Wiedemann, 1819 (Diptera: Calliphoridae) maggot from a sambar deer (*Rusa unicolor*) in Kerela, South India. *J Parasit Dis*, 36 (2): 280-282, 2012. DOI: 10.1007/s12639-012-0110-7