

# Effect of $\beta$ -Casomorphin-7 on Intestinal Mucosal Immunity in Aged Mice

Hong YIN <sup>1,a</sup> Ji-Jie LIU <sup>1</sup> Dan YANG <sup>1</sup> Hui-Qing XU <sup>1</sup>

<sup>1</sup> Department of Nutrition, School of Tourism cooking & Food science and engineering, Yangzhou University, Yangzhou 225000, CHINA

<sup>a</sup> ORCID: 0000-0002-2973-3801

Article Code: KVFD-2018-21628 Received: 24.12.2018 Accepted: 09.04.2019 Published Online: 10.04.2019

## How to Cite This Article

Yin H, Liu JJ, Yang D, Xu HQ: Effect of  $\beta$ -casomorphin-7 on intestinal mucosal immunity in aged mice. *Kafkas Univ Vet Fak Derg*, 25 (5): 689-696, 2019. DOI: 10.9775/kvfd.2018.21628

## Abstract

The immune deficiency caused by aging deserves attention, especially the weakening of intestinal mucosal immunity. The effect of  $\beta$ -casomorphin-7 on intestinal mucosal immunity was investigated in aged mice. Mice were treated without or with different doses of  $\beta$ -casomorphin-7 for 30 days. Histopathological studies showed the tissue protective role of  $\beta$ -casomorphin-7 in aged mice. Low-dose group could significantly increase the level of IL-2 and TNF- $\alpha$  in intestinal mucosa. A significant increase in the level of SIgA was observed in medium- and high-dose groups. The low and medium dose groups could significantly increase the activity of SOD in small intestine mucosa. All dose groups significantly reduced the levels of MDA. The results suggest that  $\beta$ -casomorphin-7 could improve intestinal mucosal immune decline which is induced by aging. The mechanisms for the regulating effects were likely through balancing the cytokine level and controlling the oxidative stress.

**Keywords:**  $\beta$ -casomorphin-7, Aging intestinal mucosal immune cytokine, Oxidative stress

## Yaşlı Farelerde Bağırsak Mukozası Bağışıklığına $\beta$ -Kazomorfın-7'nin Etkisi

### Öz

Yaşlanmaya bağlı bağışıklık yetersizliği özellikle bağırsak mukozası bağışıklığı olmak üzere dikkat edilmesi gereken bir husustur. Bu çalışmada, yaşlı farelerin bağırsak mukozası bağışıklığına  $\beta$ -kazomorfın-7'nin etkisi araştırılmıştır. Farelere 30 gün süresince farklı dozlarda  $\beta$ -kazomorfın-7 içeren veya içermeyen uygulamalar yapıldı. Histopatolojik incelemelerde  $\beta$ -kazomorfın-7'nin yaşlı farelerde doku koruyucu etkisinin olduğu gözlemlendi. Düşük doz grubunda bağırsak mukozasında IL-2 ve TNF- $\alpha$  seviyeleri anlamlı derecede arttı. Orta ve yüksek doz gruplarında SIgA seviyesinde anlamlı bir artma gözlemlendi. Düşük ve orta doz gruplarında ince bağırsak mukozasında SOD aktivitesi anlamlı derecede arttı. Tüm doz gruplarında, MDA aktivitesi anlamlı derecede azaldı. Elde edilen sonuçlar,  $\beta$ -kazomorfın-7'nin yaşlılığa bağlı olarak gelişen bağırsak mukozası bağışıklığında meydana gelen düşüşü iyileştirebileceğini gösterdi. Bu düzenleyici etkiyi muhtemelen sitokin seviyesi ve oksidatif stresi kontrol altında tutmak suretiyle oluşturmaktadır.

**Anahtar sözcükler:**  $\beta$ -Kazomorfın-7, Yaşlanan bağırsakta mukozal bağışıklık sitokin, Oksidatif stres

## INTRODUCTION

Our population is aging, but longevity is not always associated with good health. One of the most important effects of the aging process is the significant decline in the efficacy of the adaptive and congenital immune system, especially in the intestinal immune system. Compared with the systemic immune system, the age-related changes in the intestinal mucosal immune system are earlier than those of the systemic immune system <sup>[1]</sup>. The gut plays a vital role in absorbing nutrients and drugs, preventing

pathogen invasion and maintaining the health of the body. In many elderly people, gastrointestinal dysfunction, mucosal defense deficiency, and oxidative stress increase, influence the ability to absorb nutrients and maintain the balance of normal microbial flora, which leads to lower immunity and an increase in the incidence of inflammation and autoimmunity in the elderly. Experiments show that the gut may become an important target for promoting longevity intervention <sup>[2]</sup>.

The multifunctional properties of biologically active



### İletişim (Correspondence)



+86 051487978096



yinh@yzu.edu.cn

peptides from milk are increasingly acknowledged [3].  $\beta$ -casomorphins belong to a family of opioid peptides derived from milk protein.  $\beta$ -Casomorphin-7 (Tyr-Pro-Phe-Pro-Gly-Pro-Ile,  $\beta$ -CM-7) was first isolated from an enzymatic digest of bovine  $\beta$ -casein [4]. Current researches show that  $\beta$ -CM-7 can regulate glucose [5], antioxidative [6,7], immunological [8], hormonal and neurological responses.

In addition,  $\beta$ -CM-7 is capable of modulating gene expression of the regulatory peptides from G and D cells. Data from in situ hybridization studies indicate that  $\beta$ -CM-7 affects gastrin gene expression indirectly by means of the paracrine action of somatostatin, and depends on its intrinsic molecular function [9]. Thus  $\beta$ -CM-7 is most likely to be a signal molecule in gastrointestinal tract. However, there is no report about the effect of  $\beta$ -CM-7 on intestinal mucosal immunity in aged mice.

Presented here, the aims of this study were to investigate whether management with  $\beta$ -CM-7 has any effects of regulating intestinal mucosal immunity in aged mice and its possible mechanism.

## MATERIAL and METHODS

### Chemicals and Reagents

$\beta$ -CM-7 was purchased from Nanjing Peptide Biotech Co., Ltd. (Nanjing, China). The assay kits for analyses of superoxide dismutase (SOD), Catalase (CAT), malondialdehyde (MDA), Secretory immunoglobulin A (SIgA), Tumor Necrosis Factor- $\alpha$  (TNF- $\alpha$ ) and Interleukin-2 (IL-2) were purchased from Jiancheng Biologic Project Company (Nanjing, China). All the other chemicals and reagents were of analytical grade.

### Animals

Forty elderly male KM mice (11 months old) and ten young KM mice (2 months old) were purchased from Nanjing Qinglongshan Animal Center (Nanjing, China). They were housed under controlled environmental conditions of temperature ( $22\pm 2^\circ\text{C}$ ) with a 12 h light/12 h dark cycle, and maintained on (unless otherwise stated) standard food pellets and tap water. All animal care and procedures were performed in accordance with Jiangsu Province and institutional policies for animal health and well-being. All mice samples collection and field study were approved by guide for care and use of laboratory animals of the protocol for animal study of Animal Management Committee of Jiangsu Province and Yangzhou University. The animals were acclimatized for 1 week before the study.

### Experimental Design

The young mice ( $n=10$ ) were as the control group (group I) while the aged mice ( $n=40$ ) were randomly divided into four groups (group II to V):

Group I (Con,  $n=10$ ): Young control mice with free access to normal diet and intragastric administration of Stroke-

physiological saline solution for 30 days.

Group II (A con,  $n=10$ ): Aged control mice with free access to a normal diet and intragastric administration of stroke-physiological saline solution for 30 days.

Group III (L,  $n=10$ ):  $\beta$ -CM-7 treated mice; each animal was put on a normal diet and treated with the low dose of  $\beta$ -CM-7 ( $2\times 10^{-7}$  mol·d $^{-1}$ , intragastric administration) for 30 days.

Group IV (M,  $n=10$ ):  $\beta$ -CM-7 treated mice, each animal was put on a normal diet and treated with the medium dose of  $\beta$ -CM-7 ( $1\times 10^{-6}$  mol·d $^{-1}$ , intragastric administration) for 30 days.

Group V (H,  $n=10$ ):  $\beta$ -CM-7 treated mice, each animal was put on a normal diet and treated with the high dose of  $\beta$ -CM-7 ( $5\times 10^{-6}$  mol·d $^{-1}$ , intragastric administration) for 30 days.

### Collection of Organ Tissues

All mice were sacrificed and necropsy examination was carried out immediately. Intestinal mucosa was exposed and washed with phosphate buffer saline. Small intestine samples were taken and fixed in 4% neutral-buffered Polyoxymethylene and other intestinal mucosa samples were taken instantly into liquid Nitrogen and stored at  $-70^\circ\text{C}$ .

### Analytical Methods

**Histopathological Observation:** Small intestine fixed in 4% neutral-buffered Polyoxymethylene were embedded in paraffin, sliced at a thickness of 5  $\mu\text{m}$  and stained with hematoxylin and eosin (H&E). The histological changes were observed by light microscopic examination at a magnification of 20  $\times$ .

**Assays of SOD, CAT, MDA, SIgA, TNF- $\alpha$  and IL-2 in Intestinal Mucosa Samples:** The 10% homogenates of mucous membrane of small intestine were prepared in the phosphate buffer (0.1 M, pH 7.4) containing 1 mmol ethylenediamine-tetra acetic acid (EDTA), 0.25 mM sucrose, 10 mM potassium chloride (KCl) and 1 mM phenylmethyl sulfonyl fluoride (PMSF).

Lipid peroxidation was determined by quantifying MDA concentrations, which was spectrophotometrically measured by the absorbance of a red-colored product with thiobarbituric acid.

Briefly, the determination of SOD activity was based on the production of  $\text{O}_2^{\cdot-}$  anions by the xanthine/xanthine oxidase system. The amount of SOD that inhibits 50% the rate of reduction under the specified conditions was regarded as one enzyme unit.

Catalase activities were determined as described by Sozmen et al. [10] in which the degradation of  $\text{H}_2\text{O}_2$  is recorded spectrophotometrically at 240 nm. One unit of catalase was defined as the amount of enzyme which

decomposes 1 mol  $\text{H}_2\text{O}_2/\text{min}$  under specific conditions.

SIgA, TNF- $\alpha$  and IL-2 were determined using a commercial ELISA kit, according to the instructions.

### Statistical Analysis

Data were analyzed statistically using SPSS 16.0 for Windows and expressed as the mean  $\pm$  SD of 10 mice per group. Experimental results were compared by one-way ANOVA with least significant difference (LSD) post-hoc tests used to compare individual means as appropriate.  $P < 0.05$  or  $P < 0.01$  were considered statistically significant.

## RESULTS

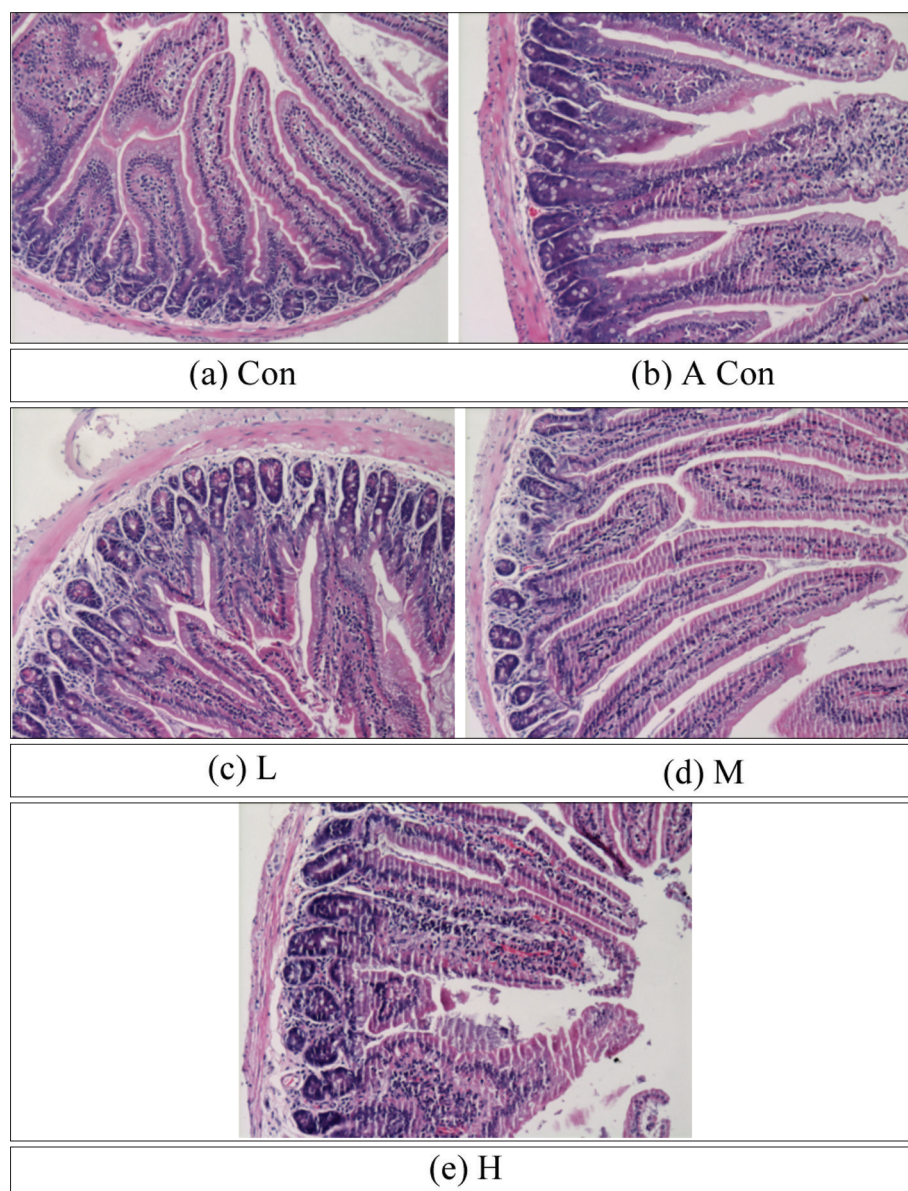
### Effect of $\beta$ -CM-7 on Histological Section in Intestinal Mucosa of Aged Mice

Fig. 1 was the result of HE staining in the mouse small

intestine tissue section. As shown in Fig. 1a, the small intestinal villi in the young control group were even slender, elongated and tidy, and the tissue structure of the small intestine in the aged control group had different degrees of damage, showing intestinal villus loss and defect, increased width, short length, sparse arrangement, reduced height and density of mucous membrane, unarranged epithelial cells and interstitial atrophy.

In the  $\beta$ -CM-7 intervention group, the gap of the small intestinal villi was significantly reduced, the swelling was reduced and the arrangement was neatly restored. In the middle dose group, the villi of the small intestine were fine and neat, and the integrity was the best.

According to Table 1, the length of intestinal mucous villus in the aged control group was significantly lower than that in the control group ( $P < 0.05$ ), and the V/C value was significantly lower than that in the control group ( $P < 0.01$ ).

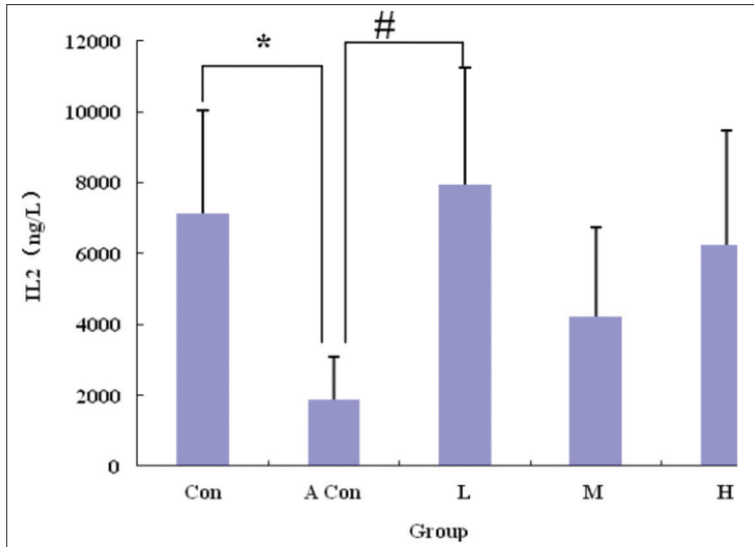


**Fig 1.** Histological section of small intestinal villi in mice (20 $\times$ )

**Table 1.** Effect of  $\beta$ -CM-7 on intestinal villus length, crypt depth and V/C value in mice (n=10)

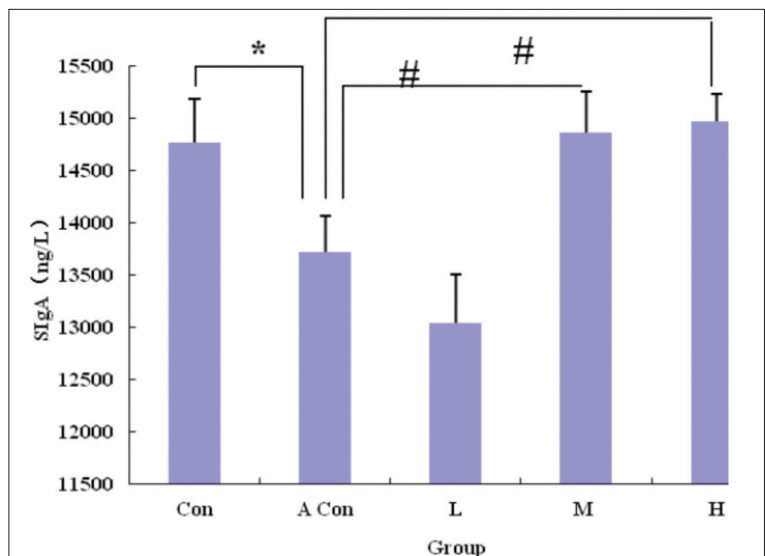
Group	Villus Length/ $\mu$ m	Crypt Depth/ $\mu$ m	Villus Length/Crypt Depth (V/C)
Con	280.49 $\pm$ 40.34	47.30 $\pm$ 10.80	6.25 $\pm$ 1.78
A Con	208.92 $\pm$ 31.83*	55.40 $\pm$ 16.80	3.96 $\pm$ 0.94**
L	289.50 $\pm$ 40.12 <sup>#</sup>	54.85 $\pm$ 9.94	5.43 $\pm$ 1.26 <sup>#</sup>
M	275.00 $\pm$ 75.11 <sup>#</sup>	53.03 $\pm$ 16.44	5.41 $\pm$ 1.34 <sup>#</sup>
H	264.62 $\pm$ 98.68	55.40 $\pm$ 11.81	4.88 $\pm$ 1.81

Compared with the Con group, P<0.05 was expressed by \*, compared with the aged control group, P<0.05 was expressed with "#"



**Fig 2.** Effect of  $\beta$ -Casomorphin -7 on The level of IL-2 in intestinal mucosa of mice (n=10). Compared with the Con group, P<0.05 was expressed by \*, compared with the aged control group, P<0.05 was expressed with "#"

**Fig 3.** Effect of  $\beta$ -casomorphin -7 on the level of SIgA in intestinal mucosa of mice (n=10). Compared with the Con group, P<0.05 was expressed by \*, compared with the aged control group, P<0.05 was expressed with "#"

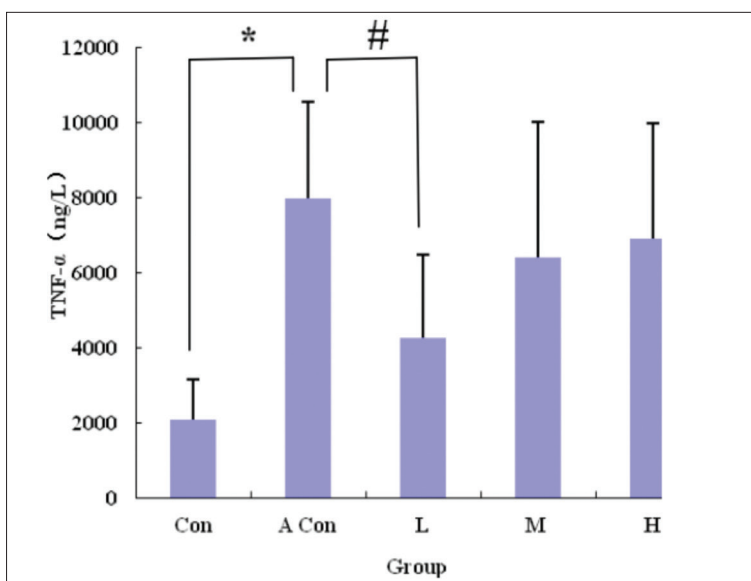


Compared with the aged control group, the dose group could increase the length of intestinal mucous villus and increase the value of V/C, and had a negative correlation with the dose. The low and middle dose groups could significantly increase the length and V/C value of intestinal mucous villus in mice, and there were statistical differences (P<0.05). However, there was no significant difference in the depth of crypt between each group, and there was no statistical difference (P>0.05).

**Effect of  $\beta$ -CM-7 on IL-2, SIgA and TNF-a in Intestinal Mucosa of Aged Mice**

According to Fig. 2, the level of IL-2 in intestinal mucosa of aged control group was significantly lower than that of young control group (P<0.05). Compared with the aged control group, the dose group could increase the level of IL-2 in the intestinal mucosa of mice, only the low dose group could significantly increase the level of IL-2





**Fig 4.** Effect of  $\beta$ -casomorphin -7 on the level of TNF- $\alpha$  in intestinal mucosa of mice (n=10). Compared with the Con group,  $P < 0.05$  was expressed by \*, compared with the aged control group,  $P < 0.05$  was expressed with "#"

Group	SOD (U/mgprot)	MDA (nmol/mgprot)	CAT (U/mgprot)
Con	295.84 $\pm$ 74.44	0.19 $\pm$ 0.03	77.72 $\pm$ 8.6
A Con	186.26 $\pm$ 15.81**	0.40 $\pm$ 0.15**	45.61 $\pm$ 7.78**
L	322.97 $\pm$ 49.93##	0.22 $\pm$ 0.14#	60.35 $\pm$ 17.71##
M	267.28 $\pm$ 27.64##	0.24 $\pm$ 0.22#	53.47 $\pm$ 7.2
H	185.71 $\pm$ 32.84	0.19 $\pm$ 0.18##	47.68 $\pm$ 14.18

*Compared with the Con group,  $P < 0.05$  was expressed by \*, compared with the aged control group,  $P < 0.05$  was expressed with "#"*

in the small intestinal mucosa, and there was a statistical difference ( $P < 0.05$ ). In addition, the concentration of IL-2 in the intestinal mucosa of the high dose group was higher than that in the middle dose group, but there was no significant difference between the middle and high dose groups ( $P > 0.05$ ) compared with the aged control group. It is suggested that  $\beta$ -CM-7 can enhance the intestinal mucosal immunity of aged mice by increasing the IL-2 content of intestinal mucosa in mice.

The SIgA content of intestinal mucosa in aged control group was significantly lower than that in young control group ( $P < 0.05$ ). Compared with the aged control group, the middle dose and high dose group could significantly increase the SIgA content ( $P < 0.01$ ). The SIgA content in the low dose group decreased slightly, but the difference was not statistically significant ( $P > 0.05$ ) (Fig. 3). It is suggested that  $\beta$ -CM-7 can improve the secretion of SIgA in the intestinal mucosa of aged mice and protect the intestinal immune barrier.

The level of TNF- $\alpha$  in intestinal mucosa of aged control group was significantly higher than that of young control group ( $P < 0.01$ ) (Fig. 4). Compared with the aged control group, the dose group could reduce the content of TNF- $\alpha$  in the intestinal mucosa of mice in different degrees, and the low dose group could significantly reduce the content

of TNF- $\alpha$  in the intestinal mucosa of mice, and there was a statistical difference ( $P < 0.01$ ). The middle dose group was lower than the high dose group, but compared with the aged control group, the difference between the middle and high dose groups was different. It was not significant ( $P > 0.05$ ). It is suggested that  $\beta$ -CM-7 can play a role in intestinal immune barrier by lowering the level of proinflammatory cytokine TNF- $\alpha$ .

#### **Effect of $\beta$ -CM-7 on SOD, MDA and CAT in Intestinal Mucosa of Aged Mice**

According to Table 2, the activity of SOD in the intestinal mucosa of the aged control group was significantly lower than that in the young control group ( $P < 0.01$ ). Compared with the aged control group, the activity of SOD in the low dose group and the middle dose group increased significantly ( $P < 0.01$ ), and the low dose group increased more than the middle dose group, and there was a significant difference between the two groups ( $P < 0.01$ ) and the high dose group. The activity of SOD in the group was slightly lower than that in the model control group.

The content of MDA in the intestinal mucosa of the aged control group was significantly higher than that in the young control group ( $P < 0.01$ ). Compared with the aged control group, the content of MDA in the low dose group

and the middle dose group had a decreasing trend, and there was a difference ( $P < 0.05$ ), and the content of MDA in the high dose group was significantly lower than that of the aged control group ( $P < 0.01$ ).

The activity of CAT in the intestinal mucosa of the aged control group was significantly lower than that in the young control group ( $P < 0.01$ ). Compared with the model group, the activity of CAT in the low dose group increased significantly ( $P < 0.01$ ), and the activity of CAT in the middle and high dose groups was increased, but the difference was not significant ( $P > 0.05$ ).

## DISCUSSION

The intestinal tract not only has the function of digestion and absorption, but also provides a natural defense barrier for the body. Adjacent intestinal epithelial cells are closely linked through intercellular junctional complexes, isolating the milieu interne of the tunicae propria and the environment outside the intestine. The intestinal barrier is divided into four parts: epithelial barrier, immune barrier, biological barrier and chemical barrier. The epithelial barrier and immune barrier are especially important. Intestinal epithelial barrier is the first line of defense against pathogens [11]. The normal structure and function of the small intestine are the basic guarantee of the nutrients being fully digested and absorbed and immune function, especially the length of intestinal villi, the depth of the recess and the thickness of the mucous membrane, which are the important indexes to measure the digestive and absorption function of the small intestine [12].

The results of this study showed that age growth could cause damage to the tissue structure of the small intestine, shorten the length of intestinal villi and decrease the ratio of the length of the villi/recess depth, which is in accordance with the results of Liang et al. [13] study.  $\beta$ -CM-7 can significantly increase the length of intestinal villi, increase the ratio of villi length/recess depth, alleviate the injury of intestinal mucosal tissue and protect the immune function of small intestinal mucosa.

Several studies have shown that aging can be accompanied by an increase in pro-inflammatory cytokines such as IL-6, IL-1 and TNF- $\alpha$ , which increase the chronic inflammation of the elderly [14,15]. It is believed that the increase of pro-inflammatory factor TNF- $\alpha$  causes the remodeling of actin, causing intestinal epithelial cells and close connections to be damaged, thereby damaging the intestinal mucosal barrier function and increasing the permeability of intestinal mucosa [16]. We observed a significant increase in TNF- $\alpha$  in the intestinal mucosa of aged mice, which is consistent with the results of the Miró et al. [17] study. After feeding different doses of  $\beta$ -CM-7, the content of TNF- $\alpha$  in intestinal mucosa of mice decreased, and the low dose had the most significant effect on TNF- $\alpha$  content in intestinal mucosa of mice. It indicated that  $\beta$ -CM-7 could reduce the

damage of proinflammatory factors on intestinal mucosa and alleviate the effect of aging on intestinal mucosal immunity.

SIgA is the most immunologically active antibody on the surface of the intestinal mucosa. It is one of the main factors of intestinal mucosal immunity and an important indicator of the immune function of intestinal mucosa. As the first line of defense against potentially invasive pathogenic microbes and participating in host microbial interactions, SIgA can prevent bacteria from adhesion and proliferation on the surface of epithelial cells, prevent the uptake of bacterial toxins and other harmful substances from the mucous membrane, have synergistic bactericidal action with complement and lysozyme, and extensive immune protection [18]. This study showed that the expression of SIgA in the intestinal mucosa of the aged model mice was significantly lower than that in the young group, but after feeding  $\beta$ -CM-7, the content of SIgA in the middle and high dose groups could be greatly increased, and the SIgA content in the low dose group decreased slightly, but the difference was not statistically significant ( $P > 0.05$ ). The results showed that  $\beta$ -CM-7 could improve the secretion of SIgA in intestinal mucosa of aged mice and protect the intestinal immune barrier.

In 1980s, Watabe et al. [19] studies confirmed that IgA mediated response depends on the help of T lymphocytes, and the participation of cytokines is also required. IL-2 is one of the T lymphocyte growth factors. It is mainly produced by activated CD4+T and CD8+T cells. It can activate immune effect cells and produce synergistic effect factors, which can effectively remove tumor cells and virus bacteria infected cells. The results of this experiment showed that the expression of IL-2 in the intestinal mucosa of the aged model mice was significantly lower than that of the young group, but the dose group was significantly higher than the old control group. This was in accordance with the results of Zhao et al. [20] study. The study of Zhao et al. [20] showed that casein peptide could increase the serum IL-2 content in the aging model mice and have anti aging effect. Zhao et al. [20] study showed that the effect was positively correlated with the dose. However, the results of this experiment showed that the increase in the low dose group was the most obvious and did not have a positive correlation with the dose. The reasons for the inconsistency need to be further studied and analyzed.

Malondialdehyde is an oxygen free radical attacking the unsaturated fatty acid in cell membrane and triggering lipid peroxidation, which is a degrading substance [21,22]. The determination of MDA content can reflect the degree of oxidative damage in the body tissue. The increase of free radical content and the increase of MDA content indicate that the degree of tissue injury is aggravated, which is an important index of aging. According to Table 2, the content of MDA in the intestinal mucosa of aged mice was significantly higher than that of young mice

( $P < 0.01$ ), indicating that the intestinal mucosa of old mice was in the state of oxidative stress. The content of MDA in low dose group and middle dose group had a decreasing trend ( $P < 0.05$ ), and the content of MDA in high dose group was significantly lower than that of model control group ( $P < 0.01$ ), which indicated that  $\beta$ -CM-7 could inhibit the damage of MDA on body tissue, and could reduce the level of oxidative stress in the elderly.

When the body constantly synthesizes free radicals, the body produces some enzymes that scavenge free radicals. SOD is a specific scavenger of superoxide anion and the first line of defense against oxidation. The detection of the content of SOD can indirectly reflect the ability of scavenging oxygen free radicals<sup>[23]</sup>. As presented in *Table 2*, the SOD activity in the small intestinal mucosa of the aged mice was significantly lower than the SOD activity in the small intestinal mucosa of the young mice ( $P < 0.01$ ), which showed that the antioxidative ability of the aged mice was weakened. The low dose group and middle dose group could significantly increase the activity of SOD ( $P < 0.01$ ), indicating that  $\beta$ -CM-7 can up regulate the activity of SOD and enhance the antioxidant stress of small intestinal mucosa, which is consistent with the results of Yin et al.<sup>[6]</sup>.

Catalase can promote the reaction of hydrogen peroxide in vivo, alleviate the damage of hydrogen peroxide on the body, and can represent the antioxidant capacity of the body<sup>[24]</sup>. According to *Table 2*, the activity of CAT in the intestinal mucosa of the aged mice was significantly lower than that of the young mice ( $P < 0.01$ ), and the low dose group could significantly increase the CAT activity of the small intestinal mucosa ( $P < 0.01$ ). The medium and high dose groups could improve the CAT activity of the small intestinal mucosa of the aged mice, but the difference was not significant ( $P > 0.05$ ). It indicated that  $\beta$ -CM-7 could improve the activity of CAT and enhances the ability of antioxidative stress in intestinal mucosa, which is consistent with the result of Yin et al.<sup>[6]</sup>.

To sum up, aging can cause the increase of the concentration of inflammatory cytokines in intestinal mucosa, the damage of intestinal tissue structure and the decrease of immune function of small intestinal mucosa.  $\beta$ -CM-7 can significantly increase the content of IL-2 and SIgA, reduce the content of pro-inflammatory factor TNF- $\alpha$  and significantly improve the activity of antioxidant kinase, such as SOD and CAT in small intestinal mucosa, and then reduce the intestinal tissue damage caused by aging, maintain the normal form of intestinal tract and enhance the immunity of small intestinal mucosa. These results suggest that  $\beta$ -CM-7 has a certain protective effect on the intestinal mucosa of old animals, but the mechanism of  $\beta$ -CM-7 reconstruction of intestinal mucosal immune homeostasis and postponing inflammatory aging need further study.

In conclusion,  $\beta$ -CM-7 can significantly increase the content of IL-2 and SIgA, reduce the content of pro-inflammatory

factor TNF- $\alpha$  and significantly improve the activity of antioxidant kinase in small intestinal mucosa. These results suggest that  $\beta$ -CM-7 has a certain protective effect on the intestinal mucosa of old animals, but the mechanism of  $\beta$ -CM-7 reconstruction of intestinal mucosal immune homeostasis and postponing inflammatory aging need further study.

## FUNDING

This project was sponsored by grants from The Natural Science Foundation of the Jiangsu Higher Education Institutions of China (No: 16KJB330011 and 17KJB190001), Science and technology innovation fostering fund of Yangzhou University (No: 2016CXJ107), and Post-graduates scientific research and innovation projects (No: XKYCX18-133).

## REFERENCES

- García-Peña C, Álvarez-Cisneros T, Quiroz-Baez R, Friedland RP:** Microbiota and aging. A review and commentary. *Arch Med Res*, 48 (8): 681-689, 2017. DOI: 10.1016/j.arcmed.2017.11.005
- Nagura H:** Mucosal immune system in health and disease. *Pathol Int*, 42 (6): 387-400, 1992. DOI: 10.1111/j.1440-1827.1992.tb03243.x
- Darewicz M, Iwaniak A, Minkiewicz P:** Biologically active peptides derived from milk proteins. *Pol J Food Nutr Sci*, 58 (6): 289-294, 2014.
- Brantl V, Teschemacher H, Henschen A, Lottspeich F:** Novel opioid peptides derived from casein ( $\beta$ -casomorphins). I. Isolation from bovine casein peptone. *Hoppe Seylers Z Physiol Chem*, 360 (2): 1211-1216, 1979.
- Yin H, Miao JF, Zhang YS:** Protective effect of  $\beta$ -casomorphin-7 on type 1 diabetes rats induced with streptozotocin. *Peptides*, 31, 1725-1729, 2010. DOI: 10.1016/j.peptides.2010.05.016
- Yin H, Miao J, Ma C, Sun GJ, Zhang YS:**  $\beta$ -Casomorphin-7 cause decreasing in oxidative stress and inhibiting NF- $\kappa$ B-iNOS-NO signal pathway in pancreas of diabetes rats. *J Food Sci*, 77 (2): C278-C282, 2012. DOI: 10.1111/j.1750-3841.2011.02577.x
- Zhang W, Miao J, Wang S, Zhang Y:** The protective effects of  $\beta$ -casomorphin-7 against glucose-induced renal oxidative stress *in vivo* and *in vitro*. *Plos One*, 8 (5): e63472, 2013. DOI: 10.1371/journal.pone.0063472
- Kaminski S, Cieslinska A, Kostyra E:** Polymorphism of bovine beta-casein and its potential effect on human health. *J Appl Genet*, 48 (3): 189-198, 2007. DOI: 10.1007/BF03195213
- Zong YF, Chen WH, Zhang YS, Zou SX:** Effects of intra-gastric beta-casomorphin-7 on somatostatin and gastrin gene expression in rat gastric mucosa. *World J Gastroenterol*, 13 (14): 2094-2099, 2007. DOI: 10.3748/wjg.v13.i14.2094
- Sozmen B, Delen Y, Girgin FK, Sozmen EY:** Catalase and paraoxonase in hypertensive type 2 diabetes mellitus: Correlation with glycemic control. *Clin Biochem*, 32 (6): 423-427, 1999. DOI: 10.1016/S0009-9120(99)00034-X
- Knodler LA, Crowley SM, Sham HP, Yang H, Wrande M, Ma C, Ernst RK, Steele-Mortimer O, Celli J, Vallance BA:** Non-canonical inflammasome activation of caspase-4/caspase-11 mediates epithelial defenses against enteric bacterial pathogens. *Cell Host Microbe*, 16 (2): 249-256, 2014. DOI: 10.1016/j.chom.2014.07.002
- De Barros Alencar AC, Neves RH, de Oliveira AV, Machado-Silva JR:** Changes in the small intestine of *Schistosoma mansoni*-infected mice fed a high-fat diet. *Parasitol*, 139 (6): 716-725, 2012. DOI: 10.1017/S0031182011002307
- Liang Z, Xie Y, Dominguez JA, Breed ER, Yoseph BP, Burd EM, Farris AB, Davidson NO, Coopersmith CM:** Intestine-specific deletion of microsomal triglyceride transfer protein increases mortality in aged

mice. *Plos One*, 9 (7): e101828, 2014. DOI: 10.1371/journal.pone.0101828

**14. Thomas S, Kenneth D, Livak J:** Analyzing real-time PCR data by comparative CT method. *Nat Protoc*, 3 (6): 1101-1108, 2008.

**15. Ershler WB, Keller ET:** Age-associated increased interleukin-6 gene expression, late-life diseases, and frailty. *Annu Rev Med*, 51 (1): 245-270, 2000. DOI: 10.1146/annurev.med.51.1.245

**16. Ponnappan S, Ponnappan U:** Aging and immune function: Molecular mechanisms to interventions. *Antioxid Redox Signal*, 14 (8): 1551-1585, 2011. DOI: 10.1089/ars.2010.3228

**17. Miró L, Garciajust A, Amat C, Polo J, Moreto M, Perez-Bosque A:** Dietary animal plasma proteins improve the intestinal immune response in senescent mice. *Nutrients*, 9 (12): 1346, 2017. DOI: 10.3390/nu9121346

**18. Man AL, Gicheva N, Nicoletti C:** The impact of ageing on the intestinal epithelial barrier and immune system. *Cell Immunol*, 289 (1-2): 112-118, 2014. DOI: 10.1016/j.cellimm.2014.04.001

**19. Watabe T, Nagaishi T, Hosoya A, Jose N, Tokai A, Kojima Y, Adachi T, Watanabe T:** The lack of secreted IgA spontaneously induces the

mucosal inflammation specifically in the ileum. *Gastroenterology*, 152 (5): S1004, 2017.

**20. Zhao L, Ma LY:** Animal experiment of casein peptide in delaying senility. *Food Ind*, 5, 11-12, 2010.

**21. Na S, Kim OS, Ryoo S, Kweon TD, Choi YS, Shim HS, Oh YJ:** Cervical ganglion block attenuates the progression of pulmonary hypertension via nitric oxide and arginase pathways. *Hypertension*, 63 (2): 309-315, 2014. DOI: 10.1161/HYPERTENSIONAHA.113.01979

**22. Bozukluhan K, Atakisi E, Atakisi O:** Nitric oxide levels, total antioxidant and oxidant capacity in cattle with foot-and-mouth-disease. *Kafkas Univ Vet Fak Derg*, 19 (1): 179-181, 2013. DOI: 10.9775/kvfd.2012.7244

**23. Kajita M, Hikosaka K, Iitsuka M, Kanayama A, Toshima N, Miyamoto Y:** Platinum nanoparticle is a useful scavenger of superoxide anion and hydrogen peroxide. *Free Radic Res*, 41 (6): 615-626, 2007. DOI: 10.1080/10715760601169679

**24. Cho SC, Chao YY, Hong CY, Kao CH:** The role of hydrogen peroxide in cadmium-inhibited root growth of rice seedlings. *Plant Growth Regul*, 66 (1): 27-35, 2012. DOI: 10.1007/s10725-011-9625-7