

Protective Effect of Ozone Against Gentamicin-Induced Nephrotoxicity and Neutrophil Gelatinase-Associated Lipocalin (NGAL) Levels: An Experimental Study

Sefer ÜSTEBAY ^{1,a} Döndü Ülker ÜSTEBAY ^{1,b} Ömür ÖZTÜRK ^{2,c} Ömer ERTEKİN ^{1,d} Yasemen ADALI ^{3,e}

¹ Kafkas University, Faculty of Medicine, Department of Pediatrics, TR-36300 Kars - TURKEY

² Çanakkale Onsekiz Mart University, Faculty of Medicine, Department of Anesthesiology and Reanimation, TR-17000 Çanakkale - TURKEY

³ Çanakkale Onsekiz Mart University, Faculty of Medicine, Department of Pathology, TR-17000 Çanakkale - TURKEY

^a ORCID: 0000-0003-1507-5921; ^b ORCID: 0000-0003-3270-8305; ^c ORCID: 0000-0003-2270-2778; ^d ORCID: 0000-0002-7846-7634

^e ORCID:0000-0002-8004-7364

Article ID: KVFD-2018-21097 Received: 02.10.2018 Accepted: 10.02.2019 Published Online: 15.02.2019

How to Cite This Article

Üstebay S, Üstebay DÜ, Öztürk Ö, Ertekin Ö, Adalı Y: Protective effect of ozone against gentamicin-induced nephrotoxicity and neutrophil gelatinase-associated lipocalin (NGAL) levels: An experimental study. *Kafkas Univ Vet Fak Derg*, 25 (3): 397-404, 2019. DOI: 10.9775/kvfd.2018.21097

Abstract

Our aim was to investigate the protective role of ozone treatment against gentamicin-induced nephrotoxicity in an experimental rat model. In this study, a total of 30 rats were allocated in 5 groups (n=6 in each group). The control group (Group 1) received isotonic saline only, while Groups 2 and 3 received gentamicin at doses of 15 mg/kg/day and 50 mg/kg/day, respectively. In Group 4, intraperitoneal ozone treatment (1 mg/kg, 5% O₃-95% O₂) was performed after administration of gentamicin at a dose of 15 mg/kg/day. Group 5 underwent ozone treatment intraperitoneally following the application of gentamicin (50 mg/kg/day). Nephrotoxicity was formed by administration of glycerol. Serum levels of urea, creatinine, neutrophil-gelatinase-associated lipocalin (NGAL), lactate dehydrogenase (LDH), total antioxidant capacity (TAC) and protein carbonyl were measured, and kidneys were histopathologically examined after the sacrifice of animals on the 5th day. Group 4 displayed more favorable outcomes regarding biochemical markers of oxidative stress such as NGAL, LDH, creatinine, urea, TAC and protein carbonyl. Similarly, histopathological alterations indicating gentamicin-induced nephrotoxicity such as hemorrhage, the presence of protein casts and epithelial injury in renal tubules were less evident in Groups 4 and 5 which received ozone treatment. To conclude, results of this experimental study demonstrated that ozone treatment might ameliorate biochemical disturbances and histopathological alterations linked with gentamicin-induced nephrotoxicity. However, further trials are warranted to document the actual therapeutic potential of ozone treatment in the clinical setting.

Keywords: Gentamicin-induced nephrotoxicity, Ozone, Oxidative stress, NGAL, Antioxidant defense

Gentamisinin İndüklediği Nefrotoksisitede Ozonun Koruyucu Etkisi ve Neutrophil Gelatinase-Associated Lipocalin (NGAL) Düzeyleri: Deneysel Çalışma

Öz

Deneysel sıçan modelinde, ozon tedavisinin gentamisin kaynaklı nefrotoksisiteye karşı koruyucu rolünü araştırmak amaçlanmıştır. Bu çalışmaya 5 grup olacak şekilde toplamda 30 rat dahil edildi (her grupta n = 6). Kontrol grubu (Grup 1) sadece izotonik salin alırken, Grup 2 ve 3, sırasıyla 15 mg/kg/gün ve 50 mg/kg/gün dozlarında gentamisin aldı. Grup 4'e 15 mg/kg/gün dozunda gentamisin uygulamasından sonra intraperitoneal ozon tedavisi (1 mg/kg, %5 O₃-%95 O₂) uygulandı. Grup 5'e 50 mg/kg/ gün dozunda gentamisin uygulamasından sonra intraperitoneal ozon tedavisi (1 mg/kg, %5 O₃-%95 O₂) uygulandı. Gliserol uygulanması ile nefrotoksisite oluşturuldu. Serum düzeyleri üre, kreatinin, nötrofil-jelatinaz ilişkili lipokalın (NGAL), laktat dehidrojenaz (LDH), total antioksidan kapasite (TAC) ve protein karbonil ölçüldü ve 5. gün hayvanların sakrifiye edilmesinden sonra böbrekler histopatolojik olarak incelendi. Grup 4'ün; NGAL, LDH, kreatinin, üre, TAC ve protein karbonil gibi oksidatif stresin biyokimyasal belirleyicileri ile daha olumlu sonuçlar verdiği gözlemlendi. Benzer şekilde, kanama, protein döküntüleri ve renal tüplerde epitel hasarı gibi gentamisin ile indüklenen nefrotoksisiteyi gösteren histopatolojik değişiklikler, ozon tedavisi alan Grup 4 ve 5'te daha az belgindi. Bu deneysel çalışmanın sonuçları ozon tedavisinin, gentamisin kaynaklı nefrotoksisite ile bağlantılı biyokimyasal bozuklukları ve histopatolojik değişiklikleri iyileştirebileceğini göstermiştir. Bununla birlikte, klinik ortamda ozon tedavisinin gerçek terapötik potansiyelini belgelemek için daha fazla deneme yapılması gerekmektedir.

Anahtar sözcükler: Gentamisin kaynaklı nefrotoksisite, Ozon, Oksidatif stres, NGAL, Antioksidan savunma



İletişim (Correspondence)



+90 536 4326293



ustabay_dr@hotmail.com

INTRODUCTION

Kidneys are frequently vulnerable to the deleterious effects of various drugs. Among these, antibiotics are the most common medications resulting in nephrotoxicity. The reason for this is excretion of antibiotics or their metabolites and high concentration of these substances in renal tissue. Nephrotoxicity due to antibiotics may occur due to several mechanisms including direct cellular injury, immunological mechanisms, hypersensitivity reactions and intratubular obstruction attributed to precipitation of drugs. Acute renal failure (ARF) linked with acute tubular necrosis, or acute interstitial nephritis may be encountered as a consequence of these pathological processes. Moreover, disturbances of acid-base and electrolyte balances may be detected following the use of antibiotics [1-5].

Nephrotoxicity is diagnosed in 10-25% of patients treated with aminoglycosides. Nephrotoxicity may develop due to the toxic accumulation in the renal cortex and diminution of glomerular filtration and renal blood flow. Risk factors involve advanced age, former renal dysfunction, dehydration, pregnancy, hypothyroidism, metabolic acidosis, use of other nephrotoxic agents (amphotericin B, vancomycin, diuretics, non-steroidal anti-inflammatory drugs, cisplatin, cyclosporin) and long-term administration of antibiotics [6].

In current practice, monitorization of serum levels of creatinine and aminoglycosides, the omission of simultaneous use of other nephrotoxic agents and limitation of the administration of aminoglycosides in short-term are recommended to decrease the risk of nephrotoxicity. Gentamicin is an important aminoglycoside used against Gram (-) bacterial infections. Acute renal failure is detected in up to 20% of patients even after the use of aminoglycosides at therapeutic doses [7-10].

Neutrophil gelatinase-associated lipocalin (NGAL) gene was recently shown to be one of the maximally induced genes early phase in the postischemic and nephrotoxic kidney injury. NGAL production is rapidly increasing in response to renal epithelium damage or inflammation. Animal models of NGAL protein have been shown to increase in renal tubule cells in ischemic and nephrotoxic akute kidney injury, as well as in plasma and urine levels. Protein carbonyl content is the most general and well-used biomarker of severe oxidative protein damage [11-15].

Glycerol administration is an established model for ARF in rats [16]. In the present study, we aimed to investigate the alterations in biochemical markers, and histopathological indicators of renal injury in an experimental model of ARF triggered with the administration of glycerol in rats receiving aminoglycosides at two different doses high doses. Furthermore, we sought whether ozone exhibited a protective effect against the hazardous impacts of gentamicin on kidneys.

MATERIAL and METHODS

Study Design

In this experimental study, ARF was elicited with the use of 50% glycerol at a dose of 9 mL/kg intramuscularly in all groups else than the control group. Five groups (n=6 for each group) consisting of male Sprague-Dawley rats were constituted. The animals were kept under a 12 h light/dark cycle with room temperature maintained at 25°C, humidity at 60% and food and water available ad libitum. The experiments were performed in compliance with the ethical guidelines for investigations in laboratory animals and were approved by the Ethical Committee for Animal Experimentation (The study was approved from the Kafkas University Animal Experiments Local Ethics Committee (KAÜ-HADYEK/2018-076).

After the administration of glycerol, rats were followed-up for macroscopic hematuria. Gentamicin was parenterally given at doses of 15 mg/kg/day and 50 mg/kg/day consecutively for 3 to 5 days. In the control group (Group 1), isotonic saline (0.1 mL) was administered intraperitoneally for five days. Second and third groups received gentamicin at doses of 15 mg/kg/day and 50 mg/kg/day, respectively. In the fourth group, intraperitoneal ozone treatment (1 mg/kg, 5% O₃-95% O₂) was performed after administration of gentamicin at a dose of 15 mg/kg/day. The fifth group underwent ozone treatment intraperitoneally (1 mg/kg, 5% O₃-95% O₂) following application of gentamicin (50 mg/kg/day). After the treatment protocols were complete, intracardiac blood samples were obtained from rats that were kept fasting for 8 h. Body weights of all animals were recorded in 5 groups. Prior to the intervention, thiopental sodium was intraperitoneally given at a dose of 75 mg/kg. Animals were sacrificed on the 5th day, while those with the deterioration of general condition, poor feeding, significant macroscopic hematuria were sacrificed on the 3rd day. Kidneys were rapidly dissected, removed and fixed in 10% formaldehyde. Tissues were embedded in paraffin, sectioned at 3 mm, stained with hematoxylin and eosin (H/E) and evaluated under light microscopy.

Outcome Parameters

Histopathological examination involved assessment of intratubular hemorrhage, intratubular protein leakage, tubular epithelial injury, interstitial hemorrhage and inflammation, glomerular injury and edema in kidney tissue.

Biochemical indicators under investigation were neutrophil gelatinase-associated lipocalin (NGAL) (ng/mL), antioxidant (Mm), protein carbonyl (nmol/mL), urea (mg/dL), lactate dehydrogenase (LDH) (U/L), and creatinine (mg/dL).

The laboratory investigators were blinded to the sample sources and clinical outcomes until the end of the study.

Measurement of Biochemical Indicators

Neutrophil Gelatinase-Associated Lipocalin (NGAL): For measurement of serum NGAL levels, ELISA was performed in accordance with the previous literature [17]. Microtiter plates pre-coated with a mouse monoclonal antibody raised against human NGAL (HYB211-05, AntibodyShop, Gentofte, Denmark) were blocked with buffer containing 1% bovine serum albumin, coated with 100 µL of serum samples or standards (NGAL concentrations ranging from 1-1000 ng/mL, Randox Laboratories, Crumlin, UK), and incubated with a biotinylated monoclonal antibody against human NGAL (HYB211-01B, AntibodyShop) followed by avidin-conjugated HRP (Dako, Carpinteria, CA, USA). TMB substrate (BD Biosciences, San Jose, CA) was added for color development, which was read after 30 min at 450 nm with a microplate reader (Benchmark Plus, BioRad, Hercules, CA, USA). All measurements were made in triplicate. The inter- and intra-assay coefficient variations ranged between 5-10%.

Total Antioxidant Capacity (TAC): Total antioxidant capacity (TAC) was measured in serum via a commercially available kit (Randox Co, England). The assay is based on the incubation of 2, 2'-azinodi-(3-ethylbenzthiazoline sulphonate) (ABTS) with methmyoglobin and hydrogen peroxide to produce the radical cation ABTS⁺, which has a relatively stable blue-green color, measured at 600 nm. The suppression of the color is compared with that of the Trolox, which is widely used as a traditional standard for TAS measurement assays, and the assay results are expressed as Trolox equivalent (mmol/L) [18].

Protein Carbonyl: Serum protein levels were measured, and the concentration was brought to 0.5-2.0 mg protein in the test sample by diluting with high purity water (TKA MicroMed, TKA Wasseraufbereitungssysteme GmbH, Germany). Protein carbonyls (damaged proteins) in the serum were measured using a commercially available protein carbonyl content kit (BioVision Inc., USA) according to the manufacturer's instructions [19].

Urea and Creatinine: Serum urea and creatinine were determined using the standard assay kit following back titration, diacetyl monoxime, and alkaline picrate methods, respectively [20].

Lactate Dehydrogenase (LDH): Following serum preparation, level of LDH was measured using the method described by Buhl and Jackson [21].

Statistical Analysis

Biochemical variables were compared using one way ANOVA, and post hoc comparisons were carried out by Tukey HSD test under the assumption of equal variances. The assumption of normality is assessed with the Shapiro-Wilk test for each group ($P > 0.05$). The pathological variables were compared using the Fisher's exact tests.

RESULTS

A comparative analysis of biochemical variables including NGAL, protein carbonyl, urea, creatinine, and LDH in 5 experimental groups is shown in *Table 1* and *Fig. 1*. Our results yielded that Group 4 displayed the most favorable results in terms of markers of antioxidant defense and oxidative stress. Interestingly, an increased dose of gentamicin seemed to result in deterioration of oxidative system balance in spite of administration of ozone treatment. An increased dose of gentamicin without administration of ozone treatment was associated with a more obvious increase in biochemical variables, whereas rats receiving the therapeutic dose of gentamicin together with the application of ozone treatment displayed the most favorable outcomes.

In *Table 2*, an overview of frequencies of histopathological alterations is presented. Accordingly, hazardous histopathological effects of gentamicin-induced nephropathy such as intratubular hemorrhage, tubular protein cast formation and tubular epithelial injury were alleviated by administration of ozone treatment in Group 4. However, histopathological changes such as interstitial hemorrhage and interstitial inflammation did not display any significant differences between any groups. *Fig. 2-5* demonstrate various histopathological alterations that occur secondary to gentamicin-induced nephrotoxicity.

DISCUSSION

The purpose of the present study was to determine the effect of ozone treatment against gentamicin-induced nephrotoxicity in an experimental rat model. Histo-pathological and biochemical evaluations of tissue and serum samples obtained from subjects demonstrated that ozone treatment alleviated the nephrotoxic effects, particularly in rats receiving therapeutic doses of gentamicin. These effects were evident both at the tissue level and in terms of biochemical oxidative stress marker levels.

The mechanism underlying aminoglycoside-induced nephrotoxicity is not well elucidated. The increase in oxidative stress markers and pathological alterations in renal tissue may provide important hints on the underlying pathophysiology. Histopathological examination of the kidneys of rats yielded that intratubular hemorrhage, tubular epithelial injury, glomerular injury and edema might reflect the renal injury secondary to aminoglycosides. As a novel mode of treatment, ozone may have remarkable potential as a protective agent against gentamicin-induced nephrotoxicity. As shown in relevant publications, the basis for this potential may be related to antioxidative mechanisms [22].

Borrego et al. [23] reported that oxidative preconditioning with ozone (O₃) displayed protective effects against drug-induced acute nephrotoxicity in rats. They noted that

Variable	Groups					P ⁺
	Group 1	Group 2	Group 3	Group 4	Group 5	
NGAL (ng/mL) Min-Max (Mean)	4.2-10.0 (6.4)	24.7-51.7 (41.52)	45.6-81.3 (68.6)	10.1-22.5 (16.2)	20.5-67.1 (43.1)	<0.001
Tukey HSD Test/F value	(2.1) ^{b,c,e}	(10.2) ^{a,c,d}	(14.3) ^{a,b,d,e}	(4.2) ^{b,c,e}	(18.0) ^{a,c,d}	
TAC (Mm) Min-Max (Mean)	2.0-3.8 (2.8)	3.2-3.8 (3.6)	2.1-3.7 (3.1)	3.8-4.6 (4.2)	3.9-4.7 (4.3)	<0.001
Tukey HSD Test/F value	(0.7) ^{d,e}	(0.2)	(0.6) ^{d,e}	(0.3) ^{a,c}	(0.4) ^{a,c}	
Protein carbonyl (nmol/mL) Min-Max (Mean)	43.4-80.4 (64.5)	75.0-108.8 (87.9)	94.2-115.9 (101.2)	68.8-89.5 (79.3)	68.1-83.6 (77.7)	<0.001
Tukey HSD Test/F value	(12.8) ^{b,c}	(12.2) ^a	(8.6) ^{a,d,e}	(7.9) ^c	(7.4) ^c	
Urea (mg/dL) Min-Max (Mean)	34-58 (41.3)	364-632 (488.3)	505-771 (624.0)	58-352 (198.3)	398-771 (498.2)	<0.001
Tukey HSD Test/F value	(8.8) ^{b,c,e}	(102.7) ^d	(115.9) ^{a,d}	(112.8) ^{b,c,e}	(155.1) ^{a,d}	
LDH (U/L) Min-Max (Mean)	736-913 (834.5)	953-1182 (1100.5)	1471-2204 (1769.0)	354-1380 (839.5)	763-1123 (962.8)	<0.001
Tukey HSD Test/F value	(71.6) ^c	(80.0) ^c	(319.5) ^{a,b,d,e}	(350.8) ^c	(145.0) ^c	
Creatinine (mg/dL) Min-Max (Mean)	0.45-0.59 (0.50)	4.73-7.98 (6.23)	9.43-11.7 (10.35)	2.85-5.75 (4.05)	3.04-9.48 (6.11)	<0.001
Tukey HSD Test/F value	(0.05) ^{b,c,d,e}	(1.26) ^{a,c}	(0.88) ^{a,b,d,e}	(1.30) ^{a,c}	(3.05) ^{a,c}	

* One-way ANOVA is performed; TAC: total antioxidant capacity; NGAL: neutrophil gelatinase-associated lipocalin; LDH: lactate dehydrogenase; Post hoc comparisons are conducted for further investigation of the differences between individual groups using the Tukey HSD test which assumes equal variances for the groups. Statistically significant differences are presented. ^a P<0.05 is observed for comparison with Group 1; ^b P<0.05 is observed for comparison with Group 2; ^c P<0.05 is observed for comparison with Group 3; ^d P<0.05 is observed for comparison with Group 4; ^e P<0.05 is observed for comparison with Group 5; The letters ^{a,b,c,d,e} in superscripts indicate Groups 1, 2, 3, 4, 5, respectively. They indicate the groups with which the group displays significant difference in terms of variable under investigation

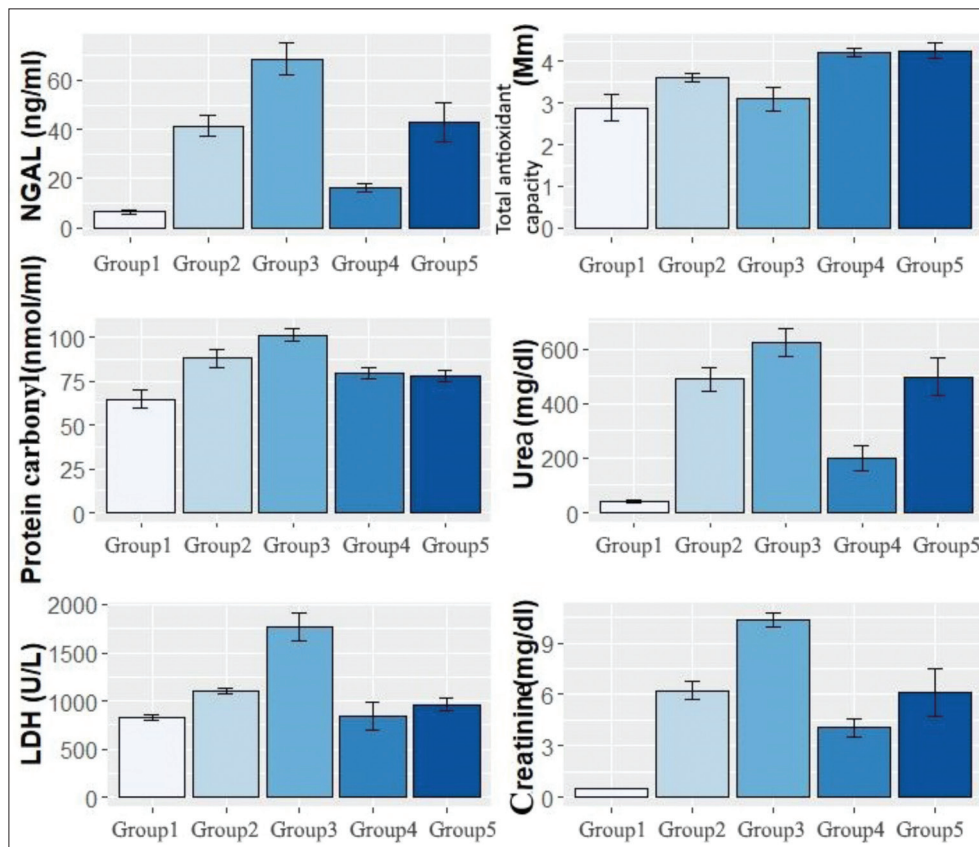


Fig 1. Demonstration of alteration of neutrophil gelatinase associated lipocalin, antioxidant, protein carbonyl, urea, lactate dehydrogenase and creatinine levels in 5 experimental groups

Table 2. Comparison of frequencies for pathological variables						
Pathological Variables	Group 1 (n=6)	Group 2 (n=6)	Group 3 (n=6)	Group 4 (n=6)	Group 5 (n=6)	P*
Intratubular hemorrhage						
None	6 ^{b,c,d,e}	0 ^{a,d,e}	0 ^{a,d,e}	0 ^{a,b,c}	0 ^{a,b,c}	<0.001
Moderate	0 ^{b,c,d,e}	0 ^{a,d,e}	0 ^{a,d,e}	4 ^{a,b,c}	3 ^{a,b,c}	
Mild	0 ^{b,c,d,e}	1 ^{a,d,e}	0 ^{a,d,e}	1 ^{a,b,c}	3 ^{a,b,c}	
Severe	0 ^{b,c,d,e}	5 ^{a,d,e}	6 ^{a,d,e}	1 ^{a,b,c}	0 ^{a,b,c}	
Intratubular protein casts						
None	6 ^{b,c,d,e}	0 ^a	0 ^{a,d}	0 ^{a,c}	0 ^a	<0.001
Moderate	0 ^{b,c,d,e}	0 ^a	0 ^{a,d}	4 ^{a,c}	3 ^a	
Mild	0 ^{b,c,d,e}	5 ^a	3 ^{a,d}	2 ^{a,c}	3 ^a	
Severe	0 ^{b,c,d,e}	1 ^a	3 ^{a,d}	0 ^{a,c}	0 ^a	
Intratubular epithelial injury						
None	6 ^{b,c,d,e}	1 ^{a,d}	0 ^{a,d}	0 ^{a,b,c}	0 ^a	<0.001
Mild	0 ^{b,c,d,e}	0 ^{a,d}	0 ^{a,d}	5 ^{a,b,c}	4 ^a	
Moderate	0 ^{b,c,d,e}	5 ^{a,d}	6 ^{a,d}	1 ^{a,b,c}	2 ^a	
Severe	0 ^{b,c,d,e}	0 ^{a,d}	0 ^{a,d}	0 ^{a,b,c}	0 ^a	
Interstitial hemorrhage	0	0	0	0	0	-
Interstitial inflammation	0	0	0	0	0	-
Glomerular injury						
None	6 ^{b,c}	0 ^a	0 ^a	3	2	<0.01
Minimal	0 ^{b,c}	6 ^a	6 ^a	3	4	
Edema						
None	6	5	5	3	3	N/A
Yes	0	1	1	3	3	
<i>*Fisher's Exact test is performed</i>						
<i>^aP<0.05 is observed for comparison with Group 1; ^bP<0.05 is observed for comparison with Group 2; ^cP<0.05 is observed for comparison with Group 3; ^dP<0.05 is observed for comparison with Group 4; ^eP<0.05 is observed for comparison with Group 5</i>						
<i>The letters a, b, c, d, e in the table indicate Groups 1, 2, 3, 4, and 5, respectively. They show the groups with which the group displays significant difference in terms of variable under investigation</i>						

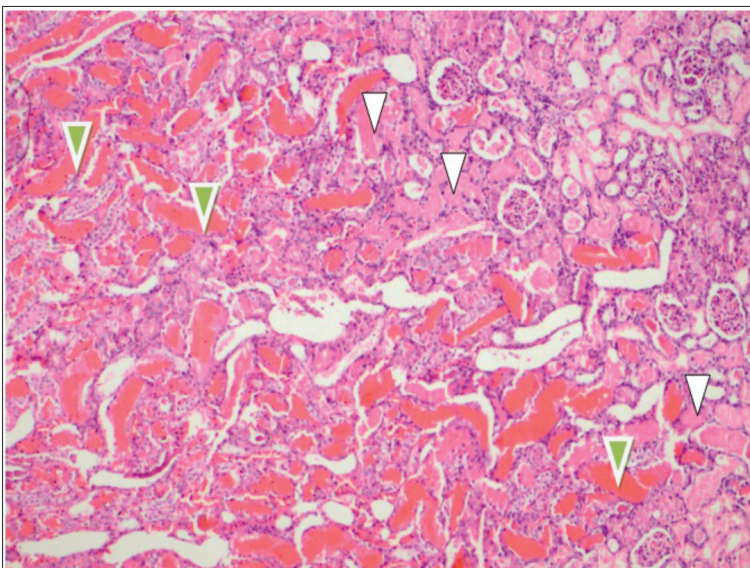


Fig 2. Extensive presence of protein casts and fibrin (H&E; 100x magnification); green arrowheads denote fibrin and white arrowheads indicate protein casts

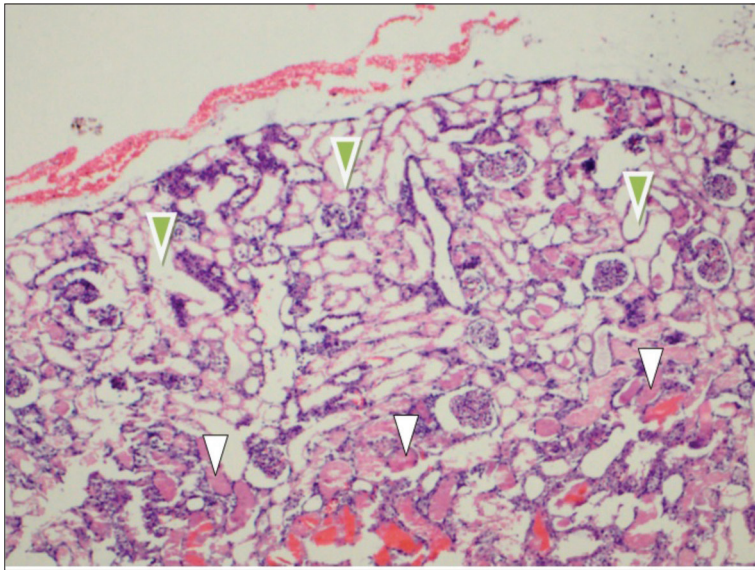


Fig 3. Decreased protein casts in cortical tubules (H&E; 100x magnification), *green arrowheads* show tubules without protein casts, while *white arrowheads* indicate protein casts

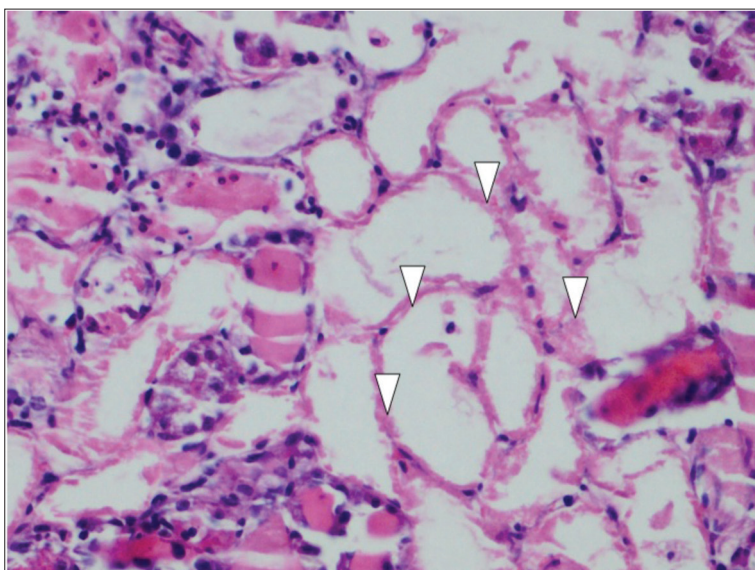
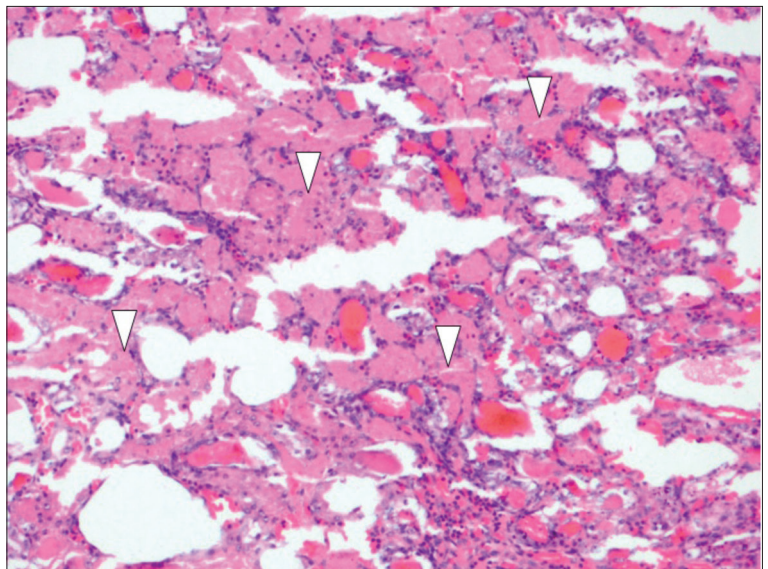
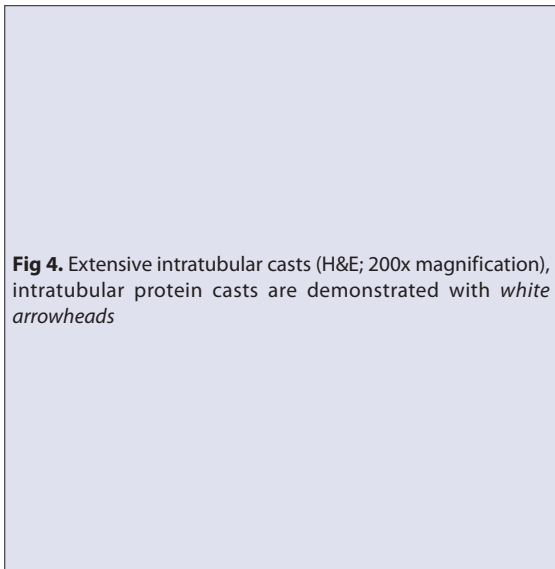


Fig 5. Dilatation and epithelial degeneration in tubules (H&E; 400x magnification), *white arrowheads* indicate degenerated tubular epithelium

ozone treatment remarkably avoided the decrease in renal antioxidant defense mechanisms and thereby avoided the deleterious impacts of drugs [23,24]. They implied that the beneficial effects of ozone treatment were dose-dependent. Ozone treatment was supposed not only to enhance the biosynthesis of antioxidant enzymes but also it could inactivate deleterious pathways of oxidative stress injury [23,24]. In conjunction with our results, ozone treatment may attenuate renal tubular damage and facilitate the regenerative response of damaged renal tubular cells. The renal damage caused by aminoglycosides may be a consequence of depletion and inhibition of antioxidant systems.

Aminoglycosides have been commonly used due to their powerful effects particularly against life-threatening Gram (-) infections. However, nephrotoxicity may occur in up to 10-15% of patients and may influence the rates of morbidity, mortality, cost-effectivity as well as the duration of hospitalization [1,2,25]. Aminoglycosides are polycationic drugs that are water-soluble, and they scarcely bind to plasma proteins. They are excreted from kidneys without any significant metabolic change. Some amount of drug may bind to the anionic phospholipids on the apical membrane of tubular cells, and it may be transferred intracellularly to lysosomes using pinocytosis. The subsequent release of lysosomal content to the cytoplasm may cause deterioration of respiratory functions of mitochondria, which leads to the formation of reactive oxygen species. Accumulation of drug in renal cortex causes a high level of drug at tissue compared to the serum drug levels. Binding of aminoglycosides on the double phospholipid layer of cell membrane adversely affects the transport processes and receptor functions. Thereby, the damaged cellular membrane cannot be repaired, and necrosis can be evident. Clinically, aminoglycoside-induced nephrotoxicity may lead to various renal findings. Deterioration of proximal tubular transport may result in glucosuria, aminoaciduria, and tubular proteinuria. Loss of potassium and magnesium may be attributed to an adverse effect on membrane transport and cellular permeability. Disturbance of the effect of adenylate cyclase on renal collecting ducts may cause failure of the concentrating function of kidneys in case of aminoglycoside-induced nephrotoxicity. Aminoglycoside nephrotoxicity is diagnosed clinically as a non-oliguric acute renal failure after administration of aminoglycoside treatment for about one week. Monitorization of drug levels to foresee nephrotoxicity is a controversial issue since the increase of threshold value is mostly due to the decrease of excretion linked with diminution of glomerular filtration rate. In other words, the increased threshold already indicates the presence of nephrotoxicity. Furthermore, there has been no relationship between peak aminoglycoside levels and occurrence of renal failure. Thus, follow-up of aminoglycoside levels has very limited value for early identification of nephrotoxicity [1,2,26-28].

In the literature, there are publications that support the beneficial effects of ozone treatment against cisplatin-induced nephrotoxicity [23,24]. To the best of our knowledge, this study is the first trial that demonstrated the protective effects of ozone against gentamicin-induced nephrotoxicity. We hope that our promising results for the use of ozone to ameliorate the hazardous effects of aminoglycosides on kidneys may encourage implementation of further experimental and clinical trials on this topic. The utility of ozone against gentamicin-induced nephrotoxicity may not only improve the rates of mortality and morbidity, but it may also contribute to achieving a more favorable cost-effectivity.

The oxidative features of ozone function as a double-edged sword. The generation of reactive oxygen species (ROS) may trigger either cell-activation or impairment depending on the amount. Usually, an optimal amount of ROS may activate phosphokinases and enhance the intracellular calcium levels; exerting a cytoprotective effect. On the other hand, a large amount of ROS is associated with hyperoxidation of DNA lipids and proteins, which in turn causes further impairment of cellular metabolism [23]. Hence, determination of the optimal dose in ozone treatment is a key point that remains to be investigated in further studies.

Moreover, possible protective roles of other antioxidant agents such as vitamin E, ascorbic acid, lipoic acid and glutathione against aminoglycoside-induced nephrotoxicity must be elucidated. Borrego et al. [23] have reported that ozone pretreatment had eliminated the increase in serum creatinine levels and had inhibited the acute tubular necrosis induced by cisplatin in renal tissue. Our data demonstrated that ozone might display these beneficial effects similarly versus gentamicin-induced nephrotoxicity.

Evaluation of both biochemical and histopathological aspects of ozone was a strength of the present study. On the other hand, lack of investigation of the dose-related effects of ozone treatment on gentamicin-induced nephrotoxicity was a weakness of our study.

To conclude, results of this experimental study demonstrated that ozone treatment might ameliorate biochemical disturbances and histopathological alterations due to gentamicin-induced nephrotoxicity. However, further trials are warranted to document the actual therapeutic potential of ozone treatment in the clinical setting.

ACKNOWLEDGMENTS

The authors declare no competing interests.

FUNDING STATEMENT

No financial support or funding was received for this paper.

REFERENCES

1. **Kaloyanides GJ:** Metabolic interactions between drugs and renal tubulointerstitial cells: Role in nephrotoxicity. *Kidney Int*, 39, 531-540, 1991. DOI: 10.1038/ki.1991.61
2. **Kaloyanides GJ:** Antibiotic-related nephrotoxicity. *Nephrol Dial Transplant*, 9 (Suppl.4): 130-134, 1994.
3. **Atamer Şimşek Ş:** Antimikrobiklerin böbreğe istenmeyen etkileri. *Klinik Derg*, 4, 114-119, 1991.
4. **Ecder ST:** Antibiyotik nefrotoksitesi. *ANKEM Derg*, 12, 366-368, 1998.
5. **Parlakpınar H, Örümlü MH, Acet A:** Free oxygen radicals in drug-induced nephrotoxicity. *F Ü Sağ Bil Tıp Derg*, 27 (1): 51-56, 2013.
6. **Radigan EA, Gilchrist NA, Miller MA:** Management of aminoglycosides in the intensive care unit. *J Intensive Care Med*, 25 (6): 327-342, 2010. DOI: 10.1177/0885066610377968
7. **Wargo KA, Edwards JD:** Aminocyclitol-induced nephrotoxicity. *J Pharm Pract*, 27, 573-577, 2014. DOI: 10.1177/0897190014546836
8. **Ateşşahin A, Karahan I, Yılmaz S, Çeribaşı AO, Pirincci I:** The effect of manganese chloride on gentamicin-induced nephrotoxicity in rats. *Pharmacol Res*, 48 (6): 637-642, 2003. DOI: 10.1016/S1043-6618(03)00227-5
9. **Ali BH, Al-Qarawi AA, Mousa HM:** The effect of calcium load and the calcium channel blocker verapamil on gentamicin nephrotoxicity in rats. *Food Chem Toxicol*, 40 (12): 1843-1847, 2002. DOI: 10.1016/S0278-6915(02)00167-9
10. **Walker PD, Shah SV:** Evidence suggesting a role for hydroxyl radical in gentamicin-induced acute renal failure in rats. *J Clin Invest*, 81, 334-341, 1988.
11. **Mishra J, Mori K, Ma Q, Kelly C, Yang J, Mitsnefes M, Barasch J, Devarajan P:** Amelioration of ischemic acute renal injury by neutrophil gelatinase-associated lipocalin. *J Am Soc Nephrol*, 15, 3073-3082, 2004. DOI: 10.1097/01.ASN.0000145013.44578.45
12. **Karadeniz Z, Tuncel Z, Yapıcı N, Kudsioğlu T, İzgi Çoşkun F, Nuraç H, Karacı AR, Karabulut S, Ukil F, Öğütmen B, Aykaç Z:** Akut böbrek hasarının erken tanısında plazma ngal (neutrophil gelatinase-associated lipocalin) etkinliğinin off-pump ve on-pump kalp cerrahisinde karşılaştırılması. *GKDA Derg*, 19 (4): 168-174, 2013. DOI: 10.5222/GKDAD.2013.168
13. **Yuen PST, Jo SK, Holly MK, Hu X, Star RA:** Ischemic and nephrotoxic acute renal failure are distinguished by their broad transcriptomic responses. *Physiol Genomics*; 25 (3): 375-386, 2006. DOI: 10.1152/physiolgenomics.00223.2005
14. **Altekin E, Kenesarı Y:** NGAL as a potential diagnostic biomarker. *Türk Klinik Biyokimya Derg*, 11 (1): 37-41, 2013.
15. **Dalle-Donne I, Giustarini D, Colombo R, Rossi R, Milzani A:** Protein carbonylation in human diseases. *Trends Mol Med*; 9 (4): 169-176, 2003. DOI: 10.1016/S1471-4914(03)00031-5
16. **Medhat Hegazy A, Hafez AS, Eid RM:** Protective and antioxidant effects of copper-nicotinate complex against glycerol-induced nephrotoxicity in rats. *Drug Chem Toxicol*, 26, 1-6, 2018. DOI: 10.1080/01480545.2018.1481084
17. **Schmidt-Ott KM, Mori K, Kalandadze A, Li JY, Paragas N, Nicholas T, Devarajan P, Barasch J:** Neutrophil gelatinase-associated lipocalin-mediated iron traffic in kidney epithelia. *Curr Opin Nephrol Hypertens*, 15 (4): 442-449, 2006. DOI: 10.1097/01.mnh.0000232886.81142.58
18. **Hajhosseini L, Khaki A, Merat E, Ainehchi N:** Effect of rosmarinic acid on sertoli cells apoptosis and serum antioxidant levels in rats after exposure to electromagnetic fields. *Afr J Tradit Complement Altern Med*, 10 (6): 477-480, 2013.
19. **Fernando N, Wickremesinghe S, Niloofa R, Rodrigo C, Karunanayake L, de Silva HJ, Wickremesinghe AR, Premawansa S, Rajapakse S, Handunnetti SM:** Protein carbonyl as a biomarker of oxidative stress in severe leptospirosis, and its usefulness in differentiating leptospirosis from dengue infections. *PLoS One*, 11 (6): e0156085, 2016. DOI: 10.1371/journal.pone.0156085
20. **Saka WA, Akhigbe RE, Popoola OT, Oyekunle OS:** Changes in serum electrolytes, urea, and creatinine in aloe vera-treated rats. *J Young Pharm*, 4, 78-81, 2012. DOI: 10.4103/0975-1483.96620
21. **Buhl SN, Jackson KY:** Optimal conditions and comparison of lactate dehydrogenase catalysis of the lactate to pyruvate and pyruvate to lactate reactions in human serum at 25, 30 and 37°C. *Clin Chem*, 24, 828-831, 1978.
22. **Borrego A, Zamora ZB, González R, Romay C, Menéndez S, Hernández F, Montero T, Rojas E:** Protection by ozone preconditioning is mediated by the antioxidant system in cisplatin-induced nephrotoxicity in rats. *Mediators Inflamm*, 13, 13-19, 2004. DOI: 10.1080/09629350410001664806
23. **Borrego A, Zamora ZB, González R, Romay C, Menéndez S, Hernández F, Berlanga J, Montero T:** Ozone/oxygen mixture modifies the subcellular redistribution of Bax protein in renal tissue from rats treated with cisplatin. *Arch Med Res*, 37 (6): 717-722, 2006. DOI: 10.1016/j.arcmed.2006.02.008
24. **González R, Borrego A, Zamora Z, Romay C, Hernández F, Menéndez S, Montero T, Rojas E:** Reversion by ozone treatment of acute nephrotoxicity induced by cisplatin in rats. *Mediators Inflamm*, 13, 307-312, 2004. DOI: 10.1080/09629350400008836
25. **Appel GB, Neu HC:** Gentamicin in 1978. *Ann Intern Med*, 89, 528-538, 1978.
26. **Maden M, Aslan V:** Deneysel gentamisin nefrotoksitesinde üriner enzim aktivitelerinin önemi. *Türk J Vet Anim Sci*, 23, 29-42, 1999.
27. **Hottendorf GH:** Comparative ototoxicity (cats) and nephrotoxicity (rats) of amikacin and gentamicin. *Am J Aled*, 61, 97-104, 1977.
28. **Pedraza-Chaverri J, Maldonado PD, Mediana-Campos ON, Olivares-Corichi IM, Granados-Silvestre MA, Hernandez-Pando R, Ibarra-Rubio ME:** Garlic ameliorates gentamicin nephrotoxicity: Relation to antioxidant enzymes. *Free Radic Biol Med*, 29, 602-611, 2000. DOI: 10.1016/S0891-5849(00)00354-3