

Atretic Ovarian Follicles Morphology and Immunolocalization of Active Caspase-3 in Algerian Bedouin Goat (*Capra hircus*) Ovaries

Sara KASSOURI-MAOUCHE ¹✉ Nouria BOUKENAOU-FERROUK ^{1,2} Salima CHARALLAH ¹
Elara MOUDILOU ³ Asma CHAKHMA ^{1,2} Jean-Marie EXBRAYAT ³ Zaina AMIRAT ¹ Farida KHAMMAR ¹

¹ University of Sciences and Technology Houari Boumediene (USTHB), Faculty of Biological Sciences, Laboratory of Research on Arid Lands (LRZA), BP 32 El Alia, Bab Ezzouar, 16111, Algiers, ALGERIA

² University Blida 1, Institute of Veterinary Sciences, BP 270 Road of Soumaa Blida, ALGERIA

³ University of Lyon, UMRS 449, General Biology, Reproduction and Comparative Development Catholic University of Lyon, EPHE/PSL, 10 Place of Archives, F-69288 Lyon Cedex 02, FRANCE

Article ID: KVFD-2018-20292 Received: 03.06.2018 Accepted: 10.11.2018 Published Online: 11.11.2018

How to Cite This Article

Kassouri-Maouche S, Boukenaoui-Ferrouk N, Charallah S, Moudilou E, Chakhma A, Exbrayat JM, Amirat Z, Khammar F: Atretic ovarian follicles morphology and immunolocalization of active caspase-3 in Algerian Bedouin goat (*Capra hircus*) ovaries. *Kafkas Univ Vet Fak Derg*, 25 (2): 147-156, 2019. DOI: 10.9775/kvfd.2018.20292

Abstract

This study aims to highlight the cellular and molecular events of atresia in the Bedouin goat ovarian follicles. Ovaries collected from slaughterhouses during breeding and non-breeding seasons were submitted to morphological studies and immunolocalization of active caspase-3. The results showed that ovaries were heavier ($P<0.05$) during the breeding season. The atresia occurred at all stages of follicular development in breeding and non-breeding seasons. At the preantral stage, degeneration affected primarily oocyte and active caspase-3 immunoreactivity was detected in the oocyte with a few staining in follicular cells. At the antral stage, atresia affected in first the granulosa layer cells which were characterized by an abnormal indentation of nuclei and positive active caspase-3 immunolabeling. At the early stage of atresia, the granulosa cells exhibited a few pycnotic nuclei and lost their cellular integrity, by getting scattered; these cells were positive to active caspase-3. At the late stage, the scattered cells invaded the antral cavity and the dead cells were eliminated by phagocytic cells. The oocyte seemed to undertake a long process of atresia via an autophagic pathway and it was the last to die. Finally, the follicle was replaced by a collagen fiber forming a scar of atresia. In conclusion, important morphological changes occurred in atretic follicles mainly in antral stage by apoptosis via caspase-3 signaling pathway, in breeding and non-breeding seasons.

Keywords: Atresia, Apoptosis, Active caspase-3, Breeding season, Non-breeding season, Bedouin goat

Cezayir Bedevi Keçisi (*Capra hircus*)'nde Atretik Ovaryum Folikül Morfolojisi ve Aktif Kaspaz-3 İmmunolokalizasyonu

Öz

Bu çalışmada Bedevi keçisi ovaryum foliküllerinde gelişen atrezide meydana gelen hücresel ve moleküler olaylar tanımlanmıştır. Çiftleşme sezonunda veya dışında kesimhanelerden toplanan ovaryumlar morfolojik çalışmalar ve aktif kaspaz-3 immunolokalizasyonu için kullanıldı. Elde edilen sonuçlar ovaryumların çiftleşme sezonunda daha ağır olduğunu gösterdi ($P<0.05$). Çiftleşme sezonunda veya dışında tüm foliküller gelişme evrelerinde atrezinin olduğu belirlendi. Prenatal evrede, dejenerasyon başlıca oositi etkilemekteydi, ve aktif kaspaz-3 immunoreaktivitesi az sayıda foliküler hücrelerde boyanma şeklinde oositlerde tespit edildi. Antral evrede, atrezi çekirdeğin anormal girinti oluşturması ve pozitif kaspaz-3 immunoboyanması ile karakterize olup ilk sıra granuloza tabakası hücrelerini etkilemekteydi. Atrezinin erken evresinde, granuloza hücreleri az sayıda piknotik çekirdek göstermekte olup hücresel bütünlükleri kaybolmuştu. Bu hücreler dağılmış halde olup aktif kaspaz-3 pozitiftiler. Geç evrede, dağılmış hücreler antral boşluğa yerleşmiş olup ölü hücreler fagosit hücreler tarafından elimine edilmişlerdi. Oosit otofajik yol ile uzun bir atrezi süreci geçirmiş olup son öldü. Son olarak, folikül kollajen fiber ile doldurularak atrezi yarısı oluşturmuştu. Sonuç olarak, hem çiftleşme sezonunda hem de dışında atrezik foliküllerde ve özellikle de antral evrede kaspaz-3 uyarı yoluyla gelişen apoptozis ile karakterize önemli morfolojik değişiklikler oluşmaktadır.

Anahtar sözcükler: Atrezi, Apoptozis, Aktif kaspaz-3, Çiftleşme sezonu, Çiftleşme dışı sezon, Bedevi keçisi



İletişim (Correspondence)



+213 54 9817885



kassourisara@gmail.com

INTRODUCTION

The Bedouin goat (*Capra hircus*) represents a great value for most of people in the western south of Algeria, due to its meat, milk and fibers production. This breed acquires its importance from its perfect adaptation to the harsh environmental conditions of its biotope [1]. This has been confirmed by various ecophysiological and metabolic studies [2-4]. Considering the paramount importance for this community, goat's production level must be maintained properly by increasing fertility and conception rate [5]. This is essential to gain a comprehensive knowledge on the reproductive physiology of this breed and on the mechanisms by which female regulates its reproduction and its follicular pool.

In most mammals, the phenomenal loss of germ cells during folliculogenesis is governed by a physiological process called atresia or follicular involution, a degenerative process that allows the elimination of follicles from the follicular pool. Many studies on follicular atresia have been carried out where the classification criteria for atresia are mainly based on morphological studies [6]. The mechanism of follicular cell death has not been fully elucidated. However, several studies have shown that in mammalian ovaries follicular atresia is under the exclusive control of apoptosis [7], genetically programmed [8] and morphologically distinct form of cell death which is initiated and executed by proteases like the family of cysteine-dependent aspartate-directed proteases [9] and characterized by oligonucleosomal fragmentation of DNA [10]. Active caspase-3, is the main effector caspase of the apoptotic cascade within cells [11]. The detection of this epitope should be a unique and sensitive indicator of apoptosis [12]. Other studies suggested that non apoptotic forms of programmed cell death like autophagy occurred; this process promote cell death by excessive self-digestion and degradation of damaged cellular proteins and organelles [13], characterized by a double-membrane vesicle that encloses organelles and portions of the cytosol [14]. Furthermore, recent studies have demonstrated that autophagy could be triggered by various stimuli inducing apoptosis suggesting that this phenomenon is closely related to apoptosis induction and is gonadotropin dependent [8,15].

In the present study we described the morphological changes in the atretic follicles and the immunolocalization of the active caspase-3 in different cell components of atretic follicles to highlight the cellular and molecular events of atresia in the Bedouin goat ovarian follicles during breeding and non-breeding seasons.

MATERIAL and METHODS

Twenty five paired ovaries from adult cyclic Bedouin goats were collected from Bechar slaughterhouses (South West of Algeria, 31°.62' N., 2°.22' W.). This experimentation was

conducted on 7 females from non-breeding and 18 females from breeding seasons, aged from 2 to 5 years. Ovaries were removed, degreased, weighed then transported to the laboratory in warm (37°C) physiological saline solution within 2 h. After that, they were rinsed with PBS (Phosphate Buffer Saline), transferred to Petri dishes for macroscopic observations then fixed in 4% (w/v) paraformaldehyde at room temperature for 24 h; samples were sectioned along the axis of the helium and then dehydrated in a graded series of ethanol, clarified in xylene, embedded in paraffin and sectioned at 4 µm. Sections were mounted in order and put on slides for histological studies, hydrated and stained with Hematoxylin-Eosin (H&E) and Heidenhain azan. Ovarian sections were analysed by light microscopy (Optika B-350) using a computer program Ts View connected to a digital camera (Hirocam MA88-500).

Follicles Classification

The histological classification of ovarian follicles stages was evaluated according to the methods described by Rodgers and Irving-Rodgers [16]. The differentiation between healthy and atretic follicles was determined according to the classification criteria of follicular atresia proposed by the Nomenclature Committee on Cell Death (NCCD) [6]. The follicle was considered as atretic when one of the following morphologic criteria was observed: 1- Follicular cells loose the integrity of their plasma membrane and some apoptotic bodies appeared; 2- The connections in granulosa layers became loose; 3- Granulosa cells were massively eliminated; 4- Residual follicular cells and oocyte were degenerated.

Immunolocalization of Active Caspase-3

The presence of active caspase-3 in the ovaries was investigated by immunohistochemistry using Avidin-Biotin Complex method (ABC) (vectastain Elite ABC kit, Vector Laboratories, Burlingame). After a deparaffinization and hydration, sections were permeabilized at room temperature in saponin (Fischer Scientific UK) and proteinase K (Eurobio) (0.2 mg/mL) mixture; this was followed by endogenous peroxidase blocking using H₂O₂ (3%) in PBS (0.1 M; pH=7.2) at room temperature. Tissue sections were washed in PBS. The antigen was blocked at room temperature with normal horse serum in a wet chamber. All sections were incubated for 1 h at room temperature with the primary antibody: a rabbit monoclonal anti- active caspase-3 (ab32042, Abcam, Cambridge, UK), which was diluted at 1:100 in PBS. Tissue sections were washed and incubated with a biotinylated mouse anti-rabbit IgG antibody (Ca 94010, Vectastain Elite ABC Kit, Vector Laboratories, Burlingame) at 1:200 dilution for 1 h at room temperature. The samples were washed and incubated for 1 h at room temperature with horse-radish peroxidase-conjugated-streptavidin. After washing, labeling was visualized with 3, 3'-diaminobenzidine-tetrahydrochloride chronic substrate (SK-4100, DAB substrate kit for peroxidase; Vector Laboratories). Sections were counterstained with hematoxylin (Hematoxylin QS, H-3404;

Vector lab, Burlingame, A, USA) and analyzed by light microscopy. Sections incubated with normal horse serum rather than primary antibody were used as negative controls. Immunohistochemical staining was evaluated using semi-quantitative methods and estimated at four levels: -/ no labeling, +/- variable, +/ moderate, ++/ intense.

Transmission Electron Microscopy Analysis

Antral follicles ($\geq 5\text{mm}$) dissected out under a binocular loupe, rinsed in PBS and cut into small pieces (1 mm^3) were prefixed in Karnovsky fixative mixture (2.5% Glutaraldehyde, 4% Paraformaldehyde) diluted in PBS for 2 h at 4°C ; then post-fixed in 1% osmium tetroxide diluted in PBS, dehydrated in graded ethanol series (50° , 70° , 90° , 100°), cleared with acetone and finally embedded in araldite (Agar Scientific Ltd.). Ultrathin sections (0.8 nm; ultramicrotome LKB V) mounted on copper grids (200 mesh) were double contrasted with uranylless (R&D-Delta Microscopies-France) and lead citrate (Wako). The sections were examined and photographed using a transmission electron microscope (Hitachi H7700, Hitachi, Tokyo, Japan) equipped with high-resolution camera.

Statistical Analysis

Results were expressed as mean \pm SEM. Statistical significance of differences between different parameters was examined by Mann Whitney test using R statistical software (R 3.4.2); $P < 0.05$ was considered to be statistically significant.

RESULTS

Ovaries Weight

The weight of the paired ovaries was $1.6 \pm 0.27\text{ g}$ in non breeding season and $2.5 \pm 0.17\text{ g}$ in breeding season (Fig. 1) and was significantly different between the two seasons ($P < 0.01$).

Morphological Analysis of Ovaries

The ovaries were found almond shaped with pale colored structures localized in the edge of the mesovarium near the lateral margin of the pelvic inlet (Fig. 2). The ovaries located within and on the floor of the pelvic cavity were ovoid shaped and flattened. Their surface was irregular by the presence of follicles and the corpora lutea in breeding season and was smoothy, devoid of any follicles in non-breeding season.

The ovaries were enclosed in a fibrous capsule the *tunica albuginea* (Fig. 3a,b). The cortex contains many follicles at different stages of folliculogenesis. The medulla consisted of connective tissue with many blood vessels (Fig. 3c). The ovarian follicles were classified into preantral and antral follicles according to the presence or

not of the antral cavity containing follicular fluid.

The healthy preantral stage regrouped primordial, primary and secondary follicles (Fig. 4a-c). At the primordial follicle (Fig. 4a), the small oocyte was surrounded by flattened not replicating granulosa cells. The primary follicle (Fig. 4b) has a large oocyte surrounded by zona pellucida and then by one layer of cuboidal granulosa cells resting on basal lamina called membrane of Slavjansky (Fig. 4b). The secondary follicle (Fig. 4c), was centered by oocyte, which enclosed nucleus and germinal vesicle and was surrounded with zona pellucida (Fig. 4c); this zone separated granulosa layers from oocyte; at this stage, we observed a differentiation between theca interna and theca externa cells (Fig. 4c). In the antral follicles, the antrum filled with the follicular fluid (Fig. 5a) was delimited by granulosa cells which were replicated massively into apical and basal cells (Fig. 5b). At this stage, we observed the oocyte centered by the

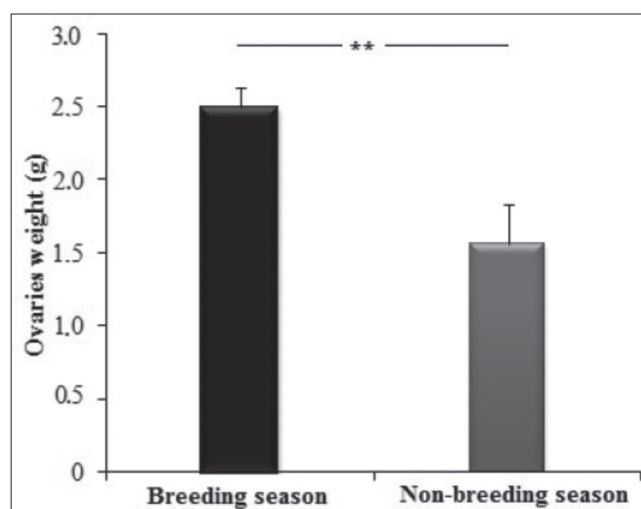


Fig 1. Ovaries weight during breeding and non-breeding seasons in Bedouin goat. Data were expressed as mean \pm ESM. ** $P < 0.01$, statistically significant

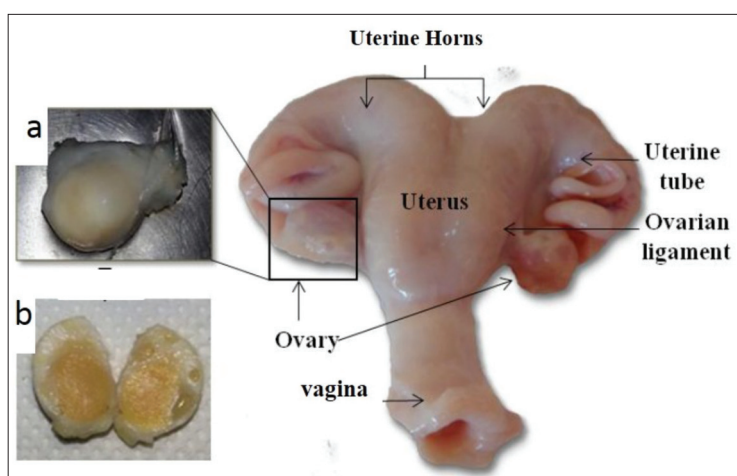


Fig 2. Morphology of female reproductive tractus in Bedouin goat showing the ovaries localization; (a): Ovary; (b): Longitudinal ovary section

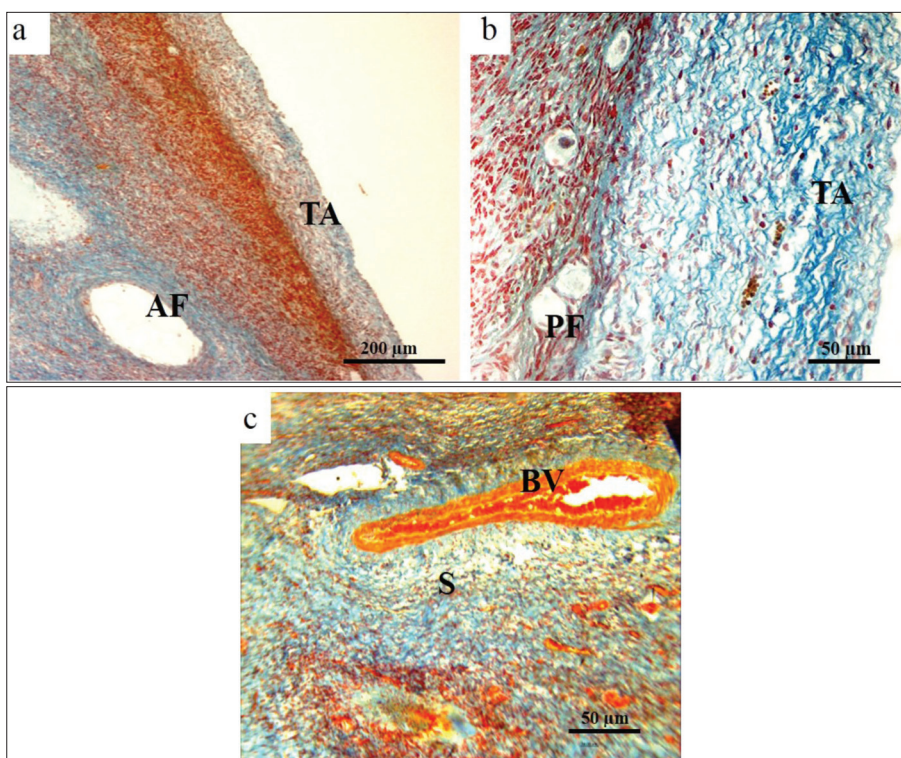


Fig 3. Histology of Bedouin goat ovary. (a) Ovarian cortex; (b) Peripheral cortex with primordial follicles; (c) Ovarian medulla reaches in blood vessels (*arrowhead*); AF: Antral Follicle; PF: Primordial Follicle; S: Stroma; TA: Tunica Albuginea; BV: Blood Vessels

nucleus, surrounded by corona radiata cells and regular zona pellucida (Fig. 5c).

The vast majority of those all ovarian follicles observed were touched by atresia, in breeding and non-breeding seasons. We noticed that atresia in the preantral stage was different from that occurred in the antral stage (Fig. 4, Fig. 5).

At the preantral stages, atresia occurred principally in the oocyte, characterized by vacuolization of oocyte cytoplasm, eccentric nucleus (Fig. 4d) and irregular outline of oocyte followed by irregularities of zona pellucida (Fig. 4e,f). The follicular cells remained unchanged.

At the antral stage, a few follicles were found to be healthy. The early stage of atresia was characterized mainly by several changes in the follicular wall including the basal lamina, which became thick with irregular contour (Fig. 5d); transformed to a vitreous membrane or "membrane of atresia", devoid of any cell type, which ended up dispersing in the ovarian stroma (Fig. 5d). In the granulosa layer, we observed few cells with pycnotic nuclei (Fig. 5e), followed by the destruction of the layers of the membrana granulosa closest to the antrum and a loss in connections between granulosa cells (Fig. 5h). This cells detached and scattered in the antrum were eliminated massively by phagocytic cells (Fig. 5h). At the late stage of atresia, the antral cavity was invaded completely by the scattered cells (Fig. 5d). The detached cells from the follicle wall induced morphological changes of the basal layer of the granulosa cells (Fig. 5e). The oocyte degenerated very late, characterized by the irregular contour with irregular zona pellucida and marginal nucleus (Fig. 5f); the oocyte cytoplasm was

completely vacuolized and its nucleus disappeared (Fig. 5i). At the end of atresia process, the follicles disappeared totally leaving behind a scare of atresia (Fig. 5g).

The ultrastructure of the atretic follicle wall showed in the granulosa layer (Fig. 6), cells with abnormally indented nuclei with condensed chromatin forming small clumps (Fig. 6a) and neighboring cells with cytoplasmic prolongations surrounding dead cells (Fig. 6b). The healthy granulosa cells adjacent to the antrum presented the nuclei centered by the nucleoli with the fibrillar center and the dense fibrillar component (Fig. 6c); in its cytoplasm a lot of lipid droplets and cytoplasmic organelles were observed (Fig. 6d). The theca interna contained many homogenous cells, blood vessels and numerous collagen fiber and leukocytes (Fig. 6e). The theca externa was constituted with elongated homogenous cells with elongated nuclei (Fig. 6f).

The percentage of healthy and atretic follicles at different stages and seasons (breeding and non-breeding) was reported in Fig. 7. The number of atretic primordial follicles was lower than the healthy ones. The follicular stage affected by atresia was principally the tertiary stage and showed a significant increase in number of atretic follicles compared to healthy follicles in all seasons (Fig. 7). At this stage, the number of atretic follicles was significantly higher ($P < 0.001$) in breeding and non-breeding seasons (Fig. 7).

Immunohistocalization of Active Caspase-3

The active caspase-3 observed in preantral and antral stages, compared to negative control, was observed during the breeding and non-breeding seasons (Fig. 8; Fig. 9).

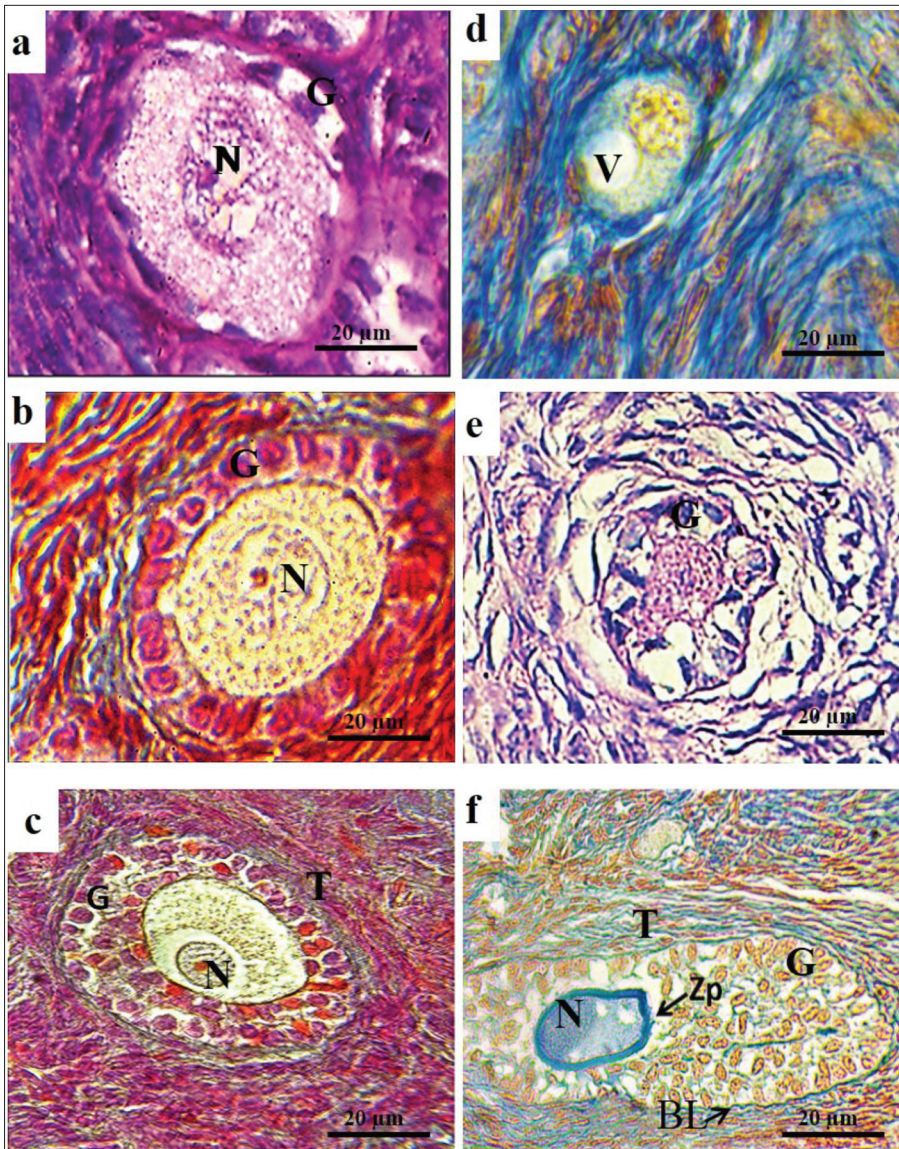


Fig 4. Histology of atretic preantral follicles compared to the healthy follicles. (a) Healthy primordial follicle; (b) Healthy primary follicle; (c) Healthy secondary follicle; (d) Atretic primordial follicle; (e) Atretic primary follicle; (f) Atretic secondary follicle; BL: Basal Lamina; G: Granulosa; N: nucleus; T: Theca; V: Vacuole; Zp: Zona pellucida; (a) and (e): stained with H&E; (b, c, d and f): stained with azan

At the preantral stage, active caspase-3 immunoreactivity was observed in the cytoplasm of the oocyte (Fig. 8) and few staining in nuclear follicular cells (Fig. 8a,d). The intensity of oocyte labeling was variable from primordial to primary follicles (Fig. 8a,c; Table 1); no labeling was observed at the oocyte of secondary follicle (Fig. 8e, Table 1). At this stage, positive cells appeared in granulosa and theca cells (Fig. 8e,f; Table 1).

At the antral stage, no staining was detected in the oocyte. A cytoplasmic immunoreactivity of granulosa, theca, and cumulus oophorus cells was observed with a little nuclear immunoreactivity (Fig. 9, Table 1).

DISCUSSION

The weight of Bedouin goat ovaries during non-breeding season was similar to those reported in Sahel and Sokoto Red goat breeds [17] and higher than that reported in Bengal and local Andhra Pradesh goat breeds [5,18,19].

In breeding season, the weight of ovaries was higher than that reported in several goat breeds [5,17-19]. This difference in weight was explained by a cyclic formation of corpus luteum characterized by a hypertrophy of luteinized granulosa cells, a fibroblast hyperplasia of the connective tissues and a vascularity which contribute to an increase in the size of the corpus luteum in breeding season [20].

Morphological aspect of ovaries was similar to that reported in Black Bengal goat [5,17]. During breeding and non breeding seasons, the folliculogenesis was accompanied by a physiological regulation process called atresia described in detail for the first time by Logothetopoulos et al. [21], this process induced many structural changes in the different components of the follicle according to the follicular stage. In our goat breed, the detection of signs of the atretic process in all follicular stages confirmed that atresia can occur at all stage of the development. Similar observations have

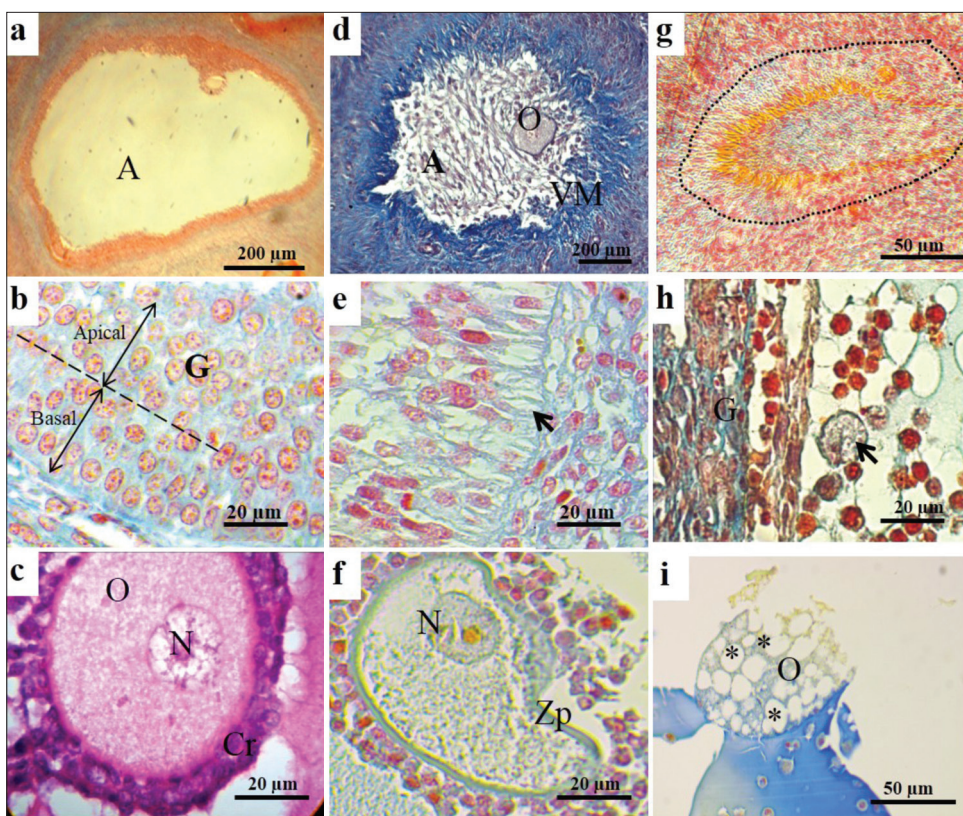


Fig 5. Histology of atretic antral follicles showing early and late stages of antral atretic follicles compared to healthy follicles. (a) Healthy large antral follicle; (b) Healthy granulosa layer with cuboidal cells resting on basal lamina; (c) Oocyte from healthy follicle. (d) Atretic follicle: granulosa invaded the antral cavity with intact oocyte, basal lamina transformed into vitreous membrane; (e) Granulosa layer from early atretic follicle: disorganization of follicular cells and extension of the cells adjacent to the basal lamina; (f) Oocyte from early atretic follicle: eccentric nuclei and irregularity in outline of oocyte accompanied with irregularity of zona pellucida; (g) The hatched line shows a scare of follicle atresia; (h) Granulosa layer from late atretic follicle: scattered cells with pycnotic nuclei and their migration in antral cavity, observation of phagocytic cells (arrow-head); (i) Appearance of some autophagic vacuoles in oocyte cytoplasm (asterisk); A: Antrum; Cr: Corona radiata; O: Oocyte; VM: Vitreous Membrane; N: nucleus; G: granulosa; Zp: Zona pellucida. (a, b, d, e, f, g, h and i) stained with Azan, (c) stained with H&E

also been reported in other vertebrate species such as the rat [22], sow [23], human [24] mice [25], pig [6], cow [16], ewe [26] and goat [27].

During the preantral stage, the first event of atresia observed in the oocyte of follicle induced a degeneration of the oocyte nucleus and a vacuolization of oocyte cytoplasm as reported in Indian goat [28] and in sow [6]. These vacuoles may contain mitochondria and inflated endoplasmic reticulum [29]. In the Brazilian local goat, it was reported that massive swelling of the mitochondria with disappearing ridges and increased size of the endoplasmic reticulum were the first signs of degeneration of the preantral follicles [30]. According to Kerr et al. [31], and Sharma and Bhardwaj [28], the second event of atresia in preantral follicle concerned the granulosa cells. The compaction and condensation of the chromatin giving the dense appearance to the nuclei is attached to the wall of the nuclear envelope giving it a very irregular appearance. This was depicted in the granulosa of the secondary follicles which seems more sensitive to degeneration than the primordial and the primary follicles, as reported in Brazilian goat [32].

At antral stages, the degeneration of follicles was more complex. In contrast to the preantral stage, in first, our results showed some morphological changes in the wall of the atretic follicles while the oocyte remains unchanged. At early stage of atresia, Escobar et al. [13] reported that the oocyte was particularly resistant to the factors inducing apoptosis. It only degenerated very late with appearance

of multiple vacuoles like autophagic vesicles or autophagosomes. This would suggest that oocyte undergo another form of cell death probably by autophagic process. In granulosa layer of atretic antral follicles, we observed in Bedouin goat, cells with abnormally indented outline of nuclei; as reported in hamster [33]. At the late stage of atresia, the phagocytic cells removed the degenerating cells in the antral cavity by macrophages and in follicular wall by the neighboring intact cells as observed in pig and mice [23,34]. In Bedouin goat we noticed the presence of leukocyte in the theca interna layer cells probably removed by apoptosis as observed in sheep [35]. Finally, our results showed that oocyte from late antral atretic follicle was the last to undergo morphological changes, so it has been shown that changes never occur in oocyte during early stage of atresia [36]. The elimination of oocyte observed in our results was probably due to a physiological process involving an autophagic pathway [13]. This elimination required a micro RNAs regulators implicated in the crosstalk between autophagy and apoptosis according to Xu et al. [15].

The initiation of atresia process was associated with a crosstalk of cell apoptosis, autophagy and ferroptosis rather than change of typical apoptosis markers such as FAS (Fas cell surface death receptor), BAX (BCL2-associated X protein) or caspases [8]. In our study, the localization of active caspase-3 was observed in oocyte cytoplasm and some nuclei of granulosa cells in atretic preantral follicles. Inversely, active caspase-3 was never observed in granulosa cells of preantral follicles. These results were

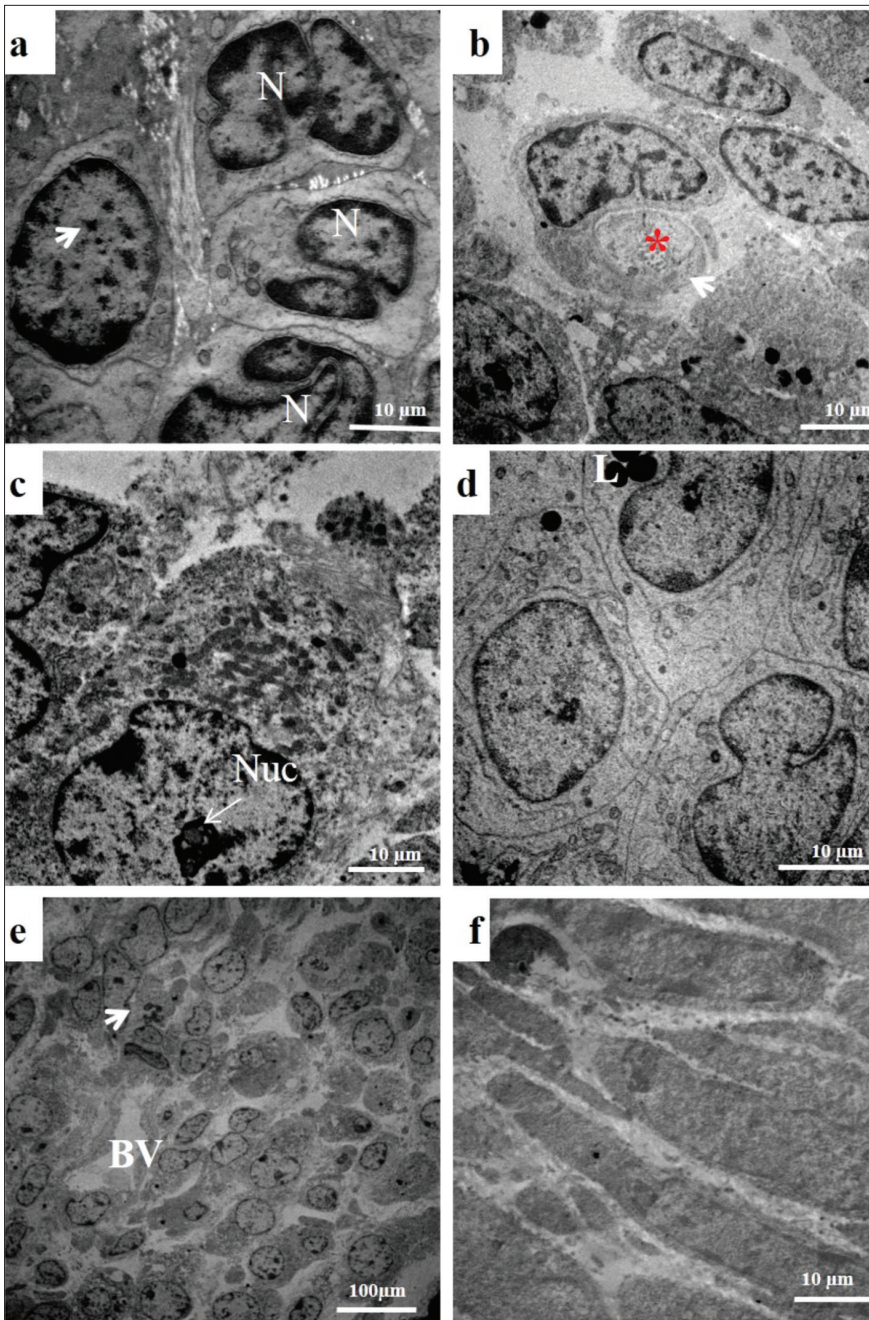


Fig 6. Electron micrographs of the granulosa and theca layers showing different characterization of atresia. (a) Granulosa cells from the atretic follicle have irregular and abnormally indented outline of nuclei with condensed chromatin forming small clumps (*arrow-head*); (b) Phagocytic cell in granulosa cell from advanced atretic follicle eliminates the cell debris (*asterisk*) containing cytoplasmic projections (*arrow-heads*); (c) Healthy granulosa cell with a nucleolus presents the fibrillar center and the dense fibrillar component; (d) Lipid droplets and cytoplasmic organelles were observed similar to the granulosa cells of normal developing follicle; (e) Theca interna layer showing the leukocyte invasion; (f) Theca externa; L: Lipid droplet; N: Nucleus; Nuc: Nucleolus; BV: Blood Vessels

Fig 7. Percentage of follicles at different stages of development during breeding and non-breeding seasons. The difference between atretic and healthy follicle at tertiary stage was significant (** $P < 0.001$) determined by Mann Whitney test

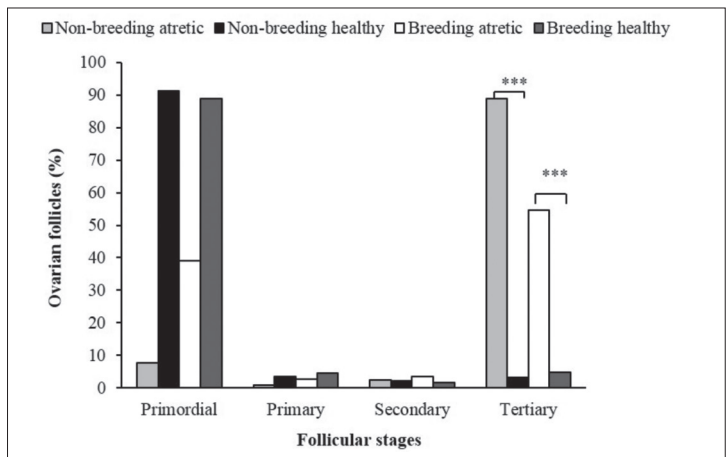


Table 1. Immunolocalization of active caspase-3 in ovarian Bedouine goat follicles

Cells	Preantral Follicles			Antral Follicles
	Primordial	Primary	Secondary	
Oocyte	++	+/-	-	-
Cumulus oophorus	-	-	-	++
Granulosa	-	+/-	+	++
Theca	-	-	+/-	+

Symbols are as follows: - negative, +/- variable, + moderate, ++ strong

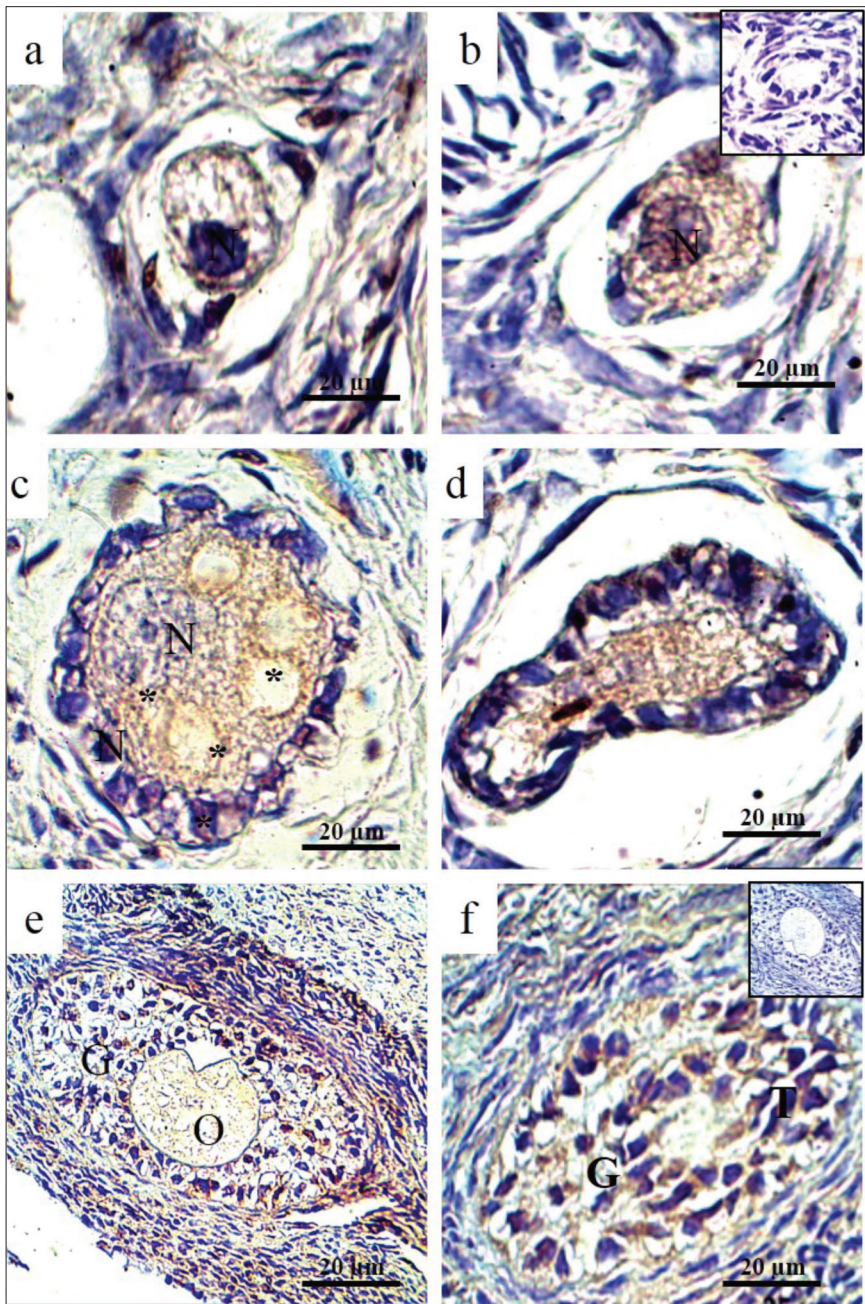


Fig 8. Immunolocalization of active caspase-3 in atretic preantral follicles in Bedouine goat ovaries. (a, b) primordial follicles surrounded by a few flattened follicular cells; (c, d) primary follicles, surrounded by one layer of cuboidal follicular cells; (e, f) secondary follicles. No immunostaining was observed in negative controls (inset); G: Granulosa; N: Nucleus; O: Oocyte; T: Theca

consistent with those found in small follicles of human ovary [24]. In the antral follicles, no labeling was detected in the oocytes despite the morphological abnormalities

observed. However, a more frequent positive signal was detected in the granulosa cell, cumulus oophorus and theca cells; similar results were reported in rat [37]. Some

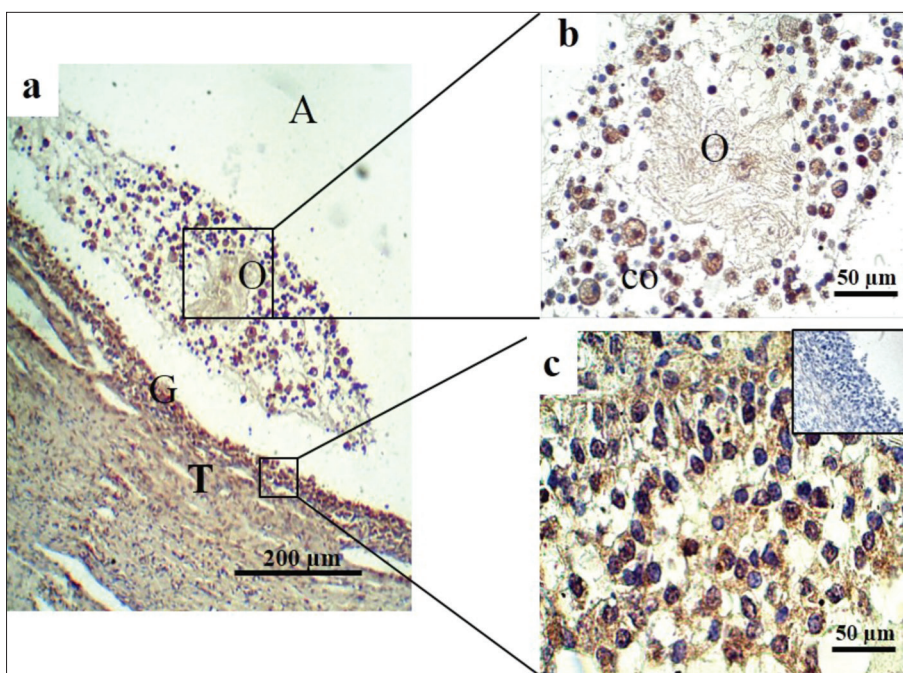


Fig 9. Immunolocalization of active caspase-3 in atretic antral follicles in Bedouin goat ovaries. No immunostaining was observed in negative controls (inset). (a) Antral atretic follicle; (b) oocyte surrounded by the cumulus oophorus cells; (c) granulosa layer; A: Antrum; Co: Cumulus oophorus; G: Granulosa; O: Oocyte, T: Theca

authors suggest that the half-life of active caspase-3 may be shorter to be detected, or that the atresia of small follicles was very rapid [25]. According to Berardinelli et al. [10], we hypothesize that apoptosis was a phenomenon taking place in time; the early expression of active caspase-3 in these follicles, primarily, recruits multiple molecular signaling inducing morphological modifications at the cellular and the follicular scales. Moreover, atresia of the antral follicle was a gonadotropin dependent process related to the sex steroid hormones. Particularly, the androgens were atretogenic to ovarian follicles and caused an elevation in morphological signs of atresia by increasing number of pycnotic granulosa cells [38]. The folliculogenesis study in the Bedouin goat during non-breeding season showed an intense immunolabeling to androgen receptors in the granulosa cells of atretic antral follicles [39]. Our study revealed that atresia process occurs principally in the antral stage; this result is in agreement with those reported in mice [40].

In conclusion, in Bedouin goat, morphological changes reach atretic follicles by apoptosis via caspase-3 signaling pathway in breeding and non-breeding seasons with a high proportion in antral stage.

ACKNOWLEDGEMENTS

We thank Dr. Djallel Eddine GHRISSI and Mr. Abdelmadjid SALHI (Veterinary doctors) for their helpful in tissue sampling, Farid CHENAF, Radia HAMMI and Reda SIDI ALI for their assistance in this work at the faculty of biological sciences.

REFERENCES

- Silanikove N:** The physiological basis of adaptation in goats to harsh environments. *Small Ruminant Res*, 35 (3): 181-193, 2000. DOI: 10.1016/S0921-4488(99)00096-6
- Charallah S, Amirat Z, Sulon J, Khammar F, Beckers JF:** Pregnancy-associated glycoprotein and progesterone concentrations during pregnancy failure in Bedouin goat from the southwest of Algeria. *Reprod Domest Anim*, 45 (6): e231-e238, 2010. DOI: 10.1111/j.1439-0531.2009.01511.x
- Malek M, Amirat Z, Khammar F, Khaldoun M:** Analysis of the energetic metabolism in cyclic Bedouin goats (*Capra hircus*): Nychthemeral and seasonal variations of some haematochemical parameters in relation with body and ambient temperatures. *J Therm Biol*, 60, 86-94, 2016. DOI: 10.1016/j.jtherbio.2016.06.005
- Chergui N, Mormede P, Foury A, Khammar F, Amirat Z:** Seasonal effects on plasma cortisol concentrations in the Bedouin buck: Circadian studies and response to ACTH. *Animal*, 11 (3): 445-451, 2017. DOI: 10.1017/S1751731116001671
- Haque Z, Haque A, Quasem MA:** Morphologic and morphometric analysis of the ovary of Black Bengal goat (*Capra hircus*). *Int J Morphol*, 34 (1): 13-16, 2016. DOI: 10.4067/S0717-95022016000100002
- Wang W, Liu HL, Tian W, Zhang FF, Gong Y, Chen JW, Mao DG, Shi FX:** Morphologic observation and classification criteria of atretic follicles in guinea pigs. *J Zhejiang Univ Sci B*, 11 (5): 307-314, 2010. DOI: 10.1631/jzus.B0900391
- Manabe N, Goto Y, Matsuda-Minihata F, Inoue N, Maeda A, Sakamaki K, Miyano T:** Regulation mechanism of selective atresia in Porcine follicles: Regulation of granulosa cell apoptosis during atresia. *J Reprod Develop*, 50 (5): 493-514, 2004. DOI: 10.1262/jrd.50.493
- Zhang J, Liu Y, Yao W, Li Q, Liu HL, Pan Z:** Initiation of follicular atresia: gene networks during early atresia in pig ovaries. *Reproduction*, 156 (1): 23-33, 2018. DOI: 10.1530/REP-18-0058
- Shi Y:** Caspase activation, inhibition, and reactivation: A mechanistic view. *Protein Sci*, 13 (8): 1979-1987, 2004. DOI: 10.1110/ps.04789804
- Berardinelli P, Russo V, Martelli A, Nardinocchi D, Giacinto OD, Barboni B, Mattioli M:** Colocalization of DNA fragmentation and caspase-3 activation during atresia in pig antral follicles. *Anat Histol Embryol*, 33, 23-27, 2004. DOI: 10.1111/j.1439-0264.2004.00504.x
- Boatright KM, Salvesen GS:** Mechanisms of caspase activation. *Curr Opin Cell Biol*, 15 (6): 725-731, 2003. DOI: 10.1016/j.ceb.2003.10.009
- Gown AM, Willingham MC:** Improved detection of apoptotic cells in archival paraffin sections: Immunohistochemistry using antibodies to cleaved caspase 3. *J Histochem Cytochem*, 50 (4): 449-454, 2002. DOI:

10.1177/002215540205000401

13. Escobar ML, Echeverria OM, Vazquez-Nin GH: Role of autophagy in the ovary cell death in mammals. In, *Autophagy- A double-edged sword - cell survival or death?* *InTech*, 423-441, 2013.

14. Yang Z, Klionsky DJ: An overview of the molecular mechanism of autophagy. *Curr Top Microbiol Immunol*, 335, 1-32, 2009. DOI: 10.1007/978-3-642-00302-8_1

15. Xu J, Wang Y, Tan X, Jing H: MicroRNAs in autophagy and their emerging roles in crosstalk with apoptosis. *Autophagy*, 8 (6): 873-882, 2012. DOI: 10.4161/auto.19629

16. Rodgers RJ, Irving-Rodgers HF: Morphological classification of bovine ovarian follicles. *Reproduction*, 139 (2): 309-318, 2010. DOI: 10.1530/REP-09-0177

17. Tizhe MA, Kubkomawa HI, Butswat IRS, Addass PA, Kwaji DT: Characterization of reproductive organs of female goats in Guinea Savannah Zone of North-Eastern Nigeria. *Sky J Agric Res*, 4 (3): 47-59, 2015.

18. Bari MA, Kabir ME, Sarker MB, Khan AHNA, Moniruzzaman M: Morphometric analysis of ovarian follicles of Black Bengal goats during winter and summer season. *Bang J Anim Sci*, 39 (1-2): 51-55, 2011. DOI: 10.3329/bjas.v40i1-2.10791

19. Ramsingh L, Sadasivarao K, Muralimohan K: Ovarian biometrics and oocyte grading percentage of yield in local goats of Andhra Pradesh. *Iosr J Pharm*, 3 (1): 47-49, 2013. DOI: 10.9790/3013-31304749

20. Islam MR, Khandoker MAMY, Afroz S, Rahman MGM, Khan RI: Qualitative and quantitative analysis of goat ovaries, follicles and oocytes in view of *in vitro* production of embryos. *J Zhejiang Univ Sci B*, 8 (7): 465-469, 2007. DOI: 10.1631/jzus.2007.B0465

21. Logothetopoulos J, Dorrington J, Bailey D, Stratis M: Dynamics of follicular growth and atresia of large follicles during the ovarian cycle of the guinea pig: Fate of the degenerating follicles, a quantitative study. *Anat Rec*, 243 (1): 37-48, 1995. DOI: 10.1002/ar.1092430106

22. Boone DL, Tsang BK: Caspase-3 in the Rat ovary: Localization and possible role in follicular atresia and luteal regression. *Biol Reprod*, 58, 1533-1539, 1998.

23. Sugimoto M, Manabe N, Kimura Y, Myoumoto A, Imai Y, Ohno H, Miyamoto H: Ultrastructural changes in granulosa cells in Porcine antral follicles undergoing atresia indicate apoptotic cell death. *J Reprod Develop*, 44 (1): 7-14, 1998. DOI: 10.1262/jrd.44.7

24. Matikainen T, Perez GI, Zheng TS, Kluzak TR, Rueda BR, Flavell RA, Tilly JL: Caspase-3 gene knockout defines cell lineage specificity for programmed cell death signaling in the ovary. *Endocrinology*, 142 (6): 2468-2480, 2001. DOI: 10.1210/endo.142.6.8078

25. Fenwick MA, Hurst PR: Immunohistochemical localization of active caspase-3 in the mouse ovary: Growth and atresia of small follicles. *Reproduction*, 124, 659-665, 2002. DOI: 10.1530/rep.0.1240659

26. Vlckova R, Sopkova D, Posivak J, Valocky I: Ovarian follicular atresia of ewes during spring puerperium. *Vet Med Int*, 2012:638928, 2012. DOI:

10.1155/2012/638928

27. Lin P, Yang Y, Li X, Chen F, Cui C, Hu L, Li Q, Liu W, Jin Y: Endoplasmic reticulum stress is involved in granulosa cell apoptosis during follicular atresia in goat ovaries. *Mol Reprod Dev*, 79 (6): 423-432, 2012. DOI: 10.1002/mrd.22045

28. Sharma RK, Bhardwaj JK: Ultrastructural characterization of apoptotic granulosa cells in caprine ovary. *J Microsc*, 236 (3): 236-242, 2009. DOI: 10.1111/j.1365-2818.2009.03281.x

29. Hay MF, Cran DG, Moor RM: Structural changes occurring during atresia in sheep ovarian follicles. *Cell Tissue Res*, 169, 515-529, 1976. DOI: 10.1007/BF00218150

30. Fuku E, Xia L, Downey BR: Ultrastructural changes in bovine oocytes cryopreserved by vitrification. *Cryobiology*, 32 (2): 139-156, 1995. DOI: 10.1006/cryo.1995.1013

31. Kerr JFR, Wyllie AH, Currie AR: Apoptosis: A basic biological phenomenon with wide-ranging implications in tissue kinetics. *Br J Cancer*, 26, 239-257, 1972.

32. Silva JRV, Ferreira MAL, Costa SHF, Santos RR, Carvalho FCA, Rodrigues APR, Lucci CM, Bao SN, Figueiredo JR: Degeneration rate of preantral follicles in the ovaries of goats. *Small Ruminant Res*, 43 (3): 203-209, 2002. DOI: 10.1016/s0921-4488(02)00017-2

33. Yoshinaga-Hirabayashi T, Osawa Y: Steroidogenic activity of atretic follicles in the cycling hamster ovary and relation to ultrastructural observations. *Histochemistry*, 102 (1): 59-67, 1994. DOI: 10.1007/BF00271050

34. Wu X, Chen L, Brown CA, Yan C, Matzuk MM: Interrelationship of growth differentiation factor 9 and inhibin in early folliculogenesis and ovarian tumorigenesis in mice. *Mol Endocrinol*, 18 (6): 1509-1519, 2004. DOI: 10.1210/me.2003-0399

35. O'Shea JD, Hay MF, Cran DG: Ultrastructural changes in the theca interna during follicular atresia in sheep. *J Reprod Fert*, 54, 183-187, 1978.

36. Hussein MR: Apoptosis in the ovary: Molecular mechanisms. *Hum Reprod Update*, 11 (2): 162-178, 2005. DOI: 10.1093/humupd/dmi001

37. Hughes FM, Gorospe WC: Biochemical identification of apoptosis (programmed cell death) in granulosa cells: Evidence for a potential mechanism underlying follicular atresia. *Endocrinology*, 129 (5): 2415-2422, 1991. DOI: 10.1210/endo-129-5-2415

38. Billig H, Furuta I, Hsueh AJW: Estrogens inhibit and androgens enhance ovarian granulosa cell apoptosis. *Endocrinology*, 133 (5): 2204-2212, 1993. DOI: 10.1210/endo.133.5.8404672

39. Kassouri S, Boukenaoui N, Charallah S, Amirat Z, Khammar F: Immunolocalization of androgen receptor in the ovary of the Bedouin goat (*Capra hircus*) in non-breeding season. In, Farooq SA, Abed R, Baqir S (Eds): *Biotechnology and Conservation of Species from Arid Regions*. Nova Science Publishers, New York, USA, 2014.

40. Uslu B, Dioguardi CC, Haynes M, Miao DQ, Kurus M, Hoffman G, Johnson J: Quantifying growing versus non-growing ovarian follicles in the mouse. *J Ovarian Res*, 10:3, 2017. DOI: 10.1186/s13048-016-0296-x