

***Moraxella ovis* and *Mycoplasma conjunctivae* Isolation from an Ovine Infectious Keratoconjunctivitis Outbreak and Fortified Treatment Approaches**

Aliye GÜLMEZ SAĞLAM ^{1,a} Ekin Emre ERKİLİÇ ² Fatih BÜYÜK ¹ Ali Haydar KIRMIZIGÜL ² Gürbüz GÖKÇE ² Lokman BALYEN ³ Enes AKYÜZ ² Uğur AYDIN ⁴ Burhan ÖZBA ⁴ Salih OTLU ¹

¹ Department of Microbiology, Faculty of Veterinary Medicine, University of Kafkas, TR-36100 Kars - TURKEY

² Department of Internal Medicine, Faculty of Veterinary Medicine, University of Kafkas, TR-36100 Kars - TURKEY

³ Department of Ophthalmology, Faculty of Medicine, University of Kafkas, TR-36100 Kars - TURKEY

⁴ Department of Surgery, Faculty of Veterinary Medicine, University of Kafkas, TR-36100 Kars - TURKEY

^a ORCID: 0000-0002-7639-5075; ^b ORCID: 0000-0003-2461-5598; ^c ORCID: 0000-0003-3278-4834

Article Code: KVFD-2018-19572 Received: 14.02.2018 Accepted: 03.06.2018 Published Online: 03.06.2018

How to Cite This Article

Gülmez Sağlam A, Erkiliç EE, Büyük F, Kirmizigül AH, Gökçe G, Balyen L, Akyüz E, Aydın U, Özba B, Otlı S: *Moraxella ovis* and *Mycoplasma conjunctivae* isolation from an ovine infectious keratoconjunctivitis outbreak and fortified treatment approaches. *Kafkas Univ Vet Fak Derg*, 24 (4): 551-556, 2018. DOI: 10.9775/kvfd.2018.19572

Abstract

The aim of this study was to determine the etiology of naturally occurring infectious keratoconjunctivitis (IKC) outbreak observed in a Tuj sheep herd rearing semi-intensively and to try fortified treatment options in symptomatic sheep. Conjunctival samples from 42 sheep with keratoconjunctivitis were collected aseptically using sterile cotton swabs. All swab were cultivated for bacterial isolation. To test treatment options symptomatic animals were randomly divided into 3 groups each were composed of adult ewes. The first group (n=13) was treated with the subconjunctival administration of penicillin G potassium (250.000 IU/animal), the second group (n=14) was treated with oxytetracycline and polymyxin B sulfate, and the third group (n=15) was treated with amikacin sulfate (diluted with isotonic NaCl to 25 mg per mL), ceftriaxone disodium and fluconazole (2 mg/mL) combination. As the results of the bacteriological examination, 36 (85.71%) of 42 conjunctival samples were found positive for *Moraxella ovis*. Also, *Mycoplasma conjunctivae* was identified in 3 (7.14%) conjunctival samples positive for *M. ovis*. After treatment, 84.61% (11/13) of the first group; 71.42% (10/14) of the second group and all animals in the third group were observed to be healed. This study demonstrated that *M. ovis* was the primary pathogen causing IKC in Tuj sheep and *M. conjunctivae* was the second rank. The combination of amikacin sulfate, ceftriaxone disodium and fluconazole have been identified as the most effective treatment option of IKC in sheep.

Keywords: Keratoconjunctivitis, Sheep, *Moraxella ovis*, *Mycoplasma conjunctivae*

Bir İnfeksiyöz Koyun Keratokonjonktivit Salgınından *Moraxella ovis* ve *Mycoplasma conjunctivae* İzolasyonu ve Güçlendirilmiş Tedavi Yaklaşımı

Öz

Bu çalışmada, semi-entansif olarak yetiştirilen bir Tuj koyun sürüsünde doğal olarak gözlenen bir infeksiyöz keratokonjonktivit (IKC) salgınının etyolojisinin belirlenmesi ve semptom gösteren koyunlarda kuvvetlendirilmiş tedavi seçeneklerinin denenmesi amaçlanmıştır. Klinik keratokonjonktivit belirtisi olan 42 koyunun konjunktival örnekleri, steril sıvap kullanılarak aseptik koşullarda toplandı. Tüm örnekler bakteri izolasyonu için kültüre edildi. Tedavi seçeneklerini test etmek için ergin koyunlardan oluşan semptomatik hayvanlar rastgele 3 gruba ayrıldı. Birinci grupta (n=13) penisilin G potasyum'un (250.000 IU/hayvan) subkonjunktival uygulanarak, ikinci grupta (n=14) oksitetrasiklin ve polimiksin B sülfat'ın gözkapığı içine mercimek tanesi büyüklüğünde konularak ve üçüncü grupta (n=15) ise amikasin sülfat, seftriakson disodyum (0.5 g) ve flukonazol (2 mg/mL) kombinasyonu damlatma şeklinde uygulanarak tedavi denemeleri yapıldı. Bakteriyolojik muayene sonucunda, 42 konjunktival sıvap örneğinin 36'sında (%85.71) *Moraxella ovis* ve bu pozitif örneklerin 3'ünde (%7.14) *Mycoplasma conjunctivae* izole edildi. Tedavi sonrası, birinci grubun %84.61'si (11/13); ikinci grubun %71.42'si (10/14) ve üçüncü grubun ise tümünde iyileşme görüldü. Bu çalışma, *M. ovis*'in Tuj koyunlarında IKC'ye neden olan primer patojen, *M. conjunctivae*'nin ise sekonder etken olduğunu göstermiştir. Amikasin sülfat, seftriakson disodyum ve flukonazol kombinasyonu, koyunlarda IKC'nin en etkili tedavi seçeneği olarak tanımlanmıştır.

Anahtar sözcükler: Keratokonjonktivit, Koyun, *Moraxella ovis*, *Mycoplasma conjunctivae*



İletişim (Correspondence)



+90 474 2426836



alis_6223@hotmail.com

INTRODUCTION

Infectious keratoconjunctivitis (IKC), also known as pink eye disease of cattle, sheep and goats, is characterized by blepharospasm, conjunctivitis, lacrimation, and varying degrees of corneal opacity and ulceration [1]. In sheep and goats, naturally occurring conjunctivitis or keratoconjunctivitis can be associated with *Chlamydia pecorum*, *Chlamydophila psittaci*, *Mycoplasma* spp. (notably *Mycoplasma conjunctivae*), *Moraxella ovis*, *Coleiata conjunctivae*, *Listeria monocytogenes*, *Acholeplasma oculi*, *Staphylococcus aureus*, *Corynebacterium* spp., *Escherichia coli* and *Thelazia* spp. [2,3]. *M. ovis* has been implicated in epizootics of IKC in domestic sheep and goats [4]. Dagnall [5] reported that *M. ovis* could be isolated from both healthy sheep and those with IKC, but isolation occurred at a higher rate in sick animals. *M. conjunctivae* has been associated with most of the IKC outbreaks in small domestic ruminants [4] and wild caprinae worldwide [6] and is considered the primary pathogen of this infection. However, *M. conjunctivae* is commonly detected in the eyes of asymptomatic sheep and is eventually endemic in sheep herds throughout Europe [4]. IKC is a highly contagious disease and it is influenced by host and environmental factors. Predisposing factors such as age, breed, immune response and eye pigmentation, season (fly season), mechanical irritation (dust, grass, weeds, etc.), and concurrent presence of the disease-involved pathogenic bacteria in the environment influences the prevalence of this disease [7]. There is usually no mortality reported associated with IKC however, the morbidity rate can reach as high as 80% [1]. Loss of productions are compounded by the cost of keratoconjunctivitis for producers in terms of incurring additional labour and treatment costs [8]. If the control and treat of the disease are not taken, it may spread in the flock and blindness may result and blind animals on range may subsequently die [9].

The effective antibiotic selection is important for the treatment of keratoconjunctivitis cases in animals. The fortified antibiotic treatments are reported to be extremely effective and reliable in the treatment of acute bacterial keratitis in human medicine [10-12]. Fortified preparations of ophthalmic antibiotics are made from antibiotics found in the market. These fortified eye drops have two main advantages, which are an increase in antibiotic concentration in the corneal stroma and a wide range option of availability. Given the potential for synergistic effects on corneal penetration, strong antibiotic combinations continue to be used in treatment for severe bacterial keratitis [13]. Fluconazole is a drug that is soluble in water and is suitable for topical application of epithelial defect. This drug with corneal penetration is effective against *Candida* sp. and *Aspergillus* sp in both human and animals [14-17]. Polymyxins have similar effect on fungi and can also be used against bacterial keratitis [18]. The combination of cephalosporins (ceftriaxone, cephazol, ceftazidime-50

mg/mL) and aminoglycosides (tobramycin, gentamycin or amikacin) gives good results when used topically against polybacterial keratitis [19]. Penicillin and tetracycline susceptibility was reported to control *M. ovis* infection, especially to avoid exacerbation of lesions primarily caused by *M. conjunctivae* [20]. Additionally, animals with *M. conjunctivae* require antibiotic combination of oxytetracycline and polymyxin B, but not to penicillin [21].

In this study, it was aimed to determine the etiology of naturally occurring infectious keratoconjunctivitis and to try different treatment approaches in a Tuj sheep herd semi-intensively farming in Veterinary Faculty Farm of the Kafkas University in Kars, Turkey.

MATERIAL and METHODS

Ethical Approval

The experiment was carried out with the approval of Kafkas University Local Ethical Committee for Animal Experiments (KAÜ-HADYEK/2018-016).

Case Definition

The study was carried out on a naturally occurring infectious keratoconjunctivitis outbreak observed in a Tuj sheep herd rearing semi-intensively in the farm of the Faculty of Veterinary Medicine, Kafkas University, in July 2017. Out of 150 animals, 42 (28%) adult (>3 years) sheep were affected by the disease and thus subjected to the study. While all affected sheep had clinical complaints such as lacrimation and conjunctivitis, some had ulceration and corneal opacity in generally one eye in addition. But no subclassification was carried out on the severity of clinical presentation of animals. The fluorescent staining test was used in the detection of corneal ulcer together with clinical examination, and defects were controlled under the daylight.

Sampling

The conjunctival samples of each of 42 sheep with clinical complaints were collected aseptically using two sterile cotton swabs, and the samples was transferred within 1 h for process at the Microbiology Laboratory of Veterinary Faculty, Kafkas University, Turkey.

Bacterial Isolation

For the pre-enrichment progress of *Mycoplasma* sp., one of conjunctival swab samples was transferred in a 3 mL *Mycoplasma* broth (Oxoid, England) enriched with 10% fresh yeast extract (Oxoid, England), 20% heat-inactivated horse serum (Sigma, USA), 0.025% thallium acetate (Fluka, Belgium), and 100 IU of penicillin G (IE, Istanbul) and incubated at 37°C in a humidified atmosphere with 5% CO₂ for 3 days. One hundred µL of pre-enriched content was then sub-cultured on *Mycoplasma* agar plates (Oxoid,

England) enriched with 10% fresh yeast extract, 20% heat-inactivated horse serum, 0.025% thallium acetate, and 100 U of penicillin G, and incubated again at 37°C with 5% CO₂ in a moist environment. These agar plates were incubated for up to 21 days and monitored every second day for signs of *Mycoplasma* growth [22]. The second samples were also inoculated on 7% sheep blood agar (Oxoid, England) plates and MacConkey agar (Oxoid, England) plates in order to determine the presence of other bacterial agents and incubated at 37°C, aerobically for two days. Identification of *Mycoplasma* isolates were carried out by conventional bacteriological methods such as catabolism of glucose, hydrolysis of arginine, phosphatase activity, tetrazolium reduction, serum digestion, digitonin sensitivity, film and spot formation [23]. The other causative agents were identified by using tests as catalase, oxidase, indole, methyl red, voges proskauer, citrate, nitrate reduction which were carried out as described earlier [24].

Clinical Trials

Affected animals were randomly distributed into three treatment groups. The subconjunctival penicillin G potassium (Ibrahim Ethem®) was administered three times (every other day) at the daily dose of 250.000 IU/animal to animals in the first group (n=13). The ocular ointment (Terramycin, Pfizer®) containing oxytetracycline and polymyxin B sulfate were applied to the animals in the second group (n=14) once per day in the lentil size area on the inside of the eyelid and treatment was continued for 1 week. Amikacin sulphate (Amikosit, Zentiva®) (diluted with isotonic NaCl to

25 mg per mL), ceftriaxone sodium (Unacefin 0.5 g, Avis®) and fluconazole (2 mg/mL) (Triflukan, Pfizer®) [19,25-27], for fungal infection probability was administered in combination with 2 drops three times per day for 1 weeks to animals in third group.

RESULTS

Culture Results

As the results of bacteriological examination, *M. ovis* was isolated and identified in 36 (85.71%) of 42 conjunctival samples. In addition, *M. conjunctivae* was identified in 3 (7.14%) conjunctival samples of ewe together with *M. ovis*. Six conjunctival swab samples were found bacterial culture negative. The other bacteria could not isolate from samples. All the treatment groups were included two culture negative animals, as well. The results of the cultivated samples and fortified treatment options were showed in Table 1.

Clinical Trial Results

The treatment groups were randomly adjusted as three groups. All the groups were included animals suffered from *M. ovis* and *M. conjunctivae*, except the first group which is infected only with *M. ovis*. After treatment, it was detected that 84.61% (11/13) of the animals in first group; 71.42% (10/14) of the animals in the second group and 100% (15/15) of the animals in the third group were observed to be healed (Fig. 1).

Table 1. The summary of the cultivated samples and fortified treatment options

Total Number of Samples	Culture Results	Treatment Options (Healing Rate)			
	Positive	Groups	Penicillin G	Oxytetracycline/ Polymyxin B	Amikacin/Ceftriaxone/ Fluconazole
42	36 (36 <i>M. ovis</i> and 2 <i>M. conjunctivae</i>)	1 st group n: 13	11/13 (84.61%)	NA	NA
		2 nd group n: 14	NA	10/14 (71.42%)	NA
		3 rd group n: 15	NA	NA	15/15 (100%)

NA: Not applied

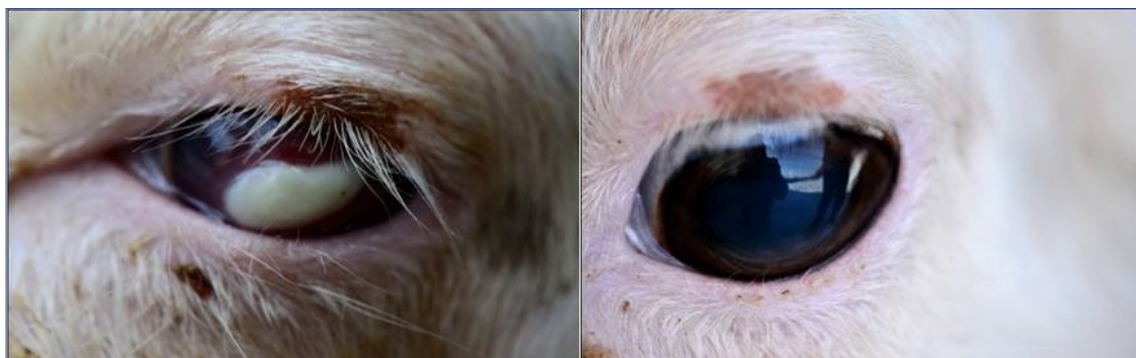


Fig 1. While affected sheeps were exhibited corneal opacity, remarkable healing was observed after treatment

DISCUSSION

The etiology of infectious keratoconjunctivitis involves many predisposing factors such as age, race, daylight, dust irritations which facilitate the colonization of the pond are important in the formation of the disease [27]. Bacteria such as *C. pecorum*, *Mycoplasma* spp. (notably *M. conjunctivae*), *Moraxella* spp., *C. conjunctivae*, *L. monocytogenes*, *A. oculi* are often blamed as causative agents of IKC in animals [2]. *Moraxella bovis* is reported to be the most common agent of infectious bovine keratoconjunctivitis in the world [8,20]. In contrast, the main microorganisms isolated from IKC of sheep lesions are *M. conjunctivae*, *C. psittaci* and *M. ovis* [5,28]. Karthik et al. [29] reported 2 *Moraxella* spp. were isolated from the eye swabs of 5 animals with keratoconjunctivitis in a sheep herd consist of 100 animals in India. Also, they found to be 99% compatible with *M. bovis* by PCR-based sequence analysis. The researchers showed that the isolates were susceptible to all antimicrobials as gamyoxyclav, enrofloxacin, ciprofloxacin, cefixime, gentamicin, tetracycline and norfloxacin. Åkerstedt and Hofshagen [3], conducted a study on Norwegian Sheep in which they took conjunctival swab from 43 sick and 42 healthy animals in 15 farms with ovine keratoconjunctivitis and 50 conjunctival swabs from sheep in 17 farms without disease and cultivated for the presence of *Mycoplasma* and other bacterial species. They reported that *M. (Branhamella) ovis* was isolated in 28% of the samples taken from the affected herds and 10% of the samples from healthy animals. In addition, *M. conjunctivae* was isolated in 16 (37%) animals with keratoconjunctivitis and 3 (7%) non-clinical animals from the farms where keratoconjunctivitis was observed, whereas *M. conjunctivae* was isolated in only 4 (8%) samples from farms without evidence of keratoconjunctivitis. *L. monocytogenes* (1%), *S. aureus* (5%), *Corynebacterium* spp. (2%) and *E. coli* (4%) were isolated in herd. The researchers has reported that it is the first time that *M. conjunctivae* was isolated from a conjunctivitis case in Norway and the other predisposing agents can be isolated such as *M. (Branhamella) ovis* and *L. monocytogenes*. They claimed that different agents may play a role in the formation of keratoconjunctivitis in the sheep, and that some are seconder invaders.

Shahzad et al. [30] have reported an IKC infection in a few Lohi lambs showing clinical symptoms as conjunctivitis, keratitis, severe lacrimation and varying degree of blindness in Livestock Experiment Station (LES), Bahadurnagar, Okara, Pakistan. Thirty six conjunctival swabs sampled from the animals were evaluated by cultural and molecular methods. Sixteen (44.44%) out of 36 samples showed turbidity in PPLO broth. Twelve (75%) out of 16 broth samples showed colony growth on PPLO agar and this isolates identified as *M. conjunctivae*. Twenty one (59%) out of 36 conjunctival direct swab samples were found positive for *M. conjunctivae* by polymerase chain reaction (PCR). Topical application of 0.5% sterile solution

of gentamycin (100 mg/mL) (Gentafar 10%, FARVET, Netherlands) proved suitable for the treatment of IKC in Lohi lambs as all clinical signs of IKC disappeared after 5 days of treatment with this antibiotic. Taghavi Razavizadeh and Razmyar [31] have reported an IKC infection in sheep herds consisting of 300 ewes with ocular lesions in Mashhad, Iran. About 10% of the flock was affected by the disease and 6 animals with severe clinical symptoms were sampled for cultural process. Following inoculation of the ocular swab samples in PPLO broth and agar, turbidity and growth of colonies were observed in them, respectively. The causative agent of the outbreak has identified to be *M. conjunctivae*. This was also the first documented report of isolation and molecular characterization of *M. conjunctivae* in Iran. The affected sheep were succesfully treated with oxytetracycline 20%, IM (20 mg/kg) twice, with interval of 72 h, and flunixin meglumin, IM (2.2 mg/kg) three times, with interval of 24 h. In addition to the listed drugs, tylosin 20%, IM (17 mg/kg), was administrated three times for sheep with pulmonary involvement. Motha et al. [32] have performed direct PCR for examination of *M. conjunctivae* in samples taken form 5 sheep herds with infectious keratoconjunctivitis. In addition, the researchers have run ELISA for screening antibody produced against *M. agalactiae* and *M. conjunctivae* and CFT for antibody of *M. capricolum*, and *Chlamydophila* spp. *M. conjunctivae* was detected specifically from conjunctival swab samples from 3 herds. Antibodies only against to *M. conjunctivae* antibodies were also detected in blood sera of animals (60/75) from all farms. *M. (Branhemella) ovis* was isolated from the remaining 2 herds. The researchers have reported that *M. conjunctivae* is the primary pathogen of IKC in sheep and that this is the first time that the agent has been reported in New Zealand. Fernandez-Aguilar et al. [4] have reported a study of IKC on sheep and goat population in Pakistan with quantitative PCR (qPCR) to investigate the presence of *M. conjunctivae* and *Chlamydiaceae*. The infection rate for *M. conjunctivae* has been reported as 19.3% for sheep and 9.5% for goat. In India, Vaid et al. [33] reported an outbreak of IKC in nomadic sheep herds and 3 *M. ovis* were isolated out of 6 cases of IKC in sheep.

In Turkey, Erdeğer et al. [34] repoted that *M. bovis* was isolated from 41 (19.7%) of 208 conjunctival swab that were obtained from 168 cattle with IBK suspects. Samsar et al. [35] reported that *M. bovis* was isolated from the all of 51 (100%) symptomatic cattle with IBK. *M. bovis* was isolated from 26 (17.9%) of 145 cattle with IBK suspected cattle in Erzurum and central villages [36].

In this study, conjunctival swab samples from 42 (28%) animals with an epidemic keratoconjunctivitis in Tuj sheep herd were collected and cultured for bacteriological examination. *M. ovis* was isolated from 36 (85.71%) of the samples, while *M. conjunctivae* (with *M. ovis*) was detected from 3 (7.14%). In this study, *M. ovis* was isolated from IKC infection similar to the results obtained in other

studies [3,32,33] and identified as the primary agent of the cases. The bacteria such as *L. monocytogenes*, *E. coli*, *Corynebacterium* spp. have been reported previously [2,3] from IKC in sheep but they did not isolated from the samples in this study except the bacteria *M. ovis* and *M. conjunctivae*. The researches have predominately shown the presence of *M. conjunctivae* as causative agent of IKC in sheep [30-32]. But in this study a substantial amount of *M. ovis* has been reported and this could indicate an outbreak of IKC caused by a monopolise agent, *M. ovis*. This study has also an importance as being the first ovine infectious keratoconjunctivitis epidemic caused by *M. ovis* in Turkey. It was believed this epidemic has developed and evolved due to the fact that the sheep have been exposed to more dust irritations during the grazing season at poor pastures resulting from the last years drought and that some environmental inducers such as the failure of the herd management, farm conditions and insect control. It was reported that these factors were effective in the emergence of the infection [7,31]. In addition, considering the variety of agents isolated from cases of infectious keratoconjunctivitis, this shows that not only the eyes of the animals can be exposed to many obligate pathogens by grazing, feeding or insect exposure periods, but also the involvement of the opportunistic pathogens present in the eye flora with the acceleration of the predisposing factors.

Fortified therapy in the case of bacterial keratitis in human medicine is widely used with different antimicrobial combinations [11,13]. Fortified drugs are made from antibiotics (parenteral or lyophilized preparations) on the market. The first advantage of these drugs is the increased antibiotic concentration in the corneal stroma when applied and the second advantage is being a wide selection chance [13]. Given the potential for synergistic and combined effects of corneal penetration and antibiotic association, fortified antibiotic drops for severe keratitis remain standard therapy [13]. Animal studies with fortified applicaitons especially in ocular infections are widely reported in cattle [37-39] but ovine cases are quite rare [32,40]. Kibar et al.[38] have reported mean time for healing of corneal ulcers and amelioration of clinical signs was significantly less for calves that received enrofloxacin or penicillin + streptomycin than for the untreated controls. Gokce et al.[37] reported that 30 *M. bovis* isolates were obtained from IBK outbreaks of calves and found that animals treated with florfenicol recovered more rapidly than the animals treated with oxytetracycline. However, studies addressing the effectiveness of clinical application of antimicrobials on animals infected with *Moraxella* spp. and *Mycoplasma* spp. are scarce in the literatures [28,41]. Most of antimicrobials are limited with *in vitro* susceptibility of isolated microorganisms and are lack of the clinical applications on existing cases. Nevertheless, susceptibility profile were individually reported both *Moraxella* spp. and *Mycoplasma* spp., as *Moraxella* species show susceptibility

to ampicillin, ceftiofur, enrofloxacin, florfenicol and gentamicin [20,42] and *Mycoplasma* species to tetracyclines, kanamycin, danofloxacin, tylosin and linco-spectin [39].

As the results of the treatment options in this study, it was found that the healing rates were higher in the first and third group, in which penicillin G and amikacin/ceftriaxone/fluconazole combination were administered, respectively. When considering the cultivated agents (completely *M. ovis*, except 2 culture negative ewes) of the first group animals the penicillin effectiveness is expectable on *Moraxella* spp. However, the penicillin resistance is likely as reported before for *M. ovis* [20,28] and was encountered in the first group (11/13) of this study. Combined antibiotic therapy is widely practised in polyfactorial infectious disease and in that in order to limit the spread of antimicrobial resistance. The trilateral combination antimicrobials in the third group of this study yielded a maximum (15/15) healing of animals infected with *M. ovis* and *M. conjunctivae*. This can support a concomitant synergistic interaction between cephalosporins and aminoglycosides [43]. An anti-fungal (fluconazole) supplementation into the treatment may have contributed to the healing since the remaining two animals found as bacterial culture negative and a fungal infections are included in the probability. Oxytetracycline is usually the first choice for antimicrobial treatment of IKC [44]. Chapman et al.[40] has gained the greatest clinical improvement when sheep with clinical signs of IKC were treated with long-acting oxytetracycline with intramuscularly. In the present study, oxytetracycline and polymyxin B combination was administered in the second treatment group animals infected *M. ovis* and *M. conjunctivae* and 71.42% (10/14) of healing was obtained. Resistance of *Moraxella* spp. to oxytetracycline is scarcely reported [20], but the indiscriminate use of oxytetracycline (most typically is terramycin) in Kars province over the years can be related with the bacterial agent resistant to this drug. Furthermore, polymyxin B as a cationic decapeptide cell membrane destroyer of Gram-negative bacteria may be inadequate in treatment of Gram positive *M. ovis*.

As the result, determining the etiology of infectious keratoconjunctivitis in animals with appropriate microbiological methods and developing an ideal fortified treatment approach to implementation will reduce the size of estimated damages of disease and contribute to animal welfare.

REFERENCES

1. Radostits OM, Gay C, Hinchcliff KW, Constable PD: A textbook of the diseases of cattle, horses, sheep, pigs and goats. Veterinary Medicine. 10th ed., 1548-1551, London: Saunders, 2007.
2. Angelos JA: Overview of infectious keratoconjunctivitis. <https://www.msddvetmanual.com/eye-and-ear/infectious-keratoconjunctivitis/overview-of-infectious-keratoconjunctivitis>; Accessed: 25.10.2017.
3. Åkerstedt J, Hofshagen M: Bacteriological investigation of infectious keratoconjunctivitis in Norwegian Sheep. *Acta Vet Scand*, 45 (1): 19-26, 2004. DOI: 10.1186/1751-0147-45-19

- 4. Fernandez-Aguilar X, Rossi L, Cabezón O, Giorgino A, Llopis IV, Frey J, López-Olvera JR:** Infectious keratoconjunctivitis and occurrence of *Mycoplasma conjunctivae* and *Chlamydiaceae* in small domestic ruminants from Central Karakoram, Pakistan. *Vet Rec*, 181 (9): 1-7, 2017. DOI: 10.1136/vr.103948
- 5. Dagnall GJR:** The role of *Branhamella ovis*, *Mycoplasma conjunctivae* and *Chlamydia psittaci* in conjunctivitis of sheep. *Br Vet J*, 150 (1): 65-71, 1994. DOI: 10.1016/S0007-1935(05)80097-1
- 6. Giacometti M, Janovsky M, Belloy L, Frey J:** Infectious keratoconjunctivitis of ibex, chamois and other Caprinae. *Rev Sci Tech*, 21, 335-345, 2002.
- 7. Bath GF, Van Wyk JA, Pettey KP:** Control measures for some important and unusual goat diseases in southern Africa. *Small Rumin Res*, 60 (1-2): 127-140, 2005. DOI: 10.1016/j.smallrumres.2005.06.007
- 8. O'Connor AM, Shen HG, Wang C, Opriessnig T:** Descriptive epidemiology of *Moraxella bovis*, *Moraxella bovoculi* and *Moraxella ovis* in beef calves with naturally occurring infectious bovine keratoconjunctivitis (Pinkeye). *Vet Microbiol*, 155 (2-4): 374-380, 2012. DOI: 10.1016/j.vetmic.2011.09.011
- 9. Smith MC, Sherman DM:** Goat Medicine, 2nd ed., June 2009, Wiley-Blackwell, 2011.
- 10. Hyndiuk RA, Eiferman RA, Caldwell DR, Rosenwasser GO, Santos CI, Katz HR, Badrinath SS, Reddy MK, Adenis JP, Klaus V:** Comparison of ciprofloxacin ophthalmic solution 0.3% to fortified tobramycin cefazolin in treating bacterial corneal ulcers. *Ophthalmology*, 103 (11): 1854-1863, 1996. DOI: 10.1016/S0161-6420(96)30416-8
- 11. O'Brien TP, Maguire MG, Fink NE, Alfonso E, McDonnell P:** Efficacy of ofloxacin vs cefazolin and tobramycin in the therapy for bacterial keratitis. *Arch Ophthalmol*, 113 (10): 1257-1265, 1995. DOI: 10.1001/archoph.1995.01100100045026
- 12. Panda A, Ahuja R, Sastry SS:** Comparison of topical 0.3% ofloxacin with fortified tobramycin plus cefazolin in the treatment of bacterial keratitis. *Eye*, 13, 744-747, 1999. DOI: 10.1038/eye.1999.220
- 13. Chiquet C, Romanet JP:** Prescribing fortified eye drops. *J Fr Ophthalmo*, 30 (4): 423-430, 2007.
- 14. Behrens-Baumann W, Klinge B, Rühshel R:** Topical fluconazole for experimental *Candida* keratitis in rabbits. *Br J Ophthalmol*, 74, 40-42, 1990. DOI: 10.1136/bjo.74.1.40
- 15. Köse S, Pamukçu K, Akkın C, Yağcı A, Tümbay E:** Fungal keratitlerde sistemik flukonazol tedavisinin etkinliği. *T Oft Gaz*, 23, 380-3, 1993.
- 16. Savani DV, Perfect JR, Cobo LM, Durack DT:** Penetration of new azole compounds into the eye and efficacy in experimental *Candida* endophthalmitis. *Antimicrob Agents Chemother*, 31, 6-10, 1987. DOI: 10.1128/AAC.31.1.6
- 17. Tümbay E:** Sistemik etkili yeni bir antifungal kemoterapötik: Flukonazol. *Turk J Infect*, 3 (1): 1989.
- 18. Shiun XW, Lo XJ, Ogawa-Lin:** Effectiveness of povidone-iodine to treat infectious conjunctivitis in dogs. *RECVET*, 3 (1): 1-5, 2008.
- 19. O'Brien TP:** Management of bacterial keratitis: Beyond exorcism towards consideration of organism and host factors. *Eye*, 17 (8): 957-974, 2003. DOI: 10.1038/sj.eye.6700635
- 20. Maboni G, Gressler LT, Espindola JP, Schwab M, Tasca C, Potter L, Vargas AC:** Differences in the antimicrobial susceptibility profiles of *Moraxella bovis*, *M. bovoculi* and *M. ovis*. *Braz J Microbiol*, 46 (2): 545-549, 2015. DOI: 10.1590/S1517-838246220140058
- 21. Baas EJ, Trotter SL, Franklin RM, Barile MF:** Epidemic caprine keratoconjunctivitis: Recovery of *Mycoplasma conjunctivae* and its possible role in pathogenesis. *Infect Immun*, 18 (3): 806-815, 1977.
- 22. Gupta B:** *Mycoplasma capricolum*: Isolation and molecular diagnosis. MSc. Thesis submitted to the U. P. Pt. Deen Dayal Upadhyaya Pashu-chikitsa Vigyan Vishwavidyalaya Evam Go Anusandhan Sansthan, Mathura (U. P.). pp. 12-44, 2005.
- 23. Barile MF, Del Giudice RA, Tully JG:** Isolation and characterization of *Mycoplasma conjunctivae* sp. n. from sheep and goats with keratoconjunctivitis. *Infect Immun*, 5 (1): 70-76, 1972.
- 24. Quinn PJ, Markey BK, Carter ME, Donnelly WJ, Leonard FC:** Veterinary Microbiology and Microbial Disease. 536, Iowa State University Press, Ames, 2002.
- 25. Hu FR, Huang WJ, Huang SF:** Clinicopathologic study of satellite lesions in nontuberculous mycobacterial keratitis. *Jpn J Ophthalmol*, 42 (2): 115-118, 1998. DOI: 10.1016/S0021-5155(97)00117-2
- 26. Kalkan Akçay E, Açıkgöz ZC, Can ME, Çelikkbilek N, Dereli Can G, Çağıl N:** Fungal keratitis caused by *Seedosporium apiospermum*: First report from Turkey. *Mikrobiyol Bul*, 47 (4): 727-733, 2013. DOI: 10.5578/mb.5262
- 27. Scott PR:** Sheep Medicine. 265-270, London, UK, The Veterinary Press, Manson Publishing, 2007.
- 28. Elad D, Yeruham I, Bernstein M:** *Moraxella ovis* in cases of infectious bovine keratoconjunctivitis (IBK) in Israel. *Zentralbl Veterinarmed B*, 35, 431-434, 1988. DOI: 10.1111/j.1439-0450.1988.tb00516.x
- 29. Karthik K, Manimaran K, Mahaprabhu R, Shoba K:** Isolation of *Moraxella* sp. from cases of keratoconjunctivitis in an organized sheep farm of India. *Open J Vet Med*, 7, 138-143, 2017. DOI: 10.4236/ojvm.2017.710014
- 30. Shahzad W, Munir R, Rana MY, Ahmad R, Khan MS, Akbar G, Ijaz M, Mehmood F:** Prevalence, molecular diagnosis and treatment of *Mycoplasma conjunctivae* isolated from infectious keratoconjunctivitis affected Lohi sheep maintained at Livestock Experiment Station, Bahadurnagar, Okara, Pakistan. *Trop Anim Health Prod*, 45 (3): 737-742, 2013. DOI: 10.1007/s11250-012-0282-2
- 31. Taghavi Razavizadeh AR, Razmyar J:** Molecular diagnosis of *Mycoplasma conjunctivae* in an outbreak of infectious keratoconjunctivitis in sheep. *IJVR*, 15 (1): 72-74, 2014. DOI: 10.22099/IJVR.2014.1988
- 32. Motha MXJ, Frey J, Hansen MF, Jamaludin R, Tham KM:** Detection of *Mycoplasma conjunctivae* in sheep affected with conjunctivitis and infectious keratoconjunctivitis. *N Z Vet J*, 51 (4): 186-190, 2003. DOI: 10.1080/00480169.2003.36362
- 33. Vaid RK, Anand T, Bera BC, Shukla BN, Nagar DK, Singh G, Virmani N, Barua S, Singh K, Singh NK:** Isolation and molecular identification of *Moraxella ovis* and *Moraxella* spp. from Infectious Keratoconjunctivitis in sheep in India. *J Veterinar Sci Technol*, DOI: 10.4172/2157-7579.S1.006
- 34. Erdeğer J, Aydın N:** Sığırlarda izole edilen *Moraxella bovis* suşlarının çeşitli özelliklerinin araştırılması. *Turk J Vet Anim Sci*, 15, 140-147, 1991.
- 35. Samsar E, Akın F, Gökçe P, Bilir B:** Sığırların İnfeksiyöz Kerato-konjunktivitisinde subkonjunktival antibiyotik ve alfa-kimotripsin uygulamaları. *Ankara Üniv Vet Fak Derg*, 40 (4): 453-474, 1993.
- 36. Işık N:** Investigation on isolation and sensitivity of antibiotic on *Moraxella bovis* in cattle with infectious bovine keratoconjunctivitis. *Dicle Üniv Vet Fak Derg*, 1, 17-22, 2008.
- 37. Gökçe I, Çitil M, Genç O, Erdoğan HM, Güneş V, Kankavi O:** Comparison of the efficacy of florfenicol and oxytetracycline in the treatment of naturally occurring infectious bovine keratoconjunctivitis. *Ir Vet J*, 55 (11): 573-576, 2002.
- 38. Kibar M, Gümüşsoy KS, Öztürk A:** Evaluation of various antibiotic treatments in calves with infectious bovine keratoconjunctivitis. *Turk J Vet Anim Sci*, 30, 553-559, 2006.
- 39. Abdou NEMI, Abdou MY:** Bacterial conjunctivitis in cattle and antibiotic sensitivity of the isolates. *Res J Anim Vet Sci*, 5, 38-42, 2010.
- 40. Chapman HM, Murdoch FR, Robertson ID, Beatty DT:** Detection, identification and treatment of infectious ovine keratoconjunctivitis (Pink Eye) in sheep from a Western Australian pre-export feedlot. Meat & Livestock Australia, North Sydney, Australia, 2010.
- 41. Egwu GO:** *In vitro* antibiotic sensitivity of *Mycoplasma conjunctivae* and some bacterial species causing ovine infectious kerato-conjunctivitis. *Small Rumin Res*, 7, 85-92, 1992. DOI: 10.1016/0921-4488(92)90071-B
- 42. Loy JD, Brodersen BW:** *Moraxella* spp. isolated from field outbreaks of infectious bovine keratoconjunctivitis: A retrospective study of case submissions from 2010 to 2013. *J Vet Diagn Invest*, 26 (6): 761-768, 2014. DOI: 10.1177/1040638714551403
- 43. Rankin GO, Sutherland CH:** Nephrotoxicity of aminoglycosides and cephalosporins in combination. *Adverse Drug React Acute Poisoning Rev*, 8 (2): 73-88, 1989.
- 44. Alexander DE:** Infectious bovine keratoconjunctivitis: A review of cases in clinical practice. *Vet Clin North Am: Food Anim Pract*, 26, 487-503, 2010. DOI: 10.1016/j.cvfa.2010.09.006