

## Diagnostic Steps of a Cat with Patent Ductus Arteriosus (Patent Ductus Arteriosuslu Bir Kedide Diagnostik Basamaklar)

Meriç KOCATÜRK<sup>1,a</sup> Ahmet SARIL<sup>1</sup> Canan ALTINCI<sup>2</sup> Hakan SALCI<sup>2,b</sup> Zeki YILMAZ<sup>1,c</sup>

<sup>1</sup> Department of Internal Medicine, Faculty of Veterinary Medicine, Uludag University, TR-16059 Bursa - TURKEY

<sup>2</sup> Department of Surgery, Faculty of Veterinary Medicine, Uludag University, TR-16059 Bursa - TURKEY

<sup>a</sup> ORCID: 0000-0002-2849-1222; <sup>b</sup> ORCID: 0000-0001-9836-0749; <sup>c</sup> ORCID: 0000-0001-6548-8754

Article Code: KVFD-2018-20140 Published Online: 30.05.2018

### How to Cite This Article

Kocatürk M, Saril A, Altinci C, Salci H, Yilmaz Z: Diagnostic steps of a cat with patent ductus arteriosus. *Kafkas Univ Vet Fak Derg*, 24 (4): 631-632, 2018. DOI: 10.9775/kvfd.2018.20140

### Dear Editor,

Patent ductus arteriosus (PDA), a fetal blood vessel between pulmonary artery and aorta that has to be closed in hours right after birth triggered by first breath of life, may result life threatening heart failure or even sudden death depend on size of the ductus<sup>[1]</sup>. PDA has been reported as a most common congenital heart defect in dogs and cats, however there is limited information on diagnostic procedure of PDA by use of three-dimensional computed tomography angiography (3D-CTA) in cats<sup>[1,2]</sup>. Thus, we report here the use of 3D-CTA to confirm the clinical diagnosis of PDA in a kitten.

A British shorthair cat (3 months, female, and 1.3 kg) was presented to Animal Hospital (Dep. of Internal Medicine, Faculty of Veterinary Medicine, Uludag University, Bursa-Turkey) with a history of lethargy, poor growth, exercise intolerance, panting and fatigue for one month. The cat was standing with open mouth breathing in sternal position and tachypneic (76 breaths/min). Cardiac auscultation revealed a tachycardia (250 bpm) with a loud continuous cardiac murmur (grade 3/6). ECG examination was consistent with the left ventricular enlargement (increased R wave amplitude, 2.4 mV/DII) and a sinus tachycardia. Thoracic radiography showed a mild bronchial pattern, perihilar pulmonary oedema and cardiomegaly as well as pulmonary artery and aortic bulging. Serum cardiac troponin I (cTnI) was slightly higher (0.19 ng/mL) than cut-off value (<0.16 ng/mL). All other parameters including complete blood cell count and serum biochemistry profile (Comprehensive Profile, VetScan®, Abaxis, UK) were within reference ranges. Cat was clean for enteric parasites checked by an easy faecal smear examination, as well.

Based on these clinical observations, congenital cardiac

pathologies such as PDA were suspected. Echocardiographic examination was performed by standard techniques with a 7.5-10 MHz phased-array transducer in this cat without sedation (CarisPlus®, Esoate, Florence, Italy), as suggested<sup>[3]</sup>. Two-dimensional and M-mode echocardiography showed left atrial (2.03 cm, reference <1.0 cm) and ventricular enlargements (2.12 cm, reference <1.5 cm) with preserved fractional shortening (46%, reference 30-59%). Colour Doppler examination revealed severe turbulence in pulmonary artery trunk and its right and left branches (Fig. 1). A connection was observed by colour Doppler between main pulmonary artery and ascending aorta (Fig. 1), suggesting the presence of PDA. Peak systolic pulmonary artery flow velocity and pressure gradient were 1.24 m/s and 6.1 mmHg (reference <1.2 m/s and <10 mmHg, respectively), indicating left to right ductal shunt in this cat. Three-dimensional volume-rendered CT images (3D-CTA) were used to assess the malformations and to plan surgery for the treatment of the vascular anomalies. 3D-CTA was run with the contrast medium (Omnipaque™, 10 mL, iv) under general anaesthesia (1). 3D anatomy of the kitten confirmed the diagnosis of a large PDA with its size (9.1 mm) and localisation (Fig. 2).

The cat was treated symptomatically with an ACE-i drug (enalapril, 0.5 mg/kg 2x1, po), diuretic (furosemide, 2 mg/kg, 2x1, po) and salt restriction, in order to control pulmonary oedema and reduce left sided volume overload for one week till the surgical correction, as suggested<sup>[4]</sup>. One week after initial of the treatment, clinical signs were improved and cat was undergone to surgery as reported in our previous study<sup>[5]</sup>.

In summary, echocardiographic examination is clinically essential in diagnosis of cats with PDA. However presence



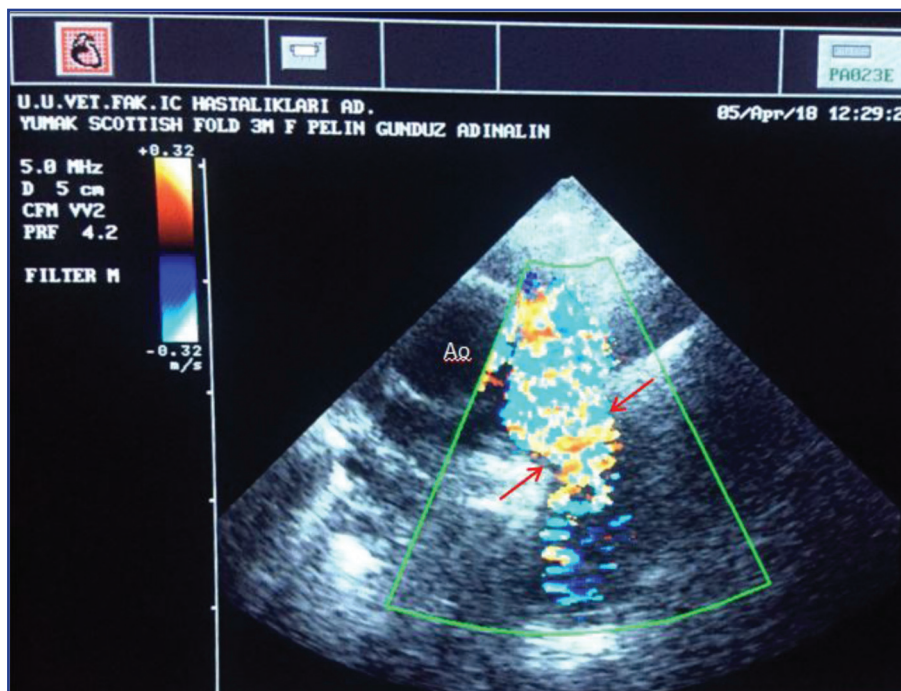
### İletişim (Correspondence)



+90 224 2940841

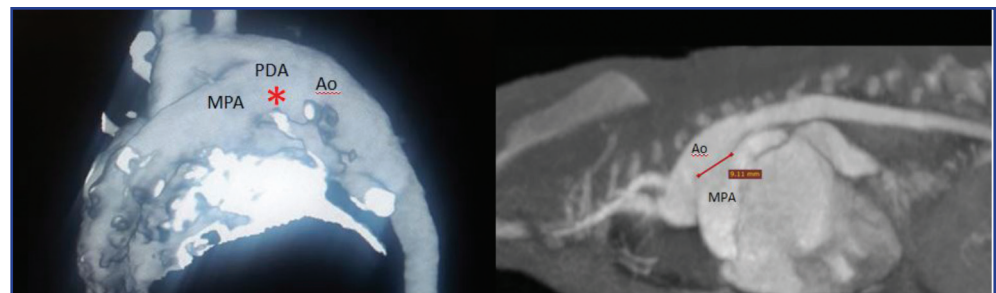


merick@uludag.edu.tr



**Fig 1.** Presence of a severe regurgitant jet of the PDA (red arrows) is seen on colour Doppler echocardiography of the pulmonary artery of the cat (Ao: Aorta)

**Fig 2.** Three-dimensional modelling of the PDA (arrow and asterix) between mean pulmonary artery and aorta is shown by computed tomography angiography (MPA: Mean pulmonary artery, Ao: Aorta, PDA: Patent ductus arteriosus)



of PDA is not always detected by echocardiography clearly, high technological diagnostic imaging systems like 3D-CTA is needed in small sized patients like kittens. Clinician should be careful auscultating patients with/without symptoms to follow the steps to the correct PDA diagnose and to confirm the diagnosis with CTA.

## REFERENCES

1. Bascuñán A, Thieman Mankin KM, Saunders AB, Bright JM, Scharf V, Singh A, O'Sullivan L, Brisson B, Estrada AH, Tou SP, Ruoff C: Patent ductus arteriosus in cats (*Felis catus*): 50 cases (2000-2015). *J Vet Cardiol*, 19 (1): 35-43, 2017. DOI: 10.1016/j.jvc.2016.10.002
2. Saunders AB, Birch SA: Three-dimensional modeling of a patent ductus arteriosus in a cat. *J Vet Cardiol*, 17 (Suppl.-1): S349-S353, 2015. DOI: 10.1016/j.jvc.2015.08.006
3. Boon JA: *Veterinary Echocardiography*. 2<sup>nd</sup> ed., Wiley-Blackwell, USA, 2010.
4. Wustefeld-Janssens BG, Burrow R, Mötsküla P, Martin M, Duker-McEwan J: Clinical findings and treatment outcomes for cats diagnosed with patent ductus arteriosus in the UK: A retrospective study of 19 cases (2004-2012). *Vet Rec*, 179 (1): 17, 2016. DOI: 10.1136/vr.103647
5. Yilmaz Z, Kocatürk M, Salci H, Levent P, Canatan U, Sag S, Güllülü S: Diagnostic importance of transthoracic echocardiography for detecting patent ductus arteriosus (PDA) in a puppy. *Kafkas Univ Vet Fak Derg*, 22 (5): 807-808, 2016. DOI: 10.9775/kvfd.2016.16081