

The Correlations Between Mean Echogenicity and Laboratory Findings of Superficial Swellings in 50 Dairy Cows

Jovan SPASOJEVIC¹ Bojan TOHOLJ¹✍️ Marko CINCOVIC¹
Milenko STEVANCEVIC¹ Branislava BELIC¹ Josip KOS²

¹ University of Novi Sad, Faculty of Agriculture, Department of Veterinary Medicine, Trg Dositelja Obradovića 8, 21000 Novi Sad, REPUBLIC of SERBIA

² University of Zagreb, Faculty of Veterinary medicine, Clinic for Surgery, Orthopaedy and Ophthalmology, Heinzelova 55, Zagreb, REPUBLIC of CROATIA

Article Code: KVFD-2018-19531 Received: 26.02.2018 Accepted: 30.05.2018 Published Online: 30.05.2018

How to Cite This Article

Spasojevic J, Toholj B, Cincovic M, Stevancevic M, Belic B, Kos J: The correlations between mean echogenicity and laboratory findings of superficial swellings in 50 dairy cows. *Kafkas Univ Vet Fak Derg*, 24 (4): 545-550, 2018. DOI: 10.9775/kvfd.2018.19531

Abstract

Ultrasonography, as a non-invasive diagnostic tool, can provide valuable information about the type, nature and duration of certain musculoskeletal inflammatory processes in animals. The aim of this study was to investigate the correlation between mean echogenicity (ME) of effusion content and its laboratory finding values. Fifty dairy cows with superficial effusions on their legs were examined in this study. Ultrasound images were analysed by software processing and ME was determined for every case of effusion. Samples of effusion contents were collected and sent to the laboratory. Investigated parameters were: Concentration of total proteins, concentration of glucose, concentration of uric acid, number of leukocytes, percentage of neutrophils, number of erythrocytes, specific weight, viscosity, colour, clarity and Gram stain. High correlation values between ME and concentration of total proteins ($R^2=0.7313$; $P<0.001$), concentration of uric acid ($R^2=0.7427$; $P<0.001$), percentage of neutrophils ($R^2=0.6923$; $P<0.001$) and specific weight ($R^2=0.6963$; $P<0.001$) showed that these laboratory parameters could have some impact on echogenicity of effusion content.

Keywords: Ultrasonography, Musculoskeletal disorders, Echogenicity, Laboratory findings, Cattle

Sütçü 50 İnekte Gözlenen Yüzeysel Ekstremitte Şişliğin Ortalama Ekojeniteleri İle Laboratuvar Bulguları Arasındaki İlişki

Öz

Ultrasonografik muayene, sığırlarda kas iskelet sisteminin belirli yangısal bozukluklarında lezyonun tipi, yapısı ve kronolojisi hakkında değerli bilgiler sunan noninvazif bir tanı yöntemidir. Bu çalışma, yangısal şişliklerde, şişliğin ortalama ekojenitesi (ME) ile şişlik içeriğinin laboratuvar bulguları arasında olası bir korelasyonun varlığını araştırmak amacıyla yapıldı. Çalışmada, ekstremitelerinde yüzeysel şişlik izlenen 50 süt sığırını kullanıldı. Şişliklerden elde edilen ultrasonografik görüntüler, görüntü çözümüleme programı ile analiz edilerek, her bir olgu için ME belirlendi. Şişliklerin punksiyonundan elde edilen içeriklerin laboratuvar analizleri yapılarak total protein konsantrasyonu, glikoz konsantrasyonu, ürik asit miktarı, lökosit sayısı, nötrofil yüzdesi, eritrosit sayısı, özgül ağırlığı, vizkositesi, rengi, berraklığı ve Gram boyama sonucu kaydedildi. İşlemciden elde edilen ME değerleri ile total protein konsantrasyonu ($R^2=0.7313$; $P<0.001$), ürik asit konsantrasyonu ($R^2=0.7427$; $P<0.001$), nötrofil yüzdesi ($R^2=0.6923$; $P<0.001$) ve özgül ağırlık ($R^2=0.6963$; $P<0.001$) arasında yüksek bir korelasyon bulunduğu tespit edildi. Bu bulgular, söz konusu laboratuvar parametrelerin, yangısal içeriğin ekojenitesi üzerinde etkili olabileceği şeklinde değerlendirildi.

Anahtar sözcükler: Ultrasonografi, Kas-iskelet sistemi bozuklukları, Ekojenite, Laboratuvar bulgular, Sığır

INTRODUCTION

Depending on the type and intensity, some disorders and diseases of locomotor system in cattle such as bursitis, hygromas, abscesses, tenosynovitis and arthritis, are characterized by extensive soft tissue swelling and presence of inflammatory exudation^[1,2].

Ultrasonography is one of the most useful diagnostic tools for their evaluation. Ultrasound allows us to evaluate echogenicity of the content, extent of effusion, type of the border of the lesion, cavity and swelling, presence of flow phenomena and presence of ultrasound artefacts (acoustic enhancement or acoustic shadowing)^[1-4]. Depending on these criteria, ultrasonography provides



İletişim (Correspondence)



+381 21 4853481



bojantoholj@gmail.com

certain information about the nature of the content in the affected area (fluid and semisolid masses), but it cannot definitively characterize the composition of the content and the type of effusion by itself [1,2].

Definitive answer about the type of effusion and its characteristics is provided by obtaining samples by centesis and laboratory analysis of aspirated fluid [1,2,5-8].

The aim of this study was to establish the correlation between the echogenicity of fluid content of certain superficial swellings on limbs in dairy cattle and parameters obtained by laboratory analysis of aspirated fluid samples (biochemical, cytological and microbiological findings).

MATERIAL and METHODS

During our mobile clinic work, in the period between 2014 and 2016, 50 cows with superficial swellings on their limbs were observed. Clinical and orthopaedic examinations were performed to identify "the region of interest" for ultrasound examination. According to clinical examination, it was found that 4 of 50 cows had swellings on their hind limbs at the femoral region, and 46 of 50 cows had swellings at the carpal or tarsal region. Before ultrasound examination was conducted, the skin over the affected area was clipped and shaved. Ultrasound examination was conducted with an ultrasound machine (Esaote Pie Medical®, Netherlands) using an 8 MHz linear transducer, in real-time. Echogenicity of the content and presence of flow phenomena were evaluated. Four ultrasound images were taken for every case of swelling and analysed by using image analyser software ImageJ (National Institutes of Health, Bethesda, Maryland, USA). Values of pixel distribution within the grayscale (0 = black, 255 = white), which present values of mean echogenicity (ME), were determined for every ultrasound image in that part which present a liquid content of effusion. These values were quantified by randomly selecting ten circles with a size of 15 pixels on every ultrasound image (Fig. 1). Average values of ME were determined for every case of swelling.

After clinical and ultrasound examination, fluid sampling was performed. Before centesis, the skin was disinfected with 10% povidone-iodine solution. The fluids were obtained using a syringe and EDTA vacutainers, stored in a portable fridge and analyzed in the laboratory within 4 h. Next laboratory findings were measured and analysed: Concentration of total proteins (Tp), concentration of glucose

(Glc), concentration of uric acid, number of leukocytes (Le), percentage of neutrophils (Ne), number of erythrocytes (Er), specific weight, viscosity, colour, clarity and Gram stain. Concentration of Tp, Glc and uric acid were measured using Analyser A15 (Biosystems S.A., Barcelona, Spain). Number of Le and Er were analysed using ADVIA 120 haematology system (Siemens, Germany).

Descriptive statistic values based on average ME values and distribution of frequency for average ME values were calculated. Correlation between average ME values and laboratory findings of effusions was examined. Pearson's correlation was used to detect correlations between average ME values and concentrations of Tp, Glc and uric acid, specific weight, number of Er and percentage of Ne. Correlation between average ME values and number of Le was investigated by logistic regression. For the purpose of logistic regression, cows were divided into two groups according to median value determined by descriptive statistics. Then, significance of differences between the values of laboratory findings in cows above the median value and in cows under the median value were determined by t-test. The correlation between average ME values and descriptive characteristics of the effusions such as viscosity (very viscous, viscous, sero-viscous, serous), colour (milky yellow, yellow, red), clarity (blurry, blurred, slightly cloudy, clear) and Gram stain (presence of bacteria, absence of bacteria), was tested using χ^2 test and $2 \times k$ contingency tables, so the significance of difference in the proportion

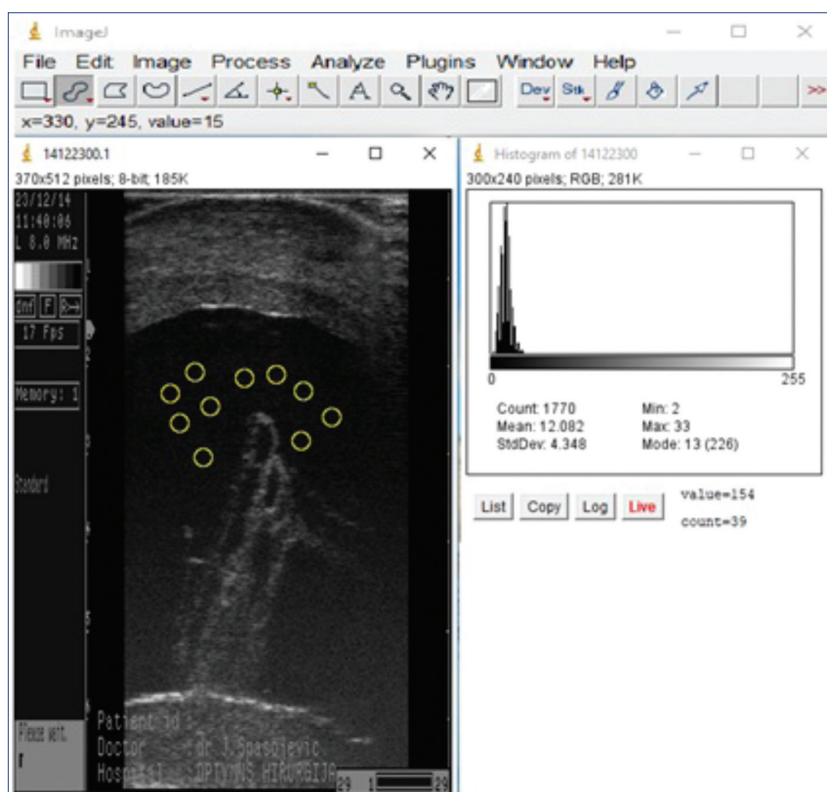


Fig 1. Determination of mean echogenicity (ME)

of cows that have certain characteristics of effusions in the groups based on average ME values above and under the median value determined by descriptive statistics has been investigated. All statistical analyses were performed with Statistica (TIBCO Software Inc., USA) and Microsoft Office Excel 2007 (Microsoft Corporation, USA).

RESULTS

Descriptive statistic values based on average ME values and distribution of frequency for average ME values are presented in *Table 1* and *Fig. 2*.

Average ME values were between 5.6 and 34.62. Skewness and kurtosis indicate that average ME values had normal frequency distribution.

Average ME values were correlated with different laboratory findings of the effusions (*Fig. 3-9, Table 2*). Positive correlation was found between average ME values and concentrations of Tp and uric acid, specific weight, number of Er and percentage of Ne. Negative correlation was found between average ME values and concentration of Glc. There was found significant correlation between the number of Le and average ME which is corresponding to positive correlation. Another valuable indicator of the usability of average ME in evaluation of effusions is the difference between laboratory finding values of effusions in groups of cows above and under the median value. Results showed that there were higher concentrations of Tp and uric acid, higher specific weight, higher number of Le, higher percentage of Ne and lower concentration

Table 1. Descriptive statistic values based on average ME values

Variable	Descriptive Statistics									
	N	Mean	Median	Min	Max	Lower Quartile	Upper Quartile	Std. Dev.	Skewness	Kurtosis
Mean Echogenicity (ME)	50	13.02	9	5.6	34.62	7	14	8.95	1.51	0.86

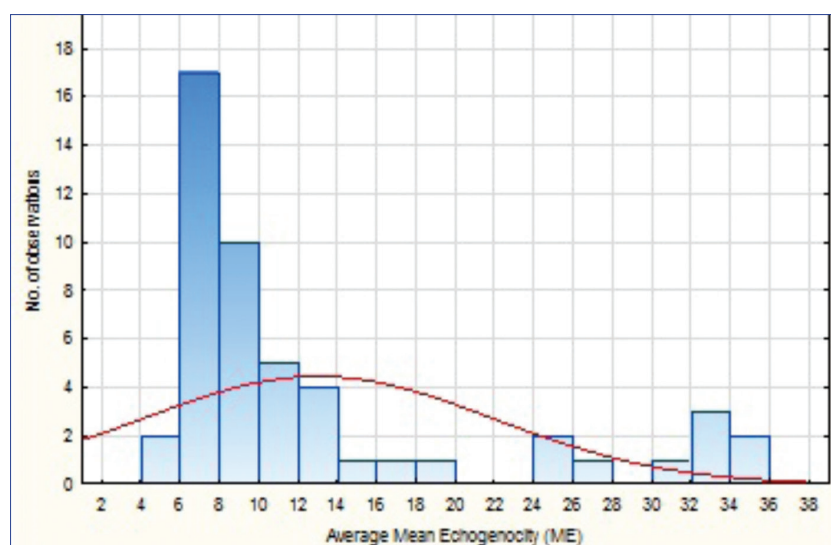


Fig 2. Distribution of frequency for average ME values

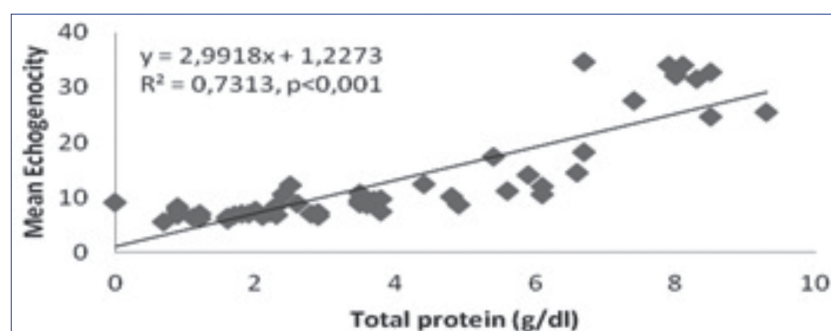


Fig 3. Linear correlation and regression between average mean echogenicity (ME) values and concentration of total proteins

of Glc in the group of cows with average ME values above the median value. A significant difference in number of Er between groups of cows above and under the median value was not found (*Table 2*).

The results in *Table 3* show that there is a significant difference in the proportion of cows with certain characteristics of effusions in function of that whether the average ME values were high or low. In cows, in which higher average ME values were found, very viscous and viscous consistency, milky yellow colour, and poor transparency (blurry) of the effusions dominated and in a large proportion of the samples there was presence of bacteria. On the other hand, in cows with lower average ME values of ultrasound findings, serous, yellow colour, and cloudy or clear effusions dominated, and also absence of bacteria in a large portion of the samples.

DISCUSSION

Ultrasonography is an ideal, non-invasive diagnostic tool for the examination and evaluation of musculoskeletal disorders and diseases such as arthritis, tenosynovitis, bursitis, hygromas and abscesses, because these diseases are

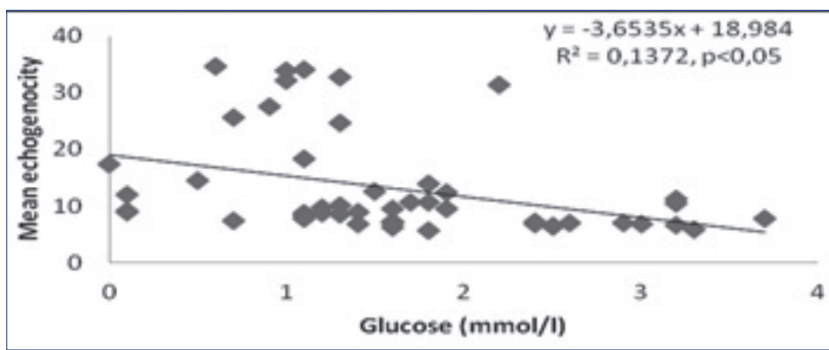


Fig 4. Linear correlation and regression between average mean echogenicity (ME) values and concentration of glucose

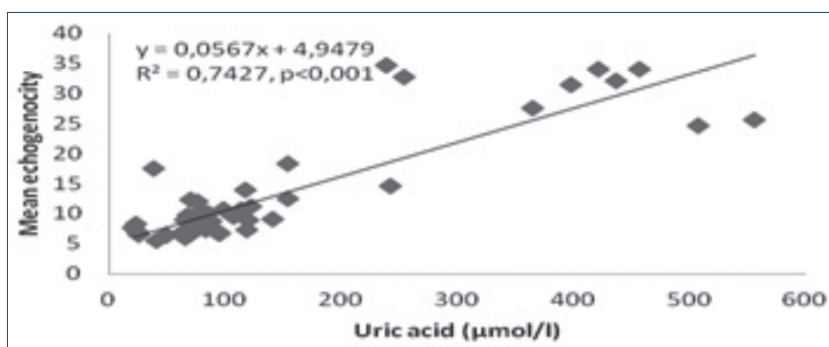


Fig 5. Linear correlation and regression between average mean echogenicity (ME) values and concentration of uric acid

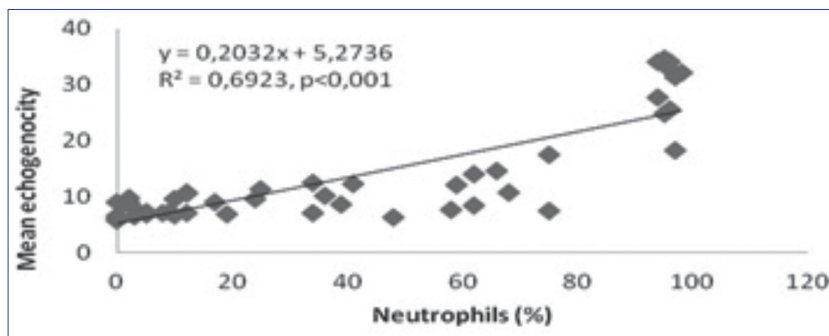


Fig 6. Linear correlation and regression between average mean echogenicity (ME) values and percentage of Ne

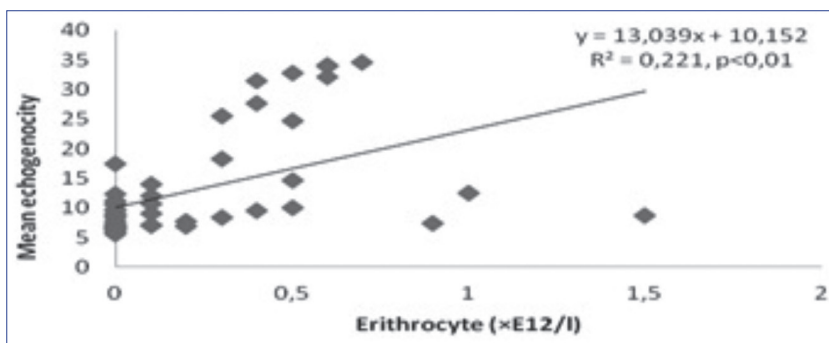


Fig 7. Linear correlation and regression between average mean echogenicity (ME) values and number of Er

frequently associated with extensive soft tissue swelling and inflammatory exudation ^[1,2].

Ultrasonographic examination can provide valuable information about the type, nature, and duration of some inflammatory processes, and this information can be helpful in planning proper therapy protocols for mentioned diseases ^[1,2,9,10].

In recent studies ^[1,2,6-8,11], it was reported that evaluation of the echogenicity of effusions and flow phenomena in some musculoskeletal disorders and diseases, which ranges from anechoic to echoic, depend on the type and nature of its inflammatory content (serous, sero-fibrinous, fibrinous, purulent). In the study with horses ^[12], the relationship between ultrasonographic examination and the degree of effusion of the synovial cavity, the degree of synovial membrane thickening and the time of the beginning of inflammatory process was found. In the study with cows ^[10], it was reported that capsule echogenicity instead of capsule thickness is a more reliable ultrasonographic parameter for determination of the duration of the inflammatory process.

It has been also mentioned that ultrasonography cannot definitely characterize the composition of the content and the type of effusion by itself. In that purpose, it was recommended to perform centesis of the inflammatory process and laboratory analysis of aspirated fluid samples ^[1,2,5-8].

In our study we investigated correlations between echogenicity of effusions on ultrasound images and laboratory finding values obtained from aspirated fluid samples. In order to investigate these correlations, we used medical image analyser and quantified echogenicity of effusions. Up to our knowledge, it could not be found that researchers quantified the echogenicity of effusions in their studies about musculoskeletal disorders in cattle such as arthritis, tenosynovitis, bursitis, hygromas and abscesses, and only descriptive methods were used for their evaluation.

Rohde et al. ^[13], defined some laboratory

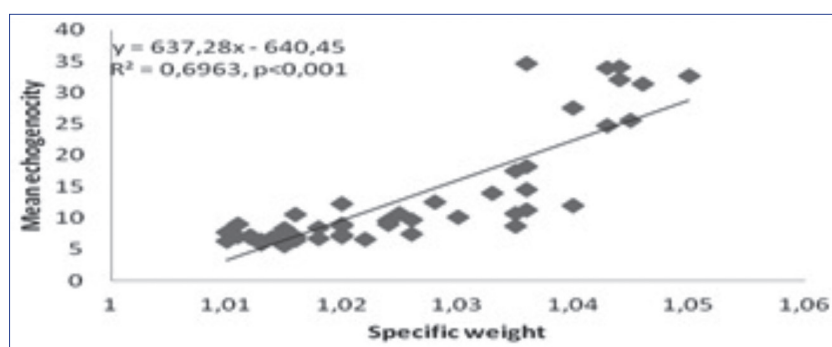


Fig 8. Linear correlation and regression between average mean echogenicity (ME) values and specific weight

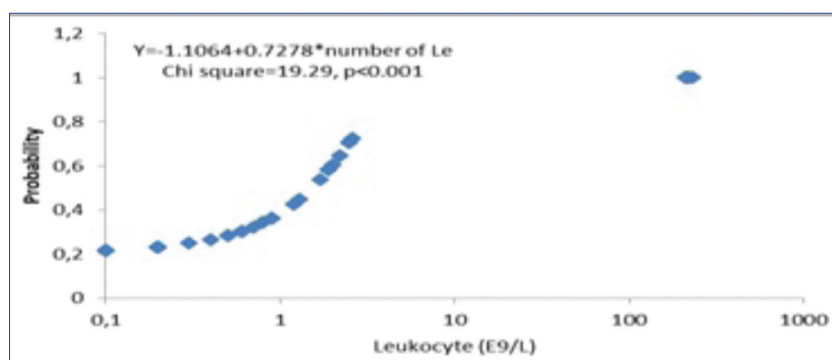


Fig 9. Correlation and regression between average mean echogenicity (ME) values and number of Le

skeletal disorders and diseases in cattle which are associated with extensive soft tissue swelling and inflammatory exudation. It could be possible to correlate ME values with laboratory parameters such as concentrations of Tp and uric acid, specific weight and percentage of Ne.

Our results could be used for confirmation of clinical cases of effusions in cattle and evaluation of therapy effects. That means that those patients with higher ME values could be in higher risks to have effusions with septic process in it, and according to that, it could define a therapy protocol, evaluation and prognosis of a diagnosed diseases.

In future studies, the limits of ME that allow detection of different types of effusions should be examined and validated.

REFERENCES

1. **Kofler J:** Ultrasonography as a diagnostic aid in bovine musculoskeletal disorders. *Vet Clin North Am Food Anim Pract*, 25 (3): 687-731, 2009. DOI: 10.1016/j.cvfa.2009.07.011

Table 2. Laboratory parameters of effusions in two groups classified as above or below median of average ME values

Parameter	Average ME Values		P
	Above Median	Below Median	
Total protein (g/dL)	5.75±2.33	2.14±1.05	<0.000001
Glucose (mmol/L)	1.32±0.82	1.94±0.9	<0.05
Uric acid (µmol/L)	216.44±160.18	68.46±27.28	<0.00005
Leukocyte (10 ⁹ /L)	87.05±107.57	0.62±0.8	<0.0005
Neutrophils (%)	59.36±36.15	16.88±22.23	<0.00005
Erythrocyte (10 ¹² /L)	0.31±0.28	0.13±0.34	>0.05
Specific weight	1.03±0.01	1.02±0.006	<0.000005

parameters in their study, and gave some recommendations about their values in synovial fluid which distinguish infectious from non-infectious processes. These recommendations helped us to define which laboratory parameters we should use in our study.

In the study with horses [12], relations between ultrasonographic findings and white blood cell count have been described. The authors reported that ultrasonographic findings were not conditioned by white blood cell count.

In conclusion, according to our results, evaluation of echogenicity of effusions and determination of ME values could be useful in the purpose of evaluation of musculo-

2. **Kofler J, Geissbühler U, Steiner A:** Diagnostic imaging in bovine orthopedics. *Vet Clin North Am: Food Anim Pract*, 30 (1): 11-53, 2014. DOI: 10.1016/j.cvfa.2013.11.003

3. **Kofler J:** Ultrasonographic examination of the carpal region in cattle-normal appearance. *Vet J*, 159 (1): 85-96, 2000. DOI: 10.1053/tvjl.1998.0339

4. **Kofler J, Edinger HK:** Diagnostic ultrasound imaging of soft tissues in the bovine distal limb. *Vet Radiol Ultrasound*, 36 (3): 246-252, 1995. DOI: 10.1111/j.1740-8261.1995.tb00255.x

5. **Heppelmann M, Rehage J, Kofler J, Starke A:** Ultrasonographic diagnosis of septic arthritis of the distal interphalangeal joint in cattle. *Vet J*, 179 (3): 407-416, 2009. DOI: 10.1016/j.tvjl.2007.10.017

6. **Kofler J:** Arthrosonography - The use of diagnostic ultrasound in septic and traumatic arthritis in cattle - A retrospective study of 25 patients. *Br Vet J*, 152 (6): 683-698, 1996. DOI: 10.1016/S0007-1935(96)80122-9

Table 3. Connection between average ME values and physical characteristic and presence of bacterial cell in effusions

Characteristics of Effusions	Category	Number of Cows According to Average ME Values		χ^2 Test
		Above the Median Value	Under the Median Value	
Viscosity	very viscous	7	0	P<0.0005
	viscous	7	1	
	sero-viscous	6	7	
	serous	5	17	
Colour	milky yellow	9	0	P<0.005
	yellow	10	18	
	red	6	7	
Clarity	blurry	16	4	P<0.005
	blurred	7	10	
	slightly cloudy	2	3	
	clear	0	8	
Presence of bacteria (Gram stain)	Presence of bacteria	16	3	P<0.0005
	Absence of bacteria	9	22	

7. Kofler J, Altenbrunner-Martinek B: Ultrasonographic findings of disorders of the tarsal region in 97 cattle-arthritis, bursitis, tenosynovitis, periarticular abscess and vein thrombosis. *Berl Munch Tierarztl Wochenschr*, 121 (3-4): 145-158, 2007.

8. Kofler J, Martinek B: Ultrasonographic imaging of disorders of the carpal region in 42 cattle-arthritis, tenosynovitis, precarpal hygroma, periarticular abscess. *Tierarztl Prax*, 32 (2): 61-74, 2004.

9. Abouelnasr K, El-Shafaey ES, Mosbah E, El-Khodery S: Utility of ultrasonography for diagnosis of superficial swellings in buffalo (*Bubalus bubalis*). *J Vet Med Sci*, 78 (8): 1303-1309, 2016. DOI: 10.1292/jvms.15-0629

10. Seyrek-Intas D, Celimli N, Gorgul OS, Cecen G: Comparison of clinical, ultrasonographic, and postoperative macroscopic findings in

cows with bursitis. *Vet Radiol Ultrasound*, 46 (2): 143-145, 2005. DOI: 10.1111/j.1740-8261.2005.00028.x

11. Magda MA, Abdel-Hakiem MAH: Ultrasonographic differential diagnosis of superficial swellings in farm animals. *J Adv Vet Res*, 2 (4): 292-298, 2012.

12. Beccati F, Gialletti R, Passamonti F, Nannarone S, Di Meo A, Pepe M: Ultrasonographic findings in 38 horses with septic arthritis/tenosynovitis. *Vet Radiol Ultrasound*, 56 (1): 68-76, 2015. DOI: 10.1111/vru.12183

13. Rohde C, Anderson DE, Desrochers A, St-Jean G, Hull BL, Rings DM: Synovial fluid analysis in cattle: A review of 130 cases. *Vet Surg*, 29 (4): 341-346, 2000. DOI: 10.1053/jvet.2000.5605