

## Helminths That Are Detected by Necropsy in Wrestling Camels <sup>[1]</sup>

Suleyman AYPAK <sup>1</sup>  Metin PEKAGIRBAS <sup>1</sup>  
Selin Uner HACILARLIOGLU <sup>1</sup> Ali Ibrahim BAGDATLIOGLU <sup>2</sup>

<sup>[1]</sup> This research was presented orally in Second International Selçuk-Ephesus Symposium on Culture Of Camel-Dealing and Camel Wrestling (18-20<sup>th</sup> January 2018, Selcuk - Izmir, Turkey)

<sup>1</sup> Adnan Menderes University, Faculty of Veterinary Medicine, Department of Parasitology, TR-09020 Efeler/Aydin - TURKEY

<sup>2</sup> Uludag Integrated Meat Facilities, Umurlu Mh. TR-09630, Efeler/Aydin - TURKEY

Article Code: KVFD-2018-19591 Received: 16.02.2018 Accepted: 11.05.2018 Published Online: 11.05.2018

### How to Cite This Article

**Aypak S, Pekagirbas M, Hacilarlioglu SU, Bağdatlioğlu Aİ:** Helminths that are detected by necropsy in wrestling camels. *Kafkas Univ Vet Fak Derg*, 24 (4): 571-576, 2018. DOI: 10.9775/kvfd.2018.19591

### Abstract

The present study aims to carry out a helminthological examination and epizootiological determination of the parasites that were detected by the parasitological examination in the carcasses and internal organs of wrestling camels that were slaughtered due to miscellaneous reasons. The material of the study comprised wrestling camels that were sent to the slaughterhouse for various reasons including sickness, old age, and underperformance due to an unknown cause. The present study was conducted on 24 male wrestling camels of ages ranging between 5 to 20 years. After slaughtering, the carcasses and internal organs were examined parasitologically. All internal organs, except for abomasum and intestines, were macroscopically analyzed in the slaughterhouse to determine whether any helminth larvae or adult helminths were present and those that bore traces of a parasitic period were brought to the laboratory for further analysis. For the examination of the digestive system, abomasum, and intestines, along with their contents, were brought to the laboratory to perform macroscopic and microscopic analyses by following appropriate methods. At least one helminth infection was seen in 14 (58%) of 24 camels in necropsy. The analysis of the organs revealed hydatid cysts in 12 (50%) animals, which were localized in the lungs of 7 animals, livers of 3 animals, both in the lung and liver of one animal and in the spleen of another animal. By examining the stomachs and intestines of the animals, *Stilesia globipunctata* was detected in the small intestines of 3 camels (12.5%), while *Nematodirus filicollis* was detected in the small intestine of one animal (4.1%), and *Oesophagostomum venulosum* was detected in the large intestine of the same animal (4.1%). Neither helminth larvae nor adult helminths were observed in other organs. The presence of hydatid cysts in over fifty percent of the examined camels is noteworthy. As a disease of great importance for public health, its prevalence in camels brings forth the absolute requirement for slaughtering animals in slaughterhouses or under the control of a veterinary physician. This study is the first one to report the occurrence of *Stilesia globipunctata*, *Nematodirus filicollis* and *Oesophagostomum venulosum* in camels at species level.

**Keywords:** Camel, Helminth, Hydatid cyst, Necropsy, Turkey

## Güreş Develerinde Nekropsi İle Tespit Edilen Helmintler

### Öz

Bu çalışmada, güreş develerinin çeşitli nedenlerle kesime sevk edilenlerinde karkas ve tüm iç organların helmintolojik açıdan muayenesi ve tespit edilen parazitlerle bu hayvanlarda epizootiyolojik bir durum tespiti yapılması amaçlanmıştır. Çalışmanın materyalini hastalık, ileri yaş, nedeni bulunamamış performans düşüklüğü gibi değişik sebeplerle mezbahada kesilen güreş develeri oluşturmuştur. Çalışma yaşları 5-20 arasında değişen tamamı erkek 24 güreş devesinde gerçekleştirilmiştir. Kesim sonrası karkas ve tüm iç organlar parazitolojik açıdan incelenmiştir. Abomasum ve bağırsaklar dışındaki tüm iç organlar helmintlere ait larva ya da erişkin dönemleri açısından mezbahada makroskopik olarak incelenmiş, her hangi bir paraziter döneme rastlananlar sonraki incelemeler için laboratuvara getirilmiştir. Sindirim sistemine ilişkin incelemeler için abomasum ve bağırsaklar içerikleri ile birlikte laboratuvara getirilerek makroskopik ve mikroskopik incelemeleri uygun yöntemlerle burada tamamlanmıştır. Nekropsisi yapılan 24 devenin 14'ünde (%58) en az bir helmint enfeksiyonu görülmüştür. Yapılan organ muayenelerinde 7'si akciğer, 3'ü karaciğer, 1'i akciğer karaciğer birlikte ve 1'i dalak yerleşimli olmak üzere toplam 12 (%50) devede hidatik kiste rastlanmıştır. Mide ve bağırsaklarda yapılan incelemelerde ise 3 devenin ince bağırsaklarında *Stilesia globipunctata* (%12.5), bir devede *Nematodirus filicollis* (%4.1) ve aynı devenin kalın bağırsaklarında *Oesophagostomum venulosum* (%4.1) tespit edilmiştir. Bunlar dışında kalan organlarda herhangi bir helminte ait larva ya da erişkin döneme rastlanmamıştır. İncelemesi yapılan develerin yarısından fazlasında hidatik kiste rastlanması dikkat çekicidir. Halk sağlığı açısından son derece önemli olan bu hastalığın develerdeki yaygınlığı kesimlerin mutlaka mezbahalarda ya da veteriner hekim kontrolünde yapılması gerekliliğini ortaya çıkarmıştır. Bu çalışmayla *Stilesia globipunctata*, *Nematodirus filicollis* ve *Oesophagostomum venulosum* develerden tür düzeyinde ilk kez bildirilmiştir.

**Anahtar sözcükler:** Deve, Helminth, Hidatik kist, Nekropsi, Türkiye



### İletişim (Correspondence)



+90 256 2470700 Fax: +90 256 2470720



suleymanaypak@yahoo.com

## INTRODUCTION

Competitive and struggling behaviors that male camels display in mating period due to hormonal alterations were colloquially considered similar to wrestling. This competition became apparent in camel owners as well, which turned into annual festival organizations and became traditional. Camel wrestling dates back to the fifteenth century, and it is still performed in Turkey <sup>[1]</sup>. Camel wrestling events are held annually between December and mid-March in almost 100 towns in Marmara, Mediterranean, and mostly Aegean region <sup>[2]</sup>. Although the relation between these animals and people is very long considering their use for transportation and traveling, there are very few scientific studies on the diseases in these animals. Studies on parasitic diseases, which may be an issue for almost any kind of animal breeding, are also limited to the detections based on fecal examination <sup>[1,3,4]</sup>.

The presence of parasites living in the digestive system and related organs can be revealed at a certain level in living animals by the detection of helminth eggs and larvae in their feces. Accordingly, a recent study performed in Turkey identified these parasites mainly at the genus level through fecal cultivation <sup>[1]</sup>. These worms, most of which were reported for the first time, also contributed significantly to the parasite fauna. In this study, 74% (81/109) of the camels were infected with one or more parasites. Some species, such as *Trichostrongylus* spp., *Ostertagia* spp., *Haemonchus* spp., *Nematodirus* spp., *Chabertia ovina*, *Oesophagostomum* spp., *Trichuris* spp., *Capillaria* spp., *Cooperia* spp., *Cooperia oncophora*, *Fasciola* spp., *Dicrocoelium* spp., *Paramphistomum* spp., *Dictyocaulus viviparus*, *Eimeria cameli*, *Eimeria* spp. have been reported at different rates <sup>[1]</sup>. However, organ examinations that use necropsy techniques are more valuable because they allow species-level identification and a morphological examination of the larval stages of cestodes; the parasites in organs not related to the digestive system, and all of the parasites found as well.

In this study, it was aimed to make a parasitological examination of the wrestling camels' carcass and all the internal organs that were subjected to slaughtering due to various reasons, and to determine the epizootiological condition of these animals based on the parasites detected.

## MATERIAL and METHODS

The subjects of this study were wrestling camels slaughtered in slaughterhouses due to various reasons such as illness, old age, or lack of performance with no detected reason. This study was conducted between November 2016 and October 2017 in Integrated Meat Facilities located in Umurlu district of Aydın on 24 male wrestling camels aged between 5 and 20 years. Because

wrestling camels frequently change owners and some camels are raised in Turkey whereas others are brought from abroad (generally Iran), we were unable to determine the origin of the camels we assessed.

After slaughtering, the carcass and all internal organs were examined in the slaughterhouse and the laboratories at the Department of Parasitology, Veterinary Medicine, Adnan Menderes University. All internal organs except abomasum and intestines were macroscopically examined in the slaughterhouse for larvae or adult helminths, and the ones in any parasitic stage were brought to the laboratory for further examination.

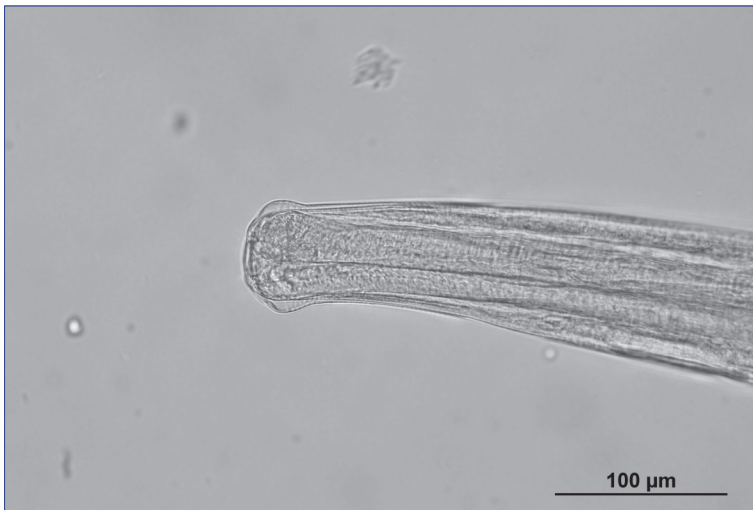A double ligature was placed at the end and beginning of small and large intestines, and they brought with their content to the laboratory for the examination related to the digestive system. Initially, macroscopic examinations were performed and parasites were collected after removing the mesenteric and adipose tissues found in these sections and cutting them lengthwise in a bathtub. The contents were then washed using a suitable porous sieve under mild running water. The residue that stayed on the sieve was moved to another container for microscopy. The collected content was transferred to Petri dishes in small quantities and examined under a stereomicroscope. The parasites were pre-cleaned in physiological saline, and stored in a 70% ethyl alcohol solution that is close to its boiling temperature until detailed examinations were made. They were kept in Lactophenol solution for transparency during the period they were diagnosed and examined between a slide and a cover slide <sup>[5]</sup>. The detection was performed using a microscope (Olympus BX51) that was capable of making digital measurement and visualization (Olympus DP70) based on the relevant literature <sup>[6-9]</sup>.

## RESULTS

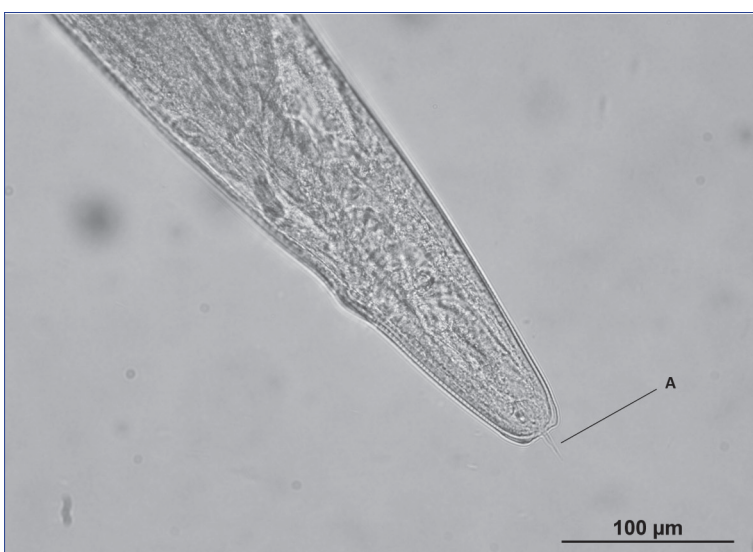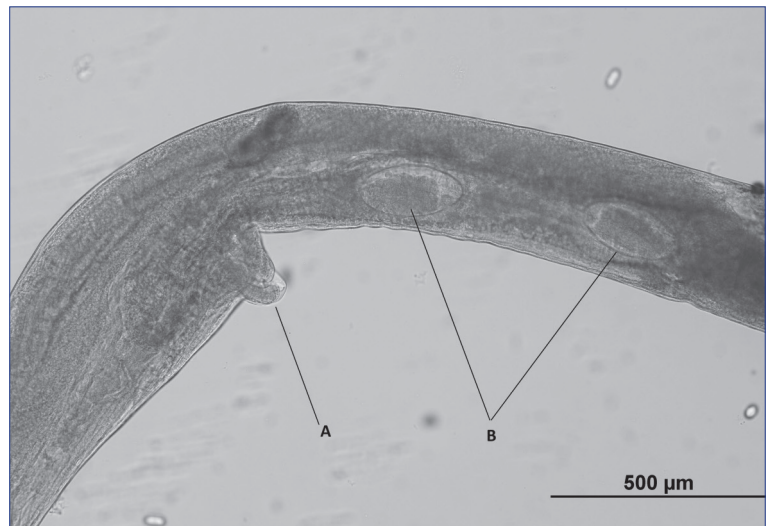
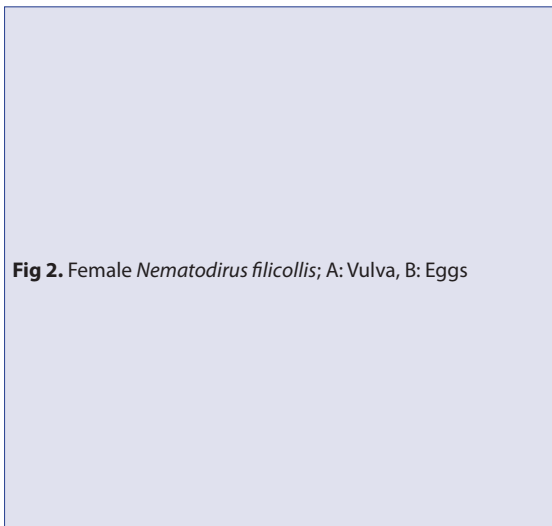
At least one helminth infection was observed in 14 of 24 (58%) of the animals on which necropsy was performed. A total of 12 (50%) hydatid cysts were found in organ examinations. Of them, 7 were in the lung, 3 were in the liver, 1 was in the lung and liver together, and 1 was in the spleen. According to the examinations made in the stomach and intestine of the animals, there was *Stilesia globipunctata* (camel 1; 7, camel 2; 23, camel 3; 121 parasites) in the small intestine of three (12.5%) camels, *Nematodirus filicollis* (Total 31 parasites; 21 female, 10 male) in one (4.1%) of the camels (*Fig. 1, 2, 3*), and also *Oesophagostomum venulosum* (Total 13 parasites; 9 female, 4 male) in the large intestine of the same (4.1%) animal (*Fig. 4, 5, 6*). Neither helminth larvae nor adult forms were found in the other organs than these ones.

## DISCUSSION

In live animals, eggs, oocytes, or larvae of parasites can



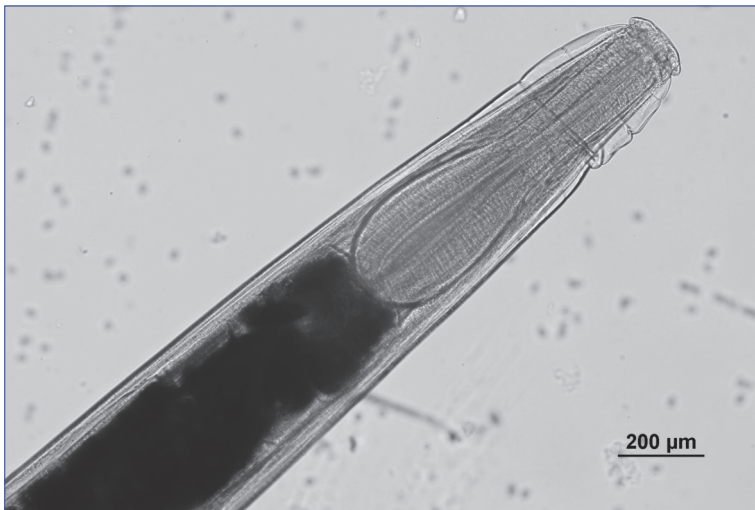
**Fig 1.** *Nematodirus filicollis* anterior end



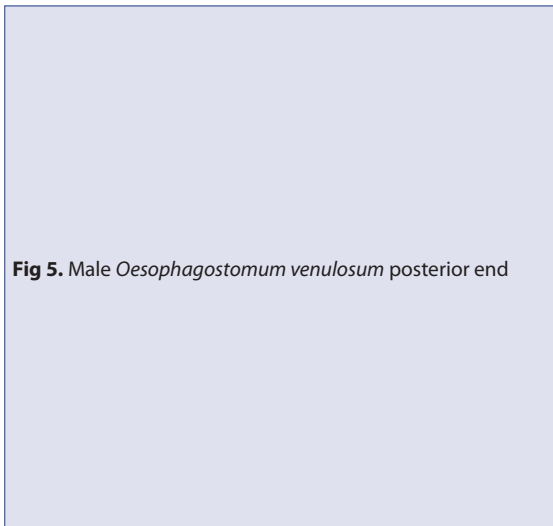
**Fig 3.** Female *Nematodirus filicollis* posterior end, A: Spin

be detected in stool samples or antigen/antibody in blood serum using a serologic test. However, they may not always reveal the parasitic load precisely. Parasitic

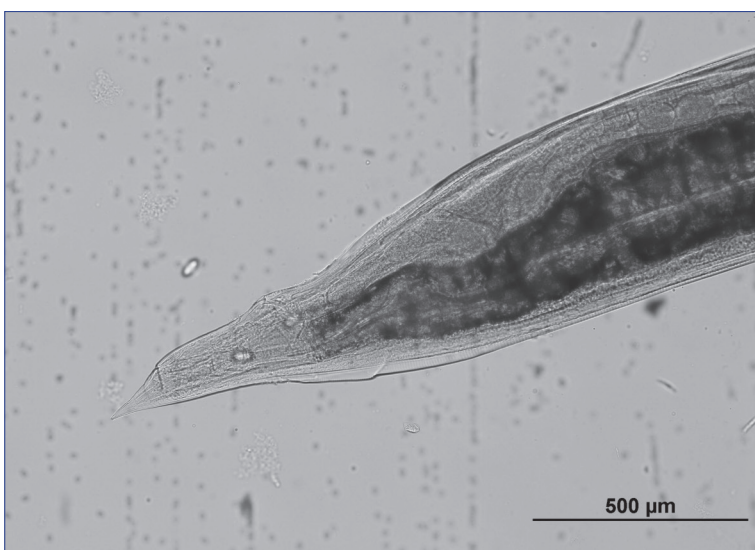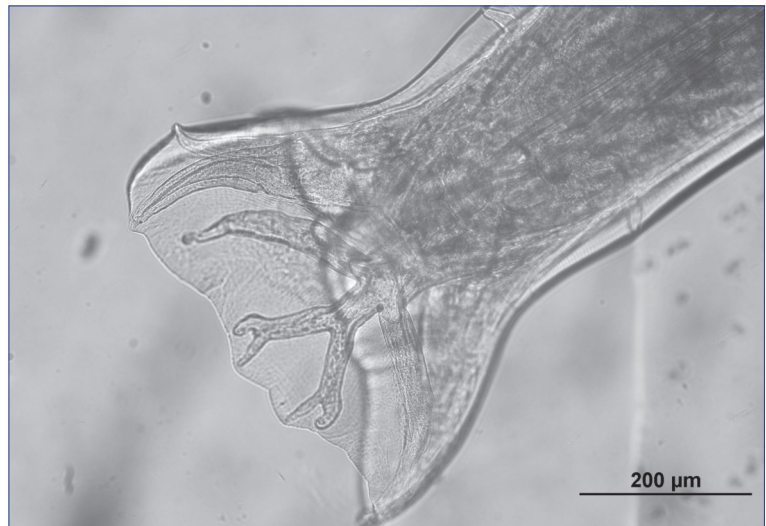
infections can be diagnosed accurately during necropsy. Macroscopic or microscopic detection of the parasite itself or its larvae in relevant organs is the way to demonstrate



**Fig 4.** *Oesophagostomum venulosum* anterior end



**Fig 5.** Male *Oesophagostomum venulosum* posterior end



**Fig 6.** Female *Oesophagostomum venulosum* posterior end

the presence and density of the parasites most clearly. This method was used in this study, and hydatid cysts were found which are not possible to detect by using

fecal examination method, and also cestodes and nematodes which were detected in a much easier and more accurate way.

The hydatid cyst, the larval form of *Echinococcus granulosus*, infects canidae such as dogs, wolves, and coyotes. The larvae develop in the internal organs of humans and other mammals, including sheep, goats, cattle, and pigs. This parasite, which causes great economic losses, is one of the most common parasitic zoonoses worldwide [10]. Hydatidosis in the final and intermediate hosts is highly endemic worldwide, especially in the rural populations of South America, coasts of Mediterranean Sea, Eastern Europe, the Near and Middle East, East Africa, Central Asia, China, and Russia [11,12]. In countries with large numbers of camels, hydatidosis is also reported in these animals. According to these results, the prevalence of hydatidosis was found to be 7.45-70% in Iran [13], 5.3% in Oman [14], 2.53% in Egypt [15], 6.86% in Saudi Arabia [16], 8.8% in Jordan [17], and 6.94% in Kenya [18]. In Central Asian camels, hydatid cysts have high viability and fertility rates [12]. In Turkey, parasites exist in 1-40% of final hosts and 3.5-58.6% of intermediate hosts [12]. In a study conducted in Aydin [19], 1% of owned dogs were positive for *E. granulosus*. In addition, hydatid cysts were detected in two of six camels slaughtered in Aydin [4]. In our study, hydatid cysts were highly prevalent in the lung, liver, and spleen of camels. This parasite was seen in 50% of camels, which is indicative of a high transmission risk from camels.

*Stilesia globipunctata* can cause growth retardation, especially in young animals, due to enteritis in ruminants where it is located. In addition, this parasite can cause septic peritonitis and related incidences of death since it is capable of perforating the small intestine actively [20]. The prevalence of this species was reported 19% and 5.5% in Ethiopia [21] and Pakistan [22], respectively. In addition, *S. vittata* species may be found in camels as well [23,24]. In a study conducted in Syria, *S. globipunctata* and *S. vittata* were found together [25]. *Stilesia globipunctata*, which was detected in three camels (12.5%) in the present study, is a parasite known to exist in sheep and goats in Turkey [20]. It is reported to be one of the most common cestodes in Iran [13]. The researcher believes that this high prevalence may be related to the large number of camels brought from Iran, Turkey's neighbor.

*Nematodirus* spp., a thin-neck or thread-neck worm with approximately 30 species, infects the small intestine of rodents and other mammals. Since the egg-laying period of *N. filicollis* is relatively long, the chance for the parasite to increase in numbers reduces during the spring season when the conditions are more suitable for the parasite. Hence, its pathogeny is relatively lower than that of other species. The pathogenicity of the intestinal mucosa and villi during development varies depending on the number of parasites. The development of enteritis during intensive infections may lead to different clinical results including different types of yield loss and even death [9]. A study in Syria [25], it was reported that *N. oiratianus* as one of the most common species (57%), while *N.*

*helvetianus* and *N. dromedarii* species were also identified. Reviews for camel parasites in Saudi Arabia [26] and India [27] have shown that the infections were caused by *Nematodirus* spp. The existence of *N. oiratianus*, *N. abnormalis*, *N. dromedarii*, *N. helvetianus*, *N. mauritanicus*, and *N. spathiger* species in Iran has been reported with reference to various investigators [13]. *Nematodirus mauretanicus* ve *N. dromedarii* are parasites that are unique in camels and have not yet been reported in any other ruminants. Other *Nematodirus* spp., except the aforementioned two species, were also observed in other ruminants [24]. *Nematodirus filicollis*, which was detected in a camel in the present study (4.5%), was also seen in camels in Egypt [28]. In Turkey, *N. spathiger*, *N. filicollis*, *N. helvetianus*, and *N. abnormalis* were reported in ruminants and *N. lanceolatum* was detected in sheep and goats [9]. *N. battus* and *N. spathiger* species were reported in the same study as well. In studies conducted in Turkey, Çırak et al. [3] found *Nematodirus* spp. eggs in the stool of one of 10 camels and Aypak et al. [1] in four of 109 camels.

Pathogenic effects of *Oesophagostomum venulosum* may be indicated in the larval, adult, and nodal stages of the parasite that are included in the final host. They feed on blood in larval and adult stages. Intestinal wall edema, hemorrhage, and protein loss that emerge in relation to this situation and many other clinical results are particularly remarkable in animals that encounter this infection for the first time. The nodular plate in recurrent infections can cause severe absorption disorders depending on the intensity of the infection. If the nodule is torn to the peritoneum, peritonitis and also death can occur [9]. This parasite was seen at a prevalence of 2.5% in a study conducted in Pakistan [22]. The presence of *Oesophagostomum* spp. have been reported in several studies in Saudi Arabia [23], *O. venulosum* and *O. radiatum* species were reported in Iran [13]. In Turkey, Aypak et al. [1] detected *Oesophagostomum* spp. at a prevalence of 4.5% (at the genus level) in wrestling camels through egg cultivation from the feces. *Oesophagostomum venulosum* was detected in the large intestine of the camel (4.5%) with *N. filicollis*. In addition, the presence of *O. columbianum* and *O. venulosum* in ruminants and *O. radiatum* in cattle and buffaloes are known in Turkey [9].

According to the studies based on fecal examination in wrestling camels in Turkey, the rate of gastrointestinal helminth was between 44-74% in different studies [1,4]. In the present study, the prevalence of gastrointestinal helminth was found to be 16%, which is much lower than these two studies [1,4]. The researcher thinks that the application of antiparasitic drugs along with many other ways of treatment in animals with unexplained disease or poor performance might have abolished the existing parasites. In addition, high parasitemia detected in wrestling camels in previous studies [1,4] will probably create a high awareness in animal owners and veterinarians.

There are very few studies on damages that are caused by the parasites found in camels [1,13,23]. The damages caused by parasites and the yield losses can be estimated from studies conducted in other ruminants. Especially, their effect on wrestling performance is open to investigation.

In Turkey, camel breeding is mainly practiced in the Aegean, Mediterranean and Marmara regions. Although the use of camel meat is not the main aim of the breeding, the meat is offered for consumption when they are slaughtered. Infection of dogs with organisms at dangerous larval stages such as hydatid cysts in the improper slaughtering places can lead to serious public health issues. This high prevalence of hydatidosis, which has an important place among zoonotic infections, emphasized the importance of slaughtering these animals in slaughterhouses or under the supervision of a veterinarian.

This study is the first one to report the occurrence of *Stilesia globipunctata*, *Nematodirus filicollis* and *Oesophagostomum venulosum* at species level in camels.

## REFERENCES

- Aypak S, Eren H, Bakırcı S, Uner S, Sımsek E, Boga B, Guler AG, Unlu AH:** Parasites detected by examination of fecal samples in wrestling camels. *Kafkas Univ Vet Fak Derg*, 19 (3): 371-374, 2013. DOI: 10.9775/kvfd.2012.7484
- Çalışkan V:** Bir Dünya Kültür Mirası: Anadolu Devecilik Kültürü ve Deve Güreşleri. 4-5, Incirliova Belediyesi Kültür Yayınları, Pozitif Matbaa, Ankara, 2016.
- Cirak VY, Senlik B, Gulegen E:** Gastrointestinal parasites of camels (*Camelus dromedarius*) from Turkey and efficacy of doramectin against *Trichostrongyles*. *J Camel Pract Res*, 18 (2): 283-285, 2011.
- Eren H, Aypak S, Selek N:** Aydın yöresinde Deve (*Camelus dromedarius*)'lerde dışkı bakılarına göre saptanan parazitler. *YYÜ Vet Fak Derg*, 14 (1): 59-60, 2003.
- Senlik B:** Teşhis yöntemleri. In, Tınar R (Ed): *Helmintoloji*. 463-535, Nobel Yayın Dağıtım, Ankara, 2006.
- Güralp N:** *Helmintoloji*. 2. Baskı, 392-402, Ankara Üniversitesi Veteriner Fakültesi Yayınları, 368, Ankara, 1981.
- Soulsby EJJ:** *Helminths, Arthropods and Protozoa of Domesticated Animals*. 7<sup>th</sup> ed., 87-346, Bailliere Tindall, England, 1986.
- Toparlak M, Tüzer E:** Veteriner *Helmintoloji*. Ders Notu No: 102., 137, İstanbul Üniversitesi Veteriner Fakültesi Yayını, İstanbul, 1999.
- Umur Ş, Köroğlu E, Güçlü F, Tınar R:** Nematoda. In, Tınar R (Ed): *Helmintoloji*. 213-536, Nobel Yayın Dağıtım, Ankara, 2006.
- Ayaz E, Tınar R:** Cestoda. In, Tınar R (Ed): *Helmintoloji*. 167-180, Nobel Yayın Dağıtım, Ankara, 2006.
- Brunetti E, Kern P, Vuitton DA:** Expert consensus for the diagnosis and treatment of cystic and alveolar echinococcosis in humans. *Acta Trop*, 114, 1-16, 2010. DOI: 10.1016/j.actatropica.2009.11.001
- Deplazes P, Rinaldi L, Alvarez Rojas CA, Torgerson PR, Harandi MF, Romig T, Antolova D, Schurer JM, Lahmar S, Cringoli G, Magambo J, Thompson RCA, Jenkins EJ:** Global distribution of alveolar and cystic echinococcosis. *Adv Parasitol*, 95, 315-493, 2017. DOI: 10.1016/bs.apar.2016.11.001
- Sazmand A, Joachim A:** Parasitic diseases of camels in Iran (1931-2017) - A literature review. *Parasite*, 24, 2017. DOI: 10.1051/parasite/2017024
- Al Kitani FA, Al Riyami S, Al Yahyai S, Al Rawahi AH, Al Maawali M, Hussain MH:** Abattoir based surveillance of cystic echinococcosis (CE) in the Sultanate of Oman during 2010-2013. *Vet Parasitol*, 211 (3-4): 208-215, 2015. DOI: 10.1016/j.vetpar.2015.06.011
- Haridy FM, Ibrahim BB, Elshazly AM, Awad SE, Sultan DM, El-Sherbini GT, Morsy TA:** Hydatidosis *granulosus* in Egyptian slaughtered animals in the years 2000-2005. *J Egypt Soc Parasitol*, 6 (3): 1087-1100, 2006.
- Toulah FH, El Shafei AA, Alsalamy MN:** Prevalence of hydatidosis among slaughtered animals in Jeddah, Kingdom of Saudi Arabia. *J Egypt Soc Parasitol*, 42 (3): 563-572, 2012. DOI: 10.12816/0006341
- Al-Yaman FM, Assaf L, Hailat N, Abdel-Hafez SK:** Prevalence of hydatidosis in slaughtered animals from North Jordan. *Ann Trop Med Parasitol*, 79 (5): 501-506, 1985.
- Mbaya H, Magambo J, Njenga S, Zeyhle E, Mbae C, Mulinge E, Wassermann M, Kern P, Romig T:** *Echinococcus* spp. in central Kenya: A different story. *Parasitol Res*, 113 (10): 3789-3794, 2014. DOI: 10.1007/s00436-014-4045-z
- Boğa Kuru B, Aypak S, Aysul N:** Aydın yöresindeki köpeklerde *Echinococcus granulosus* yaygınlığının polimeraz zincir reaksiyonu ile belirlenmesi. *Türkiye Parazitoloj Derg*, 37, 78-83, 2013. DOI: 10.5152/tpd.2013.20
- Gökçen A, Adanır R:** Koyun ve Keçilerde Parazit Hastalıkları. In, Yukarı BA, Özcel MA (Eds): *Veteriner Hekimliğinde Parazit Hastalıkları*. 907-911, Türkiye Parazitoloji Derneği Yayın No: 24, Meta Basım, İzmir, 2013.
- Bekele T:** Epidemiological studies on gastrointestinal helminths of dromedary (*Camelus dromedarius*) in semi-arid lands of eastern Ethiopia. *Vet Parasitol*, 105 (2): 139-152, 2002. DOI: 10.1016/S0304-4017(01)00583-0
- Anwar M, Hayat CS:** Gastrointestinal parasitic fauna of camel (*Camelus dromedarius*) slaughtered at Faisalabad abattoir Pakistan. *Pak J Biol Sci*, 2 (1): 209-210, 1999. DOI: 10.3923/pjbs.1999.209.210
- El Bihari S:** Helminths of the camel: A review. *Br Vet J*, 141 (3): 315-326, 1985. DOI: 10.1016/0007-1935(85)90070-3
- Aypak S:** Develerin helmint enfeksiyonları. *Türkiye Parazitoloj Derg*, 31 (3): 225-228, 2007.
- Kassouha MA:** Prevalence of Gastro-Intestinal Helminthes of Camels in Syria. Thesis. Syrian Arab Republic, Al-Baath University Faculty of Veterinary Medicine Department of Microbiology, Syria, 2011.
- Banaja AA, Ghandour AM:** A review of parasites of camels (*Camelus dromedarius*) in Saudi Arabia. *JKSUS*, 6, 75-86, 1994.
- Parsani HR, Singh V, Momin RR:** Common parasitic diseases of camel. *Vet World*, 1 (10): 317-318, 2008.
- Abd El-Wahed MM:** Incidence of *Nematodirus* species and their differentiation through the infective third stage larvae among Egyptian camels. *J Egypt Soc Parasitol*, 35 (2): 447-450, 2005.