

Effect of Bovine Corpus Vitreum on Full-thickness Dermal Wound Healing: An Experimental Study in Rats ^[1]

Celal Şahin ERMUTLU ¹ Engin KILIÇ ¹ Özgür AKSOY ¹ Sadık YAYLA ¹ Vedat BARAN ¹
Serpil DAĞ ² Muzaffer Başak ULKAY ³ Uğur AYDIN ¹ Berjan DEMİRTAŞ ⁴

^[1] This study was supported by Kafkas University Scientific Research Project Commission (Project No: 2016-TS-44)

¹ Kafkas University, Faculty of Veterinary Medicine, Department of Surgery, TR-36100 Kars - TURKEY

² Kafkas University, Faculty of Veterinary Medicine, Department of Pathology, TR-36100 Kars - TURKEY

³ İstanbul University, Faculty of Veterinary Medicine, Department of Histology and Embryology, TR-34320 İstanbul - TURKEY

⁴ İstanbul University, Vocational School of Veterinary Medicine, TR-34320 İstanbul - TURKEY

Article Code: KVFD-2017-18189 Received: 10.06.2017 Accepted: 07.10.2017 Published Online: 09.10.2017

Citation of This Article

Ermutlu CŞ, Kılıç E, Aksoy Ö, Yayla S, Baran V, Dağ S, Ulkay MB, Aydın U, Demirtaş B: Effect of bovine corpus vitreum on full-thickness dermal wound healing: An experimental study in rats. *Kafkas Univ Vet Fak Derg*, 24 (1): 33-38, 2018. DOI: 10.9775/kvfd.2017.18189

Abstract

In this study, the effects of bovine corpus vitreum on wound healing were examined macroscopically and histopathologically. The study was carried out on 28 adult rats (*Rattus norvegicus*) weighing 150-300 g. Using general anesthesia, two separate wound excisions of 1 cm in diameter were formed in the right and left back halves of all rats. In the control group, the wound care was performed only by dripping serum over the wound daily. In the study group, the corpus vitreum obtained from newly cut healthy cows in the slaughterhouse was applied to the wound surface. All injuries were photographed using digital camera on days 1, 3, 5, 7, 9, 11, 13 and 15 and wound surface areas were compared. At the end of the first and second weeks, tissue samples taken from wound beds were examined histopathologically and the results were evaluated statistically. According to the wound surface area measurements and histopathologic results, corpus vitreum was found to have a positive effect on wound healing and a faster and more regular healing was achieved in the wounds compared to the control group.

Keywords: Bovine corpus vitreum, Wound healing, Rat

Sığır Corpus Vitreumunun Tam Katmanlı Dermal Yara İyileşmesi Üzerine Etkisi: Ratlarda Deneysel Bir Çalışma

Özet

Bu çalışmada sığır "korpus vitreum"unun yara iyileşmesi üzerine etkisinin makroskobik ve histopatolojik olarak araştırılması amaçlandı. Çalışma ortalama 150-300 g ağırlığında erişkin 28 adet sıçan (*Rattus Norvegicus*) üzerinde yürütüldü. Genel anestezi eşliğinde tüm sıçanların sol ve sağ sırt yarımında 1'er cm çapında iki ayrı eksizyon yarası oluşturuldu. Kontrol grubunda yaralara günlük olarak sadece serum damlatılarak yara bakımı gerçekleştirildi. Çalışma grubunda ise mezbahada yeni kesilen sağlıklı sığırlardan elde edilen korpus vitreum, yara yüzeyine tatbik edildi. Tüm yaralar 1., 3., 5., 7., 9., 11., 13. ve 15. günlerde dijital fotoğraf makinesi kullanılarak fotoğraflandı ve yara yüzey alanları karşılaştırıldı. 1. ve 2. haftanın sonunda yaralardan alınan doku örnekleri, histopatolojik açıdan incelendi ve sonuçlar istatistiksel olarak değerlendirildi. Yara yüzey alanı ölçümleri ve histopatolojik sonuçlara göre korpus vitreum'un yara iyileşmesine olumlu etkisinin olduğu ve uygulandığı yaralarda kontrol grubuna oranla daha hızlı ve düzenli bir iyileşmenin olduğu görüldü.

Anahtar sözcükler: Sığır korpus vitreumu, Yara iyileşmesi, Rat

INTRODUCTION

Healing of a wound, which occurs due to many reasons and is defined as the disruption of tissue integrity, comprises different successive processes such as bleeding and clot-scab formation period, inflammatory period, fibroplasia period, collagen period and epithelialization and maturation period ^[1-4]. It may be encountered

various complications in the treatment process and the most important local factor that hinders these processes is infection. Different methods and materials such as placenta, collagen gels, regional antibiotic and/or epithelial pomades, antiseptics, plant extracts, insulin and local electrical stimulation have been used all along for short term completion of the healing process ^[1-8]. The main use of these materials is to shorten the process but the



İletişim (Correspondence)



+90 546 2626007



sahinermutlu@hotmail.com

effect of each can be at different periods of the healing process.

Collagenase has a great importance in cell migration, is produced by epithelial cells or keratinocytes in the region at physiological pH and appropriate temperature and reaches a maximum level at day 5 [9,10]. In studies using collagen gels to accelerate healing in wound models that include all skin layers, it was observed that the wound healing process was completed in 11-15 days.

Hyaluronic Acid (HA), which is obtained directly or by isolation from cockscomb, spinal cord, skin, joint fluid and humor vitreous, is the simplest, sulphate-free member of the connective tissue protein group called glycosaminoglycan, and is actively involved in wound healing. HA, which undertakes the task of increasing the volume of vitreous fluid, also contributes to regeneration and tissue strength in the dermis and epidermis [11-13].

Vitreous is transparent, gel-like and has an extracellular matrix structure with heterogeneous viscoelastic character. Vitreous, which is around 98% water, chemically contains glycosaminoglycans, collagens, opticin, HA, chondroitin sulphate, heparan sulphate and proteoglycans. One of the important macromolecules of vitreous gel is HA and it was first isolated from cow vitreous in 1934. The other macromolecules it contains are type II (75%), hybrid type V/XI (10%), and type IX (15%) collagen fibrils. Therefore, vitreous is described as hyaluronan molecules interspersed between collagen webs [14,15].

It was reported that substances applied on wounds in order to create a humid environment better protects the vitality of the tissue by preventing wound dehydration, accelerates angiogenesis by enhancing proliferation ability of the cells and affects wound healing positively by increasing the efficiency of growth factors [16].

Bovine corpus vitreum is the ideal material containing both collagens and HA and this study focuses on its effectiveness on wound healing in experimental wound models.

MATERIAL and METHODS

The study was conducted after obtaining the approval of the Kafkas University Animal Experiments Local Ethics Committee (KAÜ-HADYEK/2016-046).

The animal material of the study was 28 adult rats (*Rattus norvegicus*) weighing an average of 225 g (150-300 g) obtained from the Kafkas University Experimental Animal Research Center. The rats were fed *ad-libitum* with standard rat pellet diet until the end of the study. Prior to the experiments, rats were allowed to adapt to the environment for a week. During the adaptation period and throughout the experiment, the rats were maintained

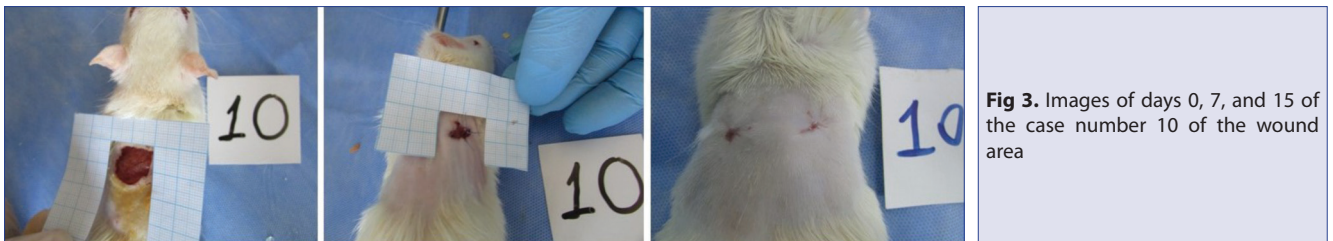
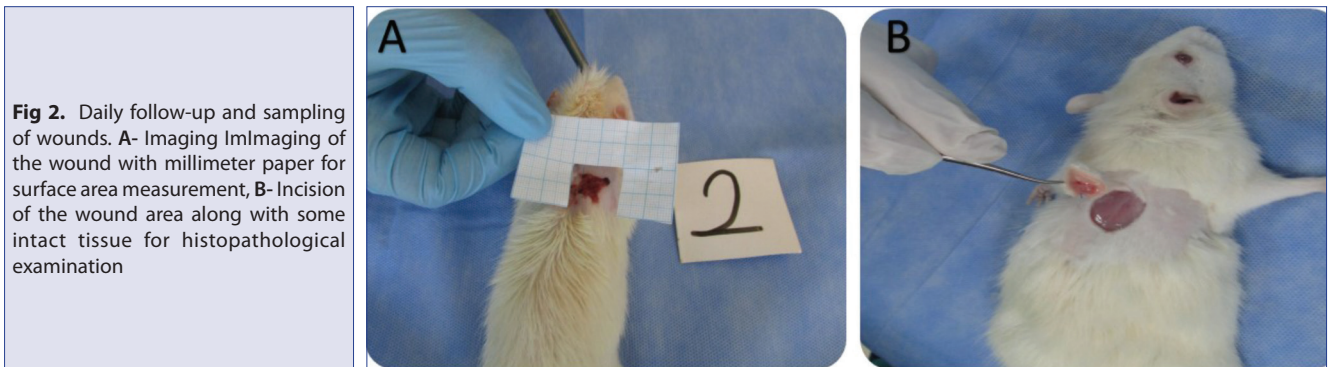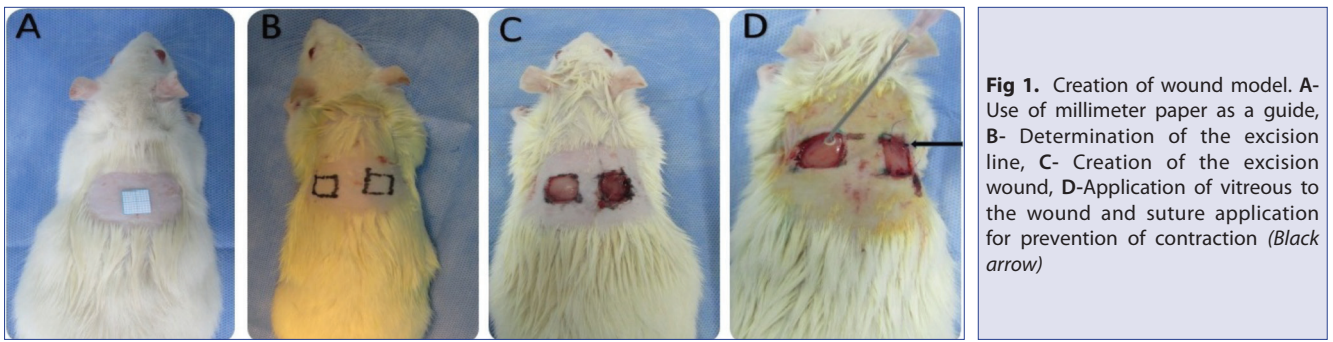
at 20-22°C constant temperature and 45-55% humidity, under a 12-h light and 12-h dark cycle.

Fresh corpus vitreum was collected daily by visiting the slaughterhouse. Immediately after the cattle were slaughtered, the corpus vitreum aspirated by entering the vitreous with a 20 gauge pink cannula under aseptic conditions. The obtained liquid-gel vitreous fluid was brought to the experimental animal research and application center as soon as possible. Attention was paid to repeat the applications every 24 h. In the control group, saline was administered simultaneously with the study group instead of vitreous fluid. This practice lasted for 14 days.

Two groups were formed with 14 rats in each group. After identifying Group I as experimental group and Group II as control group, each group was categorized as I A (right), I B (left), II A (right) and II B (left). The rats were starved for 12 h prior to the operation. Anesthesia with xylazine HCl (10 mg/kg IM, Rompun, BAYER) and ketamine HCl (100 mg/kg IM, Ketasol 10%, Richter pharma) was preferred for operations and operations were performed under aseptic conditions. Following anesthesia, the right and left regions of the rats' shoulders were shaved and aseptic conditions were maintained. While creating a wound, millimeter paper was used as a guide to ensure standardization of the surface areas (Fig. 1A). The wound margins were marked with previously prepared millimeter papers of 1 cm² in order to create wounds of equal size (Fig. 1B) and then a full thickness wound of 1 cm² in a square shape was created by the same operator by incising the skin on the right and left sides of the shoulder region of each rat in a way to include all skin thickness (Fig. 1C). To the wounds formed on the right side of each of rats (Group I A, Group II A), one simple interrupted suture was applied using absorbable 3-0 polyglactin-910 (vicryl) thread (Fig. 1D black arrow) to prevent surface contraction. To the wounds on the left side (Group I B, Group II B), no sutures were applied to prevent contraction. Thus, the wound on the left side of each rat was evaluated as the control of the right side. Fresh vitreous fluid was applied daily to cover the entire in Group I A and Group I B and the wounds were left open (Fig. 1D).

The wounds in all groups were imaged with millimeter paper using a digital camera (Fig. 2A) on days 1, 3, 5, 7, 9, 11, 13 and 15 (Fig. 3) to measure wound surface areas. Wound surface areas were measured using Stereo Investigator version 9 (MBF Bioscience U.S) image analysis program.

At the end of the 7th day, the final images of the wound areas were taken from the first 7 subjects in each group and the wound areas were fully excised in a way to contain some intact tissue (Fig. 2B). Obtained tissues were fixed in 10% buffered formalin solution for histopathological examination. The same procedure was carried out on the 15th day in the remaining rats.



Histopathology

On the 7th and 15th days of the study, tissue specimens fixed were routinely processed and embedded into paraffin blocks. Then sections with a thickness of 5 μ taken from the paraffin blocks were stained with hematoxylin eosin (HE) and Masson's Trichrome stain. The sections were evaluated under a light microscope for reepithelization, presence of necrosis, neutrophil granulocyte infiltration in the areas surrounding the necrosis, granulation, neovascularization, collagen accumulation, angiogenesis, inflammatory cell volume and new connective tissue formation. The normal distribution in the groups was examined by the Shapiro-Wilk test. The statistical comparison was made with Mann Whitney U Test.

Statistics

The data obtained from the wound surface area measurements were subjected to statistical evaluation using the Minitab 17 packet program. Each group was subjected to a test of normality. Because the groups were dependent and repeated measures were used, they were evaluated by variance analysis in repeated measures. Mean and \pm standard deviation values of the groups were

obtained. Values of $P < 0.05$ were considered statistically significant.

RESULTS

In the daily routine maintenance and control of rats, no adverse situations such as nourishment issues or indifference to the environment were encountered. There were no deaths in the groups and no infection or similar complications were encountered in wound areas. There was no evidence of serous accumulation or an allergic condition on the wound surface in response to the vitreous used in this stage.

When the wound surface areas in Group I A and Group II A were compared, it was determined that between the 5th-13th days, the healing in Group I A was faster and the difference was statistically significant ($P < 0.05$). There was also a significant difference ($P < 0.05$) between Group I B and Group II B from day 5, and wound closure in Group I B was faster. A significant difference ($P < 0.05$) between Group II A and II B on day 11 and a faster wound closure in Group II A was recorded also. The rate of healing in Group I B was statistically different than Group II A and II B on days

Table 1. The values of wound surface area of groups

Groups		1. Day (n=14)	3. Day (n=14)	5. Day (n=14)	7. Day (n=14)	9. Day (n=7)	11. Day (n=7)	13. Day (n=7)	15. Day (n=7)
Group I (cm ²)	A (right)	0.91±0.08 ^a	0.81±0.09 ^{ab}	0.69±0.12 ^a	0.52±0.12 ^a	0.34±0.05 ^a	0.10±0.04 ^a	0.02±0.01 ^a	0.00±0.00 ^a
	B (left)	0.92±0.02 ^a	0.77±0.07 ^a	0.63±0.06 ^a	0.47±0.06 ^a	0.31±0.02 ^a	0.18±0.01 ^a	0.02±0.01 ^a	0.00±0.00 ^a
Group II (cm ²)	A (right)	0.93±0.01 ^a	0.85±0.03 ^b	0.77±0.03 ^b	0.70±0.03 ^b	0.60±0.04 ^b	0.38±0.05 ^b	0.28±0.03 ^b	0.04±0.06 ^{ab}
	B (left)	0.94±0.02 ^a	0.88±0.02 ^b	0.81±0.01 ^b	0.75±0.02 ^b	0.67±0.03 ^b	0.52±0.05 ^c	0.29±0.02 ^b	0.07±0.05 ^b

^{a, b, c} different letters on each line show statistical differences ($P < 0.05$)

3, 5, 7, 9, 11 and 13 (Table 1). On day 15, the wounds in Group I were completely closed but the wound surfaces in Group II were not completely closed.

In all cases of Group I (Group I A and Group I B), the wound surface was almost closed on the 15th day and the new tissue formed in the healing area was similar to the intact tissue. In the control group (Group II A and II B), however, it was determined that the wound was prominently open. When the groups of rats with and without suture application were compared, there was no statistically significant difference ($P > 0.05$) between the groups except the 11th day.

Histopathological Results

It was evaluated reepithelization, presence of necrosis, granulation, neutrophil granulocyte infiltration, collagen accumulation, inflammatory cell volume, neovascularization, angiogenesis and ulcer formation.

In the 7th day evaluation of the specimens of the groups (Group I and Group II B) that were not sutured after excision and used as control groups, it was observed that the excision surface was covered with scab, re-epithelialization had started to form at the wound edges, granulation tissue was formed beneath the scab, and a large number of new capillary formation was present. None of the specimens showed any ulceration or inflammation of the dermis. In the 7th day evaluation of the specimens of the group (Group I A) that was sutured after excision and applied corpus vitreum, it was determined that reepithelization was started and neovascularization and fibrous tissue were formed. In the specimens of the group (Group I B) that was not sutured after excision and applied corpus vitreum, it was observed that the excision surface was covered with scab. Re-epithelialization had started to form, and presence of young granulation tissue with new capillary formation was detected in the excision area. Also; in all groups, there were capillary hyperemia and occasionally hemorrhage areas in some specimens.

Masson's Trichrome staining, which was performed to detect collagen distribution in the specimens of the control group and the experimental group (Group I A-B, Group II A-B) taken on the 7th day, showed that there was irregular collagen distribution in subepidermal regions along with new connective tissue formation and neovascularization

while collagen had not yet matured (Fig. 4 A,B,C). There were regular bundles of mature collagen present in deep dermis.

In the 15th day evaluation of the specimens of the group (Group II B) that were not sutured after excision, the wound surface was completely closed and the epidermis was observed to be normal. There was significant fibrosis in this group but a decrease in the number of vessels. The results observed in Group I A were similar to those in Group I B. Epithelization was incomplete on in one member of this group and there was granulation tissue, congested vessels and inflammatory cell infiltration in the dermis. In addition to these results, it was observed that epidermis was thicker in the groups treated with vitreous than the other groups and papillae extended to the dermis.

Masson's Trichrome staining, which was performed to detect collagen distribution in the specimens of all groups taken on the 15th day, showed similar results and fibrosis. Collagen synthesis was present and maturing was observed in the resulting fibrous tissue (Fig. 5 A,B,C).

DISCUSSION

A number of studies [1,2,5,7,8,19,20] have been carried out from the past to the present day on the completion of these cellular and biochemical phases in a shorter time by supporting the organism, thus reducing the risk of complications and achieving shorter healing. We also aimed to investigate the effect of bovine vitreous in wound healing in our study. The most basic reason for this is that biochemical structure of vitreous is formed by structural proteins such as glycosaminoglycans, collagens, opticin, fibrillin, and HA.

Cellular contraction movement, which takes place during cell proliferation stage following inflammation, one of the stages in the healing of open wounds with tissue loss, was reported to be effective 80% in closure of open wounds [6,18,19,22,24]. For acute and chronic wound models, rodents which are easy to maintain and feed, rapidly multiply and grow, and whose biological properties are well known are preferred, as in our work. However, as the link between skin and subcutaneous tissues is weak and *m. panniculus carnosus* leads to withdrawal of the wound easily, the wound is closed in a short time in these

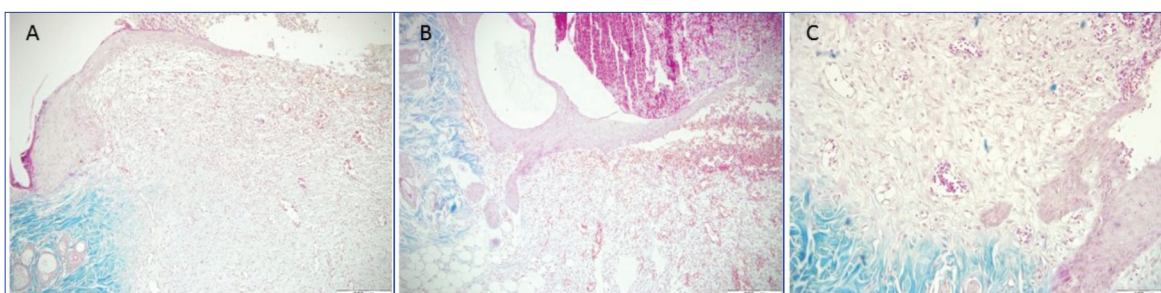


Fig 4. Histopathological view of the 7th day of the groups, Masson's Trichrom. **A-** Group II, day 7; Initiation of reepithelization, neovascularization and young granulation tissue, regular collagen fibers in bundles in the dermis, irregular collagen fibers that are not yet stainable in the newly formed fibrous tissue, Masson's Trichrom, Bar: 200 µm, **B-** Group I, day 7; Initiation of reepithelization, hyperemic vessels and bleeding, regular collagen fibers in bundles in the dermis, collagen fibers that are not yet stainable in the newly formed fibrous tissue, Masson's Trichrom, Bar: 200 µm, **C-** Group I B, day 7; Initiation of reepithelization, regular collagen fibers in the dermis, collagen fibers that are not yet stainable in the newly formed fibrous tissue, Masson's Trichrom, Bar: 200 µm

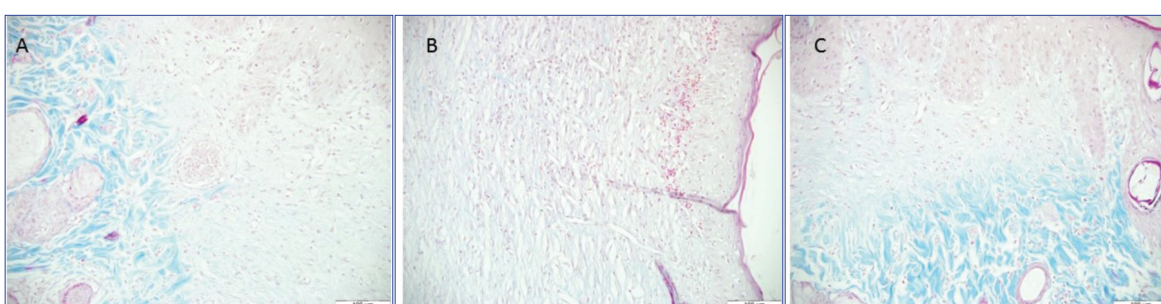


Fig 5. Histopathological view of the 15th day of the groups, Masson's Trichrom. **A-** Group II, day 15; Reepithelization, decrease in number of vessels in fibrous tissue, collagen fibers, Masson's Trichrom, Bar: 100 µm, **B-** Group I, day 15; Reepithelization, decrease in number of vessels in fibrous tissue, collagen fibers, Masson's Trichrom, Bar: 100 µm, **C-** Group I B, day 15; Reepithelialization, decrease in number of vessels in fibrous tissue, and maturation of collagen fibers, Masson's Trichrom, Bar: 100 µm

animals [1,18,23-25]. This leads to a failure to fully understand the effectiveness of the material used for healing. In this study, in order to prevent the effect of cellular movement (withdraw) in closing the wound surface, epidermis and dermal connective tissues of the square shape excisional wound were attached to muscular tissue underneath with simple interrupted sutures from four corners of the wound. So this method enabled to clearer understanding of effectiveness of corpus vitreum in wound healing.

HA is found in both the dermis and the epidermis layer, while it is present more densely in the dermis. Because of this, it is a good choice for dermal regeneration and strengthening. HA hydrogel films were reported to accelerate healing in full-thickness skin wounds [26]. It was reported that HA is effective particularly during the first stages of healing and the amount of HA in the tissue increases during the healing process [13]. Histopathologically, topical use of HA in wound healing was found to have a positive effect in cell proliferation and migration [27]. It was also reported that it increases epithelial cell migration and differentiation, decreases fibrosis and accelerates healing [13,27]. In the wound specimens examined histopathologically on the 7th and 15th days of the study, it was determined that the presence of reepithelization and young granulation tissue was more advanced than the control group. It was observed that the epidermis was thicker and sent

papillar extensions towards the dermis in the groups treated with vitreous compared control groups. It was also observed that collagen synthesis was present in the fibrous tissue that formed and began to mature. These results indicate that HA and collagen in corpus vitreum are effective at the cellular level in the process of healing and our findings are in parallel with similar studies in the literature in this respect.

In the histopathologic evaluation of Group I and Group II subjects on the 7th day, it was observed in all subjects whose wound surface was covered with scab, reepithelialization started at wound edges, granulation tissue was formed under the scab, and a large number of new vessel formations were present. In one case of Group I A, inflammatory cell infiltration was encountered in the suture area. The presence of neutrophil granulocytes and foreign body giant cells in the suture line was interpreted as a response of the organism to the suture thread. In both groups it was observed that there was an irregular collagen distribution but the collagen had not matured. On the 15th day of the study, histopathologic evaluations revealed that the epidermis was thicker and grew papilla extensions into the dermis in the vitreous group (Group I) compared to the control group (Group II). This result indicates that the healing of the wounds of Group I was more regular than that of Group II.

To establish a standard in the study and to ensure ease of application, vitreous fluid application was performed once a day. This biological material which was used by us for the first time for wound healing, different results may occur if it is used more than once in a day or in a longer time interval. But it is clear that there is a need for further work for this.

Although vitreous liquids are obtained from healthy cattle slaughtered in veterinary control slaughtered house, since the material in question is a material of liquid biological origin, it can be transferred mainly as prions, bacterial and viral origin. It must not be forgotten that there is a risk in terms of infectious diseases. However, since the study was an experimental nature and its primary purpose was to investigate the effect of vitreous fluid on wound healing, this fact was ignored. This biological material must be converted into a commercial for use clinical trials of different species. It may be possible to use it after the product passes different safety tests. Besides none of groups had any abnormal findings that could be evaluated in this context, mainly infection.

When the data obtained from the wound surface area measurements were evaluated, corpus vitreum was found to be more effective in wound healing compared to the control group. However, no statistically significant difference was observed between Group I A and Group I B and between Group II A and Group II B. This result suggested that the sutures applied to the contour of the wound area had a stimulating effect on the area and the healing could take place at the same speed without contractions. As a result, when both macroscopic and histopathological results were evaluated together, it was found that corpus vitreum had a positive effect on wound healing. The fact that this material is readily available and has low cost suggests that it can be used in wound healing in clinical practice. However, due to the fluid nature of the corpus vitreum, it was not able to hold on to the wound surface and it has been observed to flow out in a short time due to the effect of gravity. Thus contact time between the vitreous and the wound surface is reduced. The experience we have gained from our study made us conclude that if corpus vitreum is used in conjunction with a vaseline-like carrier, the effectiveness of this material may be further increased. However, it is also clear that there is a need for further work in which other carriers are evaluated to illuminate this matter.

REFERENCES

- Alkan Z:** Yara iyileşmesinin plasenta kullanılması ile hızlandırılması. *Ankara Üniv Vet Fak Derg*, 34 (3): 519-533, 1987.
- Alkan Z, Bilgili H, Baran V, Aydın Y, Bumin A:** Köpeklerde deri ensizyonlarının kapatılmasında skin stapler silk strip veagraf uygulamaları üzerine deneysel çalışmalar. 3. *Ulusal Veteriner Cerrahi Kongresi*, 25-27 Haziran, s.149-159, 1992, İstanbul, Türkiye.
- Anuk T, Öztürk S, Özaydın İ, Kahramanca Ş, Yayla S, Aksoy Ö, Okumuş Z, Aydın U, Bilgin BÇ, Demirhan İ:** Comparison of three fixation methods for the prevention of wound contractions in diabetic and non-diabetic mice with full-thickness skin excision. *Kafkas Univ Vet Fak Derg*, 22 (5): 647-651, 2016. DOI: 10.9775/kvfd.2015.14837
- Balazs EA:** Physiology of the Vitreous Body. In, Schepens CL (Ed): Importance of the Vitreous Body in Retinal Surgery with Special Emphasis on Re-operation. 29-57, The C.V. Mosby Company, St Louis, 1960.
- Kaya A, Bilgili H, Olcay B, Aydın Y:** Yara iyileşmesinde kullanılan çeşitli materyallerin iyileşme üzerindeki etkilerinin deneysel olarak araştırılması. *YYU Vet Fak Derg*, 2, 58-66, 1995.
- Özaydın İ, Aksoy Ö, Yayla S, Kılıç E, Sülü B, Yakın B, Bingöl SA, Deprem T:** Diabetik ve nondiabetik fare modellerinde doku kayıplı açık yara sağaltımında lokal insülin kullanımının myofibroblast aktivitesi üzerine etkisi. 13. *Ulusal Veteriner Cerrahi Kongresi*, 27 Haziran - 01 Temmuz, Sarıkamış, Kars, s.87-88, 2012.
- Sumano H, Goiz G, Clifford V:** Use of electrical stimulation for wound healing dogs. *Israel J Vet Med*, 57 (1): 31-37, 2002.
- Swaim SF, Lee HL:** Topical wound medications: A review. *JAVMA*, 12 (15): 1588-1592, 1987.
- Agren MS, Taplin CJ, Woessner JF, Eaglstein WH, Mertz PM:** Collagenase in wound healing: Effect of wound age and type. *J Invest Dermatol*, 99 (6): 709-714, 1992. DOI: 10.1111/1523-1747.ep12614202
- Ruszczak Z:** Effect of collagen matrices on dermal wound healing. *Adv Drug Deliv Rev*, 55, 1595-1611, 2003. DOI: 10.1016/j.addr.2003.08.003
- Özaydın İ, Özba B, Okumuş Z, Maraşlı Ş, Cihan M, Utlu N:** Atlarda tendinitis ve tenosinovitislerin sağaltımında hyaluronik asit kullanımı. *Kafkas Univ Vet Fak Derg*, 2 (2): 211-217, 1996.
- Preswich GD, Vercruyse KP:** Profiles therapeutic applications of hyaluronic acid and hyaluronan derivatives. *Pharm Sci Technol Today*, 1, 42-43, 1998.
- Tırnaksız F, Kaymak Y:** Hyaluronik asit. *Türkiye Klinikleri J Dermatol*, 18, 9-16, 2008.
- Mayne R:** The eye. In, Royce PM, Steinman B (Eds): Connective Tissue and Heritable Disorders. 131-141, Wiley-Liss, New York, 2002.
- Kerimoğlu H:** Medical (Pharmacologic) vitreolysis. *Ret Vit*, 18 (Suppl.), 37-41, 2010.
- Kumar S, Wong PF, Leaper DJ:** What is new in wound healing? *Turk J Med Sci*, 34, 147-160, 2004.
- Kılıçoğlu B, Kılıçoğlu SS, Eren VÇ:** Gastrointestinal sistemde yara iyileşmesi. *S.D.Ü. Tıp Fak. Derg*, 12 (1): 67-76, 2005.
- Koç B, Özaydın İ, Özba B, Ünsaldı E, Okumuş Z:** Doku kayıplı-gangrenli açık yaralarda lokal insülin ve pinch greft uygulamaları ile iyileşmenin hızlandırılması üzerinde klinik gözlemler. 2. *Ulusal Veteriner Cerrahi Kongresi Tebliğleri*, 60-65, 1-2 Ekim, Alata/Mersin, 1990.
- Thorey IS, Hinz B, Hoefflich A, Kaesler S, Bugnon P, Emlinger M, Wanke R, Wolf E, Werner S:** Transgenic mice reveal novel activities of growth hormone in wound repair, angiogenesis and myofibroblast differentiation. *J Biol Chem*, 279 (25): 26674-26684, 2004. DOI: 10.1074/jbc.M311467200
- Zcharia E, Zilka R, Yaar A, Yacoby-Zeevi O, Zetser A, Metzger S, Sarid R, Naggi A, Casu B, Ilan N, Vlodavsky I, Abramovitch R:** Heparanase accelerates wound angiogenesis and wound healing in mouse and rat models. *FASEB*, 19, 211-221, 2005. DOI: 10.1096/fj.04-1970com
- Davis RH, Leinter MG, Russo JM, Byrne ME:** Wound healing. Oral and topical activity of aloe vera. *JAPMA*, 79 (11): 559-562, 1989. DOI: 10.7547/87507315-79-11-559
- Sabol F, Dancakova L, Gal P, Vasilenko T, Novotny M, Smetana K, Lenhardt L:** Immunohistological changes in skin wounds during the early periods of healing in a rat model. *Int J Vet Biomed Sci*, 57 (2): 77-82, 2012.
- Werner S, Grose R:** Regulation of wound healing by growth factors and cytokines. *Physiol Rev*, 83, 835-870, 2003. DOI: 10.1152/physrev.00031.2002
- Hinz B:** Formation and function of the myofibroblast during tissue repair. *J Invest Dermatol*, 127, 526-537, 2007. DOI: 10.1038/sj.jid.5700613
- Özaydın İ:** Travmatik yaralar. In, Özaydın İ (Ed): Veteriner Acil Klinik: İlk Yardım, Transport, İlk Müdahale. 128-137, Eser Ofset, Erzurum, 2004.
- Necas J, Bartosikova L, Brauner P, Kolar J:** Hyaluronic acid (hyaluronan): A review. *Veterinarni Medicina*, 53 (8): 397-411, 2008.
- Maibach HI:** Hyaluronic acid and skin: Wound healing and aging. *Int J Dermatol*, 35, 539-544, 1996. DOI: 10.1111/j.1365-4362.1996.tb03650.x