

# The Anatomical and Histological Structures of Buzzard's (*Buteo buteo*) Small Intestine and Liver, and Immunohistochemical Localization of Catalase

Serap KORAL TAŞÇI <sup>1</sup>  Turgay DEPREM <sup>1</sup> Seyit Ali BİNGÖL <sup>2</sup> Yalçın AKBULUT <sup>3</sup>

<sup>1</sup> Department of Histology and Embryology, Faculty of Veterinary Medicine, Kafkas University, TR-36100 Kars - TURKEY

<sup>2</sup> Department of Histology and Embryology, Faculty of Medicine, Kafkas University, TR-36100 Kars - TURKEY

<sup>3</sup> Department of Anatomy, Faculty of Medicine, Kafkas University, TR-36100 Kars - TURKEY

Article Code: KVFD-2017-18333 Received: 30.06.2017 Accepted: 01.10.2017 Published Online: 03.10.2017

## Citation of This Article

**Koral Taşçı S, Deprem T, Bingöl SA, Akbulut Y:** The anatomical and histological structures of buzzard's (*Buteo buteo*) small intestine and liver, and immunohistochemical localization of catalase. *Kafkas Univ Vet Fak Derg*, 24 (1): 69-74, 2018. DOI: 10.9775/kvfd.2017.18333

## Abstract

This study aimed to examine the structure of the buzzard's *Buteo buteo* small intestine and liver, and the localization of catalase in those organs. Crossman's modified triple stain and Periodic Acid Schiff (PAS) stain were applied to the samples for histological examination. To detect catalase localization in the tissues, the avidin-biotin-peroxidase complex (ABC) technique was used. It was observed that the general histological structure of the buzzard's small intestine and liver was similar to that of other avian species. Catalase immunoreactivity in the lamina propria and submucosa in the small intestine were also observed, as well as catalase immunoreactivity in the hepatocyte cytoplasm in the liver. Some areas in the small intestine and liver had catalase immunoreactivity, which means that an antioxidant defence occurs in those areas.

**Keywords:** Antioxidant Enzyme, Buzzard, Catalase, Immunohistochemistry, Liver, Small intestine

## Şahin (*Buteo buteo*) İnce Bağırsak ve Karaciğerinin Anatomik ve Histolojik Yapısı İle Katalazın İmmunohistokimyasal Lokalizasyonu

### Özet

Bu çalışmada şahinlerin (*Buteo buteo*) ince bağırsakları ile karaciğerlerinin genel yapısı ve bu dokularda katalazın immunohistokimyasal lokalizasyonunun incelenmesi amaçlandı. Histolojik incelemeler için dokulara üçlü boyama ve periyodik asit Schiff (PAS) boyaması yapıldı. Dokulardaki katalaz enziminin immunohistokimyasal lokalizasyonunun belirlenmesi için Avidin-Biotin-Peroksidaz Kompleks (ABC) tekniği uygulandı. Şahin ince bağırsağı ve karaciğerinin genel histolojik yapısı incelendiğinde diğer kanatlı türlerine benzer olduğu görüldü. Katalaz immunoreaktivitesinin ince barsaklarda lamina propria ve submukoza katmanlarında, karaciğerde ise hepatositlerin sitoplazmalarında olduğu görüldü. Antioksidan bir enzim olan katalazın ince bağırsak ve karaciğerde belirtilen yerlerde olması bu bölgelerin antioksidan savunmanın gerçekleştiği yer olduğunu düşündürmektedir.

**Anahtar sözcükler:** Antioksidan Enzim, İmmunohistokimya, İnce bağırsak, Karaciğer, Katalaz, Şahin

## INTRODUCTION

The digestive system has many functions, such as digestion and absorption of nutrients, which are necessary for organisms <sup>[1]</sup>. The avian small intestine has three parts: the duodenum, jejunum and ileum, which makes it similar to that of mammals <sup>[2]</sup>. The duodenum arises from the upper right side of the gizzard and forms a u-shaped fold in all avian species. The jejunum, which is the longest part of the small intestine, is situated in the lower right

quadrant of the abdomen. The ileum, which is the shortest and thinnest part of the intestine, is located above the duodenum and below the rectum <sup>[3,4]</sup>. The structure of the avian intestine varies from one species to another. It is thought that those differences are based on varying diets in different species <sup>[5]</sup>. In carnivorous birds like the buzzard, the small intestine develops fully, but the cecum does not develop as well as the small intestine <sup>[6]</sup>. The wall structure of the small intestine in avians comprises tunica mucosa, submucosa, tunica muscularis and tunica serosa like that



İletişim (Correspondence)



+90 474 2426839/5298



serapkorah@hotmail.com

of mammals [5]. Tunica mucosa is formed by leaf-shaped intestinal villi and the crypts of Lieberkuhn, which is short, simple and open between the villi and has tubular ducts. The epithelium consists of a single layer which includes three types columnar cells: main epithelial cells, goblet cells and enterochromaffin cells. Lamina propria consists of loose connective tissue which contains blood and lymph vessels, nerves and lymphoid cells. The lamina muscularis is not well-developed, and consists of longitudinal muscle fibres. The submucosa consists of connective and elastic fibres. The small intestinal submucosa of avians is thin, and includes many diffuse and nodular lymphocytes. The tunica muscularis consists of an inner circular and an outer longitudinal smooth muscle. Tunica serosa is a thin layer of loose connective tissue [2,5,7]. The avian duodenum does not contain Brunner glands, unlike the mammalian duodenum, which does contain them [2,8].

The liver is situated in the upper right quadrant of the abdominal cavity as two lobes; these are the left and right lobes, and the right lobe is larger than the left. There is a parenchyma bridge between the two lobes, which are separated from each other by the cranial interlobar fissure at the front and the caudal interlobar fissure at the back [2,9]. The avian liver is similar to that of mammals in terms of histological features and functions. The structure of the interlobular septum and lobules are not seen in avian livers, but they are noticeable in mammalian livers [7,10,11]. However, each unit, which has central vein, is accepted as a lobule in avian livers [2]. In addition, there are no lymph nodes in avians (apart from some species), so there are lymph follicles and diffuse lymphoid tissue areas (lymphoid infiltration or ectopic lymphoid areas) in the liver, as in other organs (such as kidney, pancreas, gonads, thyroid and brain) [10,11]. Therefore it should not be taught those areas in avian species are caused only because of pathological reasons [7].

The digestive tract is always at risk of encountering pathogens, which cause various diseases, because it is directly open to the external environment. The effects of pathogens in the digestion system most probably affect other systems in an organism [12]. Reactive oxygen species, which are quite harmful for organisms, occur during normal functioning in the cell, or during inflammation caused by external pathogens in the digestive system. These harmful radicals cause various diseases. The organism protects itself against the harmful effects of reactive oxygen species with an antioxidant system, which includes antioxidant enzymes, such as catalase [13-15]. The amount of catalase in tissue, which protects the organism from harmful reactive oxygen species, is changeable [16].

This study aimed to investigate the anatomical and histological structure of the buzzard's liver and small intestine, as well as the immunohistochemical localization of catalase.

## MATERIAL and METHODS

This study was approved by the Local Ethics Commission of Experimental Animals of Kafkas University (KAÜ-HADYEK/2014-36) and the Turkish Republic Ministry of Forest and Water Management (General Directorate of Nature Conservation and National Parks [Approval no: 02.06.2015/119062]).

In this study, the small intestines and livers of four adult buzzards (*Buteo buteo*) were used. The livers were weighed with an electronic scale (0.01 g, SF-550), and the diameter and length of the small intestines were measured with an electronic caliper (0.01 mm, BTS). The nomenclature used in this study was consistent with the *Nomina Anatomica Avium* [17].

The samples for histological examination were fixed in a 10% formalin solution, following a routine histological process and then embedded in paraffin. Sections of 5 µm thickness were taken from paraffin blocks. Crossman's modified triple stain was applied to the sections to examine the histological structure of tissues [18], and Periodic Acid Schiff (PAS) stain was applied to detect glycogen-rich areas [19].

The avidin-biotin-peroxidase complex (ABC) technique was applied to determine immunohistochemical localization of catalase enzyme in tissues [20]. Sections taken from paraffin blocks were deparaffinized and rehydrated. Subsequently, 3% H<sub>2</sub>O<sub>2</sub> was applied to the sections to block endogenous peroxidase activity. The sections were incubated in citrate buffer (0.1 M, pH: 6.0) in the microwave (800 watt, 10 min) for antigen retrieval, and the samples were washed with phosphate buffer solution (PBS, 0.1 M, pH 7.2). After the samples had been incubated in the blocking buffer for 10 min, they were washed with PBS. Next, slides were incubated with anti-CAT (catalase) antibody (abcam, [ab1877], Cambridge MA, USA), which was diluted at 1:1000 for the liver and at 1:1500 for the small intestine, for an hour at room temperature, and they were then washed with PBS. Afterwards, biotinylated secondary antibody was applied to the samples for 30 min (Ultravision Detection System, Thermo Scientific, Fremont, USA). Then the samples were washed with PBS again and incubated with streptavidin horseradish peroxidase (Ultravision Detection System, Thermo Scientific, Fremont, USA) for 30 min. After washing the samples, DAB (Thermo Scientific, Fremont, USA) was applied to them. Negative control was used to determine specific catalase immunoreactivity, and hematoxylin stain was used as a nuclear counter stain.

## RESULTS

### Anatomical Results

During examination of the small intestines, it was observed that the duodenum arises from the upper right side of the

gizzard and forms a U-shaped fold. It was also observed that the jejunum was in the right side of the abdomen and that the ileum was above the upper side of the duodenum (Fig. 1). Measurements showed that the average length of the duodenum, jejunum and ileum were  $127.67 \pm 1.71$  mm,  $651.11 \pm 13.59$  mm and  $118.70 \pm 3.10$  mm, respectively, and their average diameters were  $4.79 \pm 0.39$  mm,  $5.08 \pm 0.62$  mm and  $3.93 \pm 0.45$  mm, respectively.

The anatomical examination also revealed that the liver comprised two lobes, which were the right and left lobes (Fig. 1). The average weight of the right lobe was  $8.11 \pm 0.29$  g after removal of the vesica fellea, and that of the left lobe was  $9.41 \pm 0.82$  g. The right and left lobes of the liver were separated from each other by two fissures, one of which was a deep cranial interlobar fissure at the front, while the other was a caudal interlobar fissure at the back. Inspection revealed that the diaphragmatic surface (parietal surface) was convex and the visceral surface was concave. A ventricular impression and cardiac impression were noticeable on both lobes of the liver.

### Histological Results

It was observed that the wall of the small intestine consisted of tunica mucosa, submucosa, tunica muscularis and tunica serosa layers (Fig. 2a). The epithelial laminae of the tunica mucosa were formed with single-layered of columnar cells and goblet cells were found between them. The lamina propria included diffuse lymphoid tissue. It was observed that the lamina muscularis extended into the intestinal villi as a smooth, thin muscular layer. The submucosa was seen

to be loose connective tissue, which included lymphoid tissue. The tunica muscularis had inner circular and outer longitudinal smooth muscle layers, and the tunica serosa was composed of loose connective tissue.

The lobules in the buzzard's liver were not noticeable when they were examined histologically because it was seen that there were no interlobular septum (Fig. 3a). Examination showed that in the case of hepatocytes, their edge was evident, surrounding the central vein, and there were also sinusoids between hepatocytes. The hepatic artery, interlobular vein and a bile duct were observed in the Kiernan space (portal field) in the liver. In addition, lymphoid areas were found in the liver (Fig. 3a).

A PAS positive reaction was detected in the goblet cells and in the submucosa of the small intestine (Fig. 2b). It was also observed in some hepatocyte cytoplasm and in some areas of connective tissue in the liver (Fig. 3b).

### Immunohistochemical Results

It was identified that there was cytoplasmic catalase immunoreactivity in the lamina propria and submucosa layers of the duodenum, jejunum and ileum during examination of the small intestine (Fig. 4a). However, this reaction was not found in the epithelial lamina and lamina muscularis layers in those parts of the small intestine (Fig. 4a,b). Some crypt epithelial cells had a very weak reaction, but no reaction in other parts of the crypts.

The catalase immunoreactivity in the liver was diffuse and granular in the hepatocyte cytoplasm (Fig. 5a,b). The reaction was generally in the cytoplasm, but in some hepatocytes, the reaction was seen in both the cytoplasm and nuclei. It was observed that the hepatocytes had varying degrees of immunoreactivity (Fig. 5b). There was no catalase immunoreactivity in the areas of connective tissue, endothelial cells, Kupffer cells and bile duct of the liver.

## DISCUSSION

The purpose of this study was to examine the anatomical and histological structures of the buzzard's small intestine and liver, and also the localization of an antioxidant enzyme catalase in these organs.

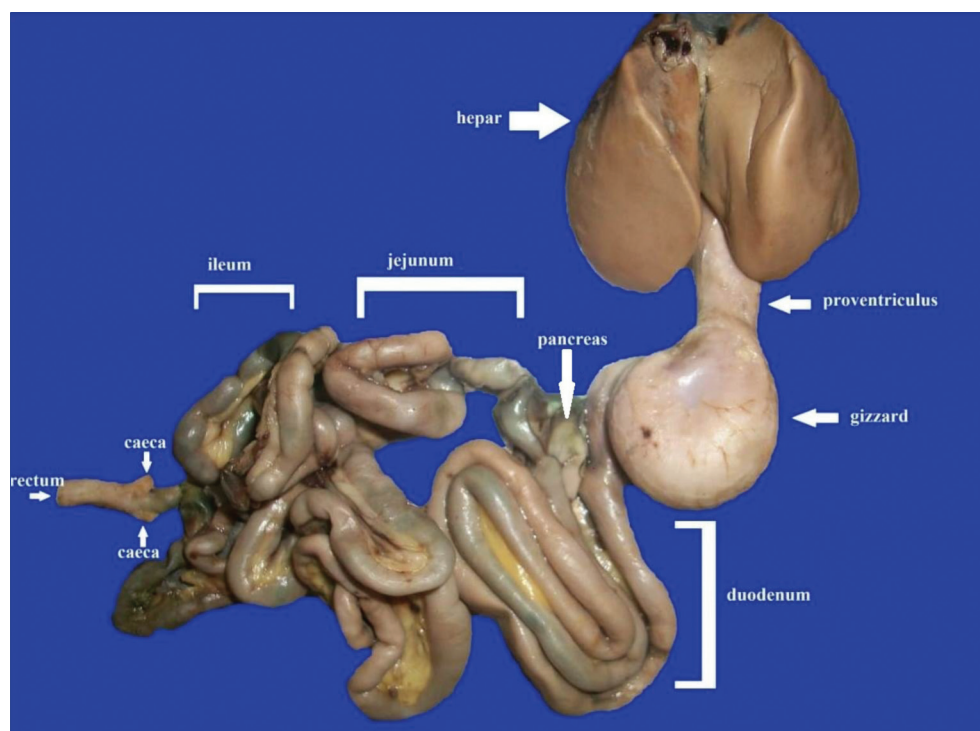
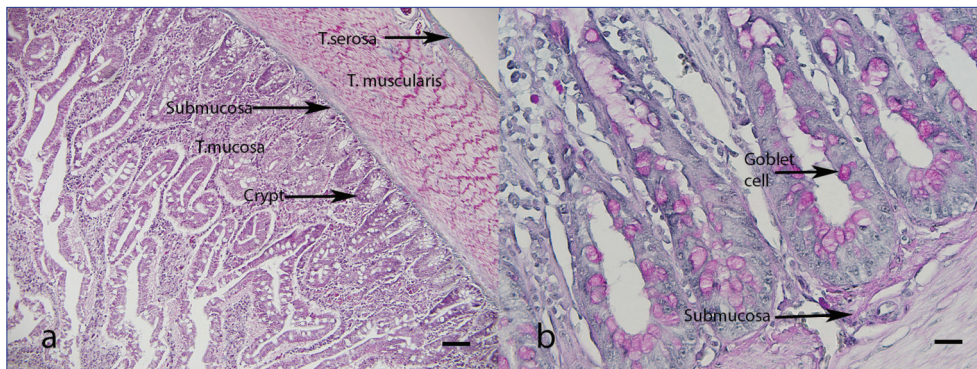
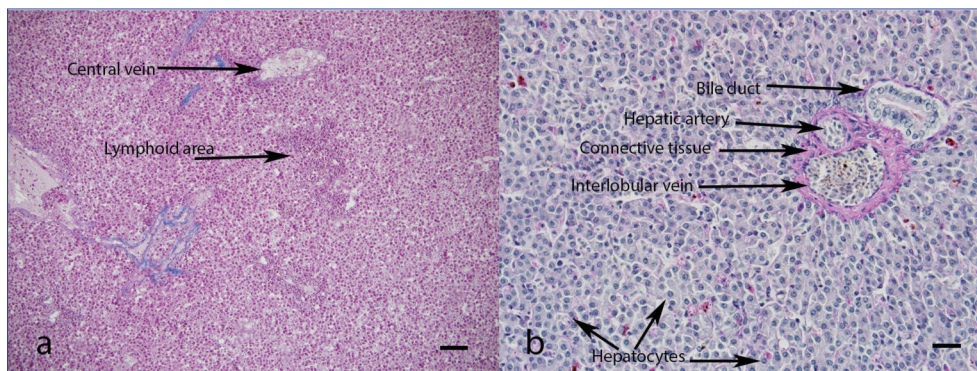


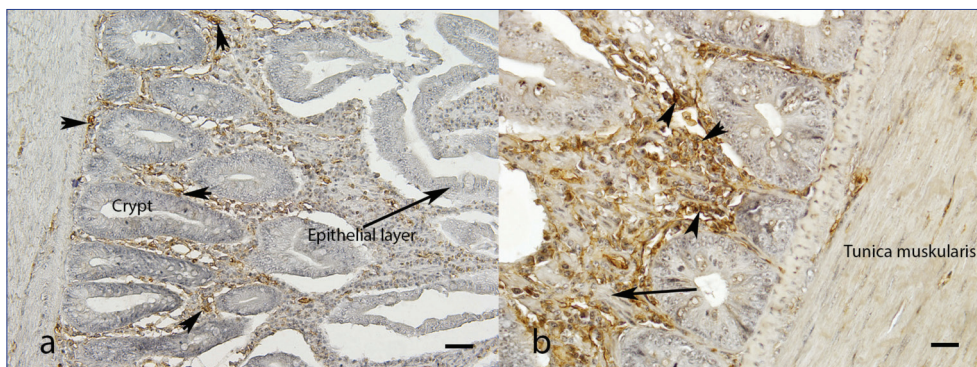
Fig 1. General view of Buzzard's digestive system



**Fig 2.** Small intestine. a- General view of small intestine, Crossman's modified triple staining, Bar: 200  $\mu$ m; b- PAS staining in small intestine, Bar: 50  $\mu$ m



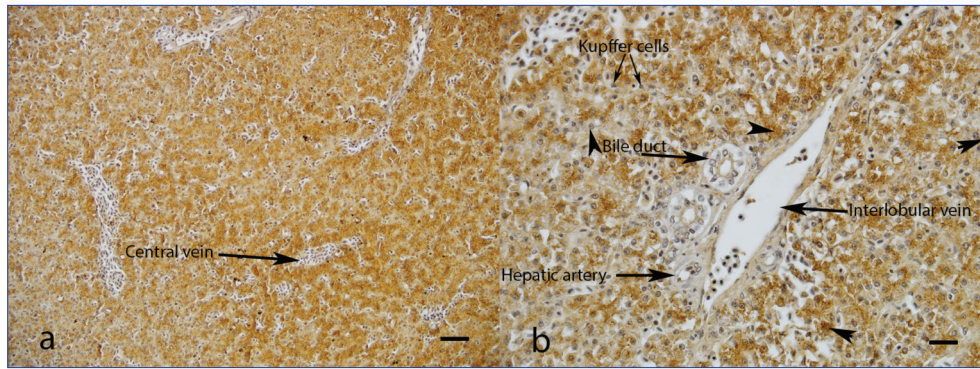
**Fig 3.** Liver. a- General view of liver. Crossman's modified triple staining, Bar: 200  $\mu$ m; b- PAS staining in liver, Bar: 50  $\mu$ m



**Fig 4.** Catalase immunoreactivity in small intestine. a- Arrow heads: catalase immunoreactivity, Bar: 100  $\mu$ m; b- Arrow: lamina muscularis, Arrow heads: catalase immunoreactivity, Bar: 50  $\mu$ m

The length and diameter of the small intestine vary from one species to another [2,21]. Anatomical examination of a buzzard's small intestine showed that the length and diameter of the duodenum, jejunum and ileum are similar to those of a pigeon [2,4]. The weight of the avian liver differs according to species, weight, race and diet [3,4]. It has been reported that the left lobe is larger than the right in chicken livers, but both are equal in turkey livers. Conversely, it has been noted that the right lobe is larger than the left in many avian species [3,4]. In this study, it was found that the left lobe was heavier than the right in the buzzard's liver.

During the histological examination, the wall of the small intestine comprised mucosa, submucosa, muscularis and serosa layers, and the structure of the epithelial cells, intestinal crypts and intestinal villi were similar to the data in the literature in terms of histological features that were consistent with other animals [2,7,22]. The absence of lobules in the liver, the hepatocytes surrounding the central vein, the structure of the portal triad in Kiernan's space and lymphatic tissue were in accordance with the existing literature [2,7,8,11]. In the current study, it was seen that there were lymphoid areas as infiltration in the



**Fig 5.** Catalase immunoreactivity in liver. **a-** Catalase immunoreactivity in liver, Bar: 100  $\mu$ m; **b-** Catalase immunoreactivity in liver, Arrow heads: catalase immunoreactivity in hepatocyte in various degrees, Bar: 50  $\mu$ m

liver. That finding is normal for tissues of avian species because lymphoid areas are seen as lymphoid follicles or lymphoid infiltration rather than lymphoid nodules [7,23,24]. The general histological features of the buzzard's liver and small intestine were basically similar to those of other avian species.

Kruidenier et al. [14] declared that catalase as an antioxidant enzyme in macrophages, and neutrophils in the lamina propria layer, prevented the harmful effects of  $H_2O_2$  in the small intestine of mammals. Dobashi et al. [25] reported that another antioxidant enzyme, glutathione peroxidase, had strong immunoreactivity in the lamina propria and weak immunoreactivity in the columnar cells, goblet cells and muscular layer in rats. The present study showed that catalase immunoreactivity was noticeable in the same parts of a buzzard's small intestine as those of rats. So, the present study's results were similar to those of Dobashi et al. [25]. Both these enzymes had a reaction in the same places in different species [14,25], which means that those parts of the intestines are important for antioxidant defence.

Morikawa and Harada [26] investigated immunohistochemical localization of catalase in mammals and announced that this enzyme showed granular staining in the cytoplasm of the hepatocytes. In the same study, they reported that there was no reaction in the nuclei of hepatocytes. Bingol et al. [27] stated that there was diffuse cytoplasmic immunoreactivity and positive reaction in some nuclei in the hepatocytes of goose liver. The present study showed that catalase immunoreactivity was diffuse cytoplasmic in hepatocytes, in line with the results of Morikawa and Harada [26], and Bingol et al. [27]. As mentioned earlier, there was no immunoreactivity in the connective tissue, bile ducts and endothelial cells in the present study.

It was concluded that the general histological structure of the buzzard's small intestine and liver were similar to those in other avian species. Some areas in the small intestine and liver had catalase immunoreactivity, which means that an antioxidant defence occurs in those areas. The current study has provided information about the general

structures of a buzzard's liver and small intestine, and it has also contributed to different studies about the antioxidant system in avians.

#### ACKNOWLEDGEMENTS

The authors would like to thank the Turkish Republic's Ministry of Forest and Water Management the General Directorate of Nature Conservation and the National Parks; and Wildlife Conservation, Recovery, Rehabilitation, Research and Application Centre of Kafkas University for their contributions.

#### REFERENCES

1. **Denbow DM:** Gastrointestinal Anatomy and Physiology. In, Scanes CG (Ed): *Sturkie's Avian Physiology*. 337-366, Academic Press, London, 2015.
2. **Karadağ H, Nur İH:** Sindirim Sistemi. In, Dursun N (Ed): *Evcil Kuşların Anatomisi*. 64-71, Medisan, Ankara, 2002.
3. **Taşbaş M:** Comparative macro-anatomic and subgross investigations on the digestive system of the hen-cock (*Gallus domesticus*) and the Turkey (*Meleagris gallopavo*). *Ankara Üniv Vet Fak Derg*, 25, 500-516, 1978. DOI: 10.1501/Vetfak\_0000000569
4. **King AS, McLellend J:** Birds: Their Structure and Function. Saunders, Bailliere Tindall, 1984.
5. **Hamdi H, El-Ghareeb A, Zaher M, AbuAmod F:** Anatomical, histological and histochemical adaptations of the avian alimentary canal to their food habits: II- *Elanus caeruleus*. *IJSER*, 4, 1355-1364, 2013.
6. **Niu H, Bu Y, Lu Q, Dong Z:** Morphological observation of digestive system of *Buteo buteo*. *J Henan Normal Univ (Natural Sci)*, 32 (3): 73-76, 2004.
7. **Hodges RD:** The Histology of the Fowl. Academic Press, London, 1974.
8. **Hill KJ:** The Structure of the Alimentary Tract. In, Bell DJ, Freeman BM (Eds): *Physiology and Biochemistry of the Domestic Fowl*. 1-22, Academic Press, London, 1971.
9. **Nickel R, Schummer A, Seiferle E:** Anatomy of Domestic Birds. Verlag Paul Parey, Berlin-Hamburg, 1977.
10. **Aslan Ş, Artan ME:** Histological changes on liver tissue of broilers fed with rations containing different rates of crude protein. *Istanbul Üniv Vet Fak Derg*, 22, 285-294, 1996.
11. **Gülmez N:** Sindirim Sistemi III. In, Özer A (Ed): *Veteriner Özel Histoloji*. 185-196, 2. Baskı. Nobel Yayın, Ankara, 2008.
12. **Yörük M:** Sindirim Sistemi II. In, Özer A (Ed): *Veteriner Özel Histoloji*. 161-184, 2. Baskı. Nobel Yayın, Ankara, 2008.
13. **Matés JM:** Effects of antioxidant enzymes in the molecular control

of reactive oxygen species toxicology. *Toxicology*, 153, 83-104, 2000. DOI: 10.1016/S0300-483X(00)00306-1

**14. Kruidenier L, Kuiper I, Van Duijn W, Mieremet-Ooms MA, Van Hogezaand RA, Lamers CB, Verspaget HW:** Imbalanced secondary mucosal antioxidant response in inflammatory bowel disease. *J Pathol*, 201, 17-27, 2003. DOI: 10.1002/path.1408

**15. Kruidenier L, Kuiper I, Lamers CB, Verspaget HW:** Intestinal oxidative damage in inflammatory bowel disease: Semi-quantification, localization, and association with mucosal antioxidants. *J Pathol*, 201, 28-36, 2003. DOI: 10.1002/path.1409

**16. Nishikawa M, Hashida M, Takakura Y:** Catalase delivery for inhibiting ROS-mediated tissue injury and tumor metastasis. *Adv Drug Deliv Rev*, 61, 319-326, 2009. DOI: 10.1016/j.addr.2009.01.001

**17. Baumel JJ, King SA, Breazile JE, Evans HE, Vanden Berge JC:** Handbook of Avian Anatomy. Nomina Anatomica Avium. 2<sup>nd</sup> edn. MA: Published By the Club, Cambridge, 1993.

**18. Bancroft JD, Cook HC:** Manual of Histological Techniques. Churchill Livingstone, Edinburgh, 1984.

**19. Luna LG:** Manual of Histologic Staining Methods of Armed Forces Institute of Pathology. Mc Graw-Hill Book Comp, New York, 1968.

**20. Hsu SM, Raine L, Fanger H:** Use of avidin-biotin-peroxidase complex (ABC) in immunoperoxidase techniques: A comparison between ABC

and unlabeled antibody (PAP) procedures. *J Histochem Cytochem*, 29, 577-580, 1981. DOI: 10.1177/29.4.6166661

**21. Gezer Ince N, Pazvant G, Kahvecioğlu KO:** Macro anatomic investigations on digestive system of Marmara Region sea gulls. *J Anim Vet Adv*, 9, 1757-1760, 2010. DOI: 10.3923/javaa.2010.1757.1760

**22. Dağlıoğlu S, Alp M, Armutak A, Fırat UB, Uğurlu S, Çörekçi İ, Aslan Ş:** Broiler yemlerine katılan antibiyotiklerin ince bağırsak üzerine histolojik etkileri. *İstanbul Üniv Vet Fak Derg*, 20, 327-340, 1994.

**23. Hassa O:** Tavukların Sindirim Sistemi Üzerinde Histolojik İncelemeler. Ankara Üniversitesi Basımevi, Ankara, 1961.

**24. Erençin Z:** Özel Histoloji (Mikroskopik Anatomi). Ankara Üniversitesi Basımevi, Ankara, 1963.

**25. Dobashi K, Asayama K, Hayashibe H, Munim A, Uchida N, Kawaoi A, Nakazawa S:** Immunohistochemical localization of cellular glutathione peroxidase in adult rat tissues by use of newly prepared polyclonal antibodies. *Yamanashi Med J*, 9, 69-79, 1994.

**26. Morikawa S, Harada T:** Immunohistochemical localization of catalase in mammalian tissues. *J Histochem Cytochem*, 17, 30-35, 1969. DOI: 10.1177/17.1.30

**27. Bingöl SA, Deprem T, Koral Taşçı S, Kocamış H:** Immunohistochemical localization of catalase in geese (*Anser anser*) liver. *Kafkas Univ Vet Fak Derg*, 17, 77-81, 2011. DOI: 10.9775/kvfd.2010.2423