

Histoanatomical Studies on the Fibrous Tunic of Eye in Dromedary Camel ^[1]

Mohammad Ali Ebrahimi SAADATLOU ¹ 

^[1] This study was granted by research deputy of Islamic Azad University, Tabriz Branch

¹ Department of Basic Sciences, College of Veterinary Medicine Tabriz Branch, Islamic Azad University, Tabriz, IRAN

Article Code: KVFD-2017-17976 Received: 03.05.2017 Accepted: 15.08.2017 Published Online: 31.08.2017

Citation of This Article

Karabag K, Alkan S, Mendes M: Histoanatomical studies on the fibrous tunic of eye in dromedary camel. *Kafkas Univ Vet Fak Derg*, 23 (6): 911-915, 2017. DOI: 10.9775/kvfd.2017.17976

Abstract

This study was conducted to understand the macroscopic and microscopic structures of the fibrous tunic of 20 healthy adult dromedary camel eyes. First, the fibrous tunic of the eye was anatomically examined in terms of appearance, dimensions, location and structure. Then prepared histological slides were studied microscopically after staining by H&E, Verhoeff, Trichrome masson's and P.A.S. The result showed that in the oval-shaped camel cornea, the internal angle is rounder than the external one. The average cornea length (lateral-medial), width (dorsal-ventral), and thickness were respectively measured as 2.91 ± 0.05 , 2.07 ± 0.04 , and 0.12 ± 0.05 cm. The thickest part of sclera is in the posterior pole of the eyeball. There was not any Bowman's membrane in camels. Descemet's membrane includes a rather even, pink, thick and shapeless membrane. Descemet's membrane is characterized with a very high positive P.A.S. reaction. Caudal endothelium of cornea did not show positive P.A.S. reaction and is observed in the form of a thin band attached to descemet's membrane. In the structure of sclera, the collagen fibers are remarkably thick, and the longitudinal and transverse cross sections are observed in the form of alternating layers. There were small elastic fibers in camel sclera. In anatomy, except for some differences, the cornea and sclera of the camel are similar to those of the other ungulates. Except for a little differences in Bowman's layer and descemet's membrane, it is similar to the fibrous tunic of the other animals.

Keywords: Dromedary camel, Eye, Fibrous tunic, Histoanatomy

Tek Hörgüçlü Devede Gözün Fibröz Tabakasında Histoanatomik Çalışmalar

Özet

Bu çalışma tek hörgüçlü 20 adet sağlıklı erişkin devede gözün fibröz tabakasının makroskopik ve mikroskopik yapılarını araştırmak amacıyla yapılmıştır. İlk olarak gözün fibröz tabakası anatomik olarak görünüş, boyut, yerleşim ve yapı bakımından incelendi. Sonrasında, hazırlanan histolojik kesitler H&E, Verhoeff, Masson'un üçlü boyası ve PAS ile boyanarak mikroskopik olarak araştırıldı. Oval şekilli deve korneasında iç açının dış açıdan daha yuvarlak olduğu gözlemlendi. Ortalama kornea uzunluğu (lateral-medial), genişliği (dorsal-ventral) ve kalınlığı sırasıyla 2.91 ± 0.05 , 2.07 ± 0.04 ve 0.12 ± 0.05 cm olarak ölçüldü. Skleranın en kalın yeri göz yuvarlağının posterior kutbuydu. Develerde Bowman membranı bulunmamaktaydı. Descemet membranı daha düz, pembe, kalın ve şekilsiz membrandan oluşmaktaydı. Descemet membranı çok fazla PAS pozitif reaksiyon ile karakterize idi. Korneanın kaudal endoteliumu PAS pozitif reaksiyon göstermezken, descemet membrana bağlı ince bir bant şeklinde gözlemlendi. Skleranın yapısında kollajen fibriller oldukça kalın olup longitudinal ve transversal kesitlerde yer değiştiren formlarda gözlemlendi. Deve sklerasında küçük elastik fibriller bulunmaktaydı. Anatomik olarak bazı farklar dışında devenin kornea ve sklerası diğer toynaklı hayvanlara benzerlik göstermekteydi. Bowman katı ve descemet membranındaki küçük farklar dışında devenin fibröz tabakası diğer hayvanlarınkine benzerlik göstermekteydi.

Anahtar sözcükler: Tek hörgüçlü deve, Göz, Fibröz tabaka, Histoanatomik

INTRODUCTION

Eye is one of the important sensory organs of the body which plays a very important role in communication between the living creatures and their environment ^[1,2].

Because of its importance and critical nature, a lot of researchers have focused their studies on this issue ^[3,4]. Anatomically finding, the eye is made up of three important layers, namely nervous, vascular and fibrous layers ^[2,5,6]. Eye is among the sensitive parts of the body that, its anterior



İletişim (Correspondence)



+98 413 6372274



anatomist2001@gmail.com

epithelium exposed to different types of threats, and it is examined in most illnesses for any probable changes in appearance [7,8]. Before studying the unnatural states of the eye, definitely we need to study its natural state and the different parts of the eye.

The eye of a one-humped camel looks like the eye of ruminants, especially cow. Most of the studies on the camel's anatomy between 1940 and 1970 have been conducted in some European and Arabian countries as well as India. A few studies have also been conducted on the anatomy of the camel's eye between 1980's and 1990's [9,10]. Some of the researchers have also studied the characteristics of the microscopic power of the camel's eye. For example, they have explicated that the adjacent parts of the camel's cornea is colored, the eyelid outgrowths are long, the eyelid have fissure, and the pupil of a camel's eye is oval in shape. Some researchers have studied the sensory receptors in the capsule of skeletal muscles in the camel's eye and have concluded that there are receptors in the muscles of a camel's eye, mostly located in the adjacency of the origin of the muscle; the elevator of upper eyelid has the most receptors in the sensory capsule [10,11]. In some animals, tapetum lucidum exists in the posterior wall of the eye hole. This layer is fibrous in some animals like equines and ruminants, but in some other animals like carnivores it is cellular; it also has the ability to reflect light; its color also varies across different animals [12,13]. Therefore, the present study is conducted with the purpose of understanding the macroscopic and microscopic structure of fibrous tunic of eye in one-humped camel.

MATERIAL and METHODS

In the present study, a total number of 20 eyes (right or left) [14] from 10 adult one-humped camels; 3-5 years old, 500 kg, prepared from Tabriz and Kerman slaughterhouse, were studied. First, the parts were anatomically studied for their appearance, dimensions, location and structure. Moreover, the dimensions were measured using calipers. Then for identifying their microscopic structure, fibrous tunic parts of the samples were cut and fixed in 10% formalin for at least 48 h. It is necessary to add that for complete fixation of the inner parts of the eye, 10%

Formalin was injected into the eyeball with a syringe. The tissue samples were prepared, and their slides were produced using the routine methods of histology. The histological slides were stained by a general H&E staining (for the general study of the tissue), three types of Verhoeff special staining (for studying the elastic fibers), Trichrome masson's (for studying collagen fibers and muscles) and P.A.S. (for studying the existence of carbohydrates and tissue glycogen). They were later studied with a light microscope [15-17].

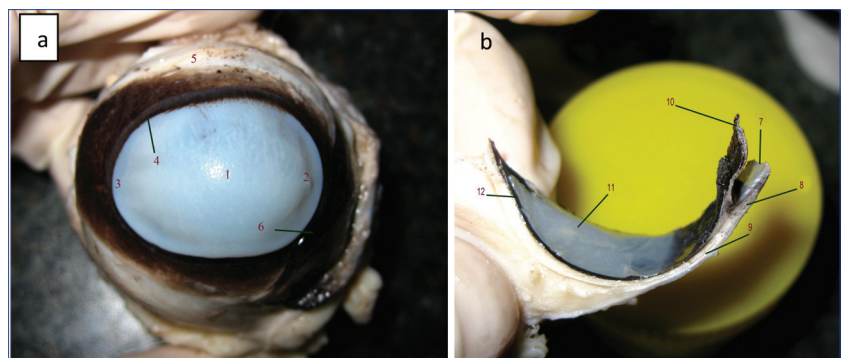
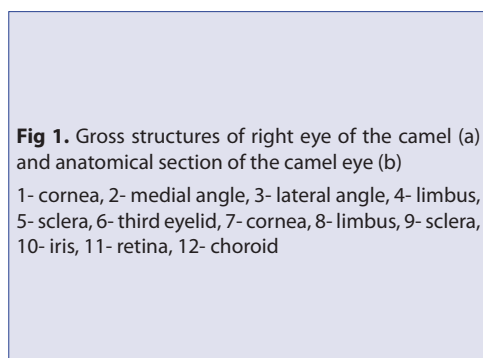
RESULTS

Anatomic Results

Cornea in a camel's eye is oval, but its medial angle is completely round, and its lateral angle is thinner and sharper (Fig. 1a). In its normal state, cornea looks transparent and bright. The average cornea length (lateral-medial), width (dorsal-ventral), and thickness were respectively measured as 2.91 ± 0.05 , 2.07 ± 0.04 , and 0.12 ± 0.05 cm. Moreover, the average cornea projection from the eyeball surface was 0.84 ± 0.02 cm, and the average width of the brown layer or the width of black limbus layer was obtained as 0.4 ± 0.0 cm. The eyeball that is seen in the form of a globe is made up of three layers, and it has vertical (dorsal-ventral), longitudinal (medial-lateral) and axial (anterior-posterior) diameters. Sclera is the thickest and most external layer of the eyeball and is basically white. Choroid and retina which are very fragrant, are packed together and located inside the sclera. The boundary between sclera and cornea is called limbus which has a black ring in its external surface; it is rather black in the parts adjacent to the cornea, but in the sclera area the blackness decreases (Fig. 1a). In camels, the thickest part of the sclera is along the eye axis, and it is thinner in limbus areas (Fig. 1b). In the limbus area, there is a projection of almost 0.2 cm towards the iris. The average dorsal-ventral, medial-lateral, and anterior-posterior thickness of the eyeball was respectively measured as 4.5 ± 0.05 , 4.52 ± 0.05 , and 3.32 ± 0.03 cm. The thickness of the eye's three layers was measured as 0.1 cm.

Histology Results

The anterior epithelium of the cornea consists of non-



keratinised stratified squamous epithelium in which 2 or 3 layers of the surface cells are squamous in shape, and the lower layers include cells with round nucleus which are condensed to each other (Fig. 2a). In the stroma of the cornea, the nucleus of the fibrocytes located in a thin form between the layers containing collagen fibers parallel to the corneal surface (Fig. 2b). Using the rows of the nucleus of the fibrocytes, the layers of the collagen fibers can be counted; in the present study 12 to 14 collagen layers were observed. The collagen fibers were observed in longitudinal and transverse cross sections. Descemet's membrane (posterior lamina) includes a nearly continuous thick shapeless layer with a dark pink color the thickness of which is 15 to 20 μm (Fig. 2b). The cornea's posterior epithelium includes a single layer of flattened cells that is separate from the posterior lamina. The intercellular borders of this epithelial layer are not clear. The nearest epithelium layer to the surface contains a thin positive P.A.S. reaction (Fig. 2c). Inside the cytoplasm of the epithelial cells under the nucleus, the crescent shaped parts of the cytoplasm shows positive P.A.S. reaction. These areas show remarkable increase in the depth of the epithelium, but in the basal layer (the first cell layer from the epithelium) the cytoplasm does not have the areas reacting to P.A.S. The basement membrane is observed with a considerable thickness under the anterior epithelium of cornea in the form of positive P.A.S. red band (Fig. 2c). In the corneal stroma, there are few areas reacting to P.A.S. coloring and are characterized by thin bands on collagen fibers. Descemet's membrane has the characteristic of high positive P.A.S. reaction and is observable in dark red (Fig. 2b). The posterior epithelium of the cornea does not have the characteristic of positive P.A.S. reaction and is observed in the form of a thin band

attached to descemet's membrane (light brown). In this coloring, the posterior endothelium is observed more distinctly. In Verhoeff coloring, the elastic fibers were observed among the collagen fibers of stroma (Fig. 2d). In the posterior part of the eyeball (from inside to outside), the pigmented epithelium (containing melanin particles) forms the nearest layer to the surface. The thickness of epithelium increases in the anterior part of the eye ball, and in this part a non-pigment cell layer is added. The non-pigment epithelium is in the shape of simple columnar at the beginning, but later it turns into simple cubic form. This two-layered epithelium continues with more folds in the anterior part. Under epithelium, the collagen fibers are located parallel to the epithelium, so in some parts of this thickness the blood veins are scattered in fewer numbers (Choroid layer). After that there is the structure of sclera in which collagen is considerably thick, and the longitudinal and transversal cross sections are observed in the form of alternating layers (Fig. 3a). Outside the sclera, connective tissue is loosed outwards and is covered with stratified cuboidal epithelium containing mucosal cells (conjunctiva) (Fig. 3a). The conjunctiva epithelium has more mucosal cells in the posterior part, and the anterior part is observed in stratified columnar or transitional form. The connective tissue under the choroid, especially a striped area just below the pigment epithelium, shows greater P.A.S. state. In sclera, the collagen fibers have less positive P.A.S. reaction (Fig. 3b) while greater P.A.S. reaction is observed between the eyeball's skeletal muscles and the connective tissue of the conjunctiva; the conjunctiva epithelium also has positive P.A.S. reaction.

There are fewer elastic fibers in the eyeball, and they are observed in fewer numbers only in the depth of

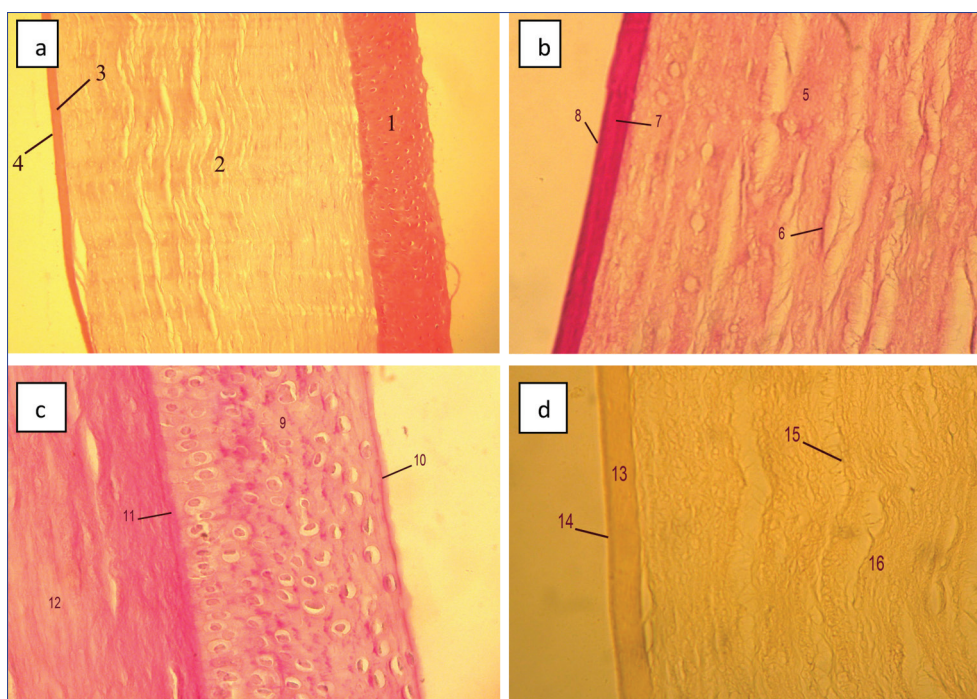


Fig 2. Photomicrograph of histological section of cornea in camel eye (H&E, $\times 100$; a), (H&E, $\times 400$; b), (P.A.S., $\times 400$; c) and (Verhoeff, $\times 400$; d)

1- Anterior epithelium, 2- stroma, 3- descemet's membrane, 4- posterior epithelium, 5- stroma, 6- fibrocyte, 7- descemet's membrane, 8- posterior epithelium, 9- anterior epithelium, 10- squamous cells, 11- basement membrane, 12- stroma, 13- descemet's membrane, 14- posterior epithelium, 15- elastic fibers, 16- stroma

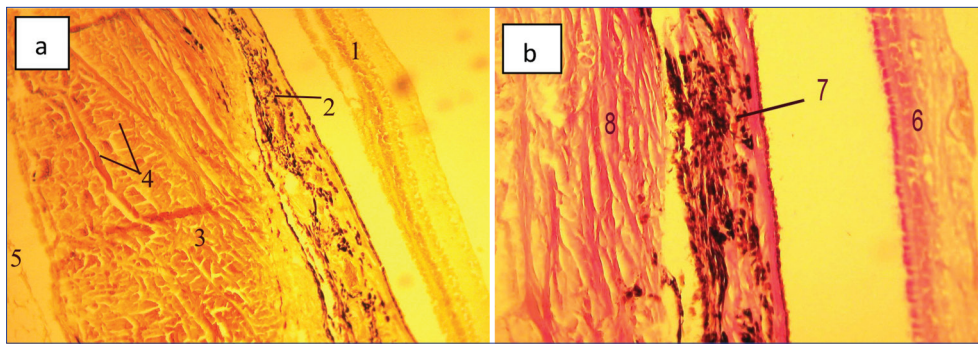


Fig 3. Photomicrograph of histological section of the eye in camel (Trichromemasson's, $\times 400$; a), (P.A.S., $\times 400$; b)

1- retina, 2- choroid, 3- sclera, 4- collagen fibers, 5- loose connective tissue, 6- retina, 7- choroid, 8- sclera

conjunctiva in the form of very thin fibers parallel to the collagen fibers. Choroid is located inside the sclera and contains pigment cells and blood vessels. The collagen fibers were observed in sclera and choroid, but they were not observed in retina (Fig. 3a). Moreover, the camel's sclera has less elastic fibers which are observed in the form of very thin fibers and are different from the collagen fibers.

DISCUSSION

Anatomic Discussion

According to the research results, the present study, conducted on the eye of camel, revealed that the cornea in camel's eye is oval in shape; the only difference is the fact that its medial angle is completely round, and its lateral angle is thinner and rather sharp. In equines cornea makes up one fifth of the eye's fibrous tunic, and it is transparent, colorless and without any blood vessels [17]. Moreover, in horse the cornea is oval, and its medial angle is flatter than its lateral angle [8]. The egg-like shape of cornea has also been reported in cow [25]. The average transverse diameter (dorsal, ventral) of cornea in camel's eye is 2.07 ± 0.04 cm while in cow it has been reported to be 2.5 cm [5,18]. In carnivores the thickness of the middle part of cornea has been reported to be more than the side parts (In the middle, the thickness is 0.1 cm, and in the sides it is 0.07 cm) [17]. As for other animals, cornea projection from the surface of eye ball is observed in camel too [8]. Corneal thickness, lens thickness and scleroretinal rim thickness increase with the advance of age in both buffaloes and camels [14,19].

The results show that the eyeballs of a camel are compressed in the anteroposterior axis. In other words, the length of the dorsoventral diameter of the eyeball is more than that of the anterioposterior diameter [15]. The same state has been reported in equine and large ruminant while in the carnivores the eye ball is completely global in shape [17]. In equine, four fifth of the eye ball is made up of sclera [17]. In cats and dogs, sclera is less thick along the eye axis, and is thicker in limbus areas or at the equator of the globe while in ungulates the thickest part of sclera is in the region of the optic nerve [17]. In dogs the average dorsal-ventral and medial-lateral diameter have been

reported as 2.1 and 2.0 cm respectively [12,17]. Even some studies have reported that the anterior-posterior diameter of the eyeball in carnivorous is more than the vertical diameter [17]. Generally, the eyeball of the birds is bigger than the other animals, though the birds have smaller bodies [8,17]. This was true of the adaptation to underground seen in some rodents which involved the thickness of the cornea, sclera and choroids [20].

Histologic Discussion

The main body of sclera in other animals looks like the dermis of the skin that includes a great amount of irregular dens connective tissue [1,16,17]. Scleral tissue was composed of compacted bundles of collagen fibers. These fibers tended to be rounder in outer regions of sheep eyes compared to inner regions [22]. In most of the animals the outer layer of sclera or episclera also consists of loose connective tissues that are very vascular and contain neural fibers [15]. The camel has the longest dorsal and ventral shelf followed by donkey, buffalo and cow. On the other hand, the medial and lateral shelves are longest in donkey and smallest in camel [23]. In most of the animals, at the point where the optic nerve passes through the sclera it becomes sieve like and is known as the scleral lamina cribrosa [8]. Abnormal tension in this region due to glaucoma results in the disruption of axoplasmic flow in individual nerve fibers of the optic nerve [17]. Such a cribrosal sheet is also observed in camels. Only the blood vessels feeding the retina are located in limbus area, and the retina, by itself, has no vessels [8,24]. Besides dens connective tissue, the sclera can be composed of cartilage as in birds [17]. When cartilage is found in the sclera, it usually forms a complete cup that extends to a ring of bony plates or scleral ossicles [17]. Although birds and reptiles possess this structure, the ossicle is believed to have originated from fish and were eventually passed on to amphibian [17]. Birds such as the kingfisher and other diving birds have larger and potentially more powerful ossicles than those species that tend to be more confined to land [17]. Owl and hawks have used them to produce elongated and cone-shaped eyes that have resulted in remarkable differences in the radii of curvatures between the cornea and globe [15,17]. In a functional sense ossicles are believed to have been devised for retaining ocular rigidity [8,17]. The bones have developed for strengthening

the eyeball, but this type of bones was not observed in the camel. In the other animals, the cornea epithelium has been reported to be of nonkeratinized stratified squamous type, containing 4-12 cell layers^[8,15]. The epithelial tissue of cornea in dogs, cats, and birds consists of one layer of basal cells with two or three layers of polyhedral (wing) or coin cells and 2 or 3 layers of nonkeratinized squamous cells^[21]. The bigger animals have more layers of wing and squamous layers^[21]. The anterior epithelium of cornea in carnivores is 25-40 nanometers, and in big domestic animals it is 2 to 4 times thicker^[1,8]. The cornea epithelium is thicker in the edges in comparison to the central parts, but in limbus area, it suddenly becomes thin^[17]. In primates, the Bowman's membrane or the anterior limiting lamina does not have any cells, and it is even with a thickness of 10-16 nanometers in human eye^[16]. It contains collagen fibers dispersed in different dimensions, and has an oblique path in the adjacency of lower segment^[25]. The Bowman's membrane is not formed in most animals, occurring in avian and human cornea as well as some cetaceans and the giraffe^[17]. Though it is considered part of the corneal stroma, it is formed by the anterior epithelium and is 10 to 15 nanometers thick, acellular, and composed of small highly organized collagen fibers^[17,25].

In camels, the epithelium constituted 36% of the camel cornea whereas corneal stroma constituted 62% of the corneal thickness^[25,26]. In most of the animals, the corneal stroma comprises 90% of the thickness of the cornea^[8]. It is ligamentous-like, consisting of transparent lamellae of dense regular connective tissue^[15]. In some animals, at the fine structural level, the descemet's membrane consists three regions: an anterior unbanded zone, an anterior banded zone, and a posterior unbanded zone has been reported^[15,26]. Descemet's membrane, is a homogeneous acellular membrane that is 10 to 15 µm thick in the dog and up to 30 µm thick in the horse^[17]. In most of the animals, this membrane is eosinophilic when stained with H&E and with PAS it stains brightly^[15]. This layer is a true basement membrane that is formed by endothelium membrane^[8]. In the other animals, the corneal endothelium contains a layer with cuboidal or polygonal cells and has covered the posterior surface of the cornea^[17]. In some animals the existence of hexagonal cells of this layer has been reported^[15].

In anatomy, except for some differences, the cornea and sclera of the camel are similar to those of the other ungulates. Except for a little differences in Bowman's layer and descemet's membrane, it is similar to the fibrous tunic of the other animals.

REFERENCES

- Banks W:** Applied Veterinary Histology. 3rd edn., 371-389, Mosby Year Book, USA, 1993.
- Dyce KM, Sae WO, Wensing CYG:** Text Book of Veterinary Anatomy. 4th edn., 323-336, Saunders Company, USA, 2010.
- Kassa A, Aogama M, Sugita S:** The morphology of the iridocorneal angle of buffaloes (*Bos bubalis*): A light and scanning electron microscopic study. *Okajimas Folia Anat Jpn*, 78 (4): 145-52, 2001.
- Abdo M, Hosaka YZ, Erasha A, Nada M, Ali S, Uehara M:** Prenatal development of the eye tunics in the dromedary camel. *Anat Histol Embryol*, 43 (4): 257-264, 2014. DOI: 10.1111/ah.12069
- Getty R:** Sisson and Grossman's Anatomy of the Domestic Animals. 5th edn., 224-244, 703-716, 1180-1204, 1741-1768, WB Saunders Co, USA, 1975.
- Sadler TW:** Langmans's Medical Embryology. 9th edn., 394-404, Wolters Kluwer, USA, 2012.
- Mc Geady TA, Quinn PJ, Fitz Patrick ES, Ryan MT:** Veterinary Embryology. 295-305, Blackwell Publishing, USA, 2006.
- Dellmann HD, Eurell J:** Textbook of Veterinary Histology. 6th edn., 350-363, Lea and Febiger, USA, 2006.
- Awkati A, Al-bagdadi E:** Lacrimal gland of camel (*Camelus dromedaries*). *Am J Vet Res*, 32 (3): 505-510, 1971.
- Abubl-atta A, Desantis M, Wong A:** Encapsulated sensory receptors within intraorbital skeletal muscle of a camel. *Anat Rec*, 247, 189-198, 1997. DOI: 10.1002/(SICI)1097-0185(199702)247:2<189::AID-AR5>3.0.CO;2-T
- Adogwa AO:** The oculomotor and trochlear nuclear in the one-humped camel. *Kaibogaka-Zaffhi*, 74 (2): 175-182, 1999.
- Prince JH, Diesem CD, Eglitis LR:** Anatomy and Histology of the Eye and Orbit in Domestic Animals. 756-758, Spring Filed, USA, 1960.
- Oliver FJ, Samuelson DE, Brooks PA, Lewis ME, Kallberg AM:** Comparative morphology of the tapetum lucidum (among selected species). *Vet Ophthalmol*, 7, 11-22, 2004. DOI: 10.1111/j.1463-5224.2004.00318.x
- Abuagla IA, HA Ali, ZH Ibrahim:** An anatomical study on the eye of the one-humped camel (*Camelus dromedarius*). *Inter J Vet Sci*, 5 (3): 137-141, 2016.
- Eurell JA, Frappier BL:** Dellmann's Textbook of Veterinary Histology. 6th edn., 350-363, Blackwell Publishing, USA, 2006.
- Junqueira LC, Carneiro J, Kelly R:** Basic Histology. 9th edn., 448-464, Appleton & Lange, USA, 2013.
- Samuelson DA:** Textbook of Veterinary Histology. 487-512, Saunders Elsevier, USA, 2007.
- Hifny A, Abdulla KEH, Aly KH, Kamel G:** Biometrical studies on the cornea in some domestic animals. *Anat Histol Embryol*, 34, 18, 2005. DOI: 10.1111/j.1439-0264.2005.00669_40.x
- Kassab A:** Ultrasonographic and macroscopic anatomy of the enucleated eyes of the buffalo (*Bos bubalis*) and the one-humped camel (*Camelus dromedarius*) of different ages. *Anat Histol Embryol*, 41, 7-11, 2012. DOI: 10.1111/j.1439-0264.2011.01097.x
- Liuch S, Ventura J, Lopez Fuster MJ:** Eye morphology in some wild rodents. *Anat Histol Embryol*, 37 (1): 41-51, 2008. DOI: 10.1111/j.1439-0264.2007.00796.x
- Hifny A, Mifk NA:** The anatomy of the tendon of insertion of the extrin muscle of the eyelash in the buffalo, coward camel. *Anat Histol Embryol*, 4, 339-346, 1977.
- Michael J:** Observations on the ultrastructure of equatorial scleral collagen fibrils in sheep eyes. *Vet Ophthalmol*, 15 (2): 71-80, 2012. DOI: 10.1111/j.1463-5224.2011.00938.x
- Abdolla KEH, Hifny A, Aly KH, Kamel G:** Biometrical studies on the sclera shelf in some domestic animals. *Anat Histol Embryol*, 34 (Suppl.-1): 2005. DOI: 10.1111/j.1439-0264.2005.00669_2.x
- Almohrad T, Khan F, Akhtar S:** Ultrastructural features of camel cornea. *Acta Ophthalmol*, 88, 246, 2012. DOI: 10.1111/j.1755-3768.2010.204.x
- Almohrad T, Akhtar S:** Ultrastructure features of camel cornea: Collagen fibril and proteoglycans. *Vet Ophthalmol*, 15, 36-41, 2012. DOI: 10.1111/j.1463-5224.2011.00918.x
- Almohrad T, Khan F, Akhtar S:** Ultrastructural features of camel cornea. *Acta Ophthalmol*, 88 (Special Issue): 204, 2010. DOI: 10.1111/j.1755-3768.2010.204.x