

Immunohistochemical Diagnosis of Pseudorabies (Aujeszky's Disease) in a Cow in Van, Turkey

Serkan YILDIRIM ¹  Cumali ÖZKAN ² Zabit YENER ³ Musa ÇETİN ⁴ Süleyman KOZAT ²

¹ Department of Pathology, Faculty of Veterinary Medicine, University of Atatürk, TR-25240 Erzurum - TURKEY

² Department of Internal Disease, Faculty of Veterinary Medicine, University of Yuzuncu Yil, TR-65080 Van - TURKEY

³ Department of Pathology, Faculty of Veterinary Medicine, University of Yuzuncu Yil, TR-65080 Van - TURKEY

⁴ Private Cetin Veterinary Clinic, TR-65100 Van - TURKEY

Article Code: KVFD-2016-16071 Received: 05.05.2016 Accepted: 21.06.2016 Published Online: 21.06.2016

Citation of This Article

Yıldırım S, Özkan C, Yener Z, Çetin M, Kozat S: Immunohistochemical diagnosis of Pseudorabies (Aujeszky's Disease) in a cow in Van, Turkey. *Kafkas Univ Vet Fak Derg*, 23, 173-176, 2017. DOI: 10.9775/kvfd.2016.16071

Abstract

Aujeszky's disease, also known as pseudorabies, is caused by an alphaherpesvirus that infects the central nervous system and other system. Disease was first recognized as a fatal viral disease of cattle and dogs in 1902. The natural infections have been reported worldwide in swine, cattle, dogs and variety of wildlife species in more recent years. The study material was a 5 years old cow which was brought with symptoms such as skin itching, weakness, convulsions, fever and neurological signs. As a result of the clinical examination the animal was suspected for Aujeszky's disease. Slaughter and necropsy were recommended. Subsequent to necropsy, tissues were fixed in formalin. Samples were evaluated histopathologically and immunohistochemically. According to the histopathological findings; diffuse, non-suppurative inflammation of brain, spinal cord and spinal nerves were determined. Brain lesions were detected commonly in cerebral and cerebellar cortexes. Grey and white matter were both affected. It was observed marked perivascular lymphoplasmocytic cell infiltration, glial cell proliferation, Hyperemia and hemoragia in veins in brain and light chromatolysis have been identified in some neurons. Intranuclear inclusions were observed in neurons. On the skin itching region of animal, serofibrinous inflammation in the dermis and subcutis was detected. According to the immunohistochemical findings; immunoperoxidase was detected strong positive in cytoplasm of both neurons and glial cells in areas with meningitis in brain. Consequently; after clinical, macroscopical and microscopical examination, this case was diagnosed as Aujeszky's disease. The aim of this study is presenting this disease immunochemically as it has never been reported in cattle in Turkey. We believe that it would be appropriate to present this case report since it is the first Pseudorabies case in cattle in Turkey.

Keywords: *Aujeszky's disease, Histopathology, Immunohistochemistry, Pseudorabies*

Van'da Bir İnekte Yalancı Kuduz (Aujeszky) Hastalığının İmmunohistokimyasal Teşhisi

Özet

Pseudorabies olarak da bilinen Aujeszky hastalığı, etkeni alphaherpesvirus olan ve merkezi sinir sistemi ile diğer sistemleri enfekte eden bir hastalıktır. Hastalık ilk olarak 1902 yılında sığır ve köpeklerde ölümcül bir viral hastalık olarak tanımlanmıştır. Hastalık yakın zamanda tüm dünyada domuz, sığır, köpek ve çeşitli yabani hayvanlarda bildirilmiştir. Bu çalışmanın amacı, Türkiye'de sığırlarda bildirimi olmayan bu hastalığı immunokimyasal olarak ortaya koymaktır. Çalışmanın materyalini, halsizlik, deride şiddetli kaşıntı, yüksek ateş, şiddetli konvulziyon ve sinirsel semptomlara sahip 5 yaşında bir inek oluşturdu. Klinik muayene sonucu hayvanda Aujeszky hastalığından şüphelenildi. Hayvana kesim ve nekropsi önerildi. Nekropsi sonrası alınan dokular formalinde fikse edildi. Dokular histopatolojik ve immunohistokimyasal olarak değerlendirildi. Histopatolojik olarak; beyinde spinal kortta ve spinal sinirlerde diffuz non-suppuratif meningoensefalitis belirlendi. Beyin lezyonları genellikle beyin ve beyincığın korteksinde belirlendi. Beyinde hem beyaz madde hem de gri madde etkilenmişti. Beyin damarlarında hiperemi, hemoraji, belirgin bir perivasküler hücre infiltrasyonu ve gliozis görüldü. Bazı nöronlarda hafif kromatolizis ve bazı nöronlarda ise intranükleer inklüzyonlar belirlendi. Ayrıca hayvanda kaşıntının olduğu bölgedeki derinin dermis ve subkutis katmanlarında serofibrinöz yangı tespit edildi. İmmunohistokimyasal olarak; meningeitisli bölgelerdeki nöronlarda, glia hücrelerinde ve bazı damar endotel hücrelerinde güçlü bir pozitiflik saptandı. Sonuç olarak; yapılan klinik, makroskobik ve mikroskobik muayenelerden sonra hastalığın Aujeszky hastalığı olduğu belirlendi. Türkiye'de bir sığırdan görülen ilk klinik vaka olmasından dolayı, vakayı sunmanın yararlı olacağını düşünmekteyiz.

Anahtar sözcükler: *Aujeszky's hastalığı, Histopatoloji, Immunohistokimya, Yalancı kuduz*



İletişim (Correspondence)



+90 532 0641810; Fax: +90 442 2317244



syildirim@atauni.edu.tr

INTRODUCTION

Pseudorabies or Aujeszky is a disease caused by herpesvirus. Disease is fatal in many wild and domestic animals such as cattle, sheep, goats, cats, dogs, horses and mainly in swines. It is also a zoonotic disease in humans. It is an acute viral disease characterized by central nervous system symptoms [1-7]. The disease in cattle is commonly referred as "mad itch" because of the severe pruritus [2]. In 1902, it was first detected by Prof. Dr. Aladar Aujeszky in cattle and dogs in Hungary, therefore it is named as Aujeszky's Disease. Disease was found in many countries and its incidence gradually increased [1,3-5,8-10].

In disease transmission, domestic and wild swines are common natural hosts and the main infection sources [2,3,6,8,11,12]. However, domestic and wild carnivores, eat infected carcasses and constitute important infection sources for other species. Besides, rodents such as mice and rats may also have roles in transmission. Disease is transmitted from swines to carnivores and rodents orally or through the air. In cattle, disease is transmitted by direct contact with swines or keeping the cattle together with them. Transmission occurs especially through the air. Although it is rare, rodents or biting flies may also cause infection [4-6,8,11-14].

Due to the neurotropic characteristic of virus, viral production occurs on the bitten site in small quantities and reach to brain through nerves. It produces intensely in brain and causes encephalomyelitis. Thus, it leads to death in a short time [7,11].

Clinically in cattle, symptoms such as severe local pruritus, intensely licking the pruritic location and rubbing desire of this location to places, biting, plucking its own flesh (automutilation) are reported. Besides, symptoms such as increase in body temperature, discomfort, continuous bellowing, whirling around, convulsions, opisthotonus are also seen [2,11,12,14-16].

Pruritus occurs commonly on hooves, head and chest regions where the viral contamination is the most possible. And death occurs due to paralysis in 6-48 h after the first clinical symptoms appear [11-15].

In order to perform certain diagnosis; medical history, clinical findings, hematological and biochemical parameters are not sufficient. For laboratory diagnosis, various direct and indirect tests are used (immunofluorescence, immunoperoxidase, PCR, virus neutralization, latex agglutination or ELISA). The most common diagnostic methods are immunofluorescence and immunoperoxidase [17]. As viral isolation is hard and time-consuming, immunoperoxidase is a mainly preferred method [9,11,14,17].

Even swine farms, wild swines and other infection resources are present in our country, there has never been a report according to this disease in cattle in our country. In

our case, according to the clinical findings we suspected of Aujeszky's Disease. Subsequent to histopathological and immunochemical examination the case was determined as Aujeszky's Disease. As this case is the first Aujeszky's Disease case in cattle in Turkey, we thought it might be useful to present this case report.

CASE HISTORY

Animal material of this case was a 5 years old crossbred cow in city of Van in Turkey. According to medical history received from animal owner; animal had several neurological symptoms, severe pruritus and it was biting the pruritic location along with having tendency to bite foreign materials. The feed given to the animal was obtained from a mountain village. There were too many mice in the stable. According to the clinical examination; Pseudorabies (Aujeszky's Disease) was suspected in animal. Blood samples were obtained in order to perform routine haematological and biochemical examinations. Approximately 12 h later; symptoms got more severe and the animal owner slaughtered the animal and necropsy was performed. Following necropsy; Brain, medulla spinalis, tonsilla, pharynx and skin tissue was obtained. Tissue samples were fixed in neutral buffered formalin and delivered to laboratory. In pathological examination, fixed tissue samples were processed routinely and embedded in paraffin. Then, thin sections were stained with hematoxylin-eosin (HE) for histopathological examination. The samples were examined in light microscope. Aujeszky disease antibody was detected by avidin-biotin immunoperoxidase complex method (ABC). The reagents were used of commercial origin [VMRD catalog no. 3G9F3].

According to the physical examination; body temperature (40°C), respiratory (65/min) and heart rate (110/min) were increased. Clinical findings such as loss of appetite, discomfort, perspiration, hypersalivation and tympani were found. Besides, severe pruritus on the front left leg was found and animal was licking the pruritic location and rubbing it on objects. Animal had automutilation on the pruritic region (Fig. 1A, 1B). They had neurological symptoms such as biting the foreign materials, teeth grinding (bruxism), convulsions and whirling around. According to routine haematological and biochemical parameters, WBC ($19.8 \times 10^9/L$) and serum CK (519 IU/L) values were determined as significantly increased, however other parameters were in usual reference values for cattle.

Erosions and ulcerations were found on the front leg skin due to severe pruritus and biting (Fig. 1A, 1B). At necropsy, no characteristic gross lesion was observed.

According to histopathological examinations of the obtained tissue from the pruritic regions of skin; widespread subcutaneous edema, erosions, hemorrhage and necrosis descending to muscles were determined (Fig. 1C). Diffuse, non-suppurative inflammation of brain, spinal cord and

spinal nerves were determined. Brain lesions were detected commonly in cerebral and cerebellar cortices. Grey and white matter were both affected. Marked perivascular lymphoplasmocytic cell infiltration, glial cell proliferation, hyperemia and hemorrhage were observed in brain veins (Fig. 2A, 2B, 2C). Light chromatolysis were identified in some neurons. Intranuclear inclusion bodies were determined in certain neurons (Fig. 2D).

According to immunohistochemical findings, immunoperoxidase reactivity was occurred in areas of meningitis. The cytoplasm of neurons, glial cells and some vascular endothelial cells showed strong positivity (Fig. 2E, 2F).

DISCUSSION

Pseudorabies or Aujeszky is a disease caused by herpesvirus. Disease is fatal in many wild and domestic

animals such as cattle, sheep, goats, cats, dogs, horses and mainly in swines. It is an acute viral disease characterized by central nervous system symptoms [1-7].

In our case; increase in body temperature, various neurological symptoms, severe pruritus particularly on front leg and itching the pruritic location as if going to pluck it, tendency of biting the foreign materials were observed. Symptoms in our study were similar to those reported in other studies [12,15].

As Aujeszky's disease can be confused with toxication and several disorders progressing with neurologic symptoms, making certain diagnosis is extremely important [14]. In order to make certain diagnosis medical history, clinical findings, hematological and biochemical parameters are not sufficient, therefore laboratory diagnosis, various direct and indirect tests should be also performed. The most

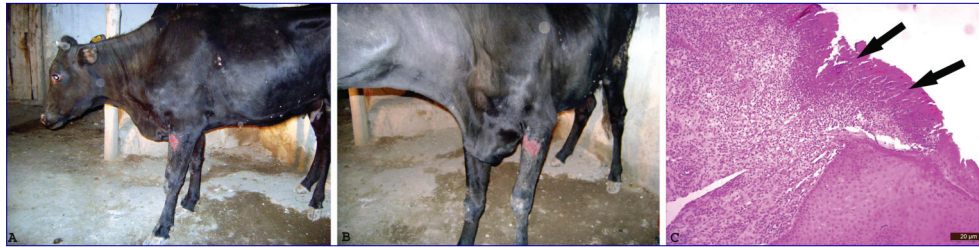

Fig 1. Severe pruritus in the front left leg and automutilation in animal (A, B), necrotic foci in skin (C), H&E, Bar: 20 µm

Şekil 1. Hayvanda sol ön bacakta şiddetli kaşıntı ve otomotilasyon (A, B), epidermiste nekrotik kitle (C), H&E, Bar: 20 µm

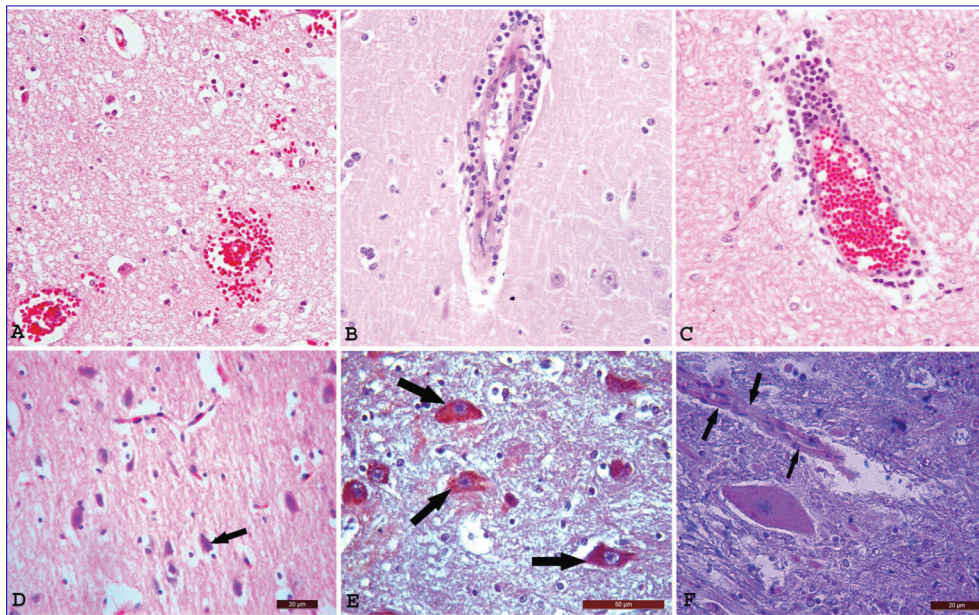


Fig 2. Hyperemia and hemorrhage in brain vein (A) and perivascular lymphoplasmocytic cell infiltration (B, C), intranuclear inclusion bodies in neurons (arrow) (D), H&E, Bar: 20 µm, cytoplasm of neurons (arrows) (E), Bar: 50µm, and vascular endothelial cells (arrow) demonstrated strong positive, immunoperoxidase (F, Bar: 20 µm)

Şekil 2. Beyinde hiperemi, hemoraji (A) ve perivasküler lenfositik hücre infiltrasyonu (B, C), nöronlarda intranükleer inklüzyon cisimciği (ok) (D), H&E, Bar: 20 µm, nöronlarda (oklar) (E, Bar: 50µm) ve damar endotel hücrelerinde immunperoksidadaz güçlü pozitiflik (oklar), (F, Bar: 20 µm)

common laboratory diagnostic methods are immunofluorescence and immunoperoxidase. As viral isolation is hard and time-consuming, immunoperoxidase is a mainly preferred method [9,11,17].

According to the immunohistochemical staining results of the obtained tissues, the cytoplasm of both neurons and glial cells showed strong positivity, thus certain diagnosis of Aujeszky's Disease was made. Histopathologic and immunohistochemical findings were similar to those previously reported [3,7,12,17].

Naturally, this disease is transmitted from swine to cattle. However in a previous study performed by Matsuoka et al. [3] Aujeszky's Disease was diagnosed in cattle living in a region which is close to a swine farm. Despite there are many case reports in many countries [2,3,15,17,18], there are not any reports in our country related to Aujeszky Disease in cattle. In our country the swine farms are rare and especially in our region there are not any swine farms. Therefore, this case report has importance as it is the first clinical case in our country and we thought that this disease might be transmitted from wild swine to cattle. In addition, the previous studies reported that wild animals and rats are also important for transmission [6,13]. We think that the transmission occurred due to mice and wild swine route because our case did not have direct contact with any domestic or wild swine and the feed was obtained from a mountain village and the stable had numerous mice. We diagnosed this case as Aujeszky Disease clinically, histopathologically and immunohistochemically.

As a conclusion; this is the first Aujeszky's Disease case in cattle in our country and there are not any swine farms in our city. We suggest that new studies should be performed related to this disease and veterinary practitioners should consider this disease during cattle examination.

REFERENCES

- Matsuoka T, Iijima Y, Sakurai K, Konosu Y, Tamiya K, Oki M, Arai N, Koda M:** Aujeszky's Disease in a dog. *Jpn J Vet Sci*, 50, 277-278, 1988.
- Beasley VR, Crandell RA, Buck WB, Ely RW, Thilsted JP:** A clinical episode demonstrating variable characteristics of pseudorabies infection in cattle. *Vet Res Commun*, 4, 125-129, 1980. DOI: 10.1007/BF02278490
- Matsuoka T, Iijima Y, Sakurai K, Koriyama T, Konosu Y, Tamiya K, Oki M, Haritani M, Imada T:** Outbreak of Aujeszky's Disease in cattle in Japan. *Jpn J Vet Sci*, 49, 507-510, 1987. DOI: 10.1292/jvms1939.49.507
- Schmidt SP, Pirtle EC, Hagemoser WA, Wages DP:** A necrotizing pneumonia in lambs caused by Pseudorabies virus (Aujeszky's Disease Virus). *Can J Vet Res*, 51, 145-149, 1987.
- Anonymous:** Pseudorabies (Aujeszky's Disease). http://www.penpages.psu.edu/penpages_reference/29801/2980122, Accessed: 15.10.2015.
- Richard E, Shope MD:** Experiment on the epidemiology of Pseudorabies, I. mode of transmission of the disease in swine and their possible role in its spread to cattle. *J Exp Med*, 62, 85-99, 1935.
- Marcaccini A, Pena ML, Quiroga MI, Bermudez R, Nieto JM, Aleman N:** Pseudorabies virus infection in mink: A host-specific pathogenesis. *Vet Immunol Immunopathol*, 124, 264-273, 2008. DOI: 10.1016/j.vetimm.2008.03.013
- Haddane B, Essalhi A:** An outbreak of Aujeszky's disease in the hunting dog (*Lycaon Pictus*). *European Association of Zoo-and Wildlife Veterinarians (EAZWV), Second Scientific Meeting*, May 21-24, 1998.
- Anonymous:** Aujeszky's Disease. http://www.oie.int/fileadmin/Home/eng/Health_standards/tahm/2.01.02_AUJESZKYS_DIS.pdf, Accessed: 15.10.2015.
- Lee JYS, Wilson MR:** A review of Pseudorabies (Aujeszky's Disease) in pigs. *Can Vet J*, 20, 65-69, 1979.
- Anonymous:** Aujeszky's Disease, the center for food security and public health, 2006. http://www.cfsph.iastate.edu/Factsheets/pdfs/aujeszkys_disease.pdf, Accessed: 15.10.2015.
- Schmidt SP, Hagemoser WA, Kluge JP, Hill HT:** Pathogenesis of ovine Pseudorabies (Aujeszky's Disease) following intratracheal inoculation. *Can J Vet Res*, 51, 326-333, 1987.
- Müller T, Teuffert J, Ziedler K, Possardt C, Kramer M, Staubach C, Conraths FJ:** Pseudorabies in the European wild boar from Eastern Germany. *J Wildl Dis*, 34, 251-258, 1998. DOI: 10.7589/0090-3558-34.2.251
- Kong H, Zhang K, Liu Y, Shang Y, Wu B, Liu X:** Attenuated live vaccine (Bartha-K16) caused Pseudorabies (Aujeszky's Disease) in sheep. *Vet Res Commun*, 37, 329-332, 2013. DOI: 10.1007/s11259-013-9568-8
- Szweda W, Janowski H, Grzechnik R, Brzeska E:** Aujeszky's Disease of cattle in the Olsztyn Province in years 1980-1991. *Med Weter*, 13, 947-957, 2006.
- Fukusho A:** Aujeszky's Disease of cattle in the Olsztyn Province in years 1980-1991. *JARQ*, 16, 131-135, 1998.
- Grieco V, Gelmetti D, Finazzi G, Brocchi E, Finazzi M:** Immunohistologic diagnosis of Pseudorabies (Aujeszky's Disease) using monoclonal antibodies. *J Vet Diagn Invest*, 9, 326-328, 1997.
- McCracken RM, McFerran JB, Dow C:** The neural spread of Pseudorabies virus in calves. *J Gen Virol*, 20, 17-28, 1973. DOI: 10.1099/0022-1317-20-1-17