

## Bladder Retroflexion in a Pointer Bitch During Pregnancy (Pointer Irkı Bir Köpekte Gebelik Sürecinde Karşılaşılan İdrar Kesesi Retrofleksiyonu)

Erhan ÖZENCİ<sup>1</sup>  Muhammed Kürşad BİRDANE<sup>1</sup>  
Mustafa Volkan YAPRAKÇI<sup>2</sup> İbrahim DEMİRKAN<sup>2</sup>

<sup>1</sup> Department of Obstetrics and Gynaecology, Faculty of Veterinary Medicine, Afyon Kocatepe University, TR-03200 Afyonkarahisar - TURKEY

<sup>2</sup> Department of Surgery, Faculty of Veterinary Medicine, Afyon Kocatepe University, TR-03200 Afyonkarahisar - TURKEY

Article Code: KVFD-2017-17521 Published Online: 24.02.2017

### Citation of This Article

Özenc E, Birdane MK, Yaprakçı MV, Demirkan İ: Bladder retroflexion in a Pointer bitch during pregnancy. *Kafkas Univ Vet Fak Derg*, 23 (3): 513-514, 2017. DOI: 10.9775/kvfd.2017.17521

### Dear Editor,

We would like to report a rare case of bladder retroflexion during pregnancy in a bitch.

A 4-year-old pregnant Pointer bitch was brought to Clinic of Obstetrics and Gynaecology Department, Faculty of Veterinary Medicine, Afyon Kocatepe University with the complaint of vaginal mass and dysuria. In patient's history, it was learnt that the bitch was mated 50 days ago. Owner also stated that the dog experienced a recent abdominal blunt trauma. On clinical examination, a protruded vaginal mass was observed (*Fig. 1a*). In ultrasonography, a large amount of anechoic image was seen in the prolapsed tissue. The abdominal ultrasonography revealed that the dog was pregnant but two fetuses were not viable. In addition, urinary bladder was not in normal position. Then it was decided to carry out ovariohysterectomy and to reduce the retroflexed bladder into normal position concurrently. Within two days after surgical intervention, the urinary bladder was retroflexed once again (*Fig. 1b*). A positive contrast cystourethrography was performed to reveal the bladder position (*Fig. 1c*). In the second surgery, cystopexy of the retroflexed urinary bladder to the right abdominal wall was performed (*Fig. 1d*). Ten days after the second surgery, the skin sutures were removed and no complications were observed (*Fig. 2*). After ten months following second surgery recurrence of the retroflexion was not detected.

Retroflexion of the urinary bladder has been documented in the first stage of parturation in a bitch<sup>[1]</sup>,

postpartum three weeks in a cat<sup>[2]</sup>, in the neutered bitch<sup>[3]</sup> and presence of follicular cyst in the ovary in a bitch<sup>[4]</sup>. Our literature search revealed that, there is one report of bladder retroflexion related to pregnancy and continuous barking<sup>[5]</sup>. However, our case differs from the study of Sontas et al.<sup>[5]</sup> since the retroflexion was associated with abdominal trauma leading to increased intra-abdominal pressure. One paper<sup>[6]</sup> describes urinary bladder retroflexion in two male dogs with a history of traffic accident. However, in our case the bladder retroflexion occurred in the bitch by blunt trauma.

To our knowledge, this case was the first report in the literature describing an increased intra-abdominal pressure related to abdominal trauma in a pregnant bitch. As a result, urinary bladder retroflexion must be correctly evaluated in pregnant bitch and cystopexy can be considered as one of the choice to prevent recurrence.

### REFERENCES

1. Canatan HE, Ergin I, Polat IM, Yazlık MO: Unusual cases of vaginal prolapse concurrent with cystocele in two dogs. *Revue Med Vet*, 166 (1-2): 43-46, 2015.
2. Risselada M, Kramer M, Van De Velde B, Polis I, Görtz K: Retroflexion of the urinary bladder associated with a perineal hernia in a female cat. *J Small Anim Pract*, 44, 508-510, 2003. DOI: 10.1111/j.1748-5827.2003.tb00112.x
3. Niles JD, Williams JM: Perineal hernia with bladder retroflexion in a female Cocker Spaniel. *J Small Anim Pract*, 40, 92-94, 1999. DOI: 10.1111/j.1748-5827.1999.tb03045.x
4. Ajadi TA, Ajayi OL, Adeniyi AA, Ajadi RA: Vaginal wall hyperplasia with fold prolapse in an eight-month-old Cane Corso dog. *Bulg J Vet Med*, 19 (3): 252-258, 2016. DOI: 10.15547/bjvm.917
5. Sontas BH, Apaydin SO, Toydemir TS, Kasikci G, Ekici H: Perineal



### İletişim (Correspondence)



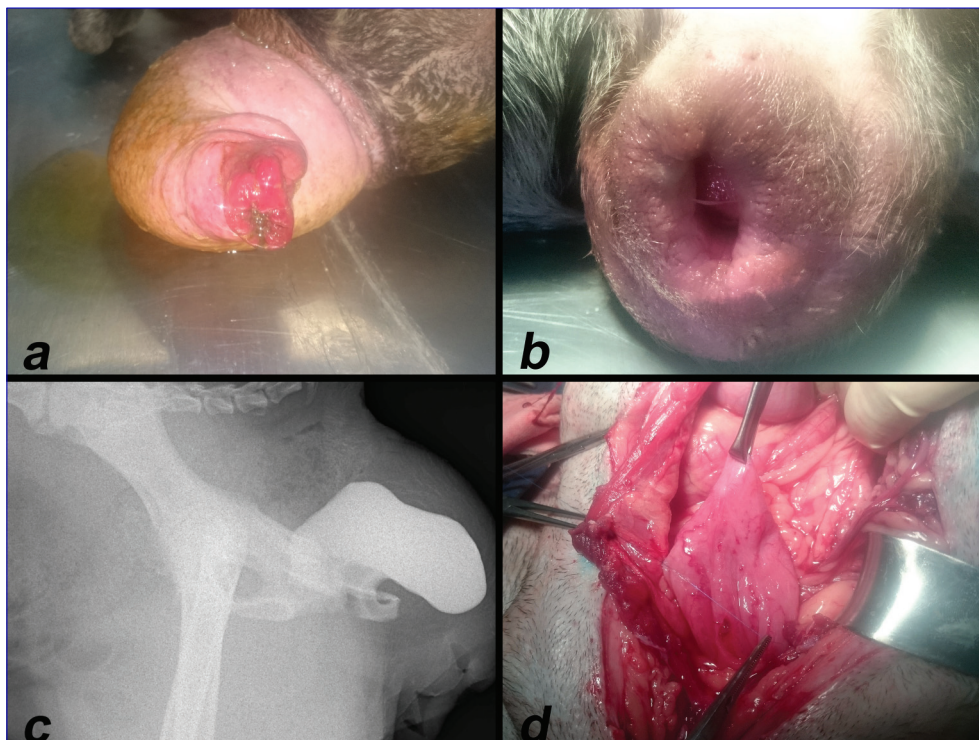
+90 272 2281312



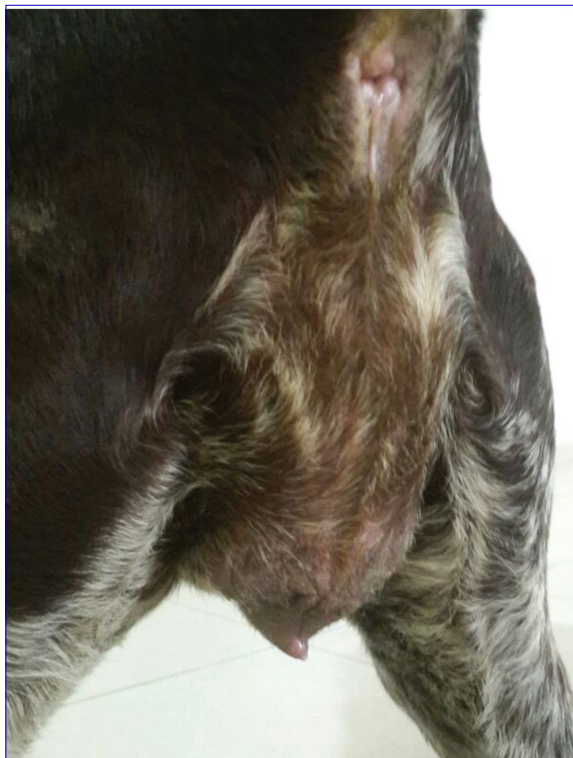eozenca@aku.edu.tr

hernia because of retroflexion of the urinary bladder in a rottweiler bitch during pregnancy. *J Small Anim Pract*, 49, 421-425, 2008. DOI: 10.1111/j.1748-5827.2008.00553.x

6. Lee H, Kang H, Kim M-S, Kim N, Lee K: Radiographic features of traumatically caused retroflexion of urinary bladder in two dogs. *J Vet Clin*, 25 (6): 553-556, 2008.



**Fig 1.** a- Prolapsed vagina in the pregnant Pointer bitch before the first surgery, b- Recurrence of the retroflexion before the second surgery, c- Positive contrast cystourethrogram (latero-lateral projection) d- Cystopexy



**Fig 2.** Ten days after the second surgery, full recovery was observed