

Surgical Treatment of Dorsal Scapular Luxation in Cats: Six Cases (2010-2016) ^[1]

Kürşat ÖZER ¹  Murat KARABAĞLI ¹ Haluk ÖMER ² Muhammet Eyüp DEMİR ³

^[1] Presented as oral presentation in 1st International Turkey Veterinary Surgery Congress, 11-14 May 2014, Erzurum-TURKEY

¹ Faculty of Veterinary Medicine, University of Istanbul, Department of Surgery, TR-34320 Avcılar, Istanbul - TURKEY

² Ambarlı District, Cumhuriyet Street, No:46, TR-34315, Avcılar, Istanbul - TURKEY

³ Ambarlı District, Doktor Sadik Ahmet Street, No:7/11, TR-34315 Avcılar, Istanbul -TURKEY

Article Code: KVFD-2016-17007 Received: 26.10.2016 Accepted: 29.12.2016 Published Online: 03.01.2017

Citation of This Article

Özer K, Karabağlı M, Ömer H, Demir ME: Surgical treatment of dorsal scapular luxation in cats: Six cases (2010-2016). *Kafkas Univ Vet Fak Derg*, 23 (3): 503-506, 2017. DOI: 10.9775/kvfd.2016.17007

Abstract

Dorsal luxation, avulsion or dislocation of the scapula is described as the dorsal displacement of the scapula, resulting from the rupture of the ventral serratus, rhomboideus and trapezius muscles. In this report, we aimed to suggest a different way for the surgical treatment of dorsal scapular luxation in cats. The study material comprised of 6 cats presented to our clinics. Intra-operatively, in all the patients it was determined that the ventral serratus and rhomboideus muscles were ruptured, however, the trapezius muscle was undamaged. In surgical intervention, cauterization of contact surfaces of two muscle to improve adhesion and suturing of serratus and rhomboideus muscles to infraspinatus and supraspinatus muscles was carried out respectively. In the clinical follow-up examination on post-operative day 15, dorsal luxation of the affected extremity during weight-bearing had completely disappeared in all of the patients. On the telephone consultation 2 months after operation, owners declared no complaints of lameness or recurrence of symptoms. In conclusion, the treatment model suggested in this study is quite simple and minimally invasive which could be applied in the treatment of the dorsal scapular luxation in cats.

Keywords: Scapula, Dorsal luxation, Avulsion, Serratus ventralis, Rhomboideus, Cat

Kedilerde Dorsal Skapular Lukzasyonun Cerrahi Sağıaltımı: Altı Olgu (2010-2016)

Özet

Skapulanın dorsal luksasyonu, avulzasyonu ya da dislokasyonu, m. serratus ventralis, m. rhombeideus ve m. trapezeus kaslarının rupturu sonucu skapulanın dorsale yer değıştirmesi olarak tanımlanır. Bu raporda, kedilerde dorsal skapular luksasyonun cerrahi sağıaltımı için farklı bir metot önermek amaçlanmıştır. Çalışmanın materyalini kliniğimize getirilen 6 kedi oluşturdu. Operasyon esnasında tüm olgularda ventral serratus ve rhombeideus kaslarının yırtıldığı ancak trapezeus kasının hasar görmediğı tespit edildi. Cerrahi müdahalede sırasıyla, temas yüzeyi bulunan iki kasın adezyonunu arttırmak için koterizasyonu ve serratus ve rhombeideus kaslarının, infraspinatus ve supraspinatus kaslarına dikilme işlemi gerçekleştirildi. Postoperatif 15. gün yapılan kontrolde hastaların tümünde basış esnasında ilgili ekstremitenin dorsale luksasyonunun tamamen ortadan kalktığı görüldü. Postoperatif 2. ay hasta sahipleriyle yapılan telefon görüşmelerinde hastaların hiçbirinde topallama şikayetinin ve nüks durumunun olmadığı öğrenildi. Sonuç olarak bu çalışmada, kedilerde skapulanın dorsal luksasyonu için önerilen sağıaltım modelinin, daha kolay uygulanabilir, daha az invaziv ve tercih edilebilir bir metot olduğu sonucuna varıldı.

Anahtar sözcükler: Skapula, Dorsal luksasyon, Avulzasyon, Serratus ventralis, Rhombeideus, Kedi

INTRODUCTION

The scapula is a flat bone located in the cranio-dorsal region of the lateral chest wall. This bone does not have a conventional joint with the torso, but is attached to the chest wall via a special arrangement of the muscles in the

area (synsarcosis) ^[1]. These muscles that attach the scapula and front legs to the chest wall are called the shoulder girdle muscles. The girdle muscles are classified as superficial and deep. The trapezius muscle is superficial, while the ventral serratus and rhomboideus muscles are deep muscles ^[2]. The girdle muscles are among those commonly subjected



İletişim (Correspondence)



+90 212 4737070/17298



ozar_kursat@yahoo.com

to avulsion in cases of dorsal scapular luxation ^[3,4].

Dorsal scapular luxation, avulsion or dislocation is described as the dorsal displacement of the scapula as a result of the rupture of the ventral serratus, rhomboideus and trapezius muscles ^[1,4]. This rare condition is more commonly observed in cats than in dogs and no breed or age predilection has been determined ^[4]. Dorsal luxations of the scapula occur in relation to jumps, falls or bite wounds. Within a few days following the injury, a distinct soft tissue swelling is apparent in the region ^[3].

On clinical examination, dorsal displacement of the scapula is clearly visible when the affected extremity is weight-bearing. Also, adduction of the extremity causes the scapula to be displaced laterally. Comparing the position with the sound side simplifies the diagnosis ^[4]. As well as clinical examination, radiological examination can be used in diagnosing patients with this condition. Conditions resulting from thorax trauma such as rib fractures, pulmonary contusions and pneumothorax can be evaluated with radiological examination. The rate of concurrent scapula fracture is low ^[5].

In the surgical treatment of this condition, the techniques used are: where possible, repairing the ruptured muscles by suturing, or circling the 5th, 6th or 7th rib with cerclage wire and threading this through a hole drilled in the caudal end of the scapula and fixing it. In some acute cases in cats and small dogs, despite reports of recovery by placing the extremity in a Valpeau sling and cage rest, surgical intervention has been reported as necessary for a satisfactory functional and cosmetic end result ^[3,5].

In the present study, the authors performed the surgical treatment and post-operative follow-up of 6 cases presenting with dorsal scapular luxation. The compiled outcome was intended to suggest a treatment model to overcome the negative aspects that could arise from fixing the scapula to the ribs.

CASE HISTORY

Of the cats included in this study, 5 were female and 1 was male which were brought to our clinic between 2010-2016, with a complaint of lameness. Breed distribution was; 1 Turkish Angora cat and 5 mixed breed. In only 1 of the patients (Turkish Angora) the age and history regarding etiology could be obtained. This was a 1-year old cat and dorsal scapular luxation had occurred due to falling from a height. The remaining 5 cats had been found in the street and presented to the clinic for treatment by their new owners. Therefore, no definite information could be obtained regarding either etiology or the age of the cats. Prior to the operation, the cats' teeth were examined and all were determined to be adult cats. Scapular luxation had occurred unilaterally in all the cases. While the Turkish

Angora cat had left-sided scapular luxation, 4 of the mixed breed cats had left-sided and 1 had right-sided scapular luxation.

On inspection, the scapula on the affected extremity was seen to displace dorsally during walking and weight-bearing (*Fig. 1a*). Neither walking nor orthopaedic examination elicited any pain response in the patients. When the related extremity was held at the elbow area and rotated laterally, the medial surface of the scapula was seen to detach laterally from the chest wall with ease (*Fig. 1b*).

Clinical examination did not reveal any swelling or ecchymotic areas on or around the scapula. None of the patients exhibited any respiratory distress or emphysema in the thorax region. In the radiological examination, while not encountering any scapular fractures, nor was there any evidence of atelectasis, emphysema or pneumothorax in the lungs. Pre-operative haemogram and serum biochemistry findings were normal in all the patients.

Patients were intubated following an induction with 4-6mg/kg IV propofol (Pofol®, Sandoz). Anaesthesia was maintained using 1.5-2.5% isoflurane (FORANE®, Abbott). Patients were placed in lateral recumbency with the affected extremity uppermost. The lateral thoracic wall was shaved up to the distal third of the humerus and the region was aseptically prepared.

A longitudinal skin incision was made along the caudal edge of the scapula (*Fig. 1c*). Intra-operatively, in all the patients it was determined that the ventral serratus and rhomboideus muscles were ruptured, however, the trapezius muscle was undamaged. After that, latissimus dorsi and trapezius muscle was incised at the level of the caudal edge of the scapula, exposing the medial surface of the scapula and the thorax wall (*Fig. 1d*). The proximal ends of the ventral serratus muscle were located. Since the patients had been presented in the chronic period, the proximal ends of this muscle were covered with granulation tissue. In the first stage of surgical treatment, in order to increase post-operative tissue adhesion, several different points were cauterized on the subscapular and ventral serratus muscles, which have a contact surface on a non-luxated scapula (*Fig. 1e*). Following this, the ruptured section of the ventral serratus muscle was pulled across the lateral surface of the scapula and sutured to the supraspinatus and infraspinatus muscles using the horizontal mattress suture technique. Similarly, the rhomboideus muscle was pulled over the scapular cartilage and sutured to the infraspinatus muscle using the horizontal mattress suture technique (*Fig. 1f,g*). The incised portion of the trapezius muscle, connective tissue and skin was closed using the simple interrupted suture technique. For all sutures, 2/0 monofilament absorbable suture material was used. The extremity was kept in a Valpeau sling for 1 week and the patient's movements were restricted for 15 days (*Fig. 1h*).

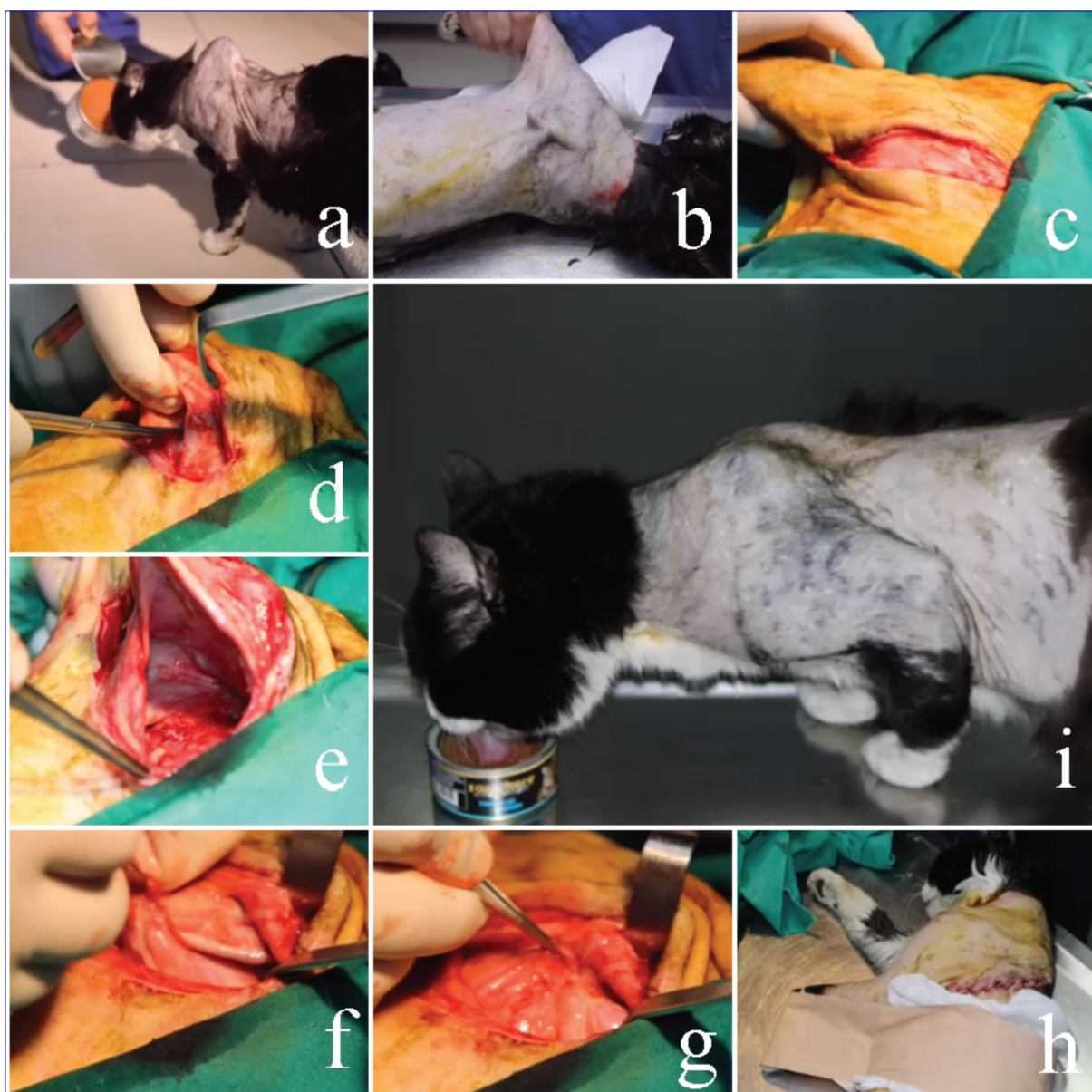


Fig 1. Preoperative-postoperative appearance of a patient during weight bearing and surgical treatment process. Preoperative appearance of dorsal scapular luxation, **a**; lateral rotation of effected limb and lateral displacement of scapula, **b**; longitudinal skin incision along the caudal border of scapula, **c**; incision of undamaged latissimus dorsi and trapezius muscles, **d**; post-cauterization appearance of the subscapularis and serratus ventralis muscles, **e**; pulling the ventral serratus muscle across the lateral surface of the scapula in order to suture to the supraspinatus and infraspinatus muscles using the horizontal mattress suture technique, **f-g**; postoperative Valpeu sling application, **h**; and postoperative 15th day appearance of the patient during weight bearing, **i**

The patients were re-examined on post-operative day 15 and discharged. Presence of dorsal scapular luxation was not determined by inspection (*Fig. 1i*) in all of the patients, while palpation was used to assess lateral movement of the scapula. Two months later, the patient owners were contacted by telephone and information regarding their latest condition was collected.

In the follow-up examination on post-operative day 15, dorsal luxation of the affected extremity was seen to have completely disappeared during weight-bearing in all the patients. On adduction of the extremity, it was observed that the scapula was not displaced laterally. There was no

clinical lameness. On the telephone consultation 2 months later, patient owners reported that none of the patients had a complaint of lameness and there was no recurrence.

DISCUSSION

The ventral serratus muscle is a large muscle mass covering the caudal wall of the thorax and is attached to the proximal medial angle of the scapula. This muscle is the major muscle support of the front leg [5]. The dorsal part of the scapula has an unossified structure also known as the scapular cartilage. This situation increases the area

available for muscle attachment and with age, this area calcifies and becomes more rigid [2]. The ventral serratus and rhomboideus muscles attach to this cartilaginous area. The trapezius muscle, frequently mentioned in dorsal scapular luxations, originates from the spinal processes of cervical and thoracic vertebrae and attaches to the scapular spine. While all three of these muscles have been reported to be affected in cases of dorsal scapular luxation [3,4], rupture of the trapezius muscle was not encountered in any of the patients in this study. Nevertheless, all clinical examination findings required to make a diagnosis of dorsal scapular luxation were present.

Various methods are available for the treatment of dorsal scapular luxation. One technique is to fix the ruptured muscles and re-attach them to the scapula. However, this procedure has been reported to fail to achieve sufficient stabilization for the extremity to bear weight [4].

Another method is to restore the scapula to its normal anatomical position and attach it to the ribs. In this technique, firstly an inverted L-shaped incision is made along the dorsal and caudal edge of the scapula. If there are parts of the serratus, rhomboideus or trapezius muscles without avulsion, these are carefully separated from their attachment points enough to allow lateral retraction of the scapula and visualization of the caudal angle and caudal border of the scapula [4]. Stabilization is achieved with a 20-22G cerclage wire passed around the 5th, 6th or 7th rib threaded through holes drilled on the caudo-dorsal edge of the scapula, in the area of origin for the teres major muscle [5]. While the cerclage wire is tightened, the aim is to minimize dorsal movement of the scapula. In other words, dorsal movement is not completely restricted [4]. In addition, the ventral serratus muscle can be reconstructed using the holes drilled in the cranio-dorsal edge of the scapula [3,7]. Post-operatively, Valpeau slings, spica splint application [8,9] or carpal flexion bandage [3] is recommended for 2 weeks. During the 2 weeks after removal of the sling, splint or carpal flexion bandage, it is recommended that the duration of the patient using its leg is gradually increased [3]. However, once the patient starts using the affected leg, this technique has the possibility of causing intercostal muscle rupture, subcutaneous emphysema and breathing difficulties due to the cerclage wire passed around the rib. However, very long skin incision is another disadvantage.

Therefore, recovery is thought to be achieved, by the Valpeau sling, splint or carpal flexion bandage applied post-operatively and kept in place for 2-3 weeks. Also use of cerclage wire for the procedure requires a second operation for wire removal following healing. The risks of non-removal of the cerclage wire include; pain and long period material reaction.

In this concept, relocation of the ventral serratus and rhomboideus muscles over the dorsal edge of the scapula and sutured to the infraspinatus and supraspinatus muscles, could be a more suitable option to prevent dorsal luxation of the scapula. Also, adhesion-increasing effect of point cauterization of subscapularis and serratus muscles and post-operative use of Valpeu slings together will decrease the operation time in this technique. In conclusion, the treatment model suggested in this study is quite simple and less invasive surgical intervention which could be applied in the treatment of the dorsal scapular luxation in cats.

REFERENCES

1. **Perry KL, Rutherford L, Arthurs GI:** A case of scapular avulsion with concomitant scapular fracture in a cat. *JFMS*, 14, 946-951, 2012. DOI: 10.1177/1098612X12459646
2. **Dyce KM, Sack WO, Wensing CJG:** The Locomotor Apparatus. In, Dyce KM, Sack WO, Wensing CJG (Eds): *Textbook of Veterinary Anatomy*. 4th edn., 32-100, Saunders Elsevier, Missouri, 2010.
3. **DeCamp CE, Johnston SA, DeJardin LM, Schaefer SL:** The shoulder joint. In, DeCamp CE, Johnston SA, DeJardin LM, Schaefer SL (Eds): *Brinker, Piermattei, and Flo's Handbook of Small Animal Orthopedics and Fracture Repair*. Fifth edn., 260-297, Elsevier, Missouri, 2016.
4. **Johnson AL, Hulse DA:** Diseases of joints. In, Fossum TW (Ed): *Small Animal Surgery*. 2nd edn., 1023-1150, Mosby, China, 2002.
5. **Parker RB:** Scapula. In, Slatter D (Ed): *Textbook of small animal surgery*. 3rd edn., 1891-1897, Saunders, Philadelphia, 2003.
6. **Bozcek-Funcke A, Kultz-Buschbeck JP, Illert M:** Kinematic analysis of the cat shoulder girdle during treadmill locomotion: An X-ray study. *EJN*, 8, 261-272, 1996. DOI: 10.1186/1746-6148-9-129
7. **Piermattei DL, Flo GL, DeCamp CE:** Fractures of scapula. In, Piermattei DL, Flo GL, DeCamp CE (Eds): *Brinker, Piermattei, and Flo's handbook of small animal orthopedics and fracture repair*. 4th edn., 255-261, Elsevier, St Louis, 2006.
8. **Peck J:** Scapula. In, Tobias KM, Johnston SA (Eds): *Veterinary Surgery Small Animal*, Vol. 1., 685-691, Elsevier Saunders, Canada, 2012.
9. **Kano WT, Rahal SC, Mesquita LR, Agostinho FS, Faria LG:** Gait analysis in a cat with scapular luxation and contralateral forelimb amputation. *Can Vet J*, 54, 990-991, 2013.