

Age Related Histopathological and Immunohistochemical Changes in Horse Brains ^[1]

Şule Yurdagül ÖZSOY ¹  Rifki HAZIROĞLU ²

^[1] This research was supported by Mustafa Kemal University Scientific Research Projects [Project no: 390 (1206 M 0115) and 14360]

¹ Mustafa Kemal University, Faculty of Veterinary Medicine, Department of Pathology, TR-31001 Alahan/Antakya, Hatay - TURKEY

² Ankara University, Faculty of Veterinary Medicine, Department of Pathology, TR-06110 Dışkapı, Ankara - TURKEY

Article Code: KVFD-2016-16417 Received: 24.06.2016 Accepted: 11.08.2016 Published Online: 11.08.2016

Citation of This Article

Özsoy ŞY, Hazıroğlu R: Age related histopathological and immunohistochemical changes in horse brains. *Kafkas Univ Vet Fak Derg*, 23 (2): 275-281, 2017. DOI: 10.9775/kvfd.2016.16417

Abstract

The aim of this study was to investigate age dependent pathological changes in horse brains. In the study, 10 mature horses aged between 10-16 years, 13 old horses aged between 17-21 years old and 7 young horses between 4-7 years old were examined macroscopically, histopathologically and immunohistochemically. As compared young horse brains; ventricular dilatation, satellitosis, neuronal vacuolization, status spongiosis, ventricular dilatation and ependymal undulation, calcium deposits and axonal swellings were seen in old horse brains. Immunohistochemical staining was obtained with Glial Fibrillary Acidic Protein (GFAP), 2',3'-Cyclic Nucleotide 3'-Phosphodiesterase (CNPase), neuron-specific enolase (NSE), β -amyloid protein (A β) antibodies to indicate age related changes in brains.

Keywords: Brain, Histopathology, Immunohistochemistry, Old horse

Atlarda Yaşla İlgili Beyinde Oluşan Histopatolojik ve İmmunohistokimyasal Değişiklikler

Özet

Bu çalışmanın amacı at beyinlerinde yaşa bağlı oluşan patolojik bulguların araştırılmasıdır. Sunulan çalışmada 10 adet genç at; yaşları 10-16 arasında, 13 adet yaşlı at; yaşları 17-21 arasında ve 7 adet genç at; yaşları 4-7 arasında (3-6 yaş arası) atlara ait beyinler makroskopik, histopatolojik ve immunohistokimyasal olarak incelendi. Genç atlara ait beyinlerle kıyaslandığında, yaşlı atlara ait beyinlerde makroskopik olarak ventriküler dilatasyon dikkat çekerken mikroskopik olarak satellitosis, nöronal vakuolasyon, status spongiosis, ventriküler genişleme ve ependimal ondülasyon, lipofuksin pigmenti, kalsiyum birikimleri ve aksonal şişmeler gözlemlendi. İmmunohistokimyasal boyamalarda yaşlı atların beyinlerinde Glial Fibrillary Acidic Protein (GFAP), ubiquitin, 2',3'-Cyclic Nucleotide 3'-Phosphodiesterase (CNPase), neuron-specific enolase (NSE), β -amyloid protein (A β), tirozin hidroksilaz antikorları ile pozitif boyanmalar gözlemlendi.

Anahtar sözcükler: Beyin, Histopatoloji, İmmunohistokimya, Yaşlı at

INTRODUCTION

With the improvements in diet, management and care in horses can allow them to live as long as humans. The average life expectancy of horses is about 24 years. Although 20 years old horses are considered to be 'geriatric', many of them are still physically fit when they reach this age ^[1]. The brains of the aging dogs and cats show pathologic changes similar to those that occur in people

with Alzheimer's disease. Equine dementia has not been well-described in the horse but age-related changes that occur in horse brains, were similar to other species ^[2].

Aging brains undergo many changes and these are described in detail in human beings ^[3-5] and in many animal species ^[6-10]. Neuroaxonal dystrophy, calcification and inflammation are the common changes in the aging brains, pathogenesis and functional consequences of



İletişim (Correspondence)



+90 326 2455845



suleozsoy@yahoo.com

these changes are not fully understood [11-14]. Lipofuscin and hemosiderin pigments, calcium deposits, satellitosis [11] neuroaxonal dystrophy, cerebrovascular disease [13,14] and Alzheimer type II cells were reported in previous studies [13] in the elderly horse brains. Furthermore, changes in the aging brain were demonstrated by some markers. In parallel with aging, astrocytes and glial changes demonstrate the neuroaxonal destruction and it can be showed with immunoperoxidase technique by using GFAP, CNPase and NSE. In some studies β -amyloid antibody is used to show amyloid accumulation in cerebral blood vessels, and it is the most common change of aging brain [15-19].

The aim of this study was to evaluate age-related pathological findings in horses in detail by routine and immunohistochemical staining methods; we also aimed to compare our findings with the previous studies on human beings and animal models.

MATERIAL and METHODS

The material of the study consists of 7 young horses aged between 4-7 years (3 female, 4 male) and 10 mature horses aged between 10-16 years (5 female, 5 male) and 13 old horses aged between 17-21 years old (7 female, 6 male) that were collected from the Jockey Clubs of Turkey, zoos and commoner, between the years of 2001-2014. Natural death due to senile/various diseases was observed in horses and they showed no signs of any neurological disease. The research project and animal housing conditions were approved by the Ethical Committee for Animal Studies (Approval 2010-3-11).

After death, necropsy was immediately done and brain samples were immediately removed and were fixed in 10% neutral buffered formalin and embedded in paraffin by routine methods. Brain sections that were taken from frontal, parietal, occipital, temporal lobes, pons, medulla oblongata, spinal cord and cerebellum, were cut 5 μ m and stained with hematoxylin and eosin (H & E) [20]. Additionally tissues were de-waxed and rehydrated by routine methods for immunohistochemical staining. For immunostaining, room temperature was used and the streptavidin-biotin-peroxidase complex method by a commercial kit (Zymed, USA) was carried out. Antigen retrieval was heated in citrate buffer, pH 6.0, for 10 min in microwave oven at 800 W. Endogenous peroxidase activity in tissue sections was blocked by applying 0.3% hydrogen peroxide in 0.01 M PBS containing 10% methanol to block nonspecific binding, and then the sections were incubated with 5% normal goat serum (blocking reagent) prior to exposure to primary antisera in oven for 20 min at 40°C. Sections were incubated with the primary antibodies anti-GFAP antibody (Abcam, UK, ab7260) (1:500) for astrocytes, anti-CNPase antibody (Sigma-Aldrich, USA, C9743) (1:200) for oligodendrocytes, anti-NSE antibody (Sigma-Aldrich, USA, SAB4500768) (1:200) for neurons and anti-A β antibody

(Sigma-Aldrich, USA, A8354) (1:300) for amyloid deposits; overnight at room temperature. The antibodies were diluted with PBS. After incubation with the rabbit anti-mouse biotinylated secondary antibody for 20 min, for color labelling the chromogen as aminoethyl carbazole (AEC) (Dako, Glostrup, Denmark) was administered for 5 min at room temperature. Finally, Mayer's hematoxylin was used for 1 min, washed under tap water and mounted with gelatinous glue. Following each incubation step, sections were washed thoroughly with PBS with the exception of the step after incubation with normal goat serum. All sections were examined by light microscopy (Olympus CX31). The findings were recorded with the support of the studies done previously and comparison was done. Finally, microphotographs were obtained by Olympus DP12. Previously known to be positive for all antibodies, tissue sections used served as the positive controls and for the negative controls, the primary antibody was omitted and replaced by PBS.

RESULTS

No gross changes were observed in the young horse brains, also microscopically all young animal brains showed normal histology structure and no staining was observed against antibodies.

Macroscopically in older horse brains only ventricular dilatation was noted (at ≥ 18 years old 5 cases, case nos: 19-23). Microscopically at some sections (Case Nos: 4, 11, 18) inflammatory cell infiltration, hemorrhage and hyperemia were observed and it was considered that they were not associated with aging. The main microscopic changes in all aged brains were gliosis, with neuronal degeneration and satellitosis (chromatolysis) (Fig. 1) and these changes were most seen in medial temporal lobe, amygdala and hippocampus. Additional main microscopic results

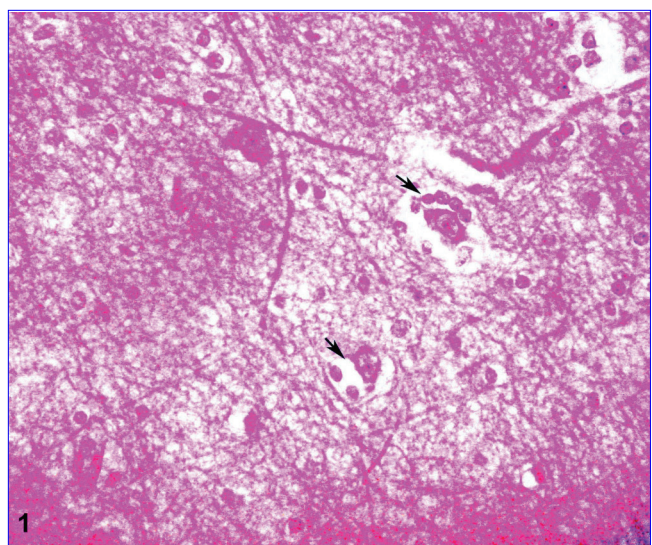


Fig 1. Satellitosis (arrows) and glia cell proliferation, H&E (Bar=12.5 μ m)

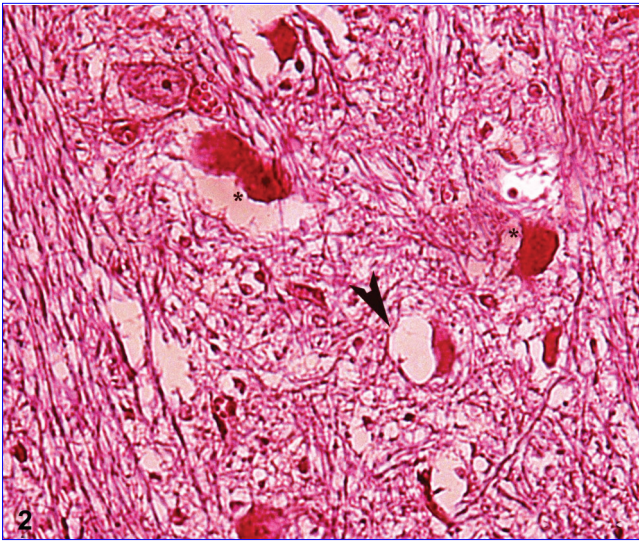


Fig 2. Neuronal vacuolation (*arrow head*) and perineural calcium deposits (*), H&E (Bar=12.5 μ m)

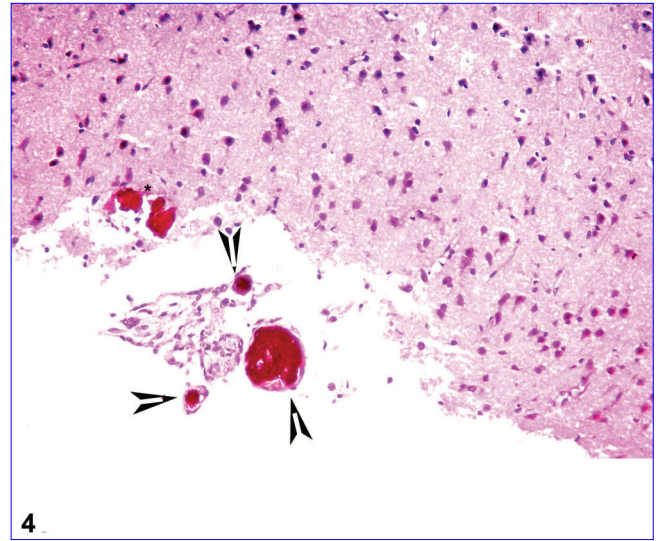


Fig 4. Ca⁺⁺ deposits at subependymal region (*) and blood vessel lumens (*arrow heads*), H&E (Bar=125 μ m)

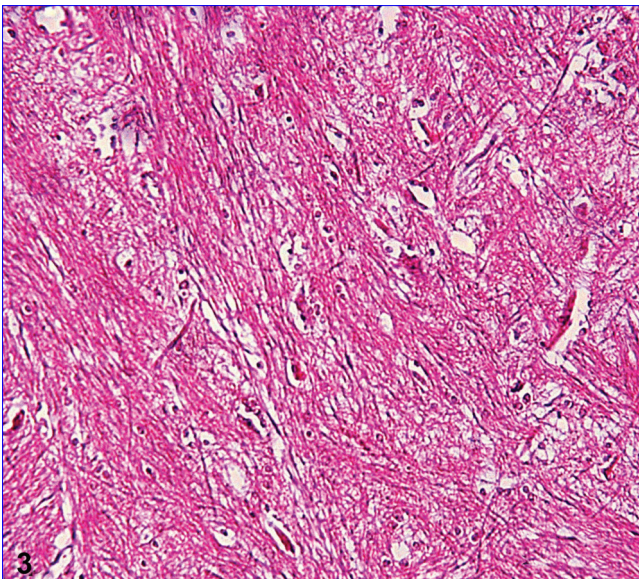


Fig 3. Status spongiosis at white matter, H&E (Bar=125 μ m)

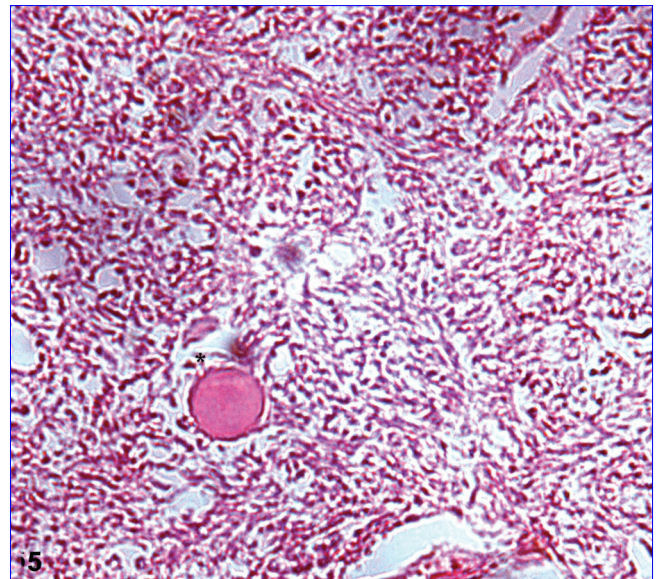


Fig 5. Axonal swelling (*), H&E (Bar=12.5 μ m)

were neuronal vacuolation (one or more vacuoles with miscellaneous dimensions) (at ≥ 17 years old 12 cases) (Fig. 2) and remarkable white matter status spongiosis (at ≥ 16 years old 15 cases) (Fig. 3) observed in medulla oblongata and pons. Intra-neuronal yellowish-brown lipofuscin pigment storage was commonly observed in cerebral cortex, thalamus and midbrain. Dark blue mineralization areas were detected in degenerated neurons with focal gliosis and these changes had no relationship with blood vessels. At five cases (Case Nos: 14, 18, 22, 23, 25) calcium deposits occurred free in subependymal parenchyma or totally filled the blood vessel walls (Fig. 4). Focal axonal swelling (at cases 11, 14, 17- 20) (Fig. 5) with axonal calcification (Case Nos: 19, 21, 23) was observed at cerebral white matter and

midbrain grey matter. At ≥ 18 years old aged brains (5 cases) ependymal convolution with inflammatory cell infiltration (mononuclear) was observed (Case Nos: 19-23). With aging, astrocytic glial cell proliferation increased and was demonstrated with GFAP antibody frequently in cerebral cortex, hippocampal area, thalamus, and cerebellar white matter (Fig. 6). The increase of oligodendrocytes was detected by CNPase antibody (Fig. 7) in the white matter of cerebral and cerebellar cortex and like GFAP positive astrocytes with aging, the number of CNPase labelled oligodendrocytes was increased. NSE-positive immunoreaction was detected at degenerated neurons (Fig. 8) in basal nuclei, thalamus, hippocampal pyramidal neurons, cerebellar dentate nuclei and some nuclei of cerebral cortex. Amyloid deposits were observed at cerebral

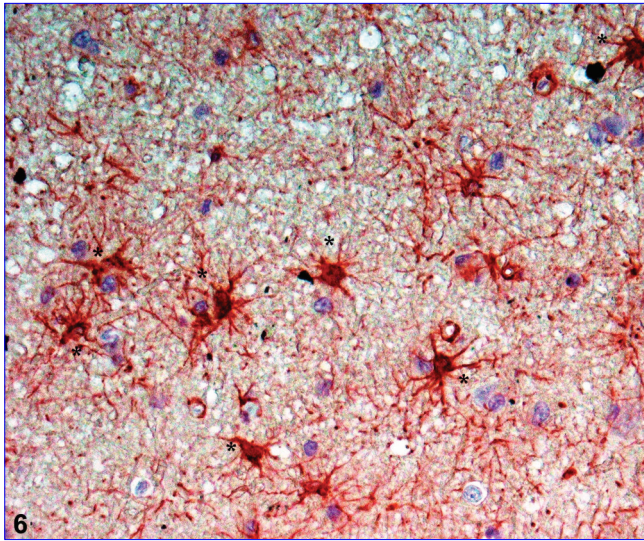


Fig 6. GFAP positive astrocytes (*), IHC (Bar=12.5 μ m)

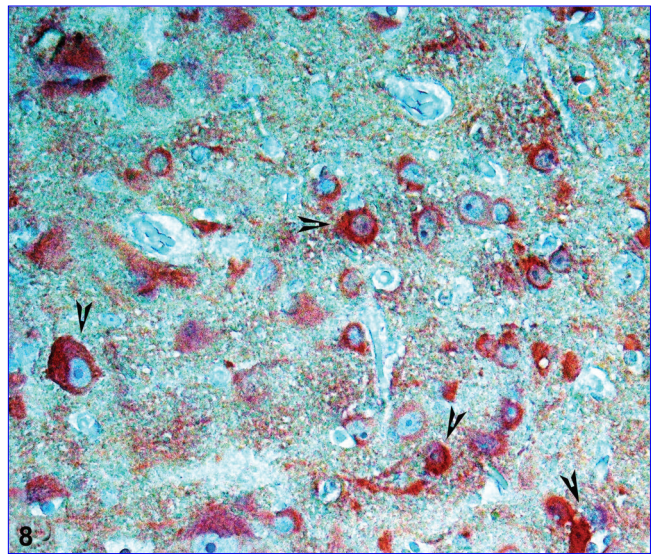


Fig 8. NSE positive neurons (arrow heads), IHC (Bar=12.5 μ m)

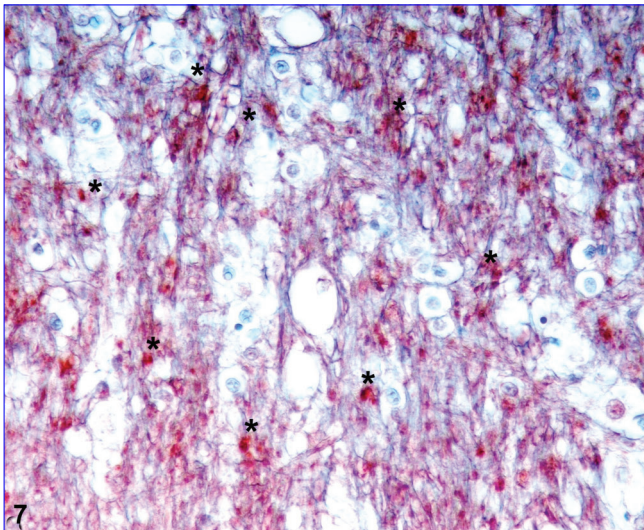


Fig 7. CNPase positive oligodendrocytes (*), IHC (Bar=125 μ m)

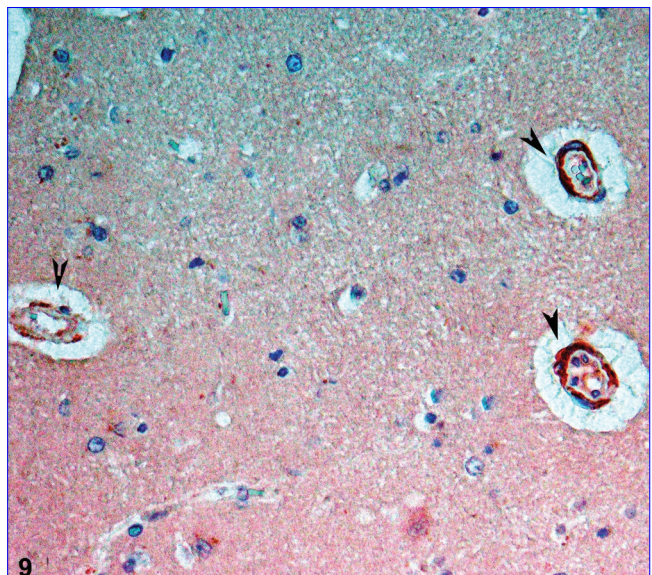


Fig 9. A β positive staining at cerebral vessel walls (arrow heads), IHC (Bar=12.5 μ m)

(Fig. 9) and meningeal blood vessels walls (Fig. 10), and demonstrated by A β antibody. Amyloid was most often found in leptomeninges, neocortex, cerebellum and brainstem vessels respectively. No senile plaque was observed. The main histopathological and immunohistochemical changes are summarized in Table 1.

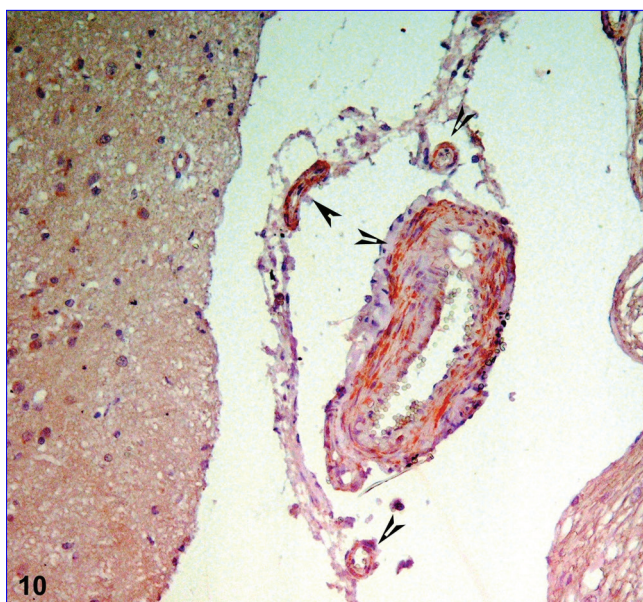
DISCUSSION

Like in pet animals such as cats and dogs with correct maintenance, feeding, and good veterinary services, the lives of horses extend to the age 30's [21,22]. The average life span for a horse is considered to be 24 years [11].

It is considered that young horses' 1-year life span is equivalent to 3.5-year life span of people but the ratio varies with the aging of the horse, and it is said that

1-year life span is equivalent to 3-year life of people. Accordingly, it is accepted that about 10-year-old horse is equivalent to 35-year-old person while 20-year-old horse is equivalent to 60-year-old man. So, 20-year-old horse is considered as old [1,15].

Ventricular dilation (enlargement) is the most common macroscopic change of aging brain in people and it is shown by MR (cerebral magnetic resonance imaging scans) and tomography [3], but in animal species [21,22] this can be shown during the necropsy by macroscopic serial sections of the brain. In this study, macroscopically and microscopically ventricular dilatation and ependymal undulation with inflammation were noted; these results were previously reported in other animal species [8,10] but not in horses.



10

Fig 10. A β positive staining at meningeal blood vessel walls (arrow heads), IHC (Bar=12.5 μ m)

observed in all 10 \geq years; we thought that these changes were related with aging.

Previous studies reported histopathological changes in aged animal brains like meningeal and choroid plexus fibrosis, hyalinization and fibrosis of the vessel walls [8,10] and cholesterol granulomas (cholesteatoma) that settled in the 4th ventriculus and causes hydrocephalus [11,13], but these findings were not shaped in this study. Neuronal lipofuscin pigmentation and mineralization areas (Ca⁺⁺ deposits) with free accumulation of Ca deposits in the parenchyma were similar with previous studies [8,10,11,23,27]. Additionally to these, same mineralization occurred at axons.

It is known that with aging a certain neurodegeneration develops and during this astrogial activation, gliosis and disruption of myelin membranes occur [26,28,29]. In addition to routine H&E staining in the study, neurodegeneration was demonstrated by specific antibodies such as GFAP, CNPase and NSE. In this study, with aging (especially between the ages 18-23) response to neuronal degeneration, astrogial activation was increased and this leads to increased GFAP

Table 1. Histopathological and immunohistochemical changes of the brain due to aging in horses.

Lesion	Affected Areas	Horse Ages (Year)	Frequency
Gliosis	Medial temporal lobe, amiglada and hippocampus	12-21	19/23 (82.6%)
Neuronal degeneration	Medial temporal lobe, amiglada and hippocampus	13-21	18/23 (78.2%)
Satellitosis	Medial temporal lobe, amiglada and hippocampus	13-21	18/23 (78.2%)
Neuronal vacuolation	Medulla oblongata and pons	17-21	12/23 (52.1%)
White matter status spongiosis	Medulla oblongata and pons	16-21	15/23 (65.2%)
Lipofuscin pigment storage	Cerebral cortex, thalamus and midbrain	18-21	7/23 (30.4%)
Calcium deposits	Free in subependymal parenchyma/ blood vessel walls	17-21	5/23 (21.7%)
Axonal swelling	Cerebral white matter and midbrain grey matter	17-21	6/23 (26.1%)
Axonal calcification	Cerebral white matter and midbrain grey matter	18-21	3/23 (13.0%)
Ependymal convolution with inflammatory cell infiltration	Mesencephalic canal and lateral ventricles	18-21	5/23 (21.7%)
Astrocytes proliferation and GFAP staining (moderate to strong)	Cerebral cortex, hippocampal area, thalamus, and cerebellar white matter	10-21	20/23 (86.9%)
CNPase staining at increased oligodendrocytes (moderate to strong)	White matter of cerebral and cerebellar cortex	16-21	14/23 (60.9%)
NSE-positive immunoreaction at degenerated neurons (moderate to strong)	Basal nuclei, thalamus, hippocampal pyramidal neurons, cerebellar dentate nuclei, and some nuclei of cerebral cortex	17-21	11/23 (47.8%)
Amyloid deposits	Leptomeninges, neocortex, cerebellum and brainstem vessels	18-21	8/23 (34.8%)
Senile plaque	None	None	0/23 (0%)

Histopathological findings in the aging brains in horses were similar with earlier studies done with horses [11,13,14,23], other animal species [8,10,21,22,24] and people [4,25,26]. In the study, even though no sex or breed difference was found, significant difference was found with aging. Jahns et al.^[13] reported that neuronal and white matter vacuolation and spheroids were not related with aging. However, in the study, neuronal degeneration, gliosis and satellitosis were

expression. CNPase is a myelin-associated enzyme that makes up 4% of total CNS myelin protein, and is thought to undergo significant age-associated changes [30]. In the central nervous system, CNPase is thought to play a critical role in the events leading up to myelination and expressed exclusively by oligodendrocytes. CNP expression that is a key myelin protein is implicated in age-related changes in myelin and axons [30,31]. Here we again examine the extent

of CNP accumulation in brain white matter of aged horses and its relationship to CNP degradation and partitioning in myelin. NSE is considered as quite established and specific markers of the central nervous tissue damage^[10,32-34]. In the study, positive anti-NSE staining results showed that aging brains undergo degenerative changes and especially neurons were mostly affected by this situation. It is known that amyloid is deposited in the walls of cerebral and meningeal blood vessels; it is the important disorder of the aging brain. Beta amyloid (A β) deposits are seen in aged individuals in many of the mammalian species that possess the same A β amino acid sequence as humans^[35]. Lesions such as senile plaques, cerebral β -amyloid angiopathy appear with advancing age in the human brain but are not specific to the human brain^[19]. We observed A β deposits in the cerebral and meningeal vessel walls but not in the brain cortex as senile plaques reported previously in other species^[8,10,21,22].

As a result, we observed that aging had a significant effect on brain tissue. The histopathological and immunohistochemical findings encountered in the brain related to aging in horses are similar with earlier studies, other animal species and humans. Also with further molecular studies, pathogenesis of these lesions will be explained in detail.

REFERENCES

- McDonnell S:** Signs of equine dementia. <http://www.thehorse.com/articles/29479/signs-of-equine-dementia>, Accessed: 10.1.2016.
- Geor R:** Conditioning the older horse. <http://www.thehorse.com/articles/10040/conditioning-the-older-horse>, Accessed: 10.11.2015.
- Breteler MM, Amerongen Van NM, Swieten Van JC, Claus JJ, Grobbee DE, Gijn Van J, Hofman A, Harskamp Van F:** Cognitive correlates of ventricular enlargement and cerebral white matter lesions on magnetic resonance imaging. *Stroke*, 25, 1109-1115, 1994. DOI: 10.1161/01.STR.25.6.1109
- Ferrer I, Gomez-Isla T, Puig B, Freixes M, Ribe E:** Current advances on different kinases involved in tau phosphorylation, and implications in Alzheimer's disease and tauopathies. *Curr Alzheimer Res*, 2, 3-18, 2005. DOI: 10.2174/1567205052727213
- Yamada S, Asano T, Enomoto M, Sakata M, Tanno M, Yamada H, Esaki Y, Mizutani T:** Ventricular dilatation and brain atrophy of normal elderly individuals and patients with Alzheimer-type dementia: A retrospective longitudinal computed tomographic study of autopsy cases. *Neuropathol*, 18, 261-269, 1998. DOI: 10.1111/j.1440-1789.1998.tb00113.x
- Gavier-Widen D, Wells GAH, Simmons MM, Wilesmith JWW, Ryan J:** Histological observations on the brains of symptomless 7-year-old cattle. *J Comp Pathol*, 124, 52-59 2001. DOI: 10.1053/jcpa.2000.0428
- Gunn-Moore DA, Mcvee J, Bradshaw JM, Pearson GR, Head E, Gunn-Moore FJ:** Ageing changes in cat brains demonstrated by β -amyloid and AT8-immunoreactive phosphorylated tau deposits. *J Feline Med Surg*, 8, 234-242, 2006. DOI: 10.1016/j.jfms.2006.01.003
- Hazıroğlu R, Güvenç T, Tunca R, Özsoy ŞY, Özyıldız Z:** Evaluation of the age related changes in dog brains. *Rev Med Vet*, 161, 72-78, 2010.
- Kikuchi K:** Über die Altersveränderungen am Gehirn des Pferdes. *Arch Tierheilkunde*, 58, 541-573, 1928.
- Özsoy ŞY, Hazıroğlu R:** Age-related changes in cat brains as demonstrated by histological and immunohistochemical techniques. *Rev Med Vet*, 161, 540-548, 2010.
- Capucchio MT, Ma'riquez M, Pregel P, Foradada L, Bravo M, Mattutino G, Torre C, Schiffer D, Catalano D, Valenza F, Guarda F, Pumarola M:** Parenchymal and vascular lesions in ageing equine brains: Histological and immunohistochemical studies. *J Comp Pat*, 142, 61-73, 2010. DOI: 10.1016/j.jcpa.2009.07.007
- Head E, Moffat K, Das P, Sarsoza F, Poon WW, Landsberg G, Cotman CW, Murphy MP:** β -Amyloid deposition and tau phosphorylation in clinically characterized aged cats. *Neurobiol Aging*, 26, 749-763, 2005. DOI: 10.1016/j.neurobiolaging.2004.06.015
- Jahns H, Callanan JJ, Mcelroy MC, Sammin DJ, Bassett HF:** Age related and non-related changes in 100 surveyed horse brains. *Vet Pathol*, 43, 740-750, 2006. DOI: 10.1354/vp.43-5-740
- Yanai T, Masegi T, Ishikawa K, Sakai H, Iwasaki T, Moritoo Y, Goto N:** Spontaneous vascular mineralization in the brain of horses. *J Vet Med Sci*, 58, 35-40, 1996.
- Edward L, Johnson K, Jo D, Mark S:** Caring for the older horse: Common problems and solutions. <http://edis.ifas.ufl.edu/an253>, Accessed: 10.1.2016.
- Frankhauser R, Luginbuehl H, Mcgrath JT:** Cerebrovascular disease in various animal species. *Ann N Y Acad Sci*, 127, 817-860, 1965. DOI: 10.1111/j.1749-6632.1965.tb49447.x
- Sloane JA, Hinman JD, Lubonia M, Hollander W, Abraham CR:** Age-dependent myelin degeneration and proteolysis of oligodendrocyte proteins is associated with the activation of calpain-1 in the rhesus monkey. *J Neurochem*, 84, 157-168, 2003. DOI: 10.1046/j.1471.4159.2003.01541.x
- Summers BA, Cummings JF, deLahunta A:** Principles of neuropathology. In, Summers BS, Cummings JF, deLahunta A (Eds): *Veterinary Neuropathology*. 40-50, Mosby, St Louis, MO, 1995.
- Uchida K, Yoshino T, Yamaguchi R, Tateyama S, Kimoto Y, Nakayama H, Goto N:** Senile plaques and other senile changes in the brain of an aged American black bear. *Vet Pathol*, 32, 412-414, 1995. DOI: 10.1177/030098589503200410
- Luna LG:** Manual of Histologic Staining Methods of the Armed Forces Institute of Pathology. 3rd edn., 32, McGraw-Hill Book Co, New York, 1968.
- Borras D, Ferrer I, Pumarola M:** Age related changes in the brain of the dog. *Vet Pathol*, 36, 202-211, 1999. DOI: 10.1354/vp.36-3-202
- Brellou G, Papaioannou N, Lekkas S, Vlemmas I:** Immunohistochemical investigation of amyloid β protein (A β) in the brain of aged cats. *Proceedings of the 22nd ESVP meeting*, Olsztyn, Poland, September, 57, 15-18, 2004.
- Hurst EW:** Calcification in the brains of Equidae and Bovidae. *Am J Pathol*, 10, 795-802, 1934.
- Braak H, Braak E, Strothjohann M:** Abnormally phosphorylated tau protein related to the formation of neurofibrillary tangles and neuropil threads in the cortex of sheep and goat. *Neuroscience Let*, 171, 1-4, 1994. DOI: 10.1016/0304-3940(94)90589-4
- Davis S, Thomas A, Perry R, Oakley A, Kalaria RN, O'brien JT:** Glial fibrillary acidic protein in late life major depressive disorder: An immunocytochemical study. *J Neurol Neurosurg Psychiatry*, 73, 556-560, 2002. DOI: 10.1136/jnnp.73.5.556
- Lyck L, Dalmau I, Chemnitz J, Finsen B, Schröder HD:** Immunohistochemical markers for quantitative studies of neurons and glia in human neocortex. *J Histochem Cytochem*, 56, 201-221, 2008. DOI: 10.1369/jhc.7A7187.2007
- Yanai T, Masegi T, Kawada M, Ishikawa K, Fukuda K:** Spontaneous vascular mineralization in the brain of cows. *J Comp Pathol*, 111, 213-219, 1994. DOI: 10.1016/S0021-9975(05)80053-2
- German DC, Liang CL, Song T, Yazdani U, Xie C, Dietschy JM:** Neurodegeneration in the Niemann-Pick C mouse: Glial involvement. *Neurosci*, 109, 437-450, 2002. DOI: 10.1016/S0306-4522(01)00517-6
- Hinman JD, Chen CD, Oh SY, Hollander W, Abraham CR:** Age-dependent accumulation of ubiquitinated 2',3'-cyclic nucleotide 3'-phosphodiesterase in myelin lipid rafts. *Glia*, 56, 118-133, 2008. DOI: 10.1002/glia.20595

- 30. Sprinkle TJ, Lanclos KD, Lapp DF:** Assignment of the human 2',3'-cyclic nucleotide 3'-phosphohydrolase gene to chromosome 17. *Genomics*, 13, 877-80, 1992. DOI: 10.1016/0888-7543(92)90174-Q
- 31. Kasama-Yoshida H, Tohyama Y, Kurihara T, Sakuma M, Kojima H, Tamai Y:** A comparative study of 2',3'-cyclic-nucleotide 3'-phosphodiesterase in vertebrates: cDNA cloning and amino acid sequences for chicken and bullfrog enzymes. *J Neurochem*, 69, 1335-1342, 1997. DOI: 10.1046/j.1471-4159.1997.69041335.x
- 32. Hajduková L, Sobek O, Prchalová D, Bilková Z, Koudelková M, Lukášková J, Tuchová I:** Biomarkers of brain damage: S100B and NSE concentrations in cerebrospinal fluid-A normative study. *Bio Med Res Int Art*, 2015 (2015), Article ID: 379071, 2015. DOI: 10.1155/2015/379071
- 33. Ozmen E, Ozsoy SY, Donmez N, Ozsoy B, Yumuşak N:** The protective effect of L-carnitine against hippocampal damage due to experimental formaldehyde intoxication in rats. *Biotech Histochem*, 89, 336-341, 2014. DOI: 10.3109/10520295.2013.855818
- 34. Ozsoy SY, Ozsoy B, Ozyildiz Z, Aytekin I:** Protective effect of L-carnitine on experimental lead toxicity in rats: A clinical, histopathological and immunohistochemical study. *Biotech Histochem*, 86, 436-443, 2011. DOI: 10.3109/10520295.2010.529825
- 35. Chambers K, Uchida K, Harada T, Tsuboi M, Sato M, Kubo M, Kawaguchi H, Miyoshi N, Tsujimoto H, Nakayama HI:** Neurofibrillary tangles and the deposition of a beta amyloid peptide with a novel n-terminal epitope in the brains of wild tsushima leopard cats. *James Plos One*, 7, 1-10, 2012. DOI: 10.1371/journal.pone.0046452