

# A New Flap Model in the Treatment of Non-Healing Elbow Wounds in Dogs: The Island Arterial Composite Flap Comprising the Skin Originating from the Thoracodorsal Artery, the Cutaneous Trunci Muscle and Fascia of the Latissimus Dorsi Muscle

Kürşat ÖZER <sup>1</sup>  Murat KARABAĞLI <sup>1</sup> Kemal UĞURLU <sup>2</sup>

<sup>1</sup> Faculty of Veterinary Medicine, University of Istanbul, Department of Surgery, TR-34320 Avcılar, Istanbul - TURKEY

<sup>2</sup> Medistate Hospital, Ruzgarlibahçe Mah. Cumhuriyet Cad. No: 24, TR-34805 Kavacık, Beykoz, Istanbul - TURKEY

Article Code: KVFD-2016-15425 Received: 27.02.2016 Accepted: 12.04.2016 Published Online: 12.04.2016

## Abstract

In the treatment of wounds with tissue loss in the elbow region, despite the most frequently used method being the tube flap of thoracodorsal artery origin, this method has the disadvantages of necrosis, opening of sutures and tension. The aim of this study is to present the results of the island arterial composite flap, containing the skin of the thoracodorsal area, the cutaneous trunci muscle and fascia of the latissimus dorsi muscle, for the reconstruction of chronic wounds in the elbow region. The material of the study consisted of 14 dogs with either non-healing wounds or wounds with tissue loss in the elbow region. Firstly, debridement of the elbow defect was carried out. Next, an elliptical incision depending on the size of the defect was made in the thoracodorsal skin. Once the thoracodorsal artery and its pedicle were exposed, this was passed through the tunnel formed in the axillary region and placed over the debrided defect in the elbow region. It was sutured using non-absorbable monofilament suture material and simple interrupted sutures and the results were evaluated. In conclusion, the skin originating from the thoracodorsal artery, muscle and fascia island artery flap may be an effective method in the reconstruction of wounds in the elbow region.

**Keywords:** *Island flap, Cutaneous trunci muscle, Non-healing elbow wounds, Dog, Composite flap, Latissimus dorsi muscle fascia*

## Köpeklerde İyileşmeyen Dirsek Yaralarının Sağaltımında Yeni Bir Flep Modeli: Torakodorsal Arter Kökenli Deri, Cutaneöz Trunci Kası ve Latissimus Dorsi Kası Fasyasını İçeren Ada Arteriyel Kompozit Flebi

## Özet

Dirsek bölgesindeki doku kayıplı yaraların sağaltımında en çok kullanılan yöntem torakodorsal arter kökenli tüp flebi olmasına karşın, nekroz, dikişlerde açılma, gerginlik gibi dezavantajları bulunmaktadır. Bu nedenle çalışmamızda, torakodorsal bölgedeki deri, kutaneöz trunci kası ve latissimus dorsi kasının üzerindeki fasya dokusunun, kompozit ada arteriyel flebi olarak, dirsek bölgesindeki kronik yaraların rekonstrüksiyonu için kullanılmasının sonuçlarının ortaya konması amaçlandı. Dirsek bölgesinde doku kayıplı veya iyileşmeyen yaraları bulunan 14 köpek çalışmanın materyalini oluşturdu. Öncelikle dirsek bölgesindeki kronik yara yenileştirildi. Daha sonra torakodorsal bölgedeki deri üzerinde, mevcut yaranın boyutuna göre değişen elips şeklinde bir ensizyon yapıldı. Torakodorsal arter pedikülü ortaya çıkarıldıktan sonra koltuk altında oluşturulan tünelden geçirilerek dirsek bölgesindeki yenileştirilmiş yara üzerine taşındı ve monofilament emilmeyen dikiş materyali ile basit ayrı teknikle dikilerek sonuçları değerlendirildi. Sonuç olarak torakodorsal arter kökenli deri, kas ve fasya ada arteriyel kompozit flebinin, dirsek bölgesindeki iyileşmeyen yaraların rekonstrüksiyonunda etkili bir yöntem olabileceği düşünüldü.

**Anahtar sözcükler:** *Ada flep, Kutaneöz trunci kası, İyileşmeyen dirsek yaraları, Köpek, Kompozit flep, Latissimus dorsi kası fasyası*

## INTRODUCTION

Wounds of the elbow region in dogs may be caused secondary to external trauma, as a result of ischemia or

pressure sores due to long time compression of the skin (decubital ulcers), following revision of damaged skin wound or as a complication of an abscess, infection or bursa extirpations. The treatment is long and arduous. Options



### İletişim (Correspondence)



+90 212 4737070/17296 (ext.)



ozar\_kursat@yahoo.com

for the treatment of elbow wounds in dogs include: second intention, simple appositional closure of the wound edges by suturing, applying axial model flaps, island artery flaps, myocutaneous flaps and skin grafts<sup>[1]</sup>.

Axial model flaps are skin flaps with their own direct cutaneous artery and vein, the same length as the flap<sup>[2]</sup>. Clinically the easiest axial model flaps to produce are thoracodorsal and caudal epigastric axial model flaps<sup>[3]</sup>. Therefore, in the treatment of elbow region wounds in veterinary practice, apart from second intention and opposition and suturing of wound edges, the most selected method is the thoracodorsal axial model flap technique. However, similar to other axial model flaps, complications such as opening of the sutures, edema, infection, seroma formation and distal flap necrosis may be observed<sup>[4]</sup>.

In dogs, the cutaneous trunci muscle originates from the profund pectoral muscle and covers the dorsal, lateral and ventral abdominal wall in a thin layer<sup>[5]</sup>. Also this muscle, enables the abdomen to twitch when exposed to external irritants<sup>[6]</sup>. Cutaneous trunci muscle circulation is provided by the direct cutaneous arteries feeding the skin above and also small muscular branches. The combined separation of the skin and cutaneous trunci muscle from the underlying tissues protects the vascular relationship of these two structures<sup>[7]</sup>.

A flap containing two or more tissue elements including skin, muscle, bone or cartilage is termed a composite flap. For the closure of foreleg defects in veterinary practice, the cutaneous trunci muscle and its overlying skin has been described and used as a myocutaneous style composite flap<sup>[8]</sup>. However, composite flaps do not have widespread usage in veterinary practice<sup>[1]</sup>.

Island artery flaps are created using direct cutaneous arteries described for axial model flaps. However, unlike axial model flaps, these are transferred onto the recipient site after total detachment of the skin connection<sup>[9,10]</sup>. The island arterial flaps can be rotated up to 180 degrees, so this provides a significant advantage in cases where the defect location is close to the base of a flap. The ventral deep circumflex iliac and cranial superficial epigastric axial pattern flap regions have been reported to be the most suitable areas for island artery flap rotation<sup>[10]</sup>.

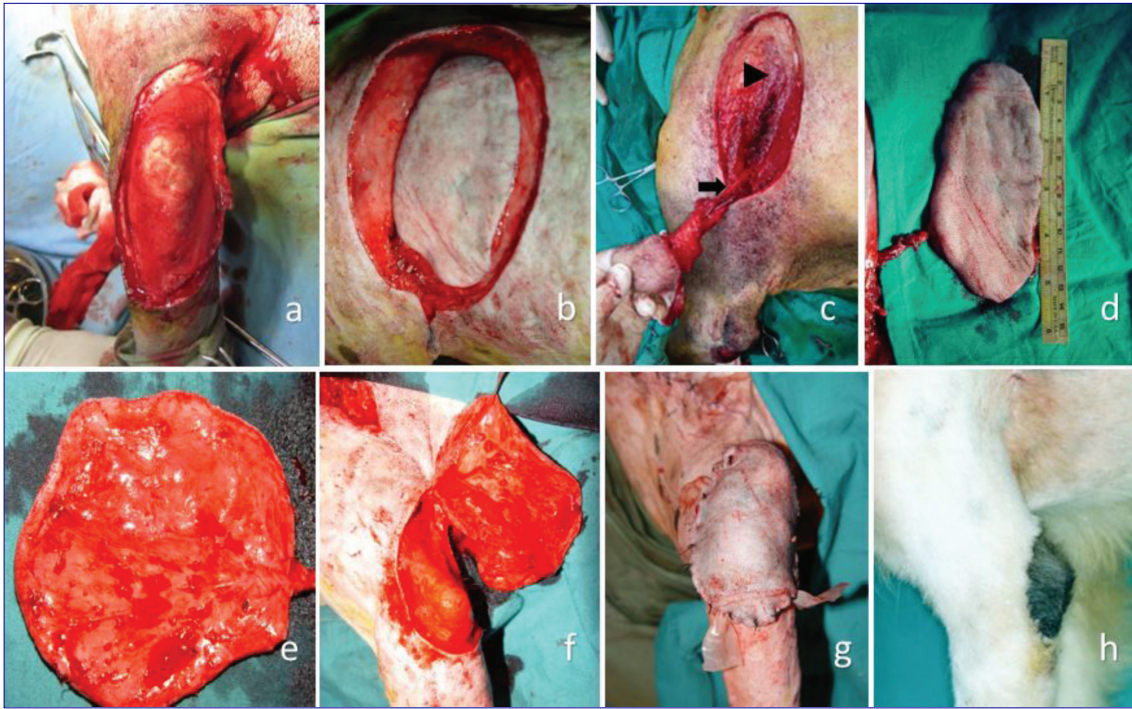
The fascial tissue has been used in the reconstruction of various tissues due to its properties such as; its easy vascularization<sup>[11]</sup>, the fact that it is easily obtainable, does not cause any loss of function afterwards and has a high tolerance to ischemia, forms a slippery surface and its resistance to stretching<sup>[12,13]</sup>. For this purpose, the most commonly used fascial tissues in veterinary practice are the thoracolumbar fascia and fascia lata<sup>[14,15]</sup>.

In the authors' opinion, the fact that this composite flap prepared from the thoracodorsal region was created in the island artery style, passed through a tunnel and

incorporated the fascial tissue on the bottom layer, may decrease complications previously reported to be encountered in axial model flaps.

## MATERIAL and METHODS

In this study, 15 defects in the elbow region of 14 dogs of different breed, age and gender, were treated using the island arterial composite flap consisting of thoracodorsal artery-originating skin, the cutaneous trunci muscle and the fascia overlying the latissimus dorsi muscle. Patients were induced with 4-6 mg/kg IV propofol (Pofol, Sandoz®, 10 mg/ml ampule) and intubated. Anesthesia was maintained with 2.5% isoflurane (Isoflurane®, Adeka) and 100% oxygen. The patient was positioned in lateral recumbency with the extremity with the defect uppermost. The affected extremity was shaved with razor blade and disinfected up to the lateral thoracic wall and distal antebrachium. Firstly, the lesion in the elbow region was freshen up by cut out of the small pieces of the skin from the wound edges circumferentially and an elliptical recipient site surrounded with healthy skin tissue was established (*Fig. 1a*). Dimensions of the defect were then measured in two planes by metric fashion. The cranial side of the flap was formed by an incision along the length of the spina scapula. The caudal border was made parallel to the first incision and twice the distance from the first incision to the caudal shoulder depression (caudal border of scapula). The caudal and cranial incisions were connected and the flap borders were established (*Fig. 1b*). Next, the skin was dissected together with the underlying cutaneous trunci muscle and latissimus dorsi muscle fascia, starting from the caudodorsal location of the area near the transversal processes of the thoracic vertebrae and was continued in a cranio-ventral direction towards the caudal shoulder depression. During dissection, any bleeding in both the latissimus dorsi fascia forming the bottom layer of the flap and the donor site was cauterized. Also, care was taken not to damage the thoracodorsal artery pedicle located at the dorsal level of the acromion in the caudal shoulder depression<sup>[10]</sup>. When the caudal shoulder depression was reached, for ease of flap transfer, the soft tissues surrounding the thoracodorsal artery and vein were carefully separated. Thus, a vascular pedicle of approximately 9-10 cm was obtained (*Fig. 1c*). The composite flap with its free vascular pedicle was passed through a tunnel, under the skin in the axillary region, made in the direction of the defect (*Fig. 1f*). It was observed that the anatomical course of the thoracodorsal artery pedicle was almost parallel to the sternum and that the prepared flap was bent approximately 90 degrees during transfer to the elbow region. The flap positioned over the defect was sutured with simple interrupted sutures using either Number 0 or Number 1 non-absorbable monofilament suture material (Prolene®, Ethicon) depending on the thickness of the skin (*Fig. 1g*). The same procedure was repeated for the donor site on the thorax. In all cases, two drains were placed in



**Fig 1.** Preparation and application stages of the island arterial composite flap comprising thoracodorsal artery-originating skin, the cutaneous trunci muscle and fascia of the latissimus dorsi muscle. Debridement of the defect in the elbow region and formation of a circular recipient site surrounded by healthy skin tissue on to which the flap can be sutured, **a**; elliptical donor site created by connecting cranial and caudal incisions, **b**; freeing the island arterial flap without damaging the blood vessel pedicle, (*black arrow*) thoracodorsal artery pedicle (*black arrow head*), latissimus dorsi muscle without its fascia, **c**; elliptical flap and thoracodorsal artery pedicle, **d**; appearance of the internal side of the flap, **e**; advancing the flap through the tunnel made towards the defect, **f**; suturing flap on to defect and placement of drains, **g**; appearance of area on post-operative day 20, **h**

**Şekil 1.** Torakodorsal arter kökenli deri, cutaneous trunci kası ve latissimus dorsi kası fasyasını içeren ada arteriyel kompozit flebinin oluşturma ve uygulama aşamaları. Dirsek bölgesindeki defektin yenileştirilmesi ve flebin üzerine dikilebileceği, sağlıklı deri dokusuyla çevrili daire şeklinde bir alıcı bölge oluşturulması, **a**; kranial ve kaudal ensizyonların birleştirilmesiyle oluşturulan elips şeklindeki donör bölge, **b**; ada arteriyel kompozit flebinin damar pedikülüne zarar vermeden serbestleştirilmesi, *siyah ok* thorakodorsal arter pedikülü, *siyah okbaşı*, üzerinden fasyası sıyrılmış latissimus dorsi kası, **c**; elips şeklindeki flep ve torakodorsal arter pedikülü, **d**; flebin iç yüzünün görünümü, **e**; flebin, deri altından, defekte doğru oluşturulmuş tünelden ilerletilmesi, **f**; flebin defekt üzerine dikilmesi ve drenlerin yerleştirilmesi, **g**; bölgenin postoperatif 20. gün görüntüsü, **h**

the recipient site and 20 mg/kg IM ceftriaxone disodium trisesquihydrate (Unacefin®, Fako) was administered for 5 days. Elizabethan collar was placed to all dogs after awaking in reanimation. The patients were hospitalized for 2 days after the operation and discharged following drain removal on day 2. Patient owners were advised to keep their dogs on soft flooring and that there was no elevation on which the dogs could rise up on their hind legs and rest their elbows. Post-operative bandage application was not performed to avoid iatrogenic obstruction of flap blood supply and partial or full flap necrosis. The patients were called back for a check-up on days 10 and 20 and healing was evaluated. Assessment of flap viability was performed by visual observation.

## RESULTS

Of the 14 dogs included in the study, 10 (71.5%) were male and 4 (28.5%) were female with ages ranging 1-11 (mean 4.6, SE 1.03) years and mean body weight was 31.9 (SE 2.47) kilogramme. Breed distribution of the dogs was: 6 mixed breed, 5 Turkish Kangal, 1 Rottweiler, 1 Saint Bernard

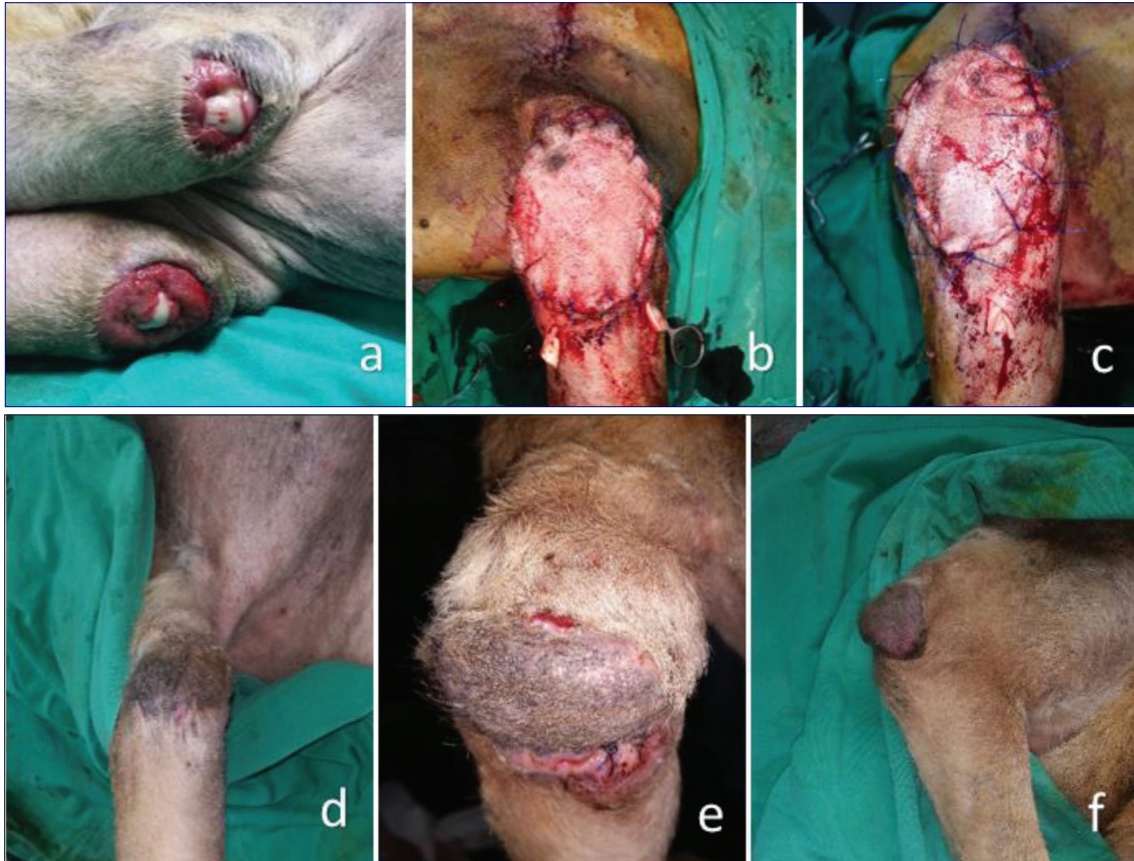
and 1 German Shepherd. Reasons for chronic wounds forming in the elbow region were: bursitis olecrani (elbow hygroma) extirpation in 7 (50%) dogs and suture failure following tumor extirpation in 5 (35.7%) dogs, pressure sores in 1 (7.15%) and unknown cause in 1 (7.15%) dog (*Table 1*). Post-operative histopathological investigation had not been performed in 4 of 5 cases following previous tumor extirpation and in one case (case no.11) the histopathology report result had showed extensive granulation tissue. In one case (case no.13), it was reported that the dog had been reluctant to stand for approximately 1 month due to neurological reasons and preferred to sit with its elbows on the floor. Physical examination revealed an ischaemia-based pressure wound with bilateral tissue loss observed in the olecranon on the caudal aspect of the elbow joint. Following improvement of neurological signs with medical treatment and the patient starting to walk again, both defects were closed with the skin, muscle, fascia composite flap described in this study. In case no.12, the reason for the elbow wound was unknown.

The patients presenting with elbow hygroma compli-

**Table 1.** Patients information**Tablo 1.** Olgulara ait veriler

No	Breed	Cause of the Elbow Region Wounds	Side	Sex	Age (Year)	Body Weight (kg)	Number of Prior Surgeries	Flap Dimensions (cm)
1	Rotweiler	Elbow hygroma	Left	M	1,5	34	1	13x8
2	Turkish Kangal	Elbow hygroma	Right	M	2	41	2	12x7
3	Mix Breed	Tumor Extirpation	Right	CM	6	23	1	12x6
4	Mix Breed	Elbow hygroma	Left	SF	1	21	1	8x5
5	Mix Breed	Tumor Extirpation	Right	F	11	26	2	9x5
6	Mix Breed	Tumor Extirpation	Left	M	8	25	2	10x5
7	Turkish Kangal	Elbow hygroma	Left	F	1	37	1	10x6
8	Mix Breed	Elbow hygroma	Left	SF	1.5	32	1	10x6
9	Turkish Kangal	Elbow hygroma	Right	M	2	39	1	10x6
10	Saint Bernard	Elbow hygroma	Left	M	1	52	4	12x7
11	Mix Breed	Tumor Extirpation	Right	CM	11	19	2	9x5
12	Turkish Kangal	Unknown	Left	M	8	38	Unknown	11x6
13	German Shepherd	Pressure Sores	Bilateral	CM	3	25	0	8x5
14	Turkish Kangal	Tumor Extirpation	Right	M	8	34	2	10x5

*M: intact male; F: Intact female; SF: spayed female; CM: castrated male*



**Fig 2.** Pre-operative appearance of defect in both caudal elbow regions in case no.13, a; immediate post-operative appearance of right elbow region, b; immediate post-operative appearance of left elbow region, c; post-operative day 10 appearance of left elbow region, d; post-operative day 10 appearance of right elbow region. Sutures in the distal part of the flap have opened and flap ends curled medially, e; post-operative day 20 appearance of right elbow region, f

**Şekil 2.** Onüç numaralı olgunun her iki kaudal dirsek bölgesindeki defektin preoperatif görüntüsü, a; sağ dirsek bölgesinin akut postoperatif görüntüsü, b; sol dirsek bölgesinin akut postoperatif görüntüsü, c; sol dirsek bölgesinin postoperatif 10. gün görüntüsü, d; sağ dirsek bölgesinin postoperatif 10. gün görüntüsü. Flebin distal kısmındaki dikişler açılmış ve flebin uçları mediale doğru kıvrılmış, e; sağ dirsek bölgesinin 20. gün postoperatif görüntüsü, f

cation had a mean age of 1.4 (SE 0.17) years and mean bodyweight of 36.5 (SE 3.56) kg, while the patients presenting with mass extirpation complications had a mean age of 8.8 (SE 0.97) years and a mean bodyweight of 25.4 kg (SE 2.45). In 13 dogs, the chronic wound in the elbow region was unilateral and in one case it was bilateral. Among the unilateral cases, the lesion was on the left side in 7 (53.8%) and on the right side in 6 (46.2%) cases. In 12 of the cases, at least one surgical intervention had been previously performed for the treatment of the chronic wound in the elbow region.

No complications such as; seroma, edema, distal or total flap necrosis or paresthesia was encountered in any of the cases. During suture removal in the follow-up examination of one case (case no.4) on day 10, two sutures were seen to be absent in the distal flap area. However, since subcutaneous tissues were not exposed, no additional treatment (bandage, ointment administration etc.) was carried out. In the examination of this case on day 20, healing was seen to have completed without any problem. In the day 10 examination of case no.13, sutures in the distal flap region were seen to have opened and rotated internally on the wound edge of the flap side (Fig. 2e). The wound edges were revised and sutured using the simple interrupted suture technique and Number 0 non-absorbable monofilament suture material (Prolene®, Ethicon). On day 20, healing without complication was observed and the sutures were removed.

## DISCUSSION

Surgical resection, severe trauma, infection, radiation necrosis and some congenital abnormalities may cause hard-to-close large defects in the body. The aim in closing these defects is to provide functional unity without producing tension. In the reconstruction of full thickness tissue losses of the body wall, it is important to select a method to close the defect with no dead spaces and protect the tissues beneath the defect [16].

In dogs, wounds of the elbow region may occur due to external traumas, ischemia in the skin resulting from exposure to long-term pressure, tumor, abscess, infection and as a complication of bursa extirpations [14].

Hygromas are described as chronic tissue swellings containing serous fluid and are caused by repetitive trauma on soft tissue overlying bony prominences. They are seen mostly in giant breeds (Great Dane, Irish Wolfhounds, Newfoundlands) and dogs younger than 2 years of age [17]. The 7 dogs included in this study due to their elbow hygroma complications had a mean age of 1.4 years and this was consistent with literature. The reason for the difference regarding breed distribution can be explained by the fact that dog breeds such as the Great Dane, Irish Wolfhound and Newfoundlands are not common breeds in

the geographical location in which the study was carried out.

Serosanguinous fluid accumulating in the dead space, formed as a result of loss of connection between the skin and subcutaneous tissue during reconstruction, is called seroma formation. This situation may cause secondary complications such as opening of sutures, and may be caused by failure to place a drain in the area following surgery [4,18]. In this study, two drains were applied to the recipient site during surgery and seroma formation was prevented. Also preparation of an island-style flap and transferring it to the recipient site through a tunnel greatly prevented formation of dead space.

Despite not being objectively measured, during suturing of the flap to the recipient site, the excessive tension may cause opening of the sutures, tissue ischemia and necrosis [18,19]. Particularly in axial pattern flaps, the diameters of blood vessels decrease towards the tip of the flap. In addition, the tension created during suturing may cause distal flap necrosis. Also, bending of the lifted flap during its transfer to the recipient site directly slows down cutaneous artery circulation, constituting another cause for distal flap necrosis [18]. In this study, it was observed that the anatomical course of the thoracodorsal artery pedicle was almost parallel to the sternum and that the prepared flap was bent approximately 90 degrees during transfer to the elbow region. Considering island artery flaps can be rotated up to 180 degrees [10], the fact that no distal or total flap necrosis was encountered in any of the cases in this study may be related to the preservation of flap circulation with this technique.

On the other hand, it has been reported that, as long as the cutaneous artery and vein are not damaged directly, there is no difference with regard to flap vitality between traditional axial pattern flaps and island artery flaps [20]. This also suggests that, observation of no complications, such as distal or total flap necrosis, cannot be solely attributed to the fact that the flap was prepared as an island artery flap. At this point, the mode of transfer of axial model flaps to the recipient site becomes important.

While the middle section of axial model flaps may be prepared in the shape of a tube for closure of distant wounds, a bridge incision may also be made to connect donor and recipient sites. Sometimes they may also be prepared in an "L" shape to close large and irregular defects. Peninsular flaps are larger than "L" shaped, "90 degrees" or "hockey stick" shaped flaps. However, it has also been expressed that, the more the flap is rotated, the more functional distance will decrease and the more the skin will fold [21]. Consequently, to the author's knowledge, since axial model flaps and island artery flaps transferred differently to the recipient site have not been compared separately, it may be wrong to assume that there is no difference regarding flap vitality between axial model flaps and island artery flaps [20].

Similar to the overlying cutaneous trunci muscle and skin, the latissimus muscle also feeds from branches of the thoracodorsal artery [5]. However, in this study, the latissimus dorsi muscle was not included in the flap. One reason for this is the fact that the latissimus dorsi muscle ends in the caudal shoulder depression and is not suitable for use as an island artery flap. Also, it has been observed that defects in the elbow region are not deep enough to require closure with another muscle layer. The fact that the bottom layer of the flap prepared in this study was formed by fascial tissue was a particular preference of the group of researchers.

The fascial tissue is an easily obtainable, easily vascularized tissue resistant to ischemia. In veterinary practice, the thoracolumbar fascia and fascia lata have been used for the reconstruction of various tissues like oral cavity mucosa, esophagus and urethra [11-15,22]. In the traditional cutaneous trunci myocutaneous composite flap, it has been reported that, when the flap is lifted, the latissimus dorsi and subcutaneous tissue between should not be included in the flap [8]. This situation prevents benefitting from the previously mentioned properties of the fascial tissue. Also, the fact that the fascia of the latissimus dorsi muscle covered the bottom section of the flap in this study, was seen as an important factor in lessening the tension on the sutures by forming a slippery surface in the recipient site. As a complication, opening of the sutures was only encountered in case numbers 4 and 13. The reason for suture opening and inward folding of the distal flap region in case no.13 was attributed to the fact that despite receiving medical treatment in the pre-operative period, the patient had laid on the floor for long periods during the post-operative period. The opening in the sutures in case no. 4 was too small to warrant revision. The reason for this opening could not be identified since there were no complications such as presence of edema or seroma formation.

Despite place a bandage over the flap area has some advantages like decrease dead space and reduce swelling, that is also known that bandage application may cause hypoxia, tissue damage and flap necrosis [21]. On the other hand, bandage application may not be performed after island arterial flap procedure [23]. In our study, postoperative bandage application was not performed to avoid to fail circulation in the thoracodorsal artery pedicle and to ensure adequate blood supply of the flap. Eventually, any common complication due to avoid bandage application was not observed.

The longer duration of surgery compared to other techniques is the only disadvantage of this method.

In the authors' opinion, the fact that the flap was prepared as an island arterial flap in this study was transferred to the recipient site via a subdermal tunnel and that the surface in contact with the defect was covered with fascial tissue,

were reasons for the low rate of complications. Also in this flap model, it was seen that the defect in the elbow region could be closed without causing tension and with minimal dead space. In conclusion, the island arterial composite flap consisting of the skin, cutaneous trunci muscle and fascia of the latissimus dorsi muscle may be an effective method in the reconstruction of chronic wounds in the elbow region.

## REFERENCES

- 1. Pavletic MM:** Pressure sores. In, Pavletic MM (Ed): Atlas of Small Animal Wound Management and Reconstructive Surgery. 3<sup>rd</sup> ed., 216-221, Wiley-Blackwell, Ames Iowa, 2010.
- 2. Swaim S, Bohling M:** Advances in small animal wound management. *Vet Focus*, 18 (1): 17-23, 2008.
- 3. Szentimrey D:** Principles of reconstructive surgery for the tumor patient. *Clin Tech Small Anim Pract*, 13, 70-76, 1998. DOI: 10.1016/S1096-2867(98)80031-5
- 4. Aper R, Smeak D:** Complications and outcome after thoracodorsal axial pattern flap reconstruction of forelimb skin defects in 10 dogs, 1989-2001. *Vet Surg*, 32, 378-384, 2003. DOI: 10.1053/jvet.2003.50043
- 5. Pavletic MM:** A comparison of the cutaneous trunci myocutaneous flap and latissimus dorsi myocutaneous flap in the dog. *Vet Surg*, 16, 283-293, 1987. DOI: 10.1111/j.1532-950X.1987.tb00954.x
- 6. Done SH, Goody PC, Evans SA, Stickland NC:** The thorax. In, Done SH, Goody PC, Evans SA, Stickland NC (Eds): Color Atlas of Veterinary Anatomy. Vol-3. 3<sup>rd</sup> ed., 195-261, Mosby Elsevier, London, 2014.
- 7. Pavletic MM:** Introduction to myocutaneous and muscle flaps. *Vet Clin North Am: Small Anim Pract*, 20, 127-146, 1990. DOI:10.1016/S0195-5616(90)50007-8
- 8. Hedlund CS:** Surgery of the integumentary system. In, Fossum TW (Ed): Small Animal Surgery, 2<sup>nd</sup> ed., 134-254, Mosby, China, 2002.
- 9. Pavletic MM:** New techniques in small animal reconstructive surgery. *Vet Quart*, 19 (Suppl.-1): 25-27, 1997. DOI: 10.1080/01652176.1997.9694791
- 10. Pavletic MM:** Pedicle grafts. In, Slatter D (Ed): Textbook of Small Animal Surgery, 3<sup>rd</sup> ed., 292-321, Saunders, Philadelphia, 2003.
- 11. Disa JJ, Klein MH, Goldberg NH:** Advantages of autologous fascia versus synthetic patch abdominal reconstruction in experimental animal defects. *Plast Reconstr Surg*, 97, 801-806, 1996. DOI: 10.1097/00006534-199604000-00017
- 12. Ugurlu K, Hüthüt İ, Özçelik D, Ozer K, Sakiz D, Yıldız K, Baş L:** Epithelialization process of free fascial flaps used in reconstruction of oral cavity mucosa defects in dogs. *Plast Reconstr Surg*, 113, 915-923, 2004. DOI: 10.1097/01.PRS.0000105625.27802.64
- 13. Ugurlu K, Karsidag T, Huthut I, Karsidag S, Ozer K, Sacak B, Akcal A:** Bare dorsal thoracic fascial flap for esophageal defects: An experimental study with dogs. *Surg Endosc*, 26, 1682-1689, 2012. DOI 10.1007/s00464-011-2093-3
- 14. Bongartz A, Carofiglio F, Balligand M, Heimann M, Hamaide A:** Use of autogenous fascia lata graft for perineal herniorrhaphy in dogs. *Vet Surg*, 34, 405-413, 2005. DOI: 10.1111/j.1532-950X.2005.00062.x
- 15. Battisti A, Polton G, Vries M, Friend E:** Chest wall reconstruction with latissimus dorsi and an autologous thoracolumbar fascia graft in a dog. *J Small Anim Pract*, 56, 218-222, 2015. DOI: 10.1111/jsap.12270
- 16. Handerson ER, Friend EJ, Toscano MJ, Parsons KJ, Tarlton JF:** Biomechanical comparison of canine fascia lata and thoracolumbar fascia: An *in vitro* evaluation of replacement tissues for body wall reconstruction. *Vet Surg*, 44, 126-134, 2015. DOI: 10.1111/j.1532-950X.2014.12247.x
- 17. White RAS:** Management of specific skin wounds. *Vet Clin North Am: Small Anim Pract*, 36, 895-912, 2006. DOI: 10.1016/j.cvs.2006.04.004
- 18. Amsellem P:** Complications of reconstructive surgery in companion animals. *Vet Clin North Am: Small Anim Pract*, 41, 995-1006, 2011.

DOI:10.1016/j.cvsm.2011.05.005

**19. Haar GT, Buiks SC, Delden MV, Reijntjes T, Sanchez RF, Kirpensteijn J:** Skin tension. **In,** Kirpensteijn J, Haar GT (Eds): *Reconstructive Surgery and Wound Management of the Dog and Cat*. 12-13, Manson Publishing, London, 2013.

**20. Sardinias JC, Pavletic MM, Ross JT, Kraus KH:** Comparative viability of peninsular and island axial pattern flaps incorporating the cranial superficial epigastric artery in dogs. *JAVMA*, 207 (4): 452-454, 1995.

**21. Wardlaw JL, Lanz OI:** Axial pattern and myocutaneous flaps. **In,**

Tobias KM, Johnston SA (Eds): *Veterinary Surgery Small Animal*. 1256-1270, Saunders, Missouri, 2012.

**22. Sade C, Ugurlu K, Ozelik D, Huthut I, Ozer K, Ustundag N, Saglam I, Bas L:** Reconstruction of the urethral defects with autologous fascial tube graft ia a rabbit model. *Asian J Androl*, 9, 835-842, 2007. DOI: 10.1111/j.1745-7262.2007.00271.x

**23. Remedios AM, Bauer MS, Bowen CV:** Thoracodorsal and caudal superficial epigastric axial pattern skin flaps in cats. *Vet Surg*, 18, 380-385, 1989. DOI: 10.1111/j.1532-950X.1989.tb01105.x