

Evaluation of Age Related Anti-Müllerian Hormone Variations in Domestic Cat

İlknur PİR YAĞCI ¹  İbrahim Mert POLAT ¹ Mert PEKCAN ²

¹ Department of Obstetrics and Gynecology, Faculty of Veterinary Medicine, Kırıkkale University, TR-71450 Kırıkkale - TURKEY

² Department of Biochemistry, Faculty of Veterinary Medicine, Ankara University, TR-06110 Ankara - TURKEY

Article Code: KVFD-2015-15288 Received: 09.02.2016 Accepted: 28.03.2016 Published Online: 28.03.2016

Abstract

Anti-Müllerian hormone (AMH) belongs to the Transforming Growth Factor- β (TGF- β) family and produces only in ovaries by the granulosa cells of growing follicles in females. Therefore the measurement of AMH levels plays an important role for the detection of the presence or absence of the ovaries. The aim of this study was to evaluate the individual AMH levels before and after ovariohysterectomy (OHE), to demonstrate mean AMH alterations in the absence of ovaries with blood sampling in different days after OHE, to demonstrate the age-related changes in serum AMH levels and investigate the usability of serum AMH levels as a diagnostic tool for detecting the presence of functional ovarian tissue in domestic cats. Totally 30 domestic cats were used for this study. The animals were allocated into 2 groups according to their ages; <1 year old (Group 1, n=13) and >1 year old (Group 2, n=17). Mean serum AMH concentrations of all cats at day 0 and day 3rd were found 3.15 ± 2.25 ng/mL and 0.38 ± 0.21 ng/mL respectively. Ten days after surgery, AMH levels of all spayed cats were below the minimum detectable concentration of the ELISA kit (<0.08 ng/mL). According to the age classification, the age of cats were correlated with AMH levels at day 0 ($r_s=0.293$, $P<0.05$) and at day 3 ($r_s=0.410$, $P<0.01$). It can be concluded that measurement of serum AMH concentrations is adequate for assessing the functional ovarian tissue in cats.

Keywords: Anti-Müllerian hormone, Cat, Ovariohysterectomy, Intact

Evcil Kedilerde Yaş İlişkili Anti-Müllerian Hormon Değişimlerinin Değerlendirilmesi

Özet

Anti-Müllerian hormon (AMH) Transforming Growth Factor Beta ailesinin bir üyesidir ve dişilerde sadece ovaryumlardaki büyüme olan granuloza hücrelerinden üretilir. Bu nedenle, ovaryumların varlığını ya da yokluğunu belirlemede AMH ölçümleri önemli rol oynamaktadır. Bu çalışmanın amacı evcil kedilerde ovariohisterektomi (OHE) öncesi ve sonrası bireysel AMH düzeylerinin değerlendirilmesi, OHE sonrası farklı günlerde alınan kan örneklerinde ortalama AMH değişimlerinin gösterilmesi, yaşa bağlı AMH düzeylerindeki değişimlerin belirlenmesi ve AMH düzeylerinin fonksiyonel ovaryum dokusunun belirlenmesinde bir tanı aracı olarak kullanılabilirliğinin araştırılmasıdır. Bu çalışmada toplam 30 evcil kedi kullanıldı. Hayvanlar yaşlarına göre iki gruba ayrıldı; <1 yaş (Grup 1, n=13), >1 yaş (Grup 2, n=17). Tüm kedilerin serum AMH konsantrasyonları 0 ve 3. günlerde sırasıyla 3.15 ± 2.25 ng/mL ve 0.38 ± 0.21 ng/mL olarak belirlendi. Operasyondan 10 gün sonra tüm kısırlaştırılmış kedilerin AMH düzeyleri ELISA kitinin ölçebildiği minimum değerden daha düşüktü (<0.08 ng/mL). Yaş sınıflandırmasına göre ise kedilerin yaşları ile AMH düzeyleri arasında 0. gün ($r_s=0.293$, $P<0.05$) ve 3. günde ($r_s=0.410$, $P<0.01$) korelasyon belirlendi. Sonuç olarak kedilerde fonksiyonel ovaryum dokusunun değerlendirilmesinde serum AMH konsantrasyonlarının ölçümü yeterli olacağı düşünüldü.

Anahtar sözcükler: Anti-Müllerian hormon, Kedi, Ovariohisterektomi, Kısırlaştırılmamış

INTRODUCTION

The female cat is classified as a seasonally polyestrous carnivore having an induced ovulation process after with vaginal stimulation or mating. Puberty depends on body weight (2.3-2.5 kg) and the photoperiod (14 hours bright light by day). Therefore in most cats, pubertal estrous

observed at 4-12 months of age but young cats (<1 age) may also have irregular estrous cycles. Overt behavioral signs of estrus may not be observed in all cats even the cat is in the mating season. Consequently, the owners may not identify the estrus signs of young cats. Cats have a long reproductive life and optimal breeding age is between 1.5-7 years ^[1,2].



İletişim (Correspondence)



+90 318 3574242/6068



ilknurpiryagci@gmail.com

Anti-Müllerian hormone (AMH) belongs to the Transforming Growth Factor- β (TGF- β) family and plays an important role in male sex differentiation with testosterone and insulin like growth factor-3 [3] and in females, it is known as a marker of ovarian follicular reserve and ovarian aging, tumor marker or tumor inhibitor and have roles in follicle development and oocyte maturation [4,5]. AMH have an inhibitory function in the antral follicle growth [4]. In females, AMH is produced only in ovaries by the granulosa cells of growing follicles. Therefore the measurement of AMH levels plays an important role for the diagnosis the presence or absence of the ovaries which have increasingly gain popularity [6-8].

The diagnosis of the spayed or intact status of female cats with unknown gynecologic history or Ovarian Remnant Syndrome (ORS) is based on history, clinical symptoms of estrus, vaginal cytology (recommended in follicular phase of the estrus cycle), hormonal analysis (estrogen and progesterone analysis with or without hormonal stimulation such as GnRH stimulation test), and exploratory laparotomy [9-11]. In ORS cases, the time period of presenting estrus following OHE may be observed within 12 months or may extend up to 9 years (mean 3 years) [9]. Because of this wide time gap, and the possibility of owning a cat elderly, it may be hard to determine whether the cat is intact or neutered.

Moreover, abdominal ultrasonography can enlighten the determination of the presence of ovaries in cats however its efficacy is depends on the practitioner's skills, the size of ovarian remnant tissue [10] and the stage of the cycle [12]. In recent years, the practicability of serum AMH levels to diagnose the presence of the ovaries in female cats is discussed in some studies [6-8] but additional studies are required to establish the references ranges of serum AMH levels in domestic cat.

The present study was aimed (1) to evaluate the individual AMH levels before and after ovariohysterectomy (OHE), (2) to demonstrate mean AMH alterations in the absence of ovaries with blood sampling in different days after OHE, (3) to demonstrate the age-related changes in serum AMH levels and (4) to investigate the usability of serum AMH levels as a diagnostic tool for detecting the presence of functional ovarian tissue in female domestic cats.

MATERIAL and METHODS

Study Material

This study was conducted in 30 healthy cats (ages ranged from 6 months to 5 years) which were referred for ovariohysterectomy in our clinics. The study was approved by the Kırıkkale University Local Animal Ethical Committee (16/01-16/12). All owners signed informed consequent. OHE sections were performed during mating season at interestrous stages.

In the present study, the animals were divided into 2 groups according to their age; <1 year old (Group 1, 13 cats) and >1 year old (Group 2, 17 cats). According to history, no estrus signs was observed in group 1 (except 4 cats) until OHE, in addition, all animals in group 2 showed at least one distinctive estrus cycle before the surgery.

Collection of blood samples

The blood samples were collected 3 consecutive times from all the animals *cephalic vein* into vacuum tubes. The collection times points were as follows (1) one h before the surgery, day 0, (2) three day after the surgery, day 3 and (3) ten day after the surgery, day 10. All the samples were stored at -20°C until analysis.

AMH analyses

The commercially enzyme-linked immunosorbent assay kit (Beckman Coulter®, AMH Gen II, USA) was used for determination of serum AMH levels according to the manufacturer instructions. The ELISA kit used in this study is based on two site immunoassay, utilizing two monoclonal antibodies of which the secondary antibodies labeled with biotin. Primary antibodies were coated in 96 well plates. All individual reagents (anti AMH biotin conjugate and streptavidin-HRP) and samples or standards are incubated one at a time. Extensive washing cycles were performed after each incubation period. Following final wash plates were incubated with chromogen solution before addition of the stop solution. The dual-wavelength absorbance measurements were taken at 450 and 620 nm.

Statistical Analysis

Data presented as the arithmetic mean and standard error of the mean. The Shapiro-Wilk test was used to control for the distribution of normality of the data. Serum AMH levels of cats before and after ovariohysterectomy was checked with *Wilcoxon* test. Pearson correlation test was used for determination of age and serum AMH interactions. $P < 0.05$ was considered to be significant. All analyses were carried out using commercial software (SPSS 14.0).

RESULTS

Mean serum AMH concentrations of Group 1 and 2 were given in *Table 1*.

Mean serum AMH concentrations of all cats without grouping at day 0, day 3rd and day 10th were found 3.15 ± 2.25 ng/mL, 0.38 ± 0.21 ng/mL and non-detectable concentrations, respectively (*Fig. 1*). There was a sharp decrease of serum AMH levels three days after surgery in all cats. Ten days after surgery, AMH levels of all spayed cats were below the detection limit of the ELISA kit (< 0.08 ng/mL).

According to ages of cats, in Group 1 and Group 2, serum AMH levels were found 1.86 ± 1.73 ng/mL and 3.57 ± 2.28

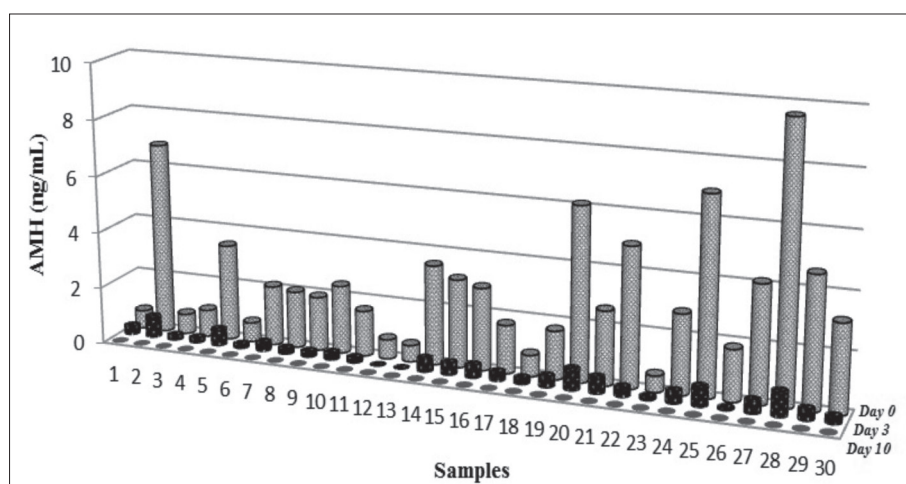


Fig 1. Mean serum AMH concentrations of all cats

Şekil 1. Tüm kedilerin ortalama AMH konsantrasyonları

Fig 2. Mean serum AMH concentrations of study groups at different days

Şekil 2. Çalışma gruplarında farklı günlerde ortalama serum AMH konsantrasyonları

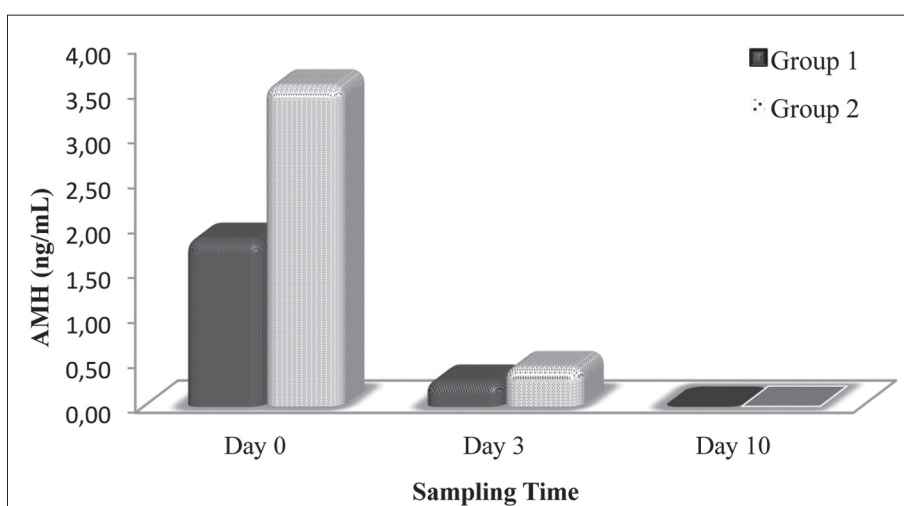


Table 1. Mean serum AMH concentrations of study groups

Table 1. Çalışma gruplarında ortalama serum AMH konsantrasyonları

Groups	Day 0	Day 3	Day 10
Group I (n=13)	1.86±1.73 ^a ng/mL	0.26±0.20 ^b ng/mL	ND
Group II (n=17)	3.57±2.28 ^a ng/mL	0.42±0.20 ^b ng/mL	ND

Values are means±S.E.M, ND: not detectable in all samples (<0.08 ng/mL).
^{a,b} Within rows, values with different superscripts are significantly different (P<0.01)

ng/mL in intact cats (Fig. 2), respectively (P<0.01). Serum AMH levels were dramatically decreased in both groups three days after OHE (P>0.05). The age of cats were highly correlated with AMH levels at day 0 ($r_s=0.293$, P<0.05) and at day 3 ($r_s=0.410$, P<0.01).

DISCUSSION

Anti Müllerian hormone is secreted from ovaries, especially preantral and antral follicles in woman and most of the domestic mammals. Ovaries are the unique source of this hormone which is an indicator for follicular population and reserve [13]. In cats, it is difficult to determine the ovarian

activity via vaginal cytology and endocrinology during the off season. Consequently, some methods are needed to determine the ovarian activity such as ovarian stimulation test which requires multiple sampling and repetitious visiting of the patient [1]. The best way to confirm the functional ovarian tissue is vaginal cytology however in the cat, cytological changes are not distinct and it is better to perform examinations during behavioral estrus [14]. These procedures are laborious, time-consuming and stressful for both owners and patients. Recently, AMH was suggested as an important indicator for the detection of presence of the ovaries in animals with unknown history and diagnosis of ORS cases as well in veterinary medicine. In a previous study [7], serum AMH levels were decreased after OHE in cat and also in bitch [6,8]. In the present study, similar to Axner *et al.* [7] and others [6,8], mean serum AMH levels (3.15 ng/mL) before OHE was dramatically decreased three days after OHE and dropped down to non-detectable concentrations at ten days after OHE in all cats (below 0.08 ng/mL). These findings support the hypothesis that the unique source of AMH is ovaries. Single sampling of AMH measurements is adequate to determine the presence of functional ovarian tissue and diagnose the ORS cases included in this study.

Bristol-Gould and Woodruff ^[15] reported that; TGF- β signals are present in primordial, primary and secondary follicles in cat ovary. Thus, all of the activation signals are ready for triggering the follicular selection process in domestic cats when they reach the pubertal age. AMH might have an important role in the regulation of follicles mainly in growing process and follicular selection for ovulation ^[13]. In this study, high serum AMH levels in sexually active cats, (Group 2) could be caused by currently presence of ovarian activity. Similar to Place *et al.*^[6] our results showed that cats had higher AMH concentrations when compared to bitches. In addition, the numbers of primordial follicles in ovarian cortex are greater in cats than other domestic mammals ^[14] might be reflect the high AMH production and secretion in this study. The production and secretion of AMH is independent and it is not affected from the stage of estrus cycle ^[15] even if sexual cycle variations are present in domestic mammals ^[16,17]. In a previous report ^[7], administration of buserelin injections did not affect the serum AMH levels in intact cats whereas the serum estradiol concentration which is a marker of terminal follicular development is altered after injections. To study cyclic variations of serum AMH levels in cats, sampling from higher number of animals are required for demonstration of AMH dynamics. Although, serum AMH concentrations are decreased after OHE in bitches ^[8] when compared to our results, these levels were non-detectable ten days after OHE (<0.08 ng/mL). This indicates that AMH might be a better indicator for detecting the presence of ovaries in cats than dogs. Moreover, measuring the serum AMH levels is useful for assessing the ovaries in cats with unknown reproductive history as well.

In conclusion, serum AMH levels showed a descent trend three days after OHE and undetectable concentrations were observed ten days after OHE. However there were individual variations of serum AMH levels between age comparison, a single sampling for evaluation of serum AMH concentrations ten days after OHE, appears to be adequate for assessing the functional ovarian tissue in cats with unknown reproductive history or ORS suspected cases.

REFERENCES

1. Johnston SD, Kustritz MVR, Olson PNS: The feline estrous cycle. In, Canine and Feline Theriogenology. 396-405, W.B. Saunders, Philadelphia, Pennsylvania, 2001.
2. Feldman EC, Nelson RW: Feline reproduction. In, Canine and Feline Endocrinology and Reproduction. 3rd ed., 1016-1017, W.B. Saunders, St. Louis, Missouri, 2004.
3. Nef S, Parada LF: Hormones in male sexual development. *Genes & Dev*, 14, 3075-3086, 2000. DOI: 10.1101/gad.843800
4. Dahiya P, Dahiya K, Dhankhar R, Hooda N, Nayar KD: The role of the anti-müllerian hormone in female fertility: A review. *J Clin Diagn Res*, 5, 384-387, 2011.
5. Karkanaki A, Vosnakis C, Panidis D: The clinical significance of anti-Müllerian hormone evaluation in gynecological endocrinology. *Hormones*, 10, 95-103, 2011. DOI: 10.14310/horm.2002.1299
6. Place NJ, Hansen BS, Cheraskin JL, Cudney SE, Flanders JA, Newmark AD, Barry B, Scarlett JM: Measurement of serum anti-Müllerian hormone concentration in female dogs and cats before and after ovariohysterectomy. *J Vet Diagn Invest*, 23, 524-527, 2011. DOI: 10.1177/1040638711403428
7. Axné E, Ström Holst B: Concentrations of anti-Müllerian hormone in the domestic cat. Relation with spay or neuter status and serum estradiol. *Theriogenology*, 83, 817-21, 2015. DOI: 10.1016/j.theriogenology.2014.11.016
8. Turna Yilmaz Ö, Toydemir TS, Kirsan I, Gunay Ucmak Z, Caliskan Karacam E: Anti-Müllerian hormone as a diagnostic tool for ovarian remnant syndrome in bitches. *Vet Res Commun*, 39,159-162, 2015. DOI: 10.1007/s11259-015-9639-0
9. Wallace MS: The ovarian remnant syndrome in the bitch and cat. *Vet Clin North Am: Small Anim Pract*, 21, 501-507, 1991.
10. Sontas BH, Gürbulak K, Ekici H: Ovarian remnant syndrome in the bitch: A literature review. *Arch Med Vet*, 39, 99-104, 2007.
11. Rohlertz M, Ström Holst B, Axné E: Comparison of the GnRH-stimulation test and a semiquantitative quick test for LH to diagnose presence of ovaries in the female domestic cat. *Theriogenology*, 78, 1901-1906, 2012. DOI: 10.1016/j.theriogenology.2012.06.027
12. Ball RL, Birchart SJ, May LR, Threlfall WR, Young GS: Ovarian remnant syndrome in dogs and cats: 21 cases (2000-2007). *J Am Vet Med Assoc*, 236, 548-553, 2010. DOI: 10.2460/javma.236.5.548
13. Visser JA, Themmen AP: Anti-Müllerian hormone and folliculogenesis. *Mol Cell Endocrinol*, 234, 81-86, 2005. DOI: 10.1016/j.mce.2004.09.008
14. Oliveira KS, Silva MAM, Brun MV, Pérez-Gutiérrez JF, Toniollo GH: Ovarian remnant syndrome in small animals. *Semina: Ciências Agrárias*, 33, 363-380, 2012. DOI: 10.5433/1679-0359.2012v33n1p363
15. Bristol-Gould S, Woodruff TK: Folliculogenesis in the domestic cat (*Felis catus*). *Theriogenology*, 66, 5-13, 2006. DOI: 10.1016/j.theriogenology.2006.03.019
16. Rico C, Médigue C, Fabre S, Jarrier P, Bontoux M, Clément F, Monniaux D: Regulation of anti-Müllerian hormone production in the cow: a multiscale study at endocrine, ovarian, follicular, and granulosa cell levels. *Biol Reprod*, 84, 560-571, 2011. DOI: 10.1095/biolreprod.110.088187
17. Monniaux D, Drouilhet L, Rico C, Estienne A, Jarrier P, Touzé JL, Sapa J, Phocas F, Dupont J, Dalbiès-Tran R, Fabre S: Regulation of anti-Müllerian hormone production in domestic animals. *Reprod Fertil Dev*, 25, 1-16, 2012. DOI: 10.1071/RD12270