

## Marbofloxacin Overdose: The Culprit for Acute Blindness in a Dog

İbrahim AKIN<sup>1</sup> Ümit KARADEMİR<sup>2</sup> Ali BELGE<sup>1</sup> Canberk BALIKÇI<sup>3</sup> Kerem URAL<sup>3</sup>

<sup>1</sup> Faculty of Veterinary Medicine, University of Adnan Menderes, Department of Surgery, TR-09000 Isikli Koyu, Aydın - TURKEY

<sup>2</sup> Faculty of Veterinary Medicine, University of Adnan Menderes, Department of Pharmacology and Toxicology, TR-09000 Isikli Koyu, Aydın - TURKEY

<sup>3</sup> Faculty of Veterinary Medicine, University of Adnan Menderes, Department of Internal Medicine, TR-09000 Isikli Koyu, Aydın - TURKEY

Article Code: KVFD-2015-15062 Received: 20.01.2016 Accepted: 13.03.2016 Published Online: 16.03.2016

### Abstract

In this case report, a 4 year old female terrier crossbred dog was presented with acute blindness following accidental high dose marbofloxacin administration was discussed. On initial referral to the clinic, a respiratory disease was evident, requiring antibiotic therapy and marbofloxacin (2.5 mg/kg) was prescribed. Meanwhile, patient was transferred to another veterinary practitioner specialized in large animal diseases, marbofloxacin had administered at an over dose (1050 mg/total dose through 3 days). The dog was then introduced back to our clinic with acute bilateral blindness. A diagnosis of marbofloxacin toxicity related to an overdose was made based on clinical examination and laboratory findings, excluding other relevant etiology. Dexamethasone was applied as initial treatment. In the following weeks, vision loss was eminent even without responding to bright light and not able to negotiate the obstacle course. According to the current literature, this is the first report on marbofloxacin overdose related acute blindness in dogs.

**Keywords:** Blindness, Marbofloxacin overdose, Dog

## Aşırı Doz Marbofloksasin: Bir Köpekte Akut Körlük İçin Olağan Şüpheli

### Özet

Bu olgu sunumunda yanlılıkla yüksek doz marbofloksasin uygulaması sonucunda 4 yaşlı, dişi, terrier melezi bir köpekte gelişen akut körlük vakası irdelenmiştir. Olgu kliniğe ilk başvurduğunda antibiyotik sağaltımı gerektiren bir solunum yolu enfeksiyonu olduğu belirlendi ve marbofloksasin (2.5 mg/kg) reçete edildi. Bu süre içerisinde, büyük hayvan hastalıkları konusunda uzmanlaşmış bir veteriner hekime götürülmüş ve marbofloksasin 3 gün boyunca aşırı dozda (1050 mg/3 gün boyunca toplam doz) uygulanmıştır. Köpek, uygulama sonrasında tekrar kliniğimize getirildiğinde akut körlük mevcuttu. Marbofloksasin toksisite tanısı, diğer ilişkili etiyoloji haricinde klinik, laboratuvar bulgular ve ilacın aşırı doz alımı temel alınarak konuldu. İlk sağaltım uygulaması olarak deksametazon uygulandı. Takip eden haftalarda görüş bozukluğunun olduğu, parlak ışığa tepki vermediği ve engellere takılmadan yürüyemediği tespit edildi. Son literatürlere göre köpeklerde marbofloksasinin aşırı doz uygulanması sonucu gelişen akut körlük ilk kez bildirilmiştir.

**Anahtar sözcükler:** Körlük, Marbofloksasin yüksek doz, Köpek

### INTRODUCTION

Adverse drug reactions are not commonly observed in pet ophthalmology, more commonly detected in the dog in contrast to the cat. The latter side effects vary from mere annoyance to life-threatening conditions.

As the dog is often interpreted to analyze the toxicity of several drugs, many agents were tested and reported to cause retinal and chorioretinal changes<sup>[1,2]</sup> in cats. In

the present case report a Terrier dog with acute blindness occurring following high dose marbofloxacin was described, to those of which, in the present authors' practice have never been reported.

### CASE HISTORY

A 4 years old, unneutered crossbred Terrier breed dog, weighing 10 kg, was presented to the clinic with upper respiratory clinical signs. On initial referral to our clinic



#### İletişim (Correspondence)



+90 256 2470700; Fax: + 90 256 2470720



umitkarademir@yahoo.com


marbofloxacin with a dose of 2.5 mg/kg for at least 1 week and an upper airway anti-inflammatory drug, oxolamine were prescribed. The owner declined further therapy at the University Clinic, and indicated that the recommended drugs would be used at private veterinary practice in Nazilli, Aydın in Turkey. Afterwards the private veterinary surgeon who was specialized in large animal diseases, administered marbofloxacin at an over dose of 35 mg/kg (a total dose of 1050 mg) for 3 days. The dog was then referred back to our clinic with acute blindness on day 4. Hematological and serum biochemical analysis were within reference ranges (data not shown). At physical examination the dog was reluctant to walk, and eyelids were quite open. When the dog reaches the color differentiation area on the flat ground, the dog was lifting its limbs more than normal (Fig. 1). This was evaluated as the dog could not recognize the color differentiation on the ground.

During ophthalmic examination in both eyes, while cornea and iris were normal, vascularization in conjunctiva and pupillary dilatation were identified. Edema and papillomatosis on optical nerve, and dilatation in the optical nerve vessels in both eyes were determined

(Fig. 2). A preliminary diagnosis of marbofloxacin toxicity was made, excluding any other apparent reasons, as the owner reported no other drug usage. A blood sample was with-drawn and forwarded to Pharmacology and Toxicology Department for analyzing plasma marbofloxacin level.

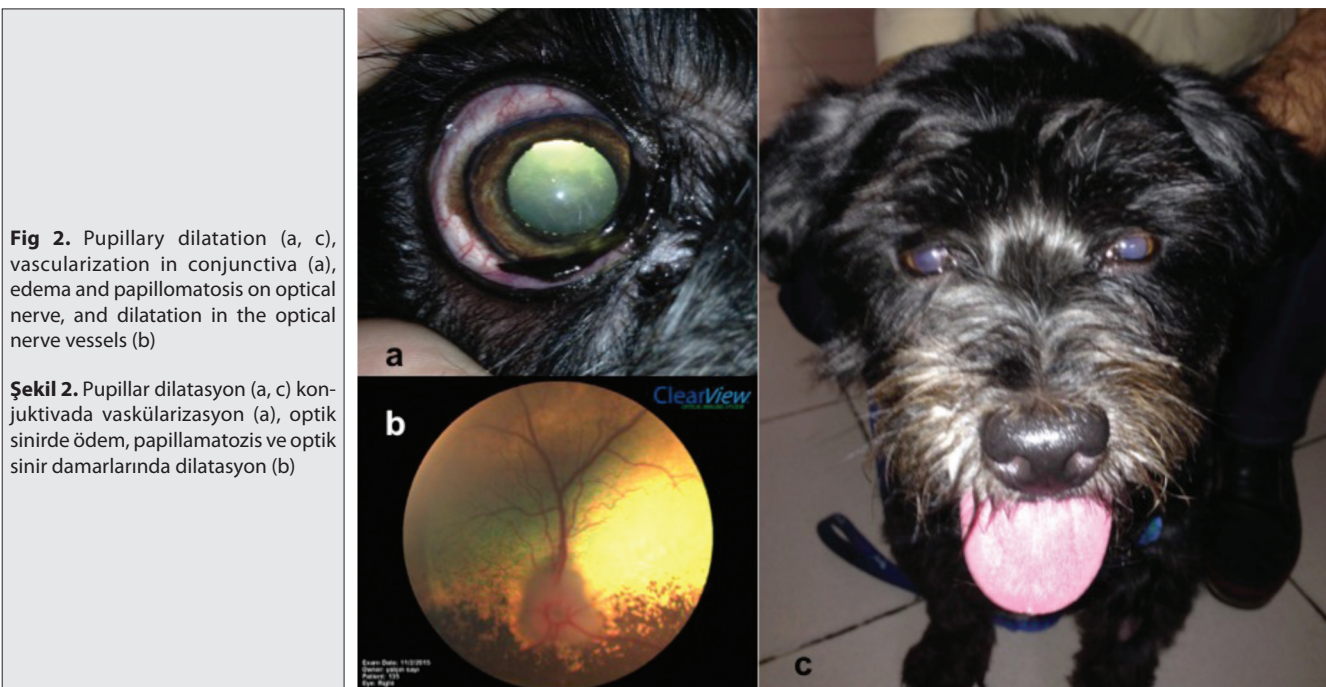
Plasma marbofloxacin level was determined by high performance liquid chromatography (HPLC) with a fluorescence detector following the extraction procedure. A marbofloxacin standard was used from Fluca (Batch No. 34039, 98% putiry; Fluka, China). Plasma extraction of marbofloxacin and the analysis by HPLC was according to the method of Karademir et al.<sup>[3]</sup> which was validated in our laboratory conditions.

Dexamethasone (Maxidex ophthalmic pomad® Alcon) was suggested 4 times a day (4x1). A telephone call following 2 weeks later indicated that the dog was unable to orient, without responding to bright light. Three weeks later a physical examination along with ocular investigation revealed that the dog was still not negotiate an obstacle course.



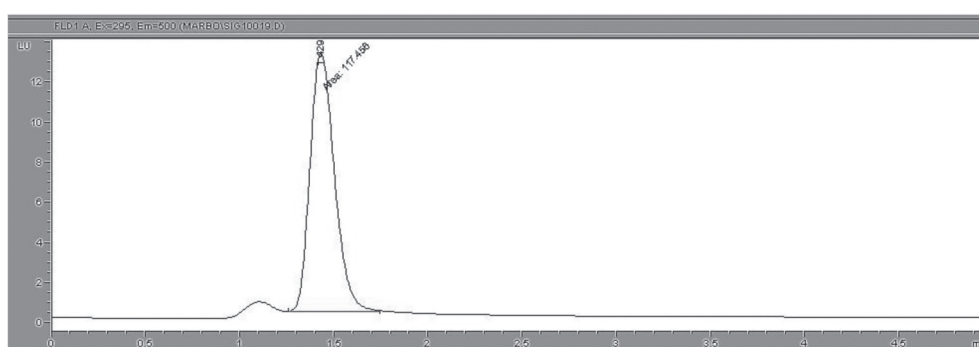
**Fig 1.** Realized of color differentiations on the ground, during the walking and lifting limbs (a. forelimb, b. hindlimb) more than normal

**Şekil 1.** Zemindeki renk değişiklikleri sebebiyle yürüme ve adım atışı sırasında ekstremiteelerin (a. ön ekstremitte, b. arka ekstremitte) normalden daha fazla kaldırılması



**Fig 2.** Pupillary dilatation (a, c), vascularization in conjunctiva (a), edema and papillomatosis on optical nerve, and dilatation in the optical nerve vessels (b)

**Şekil 2.** Pupillar dilatasyon (a, c) konjunktivada vaskülarizasyon (a), optik sinirde ödem, papillamatozis ve optik sinir damarlarında dilatasyon (b)



**Fig 3.** HPLC chromatogram of analyzed plasma sample

**Şekil 3.** Analiz edilen plazma örneğinin HPLC kromatogramı

The level of marbofloxacin in the plasma sample was found as 0.5 µg/ml (Fig. 3).

## DISCUSSION

Dogs are target species for testing toxicity of several drugs; where several compounds have been found to cause retinal or chorioretinal alterations [4]. To this content it was previously described that quinine produced rapid vasoconstriction of the retinal arterioles, optic disc atrophy and retinal ganglion loss [5]. Taking into account quinolones were derived from quinine [6], and there exists structural relationship between fluoroquinolones and quinine differing via an oxygen molecule [7-9], it may be speculated that similar ocular reactions may occur for both drugs. Excluding other probable reasons, besides marbofloxacin was the solely used injectable drug at the onset of clinical signs, it safely appeared that the usage of marbofloxacin was responsible for the vascularization in conjunctiva, dilation on pupilla and optical nerve vessels, edema and papillomatosis on optical nerve contributing to the blindness that developed in the present case.

In the current report, we hypothesized that it may be a canine case of sudden acquired retinal degeneration [10], although, to the present authors knowledge, at the time of writing and since then a canine case of retinal degeneration has not been documented elsewhere. A toxic insult to the retina was proposed similar to what have been reported previously [10], the only other drug, oxolamine phosphate, had not been associated with retinopathy. However the association of fluoroquinolones and visual disturbances [11] in cats [2,10,12] has now been well established. The use of enrofloxacin has been attributed to visual impairment with growing numbers of anecdotal reports [10]. Fluoroquinolones have long been recognized to cause acute retinal degeneration in cats [13]. Although unclearly explained, it has been suspected that the mechanism is dose dependent. Higher doses cause more severe side effects [1,14,15].

Given the molecular findings for fluoroquinolone-induced retinal degeneration and consecutive blindness in cats, ABCG2 transport protein deficiency was suggested as the responsible reason in feline retina [16]. Since previously, no case reports were presented for dogs, the present

authors may briefly suggest that species difference might be a confounding factor involving the expression of ABCG2 transporters in dogs [16,17].

In the present report, a high dose of the drug was evident, 4 days prior to the retinal degeneration being detected. Marginal renal disorders may be related to further increase in the plasma level of the drug [10]. However in the present study, the case presented no renal dysfunction based on normal levels of urea, creatinine and cystatin-C levels. Moreover, elevated plasma level for marbofloxacin was not present; since the dog was referred to the clinic 4 days after exposure to high dose exposure, indicating low plasma level as 0.5 mg/ml.

In summary, it may be suggested that marbofloxacin overdose may result in acute blindness in dogs, similar to what have been previously described in cats.

## REFERENCES

1. Gelatt KN, van der Woerd A, Ketring KL, Andrew SE, Brooks DE, Biros DJ, Denis HM, Cutler TJ: Enrofloxacin-associated retinal degeneration in cats. *Vet Ophthalmol*, 4, 99-106, 2001. DOI: 10.1046/j.1463-5224.2001.00182.x
2. Giuliano EA, van der Woerd A: Feline retinal degeneration: Clinical experience and new findings (1994-1997). *J Am Anim Hosp Assoc*, 35, 511-514, 1998. DOI: 10.5326/15473317-35-6-511
3. Karademir U, Boyacıoğlu M, Kum C, Sekkin S: Comparative pharmacokinetics of enrofloxacin, danofloxacin and marbofloxacin following intramuscular administration in sheep. *Small Rumin Res*, 133, 108-111, 2015. DOI: 10.1016/j.smallrumres.2015.09.007
4. Wilton LV, Pearce GL, Mann RD: A comparison of ciprofloxacin, norfloxacin, ofloxacin, azithromycin, and cefixime examined by observational cohort studies. *Br J Clin Pharmacol*, 41, 277-284, 1996. DOI: 10.1046/j.1365-2125.1996.03013.x
5. Budinger JM: Diphenylthiocarbazon blindness in dogs. *Arch Pathol*, 71, 304-310, 1961.
6. Andersson MI, MacGowan AP: Development of the quinolones. *J Antimicrob Chemother*, 51, 1-11, 2003. DOI: 10.1093/jac/dkg212
7. Blum MD, Graham DJ, McCloskey CA: Temafloxacin syndrome: Review of 95 cases. *Clin Infect Dis*, 18, 946-950, 1994. DOI: 10.1093/clinids/18.6.946
8. Allan DS, Thompson CM, Barr RM, Clark WF, Chin-Yee IH: Ciprofloxacin-associated hemolytic-uremic syndrome. *Ann Pharmacother*, 36, 1000-1002, 2002. DOI: 10.1345/aph.1A350
9. Campi P, Pichler, WJ: Quinolone hypersensitivity. *Curr Opin Allergy Clin Immunol*, 3 (4): 275-281, 2003.
10. Abrams-Ogg A, Holmberg DL, Quinn RF, Keller C, Wilcock BP, Claffey FP: Blindness now attributed to enrofloxacin therapy in a

previously reported case of a cat with acromegaly treated by cryohypophysectomy. *Can Vet J*, 43 (1): 53-54, 2002.

**11. Takayama S, Hirohashi M, Kato M, Shimada H:** Toxicity of quinolone antimicrobial agents. *J Toxicol Environ Health*, 45, 1-45, 1995. DOI: 10.1080/15287399509531978

**12. Glaze MB, Gelatt KN:** Feline ophthalmology. In, Gelatt KN (Ed): *Veterinary Ophthalmology*. 3<sup>rd</sup> ed., 997-1052, Lippincott/Williams & Wilkins, Philadelphia, 1999.

**13. Pallo-Zimmerman LM, Byron JK, Graves TK:** Fluoroquinolones: Then and now. *Compend Contin Educ Vet*, 32 (7): E1-E9, 2010.

**14. Ford MM, Dubielzig RR, Giuliano EA, Moore CP, Narfström KL:** Ocular and systemic manifestations after oral administration of a high

dose of enrofloxacin in cats. *Am J Vet Res*, 68, 190-202, 2007. DOI: 10.2460/ajvr.68.2.190

**15. Wiebe V, Hamilton P:** Fluoroquinolone-induced retinal degeneration in cats. *J Am Vet Med Assoc*, 221, 1568-1571, 2002. DOI: 10.2460/javma.2002.221.1568

**16. Ramirez CJ, Minch JD, Gay JM, Lahmers SM, Guerra DJ, Halderson GJ, Schneider T, Mealey KL:** Molecular genetic basis for fluoroquinolone-induced retinal degeneration in cats. *Pharmacogenet Genomics*, 21, 66-75, 2011. DOI: 10.1097/FPC.0b013e3283425f44

**17. Haritova AM, Krastev SZ, Santos RR, Schrickx JA, Fink-Gremmels J:** ABC transporters in the eyes of dogs and implications in drug therapy. *Curr Eye Res*, 38, 271-277, 2013. DOI: 10.3109/02713683.2012.754903