

# Interdental and Interfragmentary Stabilisation (IAIS) of Mandibular Symphysis Separations and Parasymphyseal Fractures in Cats: A New Technique

Kürşat ÖZER <sup>1</sup>  Murat KARABAĞLI <sup>1</sup> Gamze KARABAĞLI <sup>2</sup>

<sup>1</sup> Faculty of Veterinary Medicine, University of Istanbul, Department of Surgery, TR-34320 Avcılar, Istanbul - TURKEY

<sup>2</sup> Istanbul Municipality, Cebeci Provisional Animal Shelter, TR-34270 Sultangazi, Istanbul - TURKEY

Article Code: KVFD-2015-14899 Received: 19.12.2015 Accepted: 31.01.2016 Published Online: 17.02.2016

## Abstract

In veterinary literature, in order to achieve a more rigid stabilisation and complication-free recovery, both methods of circular (interfragmentary) and 8-shaped interdental cerclage wiring around the canine teeth are recommended in the treatment of open, infected and dislocated mandibular symphysis separations in cats. This is the only way to counteract craniocaudal and dorsoventral forces acting on the mandibular symphysis. However, this prolongs intraoperative time for the application and removal of cerclage wire, as well as necessitating deep sedation or general anaesthesia for removal. The aim of this study is to present the application stages and efficacy of a new technique (IAIS– Interdental and Interfragmentary Stabilisation) achieving both interdental and interfragmentary stabilisation in a single operation using only cerclage wire, with no need for extra stabilisation. For this purpose, the authors used the IAIS technique in the treatment of 46 patients presented to the surgery clinic between the years 2007-2015 and diagnosed with mandibular symphysis separation. Weekly post-operative follow-up examinations were carried out and clinical recovery time was evaluated. In conclusion, this new technique may be used effectively in the treatment of dislocated-uninfected and open-infected-dislocated mandibular symphyhsis separations.

**Keywords:** *Symphysis mandibula seperations, Cat, Cerclage wire, Interdental and interfragmentary stabilisation*

## Kedilerde Symphysis Mandibula Ayrılmalarının ve Parasymphyseal Kırıkların Sağaltımında Interdental ve Interfragmenter Stabilizasyon (İVİS): Yeni Bir Teknik

### Özet

Veteriner literatürde kedilerin, açık enfekte ve dislokasyonlu symphysis mandibula ayrılmalarının sağaltımında, daha rijit bir stabilizasyon ve komplikasyonsuz bir iyileşme elde edebilmek için, hem dairesel (interfragmenter) hem de canin dişler etrafından '8' şeklinde interdental serklaj teli uygulamasının bir arada kullanılması önerilmektedir. Bunun nedeni, symphysis mandibula üzerine etkiyen craniokaudal ve dorsoventral kuvvetlerin etkisinin ancak bu şekilde karşılanabilecek olmasıdır. Bu durum uygulama ve serklaj telinin uzaklaştırılması için geçen intraoperatif süreyi uzatmakta, aynı zamanda uzaklaştırma esnasında derin bir sedasyon ya da genel anesteziyi gerekli kılmaktadır. Bu çalışmanın amacı, ek bir stabilizasyon gerekmez, sadece serklaj teli kullanılarak tek seferde hem interdental hem de interfragmenter stabilizasyon sağlayabilen yeni bir tekniğin (İVİS-interdental ve interfragmenter stabilizasyon) uygulama aşamalarını ve etkinliğini ortaya koymaktır. Bu amaçla 2007-2015 yılları arasında kliniğimize getirilen ve symphysis mandibula ayrılması tanısı konan 46 hastanın sağaltımında İVİS tekniğini kullandık ve postoperatif haftalık kontroller yaparak klinik iyileşme süresini değerlendirdik. Sonuç olarak bu yeni tekniğin kedilerde dislokasyonlu enfekte olmayan, açık enfekte ve dislokasyonlu symphysis mandibula ayrılmalarının sağaltımında etkin olarak kullanılabileceği sonucuna vardık.

**Anahtar sözcükler:** *Symphysis mandibula ayrılmaları, Kedi, Serklaj teli, Interdental ve interfragmenter stabilizasyon*

## INTRODUCTION

The mandible is formed by the rostral median meeting of the two hemimandibulae in the joint known as the mandibular symphysis <sup>[1]</sup>. The cartilage structure forming the mandibular symphysis both acts as a growth centre

and determines the shape and form of the anterior mandible by growing in a specific direction <sup>[2]</sup>.

Clear differences are present between the mandibular symphyseal joint structure of adult mammals. While in some mammals fusion in this joint is never completed



İletişim (Correspondence)



+90 212 4737070/17296



ozero\_kursat@yahoo.com

(amphiarthrosis), there is a union in some (synarthrosis), and complete ossification in others (synostosis). In small adult cats, the mandibular symphysis is in the form of a synarthrosis<sup>[3,4]</sup>.

Road traffic accidents occupy first place in the etiology of mandibular symphysis separations, followed by falling from a height, fighting with other animals, firearm injuries and, rarely seen in cats, periodontal diseases and neoplasias<sup>[5,6]</sup>. Mandibular symphysis separation can easily be diagnosed with inspection and palpation of the free movement of one hemimandibula against the other<sup>[7]</sup>.

The incidence of jaw fractures in cats varies between 15-23% among all fractures<sup>[8,9]</sup>. Mandibular symphysis separations occur at a rate of 73% of all jaw fractures<sup>[8]</sup>. Mandibular symphysis separations can be classified as: uninfected with no dislocation; uninfected with dislocation; and open, infected with dislocation<sup>[10]</sup>.

In humans, vertical fractures of the mandibular region between the mandibular symphysis and canine tooth are known as parasymphyseal fractures<sup>[11]</sup> and are reported to present 19.5%-27% of mandibular fractures<sup>[12]</sup>. In dogs, the area between two mandibular canine teeth is described as the parasymphyseal region. Mandibular symphysis separations and fractures including the canine tooth are regarded as parasymphyseal fractures and the incidence has been calculated<sup>[13]</sup>. In this study, the authors considered cases in which the mandibular symphysis separation started rostrally and continued ventrally incorporating a fragment of one hemimandibula, to be cases with a parasymphyseal fracture.

In the treatment of mandibular symphysis separations, while options include; cerclage wiring, transmandibular pin and screw applications, the most prominent method is the straightforward but effective technique of treatment with cerclage wire<sup>[1]</sup>. However, in treatment using cerclage wire, only one of either interdental or interfragmentary stabilisation can be achieved<sup>[7]</sup>. In this study, we aimed to demonstrate the application stages and efficiency of a new technique (IAIS) achieving both interdental and interfragmentary stabilization by a single cerclage wire.

## MATERIAL and METHODS

The material of the study consisted of cats presented to the surgery clinic with a history of trauma between the years 2007-2015. Following clinical and radiological examinations, cats diagnosed with uninfected-dislocated and open-infected-dislocated mandibular symphysis separation were included in the study. The cats had no other orthopaedic lesions apart from mandibular symphysis separation in the lower jaw and the mandibular canine teeth were intact in all cases. All cats were radiologically assessed, with regard to presence of lung damage due to trauma. Patients with breathing difficulties and epistaxis,

together with those with haemathorax, pneumothorax and atelectasis were stabilised before surgery.

Patients deemed to be suitable for surgery following pre-anaesthesia assessment were put under general anaesthesia with 4-6 mg/kg IV propofol (Pofol®, Sandoz) and positioned in ventral recumbency. Beginning ventrally at the third incisor tooth on the medial aspect of the canine teeth and avoiding causing damage to teeth roots, two oblique canals opening into the mouth were formed using a Kirschner wire of 0.8-1mm diameter, depending on the cat's size (Fig. 1-a). A 0.6mm-cerclage wire was threaded through these holes leaving both ends of the wire within the oral cavity (Fig.1 b1, b2, b3). The ends of the cerclage wire within the oral cavity were bent caudo-lateral to the mandibular canine teeth (Fig. 1c) and stabilised by tightening above the gingiva on the ventral part of the incisor teeth (Fig. 1 d1, d2, d3). Patient owners were advised to have amoxicilline clavulonic acid 22 mg/kg IM (Synulox®, Pfizer) injections administered to their cats for 5 days post-operatively and feed their cats a soft diet and wet food for 10 days. All cats were stabilised during same-day reanimation, returned to their owners and discharged.

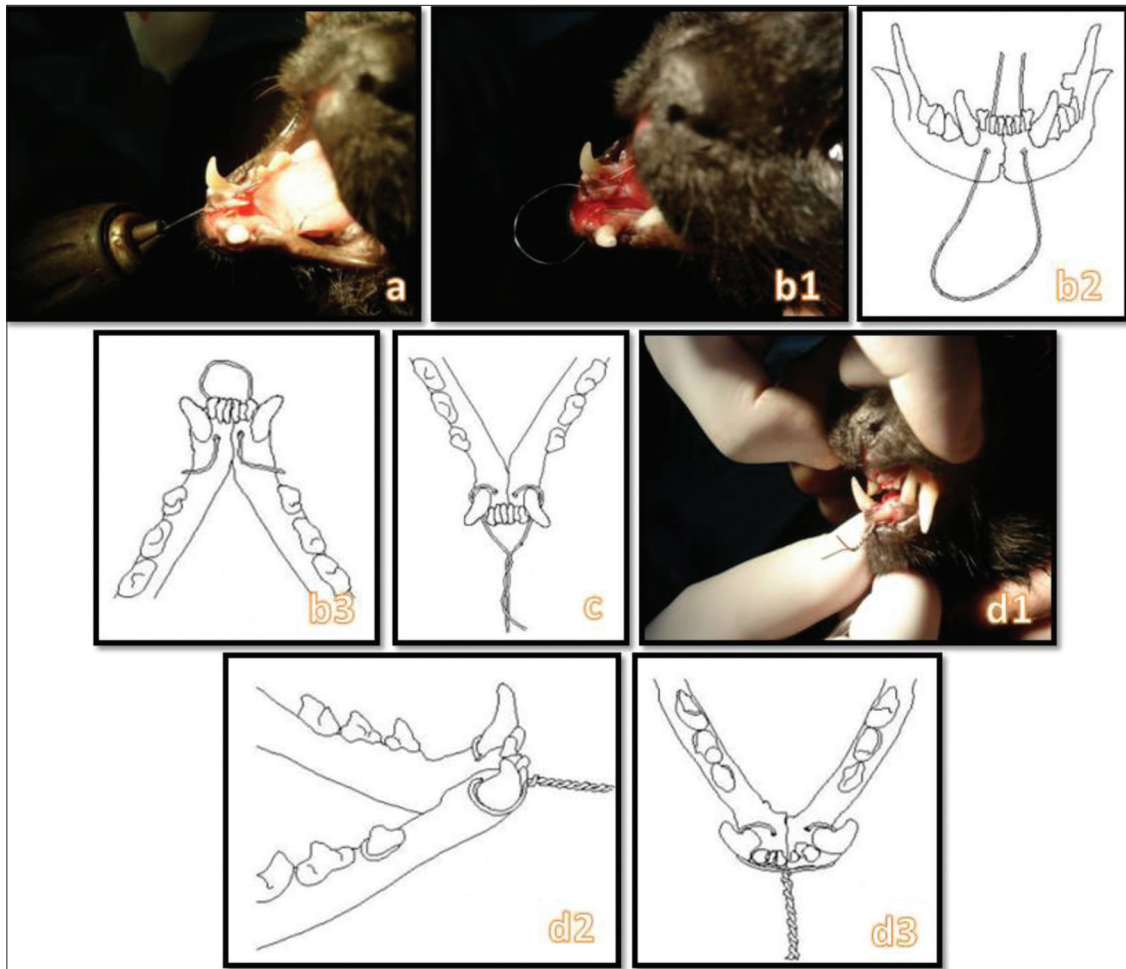
Post-operative weekly follow-up examinations of the cases were carried out and recovery was evaluated. During these examinations, patients displaying no instability upon cranio-caudal and dorso-ventral manipulation of the joint were considered to have recovered and the cerclage wire was removed.

Cats determined to have clinically recovered were sedated using 1 mg/kg IM xylazine HCl (Rompun® 2%, Bayer). The cerclage wire was removed by cutting through two points, one inside the mouth and the other to the cranial of the incisor teeth.

The age, breed, gender, fracture type and recovery times of the patients were recorded. The Kruskal-Wallis test was used to demonstrate the effect of etiology on healing time and the Mann Whitney-U test was used to show the effect of the fracture type and gender on healing time. The Spearman test was used to determine the relationship between age and healing time. Statistical significance level was regarded as  $P < 0.05$ . Analyses were carried out using the SPSS 13.0 programme.

## RESULTS

The material of this study comprised a total of 46 cats, of which 30 were male and 16 female, of different breeds and ages presented to the surgery clinic. Clinical examination revealed uninfected-dislocated mandibular symphysis separation in 20 cats, open-infected-dislocated mandibular symphysis separation in 23 cats and open-infected-dislocated parasymphyseal fracture in 3 cats. Breed distribution was; 4 Persian, 3 Van, 2 Scottish Fold, 2 Siamese and 35 mixed breed. History taking revealed road



**Fig 1.** Stages of the IAIS technique for the surgical treatment of mandibular symphysis separations. Establishing canals opening into the mouth using a 0.8-1.0 mm Kirschner wire on the medial aspect of the canine teeth and ventral aspect of the 3<sup>rd</sup> incisive tooth (a), advancing cerclage wire into oral cavity through canals (b1), cranial aspect (b2), intraoral aspect (b3), bending of cerclage wire ends inside the mouth caudolateral to mandibular canine teeth (c); twisting and securing cerclage wire ends over gingiva ventral to incisive teeth (d1), lateral aspect (d2), rostral aspect (d3)

**Şekil 1.** Symphysis mandibula ayrılmalarının IVIS tekniği kullanılarak yapılan cerrahi tedavisinin aşamaları. Köpek dişlerinin mediali, 3. insisiv dişin ventralinde 0.8-1.0 mm çapında bir kirchner teli ile ağız içine açılan birer kanal oluşturulması (a), açılan kanallardan serklaj telinin ağız boşluğuna doğru ilerletilmesi (b1), kranial görünüm (b2), intraoral görünüm (b3), serklaj telinin ağız içerisinde kalan uçlarının mandibular köpek dişlerinin kaudo-lateraline doğru bükülmesi (c), ve insisiv dişlerin ventralinde, diş etleri üzerinde sıkılarak sabitlenmesi (d1), lateral görünüm (d2), rostral görünüm (d3)

traffic accident in 23 cats, falling from a height in 14 cats and unknown etiology in 9 cats. Recovery was observed to take place between 2-5 weeks (average 3 weeks) (Table 1). No complications such as; loosening of the cerclage wire, infection or non-union were seen in any of the patients. Application time of the technique was not longer than 4 minutes in any of the cases.

Three cats were presented to our clinics with breathing difficulties and epistaxis together with those with haemathorax, pneumothorax and atelectasis respectively. Thoracocentesis was performed to haemathorax and pneumothorax patients and the own blood of haemathorax patient which we removed from thorax, was auto-transfused. Oxygen support and symptomatic therapy were performed these three cat before procedure.

Of the three cats with a parasymphyseal fracture, two were 12-months old and one was 24-months old. All three parasymphyseal fractures were open, infected and dislocated. Etiologically, 2 cats had suffered road traffic accidents, while the reason for the fracture in the third cat was unknown.

Due to its fibrocartilagenous structure, since the mandibular symphysis radiologically appeared as a radioluscent line even after recovery, post-operative radiographic assessment was not performed.

Statistical analysis demonstrated that etiology, fracture type or gender had no effect on recovery time ( $P>0.05$ ). The relationship between age and recovery, however, was found to be significant ( $P<0.05$ ).

Table 1. Patient information

Table 1. Olgulara ait bilgiler

Cases		Fracture Type							
		Uninfected with Dislocation		Open, Infected with Dislocation		Open, Infected with Dislocation- Parasymphseal		Total	
		n	%	n	%	n	%	n	%
		20	43.4	23	50.0	3	6.6	46	100
Breed	Persian	3	15	1	4.4	-	-	4	8.7
	Scottish Fold	1	5	1	4.4	-	-	2	4.3
	Siamese	2	10	-	-	-	-	2	4.3
	Turkish Van	1	5	2	8.7	-	-	3	6.6
	Mix	13	65	19	82.5	3	100	35	76.1
Sex	Male	13	65	16	69.5	1	33.3	30	65.2
	Female	7	35	7	30.5	2	66.7	16	34.8
Cause	Traffic Accident	6	30	15	65.2	2	66.6	23	50.0
	High Rise	9	45	5	21.7	-	-	14	30.4
	Unknown	5	25	3	13.1	1	33.4	9	19.6
Other Parameters									
Age	Months	6-60		6-36		12-24		6-60	
	Average	20		15.4		16		17.4	
Healing Time	Weeks	2-5		2-5		3-4		2-5	
	Average	2.95		3.13		3.25		3.065	

## DISCUSSION

The most prominent method in the treatment of mandibular symphysis fractures is the simple yet effective technique of cerclage wiring [5]. This is due to the fact that the mandibular bone is almost completely filled with tooth roots at the level of the symphysis and this, in turn, leads to reluctance to employ invasive methods for treatment [1].

In fracture treatment, using cerclage wire alone to achieve stabilisation provides one of either interdental or interfragmentary stability [7]. Particularly in the treatment of open, infected and dislocated mandibular symphysis cases, the combined application of circular and interdental 8-shaped cerclage wiring around the canine teeth has been reported to decrease cranio-caudal and dorso-ventral forces affecting the separation and provide a more rigid stabilization [6,14-16]. With the use of the IAIS technique, it was seen that dorso-ventral and cranio-caudal forces were easily counterbalanced without any need for extra stabilisation.

It has been reported that healing that will allow cerclage wire removal in mandibular symphysis fractures is achieved in 4-6 weeks [16-19]. In the present study, this duration was determined to be 3 weeks. This indicates that, in comparison to previously described methods, the IAIS technique provides shorter healing time.

The growth center, where endochondral type bone

formation occurs within the mandibular symphysis, remains active until the age of 60-days when temporary canine teeth eruption is completed. Once cartilage growth is complete, the mandibular symphysis remains a fibrocartilagenous structure [2]. In other words, regardless of age, the chances of mandibular symphysis separation occurring in cats older than 2-months can be considered a high possibility under the same conditions. This demonstrates that, mandibular symphysis separations can be observed in adult cats, and not only in growing cats. At the same time, the fact that the mean age of the cats with mandibular symphysis separation in this study was 17 months is informative.

The oral mucosa and gingiva is highly vascularized and can give a rapid inflammatory response to bacterial infection. Also, saliva and gingival fluid contain numerous antibacterial substances contributing to the non-specific defense system. Properties such as; the bactericidal effect of lysosymes and hypothiocyanites in the saliva, the effect of IgA preventing bacteria from attaching to the oral mucosa, and the lactoferrin within the saliva binding the iron needed by bacteria, are components of the oral cavity defense mechanism [20]. In this study, the fact that no infection complications were encountered in any of the patients during weekly post-operative follow-ups can be explained by the post-operative antibiotic use in addition to this mechanism.

Desirable features for the technique used in the treatment of mandibular fractures are; quick application,

atraumatic procedure and low cost, anatomical reduction, a rigid fixation and complete occlusion<sup>[17]</sup>. Anatomical reduction and rigid fixation are essential for bone healing and return to normal function. With the technique developed by the authors, the most rigid fixation possible using cerclage wire is applied using a single method. This technique also has the cerclage wire-related advantages of quick application, low cost, less invasiveness compared to other techniques, less soft tissue damage and rapid return to food consumption<sup>[16]</sup>. However, the most recommended method in the treatment of mandibular symphysis separations is for both ends of the cerclage wire to be advanced subcutaneously on the lateral side of each hemimandibula, exiting through a medial skin incision made on the ventral aspect of the mandibular symphysis and intertwining the two ends. In this technique, as well as cutting the piece of cerclage wire within the oral cavity, a medial incision on the ventral aspect must be made and the cerclage removed from this position where it has been twisted<sup>[5]</sup>. This can be performed under deep sedation or anaesthesia and not light sedation. This procedure achieved by light sedation in IAIS technique.

The IAIS technique can also be modified in cats with a single mandibular canine tooth fracture, by drilling a transversal hole in the mandibular segment between the canine tooth and first premolar tooth on the affected side, passing the intra-oral end of the cerclage wire through this hole and securing it on the ventral aspect of the incisive teeth. However, this will only provide interfragmentary stabilisation. All the same, removal of the cerclage wire following healing will be easier compared to circular cerclage wiring on the ventral medial line.

Statistical data obtained at the end of the study demonstrated that clinical healing occurred faster in young cats compared to old cats. This expected outcome was not included in the discussion since it could not be related to either the technique used by the authors or the bone in question.

In conclusion, the IAIS technique is a quick and easy-to-apply technique, provides sufficient stabilisation for bone healing and the cerclage wire can be removed under light sedation. This technique also succeeded in achieving dental occlusion in patients, and the cats were able to consume food shortly after the operation. As a result, it was concluded that the IAIS technique is a successful method in the treatment of mandibular symphysis separations in cats with intact mandibular canine teeth and that it is a first choice option particularly in open, infected and dislocated mandibular symphysis separations.

## REFERENCES

- 1. Verstraete FJM:** Maxillofacial fractures. In, Slatter D (Ed): Textbook of Small Animal Surgery. 3<sup>rd</sup> ed., 2190-2207, WB Saunders, Philadelphia, 2003.
- 2. Schacter RI, Furstman L, Bernick S:** Postnatal development of the mandible of the cat. *Am J Orthod*, 56, 354-364, 1969. DOI: 10.1016/S0002-9416(69)80003-5
- 3. Scott JE, Hogue AS, Ravosa MJ:** The adaptive significance of mandibular symphyseal fusion in mammals. *J Evol Biol*, 25, 661-673, 2012. DOI: 10.1111/j.1420-9101.2012.02457.x
- 4. Yalçın K, Kaya MA, Arslan A:** Comparative geometrical morphometries on the mandibles of Anatolian wild sheep (*Ovis gmelini anatolica*) and Akkaraman sheep (*Ovis aries*). *Kafkas Univ Vet Fak Derg*, 16, 55-61, 2010. DOI: 10.9775/kvfd.2009.385
- 5. Harasen G:** Maxillary and mandibular fractures. *Can Vet J*, 49 (8): 819-820, 2008.
- 6. Scott HW, McLaughlin R:** Fractures and disorders of the skull and mandible. In, Scott HW, McLaughlin R (Eds): Feline Orthopedics. 261-271, Manson Publishing, London, 2006.
- 7. Johnson AL, Hulse DA:** Management of specific fractures. In, Fossum TW (Ed): Small Animal Surgery. 2<sup>nd</sup> ed., 901-913, Mosby, Missouri, 2002.
- 8. Piermattei DL, Flo GL, DeCamp CE:** Fractures and luxations of the mandible and maxilla. In, Piermattei DL, Flo GL, DeCamp CE (Eds): Handbook of Small Animal Orthopedics and Fracture Repair. 4<sup>th</sup> ed., 717-736, Saunders Elsevier, St. Louis Missouri, 2006.
- 9. Owen MR, Langley Hobbs SJ, Moores AP, Bennett D, Carmichael S:** Mandibular fracture repair in dogs and cats using epoxy resin and acrylic external skeletal fixation. *Vet Comp Orthop Traumatol*, 4, 189-197, 2004.
- 10. Dingman RO, Natvig P:** Occlusion and intermaxillary fixation. In, Dingman RO, Natvig P (Eds): Surgery of Facial Fractures. 2<sup>nd</sup> ed., 143, WB Saunders, Philadelphia, 1964.
- 11. Farwell DG:** Management of symphyseal and parasymphel mandibular fractures. Operative techniques in otolaryngology, 19, 108-112, 2008. DOI: 10.1016/j.otot.2008.06.001
- 12. Boole JS, Holtel M, Amoroso P, Yore M:** 5196 mandible fractures among 4381 active duty army soldiers, 1980 to 1998. *Laryngoscope*, 111, 1691-1696, 2001. DOI: 10.1097/00005537-200110000-00004
- 13. Lopes FM, Gioso MA, Ferro DG, Leon-Roman MA, Venturini MAFA, Correa HL:** Oral fractures in dogs of Brasil - A retrospective study. *J Vet Dent*, 22 (2): 86-90, 2015.
- 14. Wiggs RB, Lobprise HB:** Oral fracture repair. In, Wiggs RB, Lobprise HB (Eds): Veterinary Dentistry: Principles and Practice. 259-279, Lippincott-Raven Publishers, Philadelphia, 1997.
- 15. Saglam M, Cetinkaya MA:** Clinical studies of orthopaedic treatments of maxillar and mandibular traumatic lesions in cats. *Vet Cerrahi Derg*, 9 (1-2): 5-10, 2003.
- 16. Legendre LF:** Management of facial fractures in cats. *Can Vet J*, 40 (11): 821-825, 1999.
- 17. Taylor RA:** Surgical repair of mandibular fractures. In, Bojrab MJ (Ed): Current Techniques in Small Animal Surgery, 4<sup>th</sup> ed., 977-984, Lippincott Williams & Wilkins, Maryland, 1997.
- 18. Umphlet RC, Johnson AL:** Mandibular fractures in the cat: A retrospective study. *Vet Surg*, 17, 333-337, 1988. DOI: 10.1111/j.1532-950X.1988.tb01028.x
- 19. Woodbridge N, Owen M:** Feline mandibular fractures a significant surgical challenge. *J Feline Med Surg*, 15, 211-218, 2013. DOI: 10.1177/1098612X13477541
- 20. Ozer K:** Ağız boşluğunun savunma mekanizmaları. In, Ozer K (Ed): Küçük Hayvan Diş Hekimliği. 13, Teknik Yayınevi, İstanbul, 1999.