

Morphological and Etiological Investigations in A Rotaviral Enteritis Outbreak in Calves

İsmet KALKANOV ¹  Ivan DINEV ¹ Marin ALEKSANDROV ²
Kiril DIMITROV ¹ Ivan ZARKOV ³

¹ Department of General and Clinical Pathology, Faculty of Veterinary Medicine, Trakia University, Stara Zagora, BULGARIA

² Institute of Experimental Pathology and Parasitology, Bulgarian Academy of Sciences, Sofia, BULGARIA

³ Department of Veterinary Microbiology, Infectious and Parasitic Diseases, Faculty of Veterinary Medicine, Trakia University, Stara Zagora, BULGARIA

KVFD-2015-14365 Received: 11.09.2015 Accepted: 18.12.2015 Published Online: 07.01.2016

Abstract

The aim of the present report was to describe the gross pathology and histopathologic findings and etiological investigations in a diarrhoeic syndrome outbreak in calves from the 24th h to 20th day of life. Clinically, affected animals exhibited profuse diarrhoea with yellow-greenish faeces mixed with mucus and blood. Rapid field tests Rainbow calf scour 5 BIO K 306 Detection of *Rotavirus*, *Coronavirus*, *E. coli* F5, *Cryptosporidium parvum* and *Clostridium perfringens* in bovine stool and ELISA was used for detection of *Rotavirus*, *Coronavirus*, *E. coli* F5, *Cryptosporidium parvum* antigens. The results of tests were positive for Group A bovine rotavirus, and negative for all other tested etiological agents. The gastrointestinal tract macroscopic lesions observed during the gross pathological examination were of inflammatory nature. Microscopic lesions confirmed the catarrhal desquamative enterocolitis through marked lymphocytic infiltration and oedema of interstitial tissues and submucosa. Non-complicated rotaviral enteritis was capable of inducing pathological alterations of the gastrointestinal tract in neonatal calves with high mortality rates.

Keywords: *Rotavirus enteritis*, *Diarrhoea*, *Group A bovine rotavirus*, *Calves*

Buzağılarda Gözlenen Bir Rotavirus Enteritis Salgınında Morfolojik ve Etiyolojik Araştırmalar

Özet

Bu çalışmanın amacı buzağılarda 24. saat ile 20. gün arasında şekillenen diare sendromu salgınında makroskobik ve histopatolojik bulguların tanımlanarak etiolojinin araştırılmasıdır. Klinik olarak hasta hayvanlarda mukus ve kan ile karışık sarı yeşilimsi renkli dışkı ile karakterize şiddetli ishal gözlemlendi. Hızlı saha testi, Rainbow calf scour 5 BIO K 306, dışkıda *Rotavirus*, *Coronavirus*, *E. coli* F5, *Cryptosporidium parvum* ve *Clostridium perfringens* antijenlerini belirlemek amacıyla kullanıldı. Testin sonuçları Grup A bovine rotavirus için pozitif ve diğer tüm etkenler için negatif olarak belirlendi. Gastrointestinal sistem organlarda gözlemlenen patolojik değişiklikler yangısal karakterdedi. Mikroskobik bakıda intersitisyel dokuda ve submukozada şiddetli lenfositik infiltrasyon ve ödem ile karakterize kataral deskuamatöz enterokolitis tespit edildi. Komplike olmayan rotavirus enteritis gastrointestinal sistemde patolojik değişiklikler yapabilme ve yüksek mortalite özelliklerine sahip olabilmektedir.

Anahtar sözcükler: *Rotavirus enteritisi*, *Diare*, *Grup A bovine rotavirus*, *Buzağı*

INTRODUCTION

Rotaviruses provoke a number of gastrointestinal illnesses in infants, calves, pigs, foals, lamb, rabbits, antelopes, mice and exotic species (grizzly bears, red kangaroos etc.) [1,2]. Group A (*gpA*) bovine rotaviruses (*GPA BRV*) are a genus within the family of Reoviridae. On the basis of antigen specificity rotaviruses are classified into groups, subgroups and serotypes [3,4]. Group A viruses

induce disease in men and ruminants. Group B affects calves, lambs and men. Group C affects mainly pigs and in some instances, men. Groups D, F and G provoke disease in domestic fowl [3,5]. Nevertheless, Group A rotaviruses are the main causative agents of infection in livestock [4,6,7]. Group A bovine rotaviruses are enteropathogenic and are most commonly associated with the etiology of neonatal calf diarrhoea from the birth to the 30th day of the age [8-10]. Usually, the virus affects calves around the 3rd week of age,



İletişim (Correspondence)



+359 888 452098



ismet_88@abv.bg

with highest frequency until 6 days of age. After entering the host, the incubation period of the virus is relatively short (about 24 h) and the duration of diarrhoea - 2-5 days [5,11]. In neonatal calves, the infection is characterized with the lack of viraemic stage, short incubation period, and profuse diarrhoea combined with severe dehydration. The simultaneous infection with secondary pathogens complicates the course of the disease [12,13]. The onset of diarrhoea is due to the replication of the virus within the enterocytes and perished absorbing enterocytes with activation of enteric nervous system by the rotavirus enterotoxin [14].

The purpose of the present report was to describe the results from gross pathology and etiologiical investigations in a diarrhoeic syndrome outbreak in calves from the 24th h to 20th day of life.

CASE HISTORY

In the cattle farm, 13 of 40 diseased calves, 5 to 20 days of age, have died during 3-week period. The disease occurred spontaneously, and the most prominent clinical sign of disease was the diarrhoeic syndrome. Profuse diarrhoea with yellow-greenish faeces, mixed with mucus and blood in 4 of calves, was observed. The course of the disease developed within 24 to 96 h, with dehydration and fatal outcome.

A total of 32 animals were included in the study. Rectal faecal content samples were collected from 10 calves with clinical signs from 7 to 20 days of age which were analysed with rapid field test Rainbow calf scour 5 BIO K 306 Detection of Rota, Corona, *E. coli* F5, Crypto and *Clostridium perfringens* (BIOX Diagnostics, Belgium). The tests detect 5 of causative agents of neonatal calf diarrhoea *Rotavirus*, *Coronavirus*, *E. coli*-F5, *Cryptosporidium parvum* and *Clostridium perfringens* type A. Also, 2 g faecal samples were obtained from the rectums of 22 calves from 5 to 20 days of age for detection of antigens of Rota, Corona, *E. coli* F5, Crypto with ELISA (BIOX Diagnostics, Belgium) sandwich test for faeces.

The serological trapping on antibody-coated electron microscope grids approach of Nicolaieff et al. [15] was used for immunoelectron microscopic detection of viruses in faeces from diarrhoeic calves. Briefly, 20-40 days after the appearance of clinical signs convalescent sera were taken from 5 calves recovered from diarrhoeic syndrome. The faecal test materials for electron microscopic analyses were obtained from 5 acutely diarrhoeic calves from 6 to 12 days of age. Butvar and carbon coated 400 mesh copper grids were floated over drops of protein A solution (usually 26 µg/ml) for 20 min. Then they were washed 4 times on drops of 0.1 M sodium phosphate buffer (pH 7.0). Thereafter, the grids were floated on drops of diluted convalescent sera 1:40 in phosphate buffer for 2 h. After an intermediate

rinse on drops of phosphate buffer, the SpA-convalescent sera-antibody-coated grids were left overnight on drops of supernatant of faecal probes diluted with an equal volume of 0.2 M phosphate buffer and centrifuged at 5.000× g for 30 min. Finally, the negative staining of all preparations was carried out with a 2% sodium phosphotungstate, pH 6.8. The examinations were carried out on an electron microscope JEOL 1200 EX at an accelerating voltage of 80 kV and an instrumental magnification of 6.000-70.000X.

Necropsy of 6 dead calves was done following the standard protocol. Specimens from affected gastrointestinal compartments were collected for histopathological examination. Materials were fixed in 10% neutral buffered formalin and embedded in paraffin. The cross sections were stained with haematoxylin-eosin. From the same carcasses, samples from viscera (liver, heart, spleen, mesenteric lymph nodes) were obtained for conventional bacteriology.

The results from rapid antigenic tests proved the presence of coproantigens against *Group A bovine rotavirus* in all 10 calves. These results were also confirmed with ELISA test (Fig. 1) with positive results in 12 samples out of 22 examined faecal samples. The antigen tests showed that all studied 22 faecal samples were positive for *Group A bovine rotavirus* (Table 1). There were no antigens of the other etiologiical agents of neonatal calf diarrhoea. The immunoelectron microscopy exhibited accumulation of rotaviral particles, distributed evenly along the grid under the form of various number of virion aggregates (Fig. 2).

Gross pathology findings were similar in all necropsied animals. The external appearance of the carcass showed signs of severe dehydration and enophthalmos without other obvious changes. The perianal region was stained with yellow-greenish faeces. After dissection of the


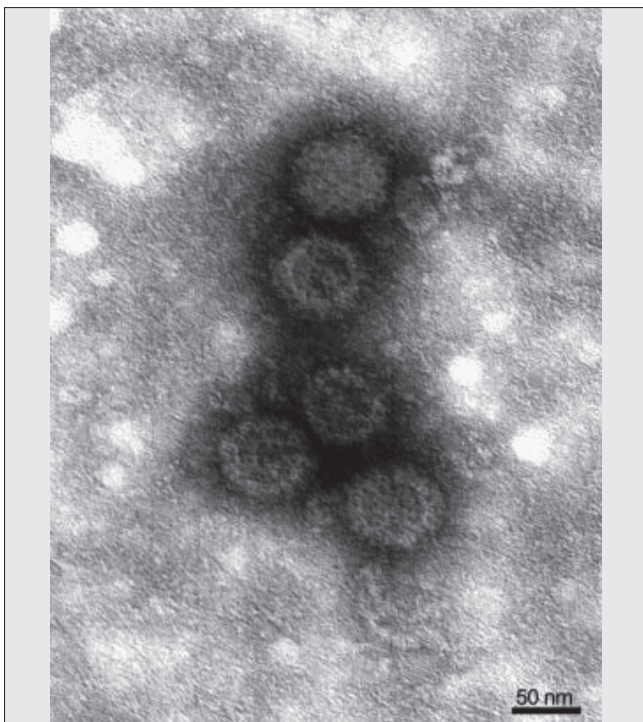


Fig 1. Positive results of sandwich ELISA test for faeces. Blue-coloured wells demonstrate the presence of antigens against rotavirus in calf faecal samples

Şekil 1. Dışkı örneklerinde sandviç ELISA pozitif sonuçları. Mavi renkli hücreler buzağı dışkı örneklerinde rotavirusa karşı antijenlerin varlığını göstermektedir

Table 1. Summary of data from etiologial antigenic tests**Tablo 1.** Etiyolojik antijenik test sonuçları

Test	Total Number of Faecal Samples from Calves n=32	Number of Samples Positive for BRV	Number of Samples Positive for BCoV	Number of Samples Positive for <i>E. coli</i> F5	Number of Samples Positive for a <i>C. parvum</i>
Rainbow calf scour 5 BIO K 306	10	10	0	0	0
ELISA sandwich test	22	12	0	0	0
Total number of positive samples		22	0	0	0

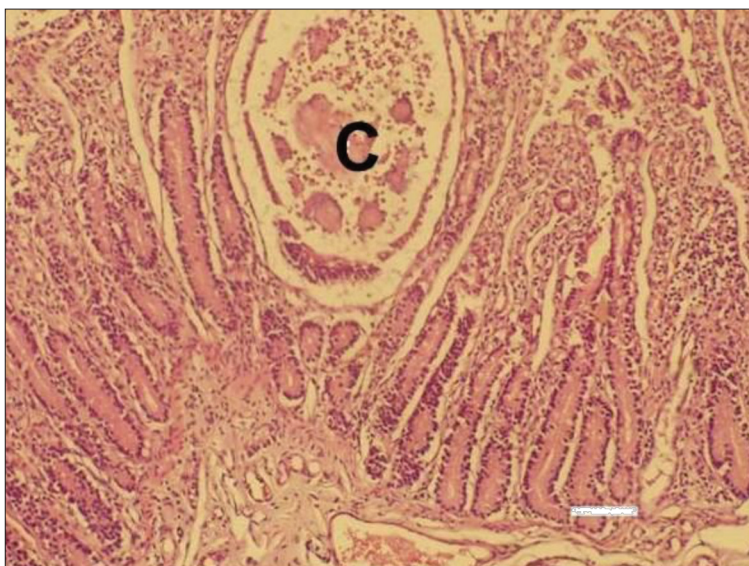
**Fig 2.** Immunoelectron microscopy of a faecal sample from diarrhoeic calf as per Nikolaieff et al.^[15]. Rotavirus particles aggregate. Negative contrasting with 2% sodium phosphotungstate pH 6.8

Şekil 2. Nikolaieff et al.^[15] tarafından tanımlanan bir ishallerli buzağı dışkı örneğinin rotavirus partikülleri. 2% sodyum fosforat pH 6.8 ile negatif kontrast

abdomen, the abdominal cavity contained excessive amount of opaque fluid. Multiple haemorrhages on the mucosa of fore stomachs were detected. The most severe changes were observed in the small intestine, corresponding to acute catarrhal haemorrhagic enteritis. The affected compartments were dilated, with moist intestinal content and meteorism. The colour of intestinal content was yellow-greenish, mixed with numerous gas bubbles. Mesenteric lymph nodes were markedly enlarged and swollen. The abomasum was filled with milk coagula, and its mucosa - hyperaemic and spattered with multiple erosions and few ulcerations.

The liver had an enlarged gallbladder and a frail consistency. In the medullary region of both kidneys, a strong hyperaemia was seen. Petechial and ecchymotic haemorrhages of the epicardium were present. There were no relevant pathoanatomical changes on the other visceral organs.

The histological study of small and large intestine revealed strong dystrophic and necrobiotic changes in enterocytes. A large amount of desquamated cells have shed into the lumen. Some of intestinal villi were strongly atrophied, and crypts – severely dilated in some areas (Fig. 3). The propria was infiltrated with numerous lymphocytes, and submucosa had a marked oedema and hyperaemia (Fig. 4). The studied bacteriological samples were negative for bacterial agents.

**Fig 3.** Transverse cross section of the jejunum. Presence of specific pseudocystic formations within the mucosa, including inflammatory cell exudate (C), H/E. Bar=50 µm

Şekil 3. Jejunumun transversal kesiti. Mukozada spesifik psödokistik oluşumlar (C) ve yangısal hücre infiltrasyonu, H/E. Bar=50 µm

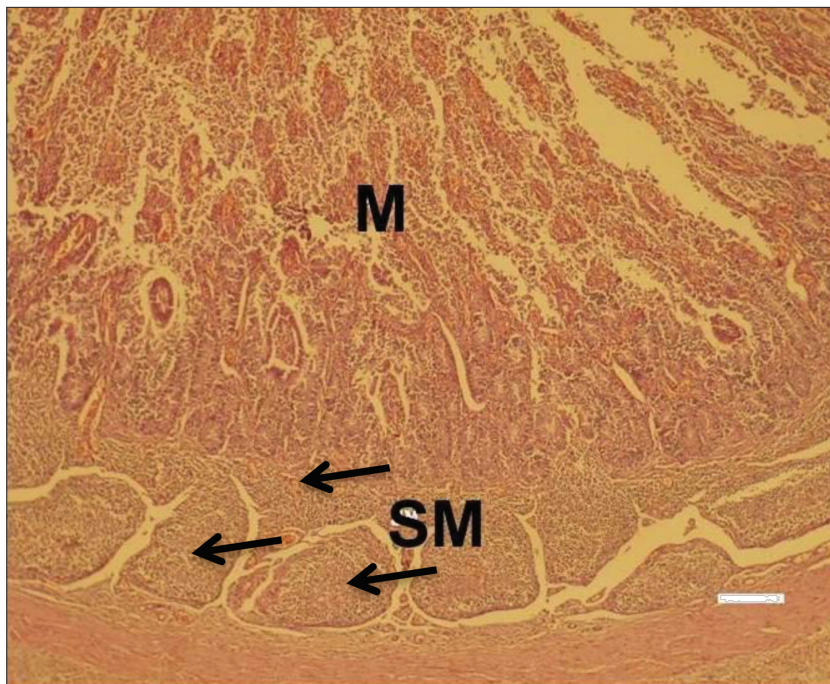


Fig 4. Transverse cross section of the ileum. Intense serous haemorrhagic and desquamative catarrh within the mucosa (M) and a diffuse inflammatory cell infiltration of the submucosa (SM), (Black arrows), H/E. Bar=100 μ m

Şekil 4. İleumun transversal kesiti. Mukozada şiddetli seröz, hemorajik ve deskuamatöz kataral yangı ve submukozada diffuz yangısal hücre infiltrasyonu (SM), (siyah oklar), H/E. Bar=100 μ m

DISCUSSION

The results from the present etiological studies proved the presence of a rotaviral monoinfection with high morbidity and mortality rate during the first 20 days of calves' life. Our results are comparable to other reports [13]. Even as a non-complicated infection, rotaviral enteritis could entail high morbidity and mortality among neonatal calves.

The method of immune electron microscopy demonstrated the presence of rotavirus particles in faecal samples from calves with diarrhoea, which confirms the results of our previous studies. In 1969, the method was used to detect the viruses causing diarrhoea in calves, and named "the gold standard" in the diagnosis of viral enteritis in calves [16].

In contrast of the direct immune electron microscopy, electron microscopy has greater sensitivity, consisting in using a specific antibody for searching virus. Both methods, ELISA and immune electron microscopy have a high sensitivity ranging from 87% to 100% of the different viral agents, which gives them good diagnostic value [17].

The observed microscopic lesions in the distal compartment of small intestines characteristic for severe surface desquamation of epithelial cells and atrophy of some villi, as well as the proliferation of the propria with lymphocytes, are at the background of the pathogenesis of rotaviral enteritis in calves, as also stated by other researchers [12].

Pathomorphological changes in the intestine and colon in coronavirus infection were expressed in atrophy

and fusion of individual villi, with involvement of the crypts epithelium [18]. In the distal section of the small intestine (ileum) were focused histological changes in *E. coli* infection. In addition to atrophy and collection of individual villi were observed and also a large number of bacteria on their surface [19].

Compared to microscopic lesions (epithelial cell desquamation in distal small intestine and proximal colon) observed by us in an *Cryptosporidium parvum* outbreak [14], the present report from the confirmed rotaviral infection provided also evidence for damage of crypts in the distal ileum.

The performed examinations allowed concluding that the antigen diagnostic tests as Rainbow calf scour 5 BIO K 306 and ELISA (BIOX Diagnostics, Belgium) combined with gross anatomy and histopathological findings are appropriate for diagnostics and differential diagnostics of gastrointestinal diseases in neonatal and juvenile calves.

REFERENCES

1. McGuire SJ, Castro AE: Evaluation of a commercial immunoassay for rapid diagnosis of rotavirus in fecal specimens from domestic species. *Proc Annu Meet Am Assoc Vet Lab Diagn*, 25, 375-388, 1982.
2. Woode GN, Bridger JC, Jones JM: Morphological and antigenic relationships between viruses (rotaviruses) from acute gastroenteritis of children, calves, piglets, mice, and foals. *Infect Immun*, 14, 804-810, 1976.
3. Desselberger U, Gray J, Estes M: Rotaviruses. In, Mahy BWJ, Meulen VT (Eds): Topley and Wilson's Microbiology and Microbial Infections. 946-958, ASM Press, USA, 2005.
4. Villarreal LY, Uliana G, Valenzuela C, Chacon J, Saldenberg A, Sanches A, Brandao P, Jerez J, Ferreira A: Rotavirus detection and isolation from chickens with or without symptoms. *Revue Brasileira Ciencia Avicola*, 8, 187-191, 2006. DOI: 10.1590/S1516-635X2006000300009
5. Steele AD, Geyer A, Gerdes G: Rotavirus infections. In, Coetzer JAW,

Tustin RC (Eds): Infectious Diseases of Livestock. 1256-1264, Oxford University Press, Southern Africa, 2004.

- 6. Snodgrass DR, Herring J, Campbell I, Inglis M, Hargreaves F:** Comparison of atypical rotavirus from calves, piglets, lambs and man. *J General Virology*, 65, 909-914, 1984. DOI: 10.1099/0022-1317-65-5-909
- 7. Ghosh S, Varghese V, Sinha M, Kobayashi N, Naik T:** Evidence for interstate transmission and increase in prevalence of bovine group B rotavirus strains with a novel VP7 genotype among diarrhoeic calves in Eastern and Northern states of India. *Epidemiol Infect*, 135, 1324-1330, 2007. DOI: 10.1017/S0950268806007813
- 8. Lucchelli A, Lance S, Bartlett P, Miller G, Saif L:** Prevalence of bovine group A rotavirus shedding among dairy calves in Ohio. *Am J Vet Res*, 53, 169-174, 1992.
- 9. Ishizaki H, Ohta C, Shirahata T, Goto H, Taniguchi K, Urasawa T, Urasawa S:** Persistence of a single electropherotype and serotype (G6P5) of bovine rotavirus in calves on a closed dairy farm from 1990 to 1993. *Am J Vet Res*, 56, 1019-1024, 1995.
- 10. Vende P, Karoum R, Manet G, Rizet C, Schelcher F, Cohen J, Navet H:** Molecular epidemiology of bovine rotaviruses from the Charolais area. *Vet Res*, 30, 451-456, 1999.
- 11. Hall GA, Bridger J, Parson K, Cook R:** Variation in rotavirus virulence: A comparison of pathogenesis in calves between two rotavirus of different virulence. *Vet Pathol*, 30, 223-233, 1993. DOI: 10.1177/030098589303000302
- 12. Torres-Medina A, Schlafer D, Mebus C:** Rotaviral and coronaviral diarrhoea. *Vet Clin North Am: Food Anim Pract*, 1 (3): 471-493, 1985.
- 13. Mebus CA, Staire L, Underdahl R, Twienaums J:** Pathology of neonatal calf diarrhoea induced by a reo-like virus. *Vet Pathol*, 8, 490-505, 1971. DOI: 10.1177/0300985871008005-00612
- 14. Kalkanov I, Dinev I, Dimitrov K, Iliev P:** Clinical and morphological investigations in a spontaneous cryptosporidium enteritis outbreak in calves. *Bulgarian J Vet Med*, 2015. DOI: 10.15547/bjvm.924
- 15. Nikolaieff A, Obert G, Regenmorte M:** Detection of rotavirus by serological trapping on antibody-coated electron microscope grids. *J Clin Microbiol*, 12 (1): 101-104, 1980.
- 16. Brugere-Picoux J, Tessier P:** Viral gastroenteritis in domestic animals and zoonoses. *Bull Acad Natl Med*, 194, 1439-1449, 2010.
- 17. Schroeder ME, Bounpheng MA, Rodgers S, Baker RJ, Black W, Naikare H, Velayudhan B, Sneed L, Szonyi B, Clavijo A:** Development and performance evaluation of calf diarrhoea pathogen nucleic acid purification and detection workflow. *J Vet Diagn Invest*, 24, 945-953, 2012. DOI: 10.1177/1040638712456976
- 18. Kapil S, Pomeroy KA:** Experimental infection with a virulent pneumo-enteric isolate of bovine corona virus. *J Vet Diagn Invest*, 3, 88-89, 1991.
- 19. Francis DH, Allen SD, White RD:** Influence of bovine intestinal fluid on the expression of K99 pili by *Escherichia coli*. *Am J Vet Res*, 50, 822-826, 1989.