

First Reports of *Sarconema eurycerca* and *Trinoton anserinum* in The Whooper Swan (*Cygnus cygnus*) in Van, Turkey

Bekir OĞUZ¹  Özlem ORUNÇ KILINÇ² M. Serdar DEĞER¹

¹ Department of Parasitology, Faculty of Veterinary Medicine, YuzuncuYil University, TR-65100 Campus, Van - TURKEY

² Ozalp Vocational High School, YuzuncuYil University, TR-65090 Van - TURKEY

Article Code: KVFD-2015-13682 Received: 21.05.2015 Accepted: 11.07.2015 Published Online: 11.07.2015

Abstract

Whooper swan *Cygnus cygnus* (Linnaeus, 1758) with wounded wing that found in the Ercis district of Van province was brought into Directorship of Wild Animal Protection of University of Yuzuncu Yil. Despite the surgical interventions, the whooper swan could not be rescued. Five lice in the feather and three nematodes in the heart were found at examination of the whooper swan. These lice specimens were identified as *Trinoton anserinum* (Fabricius, 1805). After the necropsy, nematodes were found in the heart of the whooper swan. Nematodes were identified as *Sarconema eurycerca* according to their morphological peculiarities. *Sarconema eurycerca* have been reported for the first time in Whooper swan in Van, Turkey.

Keywords: *Trinoton anserinum*, *Sarconema eurycerca*, *Cygnus cygnus*, Whooper swan, Turkey

Ötücü Kuğuda (*Cygnus cygnus*) *Sarconema eurycerca* (Filarioidea: Nematoda) ve *Trinoton anserinum* (Phthireptera: Amblycera)'un Van'da (Türkiye) İlk Bildirimi

Özet

Van'ın Erciş ilçesinden Yüzüncü Yıl Üniversitesi Yaban Hayvanlarını Koruma Müdürlüğüne kanadından yaralı getirilen Ötücü kuğu (*Cygnus cygnus* Linnaeus, 1758) cerrahi müdahalelere rağmen kurtarılamayarak ölmüştür. Kuğunun tüyleri arasında 5 adet bite, kalbinde ise 3 adet nematoda rastlanmıştır. Bitlerin *Trinoton anserinum* (Fabricius, 1805) türü oldukları tespit edilmiştir. Nekropsi sonrası kuğunun kalbinde nematodlar bulunmuş, nematodların morfolojik özellikleri göre *Sarconema eurycerca* olduğu tespit edilmiştir. Ötücü kuğuda tespit edilen *Sarconema eurycerca* Türkiye'de ilk kez bildirilmiştir.

Anahtar sözcükler: *Trinoton anserinum*, *Sarconema eurycerca*, *Cygnus cygnus*, Ötücü kuğu, Türkiye

INTRODUCTION

Sarconema eurycerca known as heartworm in swans and geese is a filarial nematode of the superfamily Filarioidea [1,2]. In the previous studies whistling, trumpeter, tundra, black, whooper and mute swan were found to infested with *S. eurycerca*. Moreover *S. eurycerca* was found in snow, white-fronted and bean geese. *Sarconema eurycerca* has been implicated as a cause of death among wild birds [2,3]. It was first described by Wehr [4] from a Whistling Swan, *Cygnus columbianus columbianus*, where it was found to be parasitic in the heart muscle [5]. *Sarconema eurycerca* has an indirect life cycle. Female adult heartworms release

microfilariae into the bloodstream of the definitive host bird [5].

Trinoton anserinum serves as natural cyclo-developmental vector for a *S. eurycerca* [6] within the sub-order Amblycera. This family of lice was classified by Clay [7] and the genus *Trinoton* is distinguished by the presence of two large sternal plates bearing many setae [8]. Among the largest lice are those of the genus *Trinoton*, which can reach 5-6 mm in length. These lice feeds with feathers, also they can feed on blood [9]. One is *Trinoton querquedulae* which is found on Anas and is related with genera and the other is *T. anserinum* on Anser and is related with genera.



İletişim (Correspondence)



+90 541 4007166



bekiroguz@yyu.edu.tr

In Turkey, there are limited studies [10-12] about *Trinoton* species but *T. anserinum* had been reported on a mute swan before (*Cygnus olor*) [3]. This is the first record for *T. anserinum* and *S. eurycerca* in whooper swan in Turkey.

CASE HISTORY

In February 2014, wounded whooper swan was found in Ercis area of Van Lake and was brought into Directorship of Wild Animal Protection of University of Yüzüncü Yıl. Five lice were found after examination of the swan and the specimens were transferred into tube containing 70% ethyl alcohol. Then it was cleared in 10% KOH, the specimens were washed in distilled water for 24 h, and was passed through a graded series of 70%, 80%, 90% and 96% alcohol, and was mounted in Canada balsam on the slides. The slides were examined by light microscopy for the identification of species and measurements were taken [12]. Whooper swan was necropsied after death. Three nematodes were found in the myocardium of the heart and stored in 70% alcohol until identification. The nematodes were examined with a light microscope to take morphological measurements and to determine sex. *Trinoton anserinum* and *Sarconema eurycerca* were identified according to literatures [13-15].

Identification of Parasites

Trinoton anserinum (Fabricius, 1805): The body of *T. anserinum* is dorso-ventrally flattened (Fig 1A, 1B). Head triangular in shape than long, greatest width at temporal region rounded and broader, the laterodorsal margin of head with small protuberance bearing setae. Chaetotaxy consisting of long and short setae of normal appearance and stout, spine-like setae. Clay and Hopkins [13] indicated that there are two species in the group of quaerquedulae as *Trinoton anserinum* and *Trinoton quaerquedulae*, these species are on the 3rd femora's ventral part (Fig. 1C) and there are spine-like stae groups in 4-5 sternites. Measurements of this species are shown in Table 1.

Sarconema eurycerca (Wehr, 1939): The parasite both of elliptical ends are extremely visible and string (Fig. 2A). The uteri occupies most of the body cavity, eggs are visible in them through the cuticle and different stages of development of microfilariae were visible in the eggs (Fig. 2C). The vulva is nearly to the anus and uteri extends almost to the anus. Eggs are thin shelled and microfilariae of *S. eurycerca* consists of a long, narrow nucleated body surrounded by a sheath. The posterior edges of microfilariae are narrower (Fig. 2B). Measurements of this species and eggs and microfilariae of this species are shown in Table 2.




Fig 1. A- *Trinoton anserinum* (female), B- *Trinoton anserinum* (male), C- *Trinoton anserinum* brushes setae ventrale side of 3rd femur

Şekil 1. A- *Trinoton anserinum* (Dişi), B- *Trinoton anserinum* (erkek), C- *Trinoton anserinum* 3. femurun ventral tarafında fırça kıllar

Fig 2. A- Heartworms on the myocardium of the heart of whooper swan, B- Anterior section of adult female nematode (*S. eurycerca*) under a light microscope, C- Fully developed microfilariae (red arrow) hatched from eggs (black arrow), still within uteri

Şekil 2. A- Ötücü kuğunun kalbinde (miyokardium) *Sarconema eurycerca* (kalp kurdu), B- Erişkin dişi nematodun (*S. eurycerca*) ön ucu, C- *Sarconema eurycerca*'nın uterusunda yumurta (siyah ok) ve gelişmiş mikrofilyara (kırmızı ok)

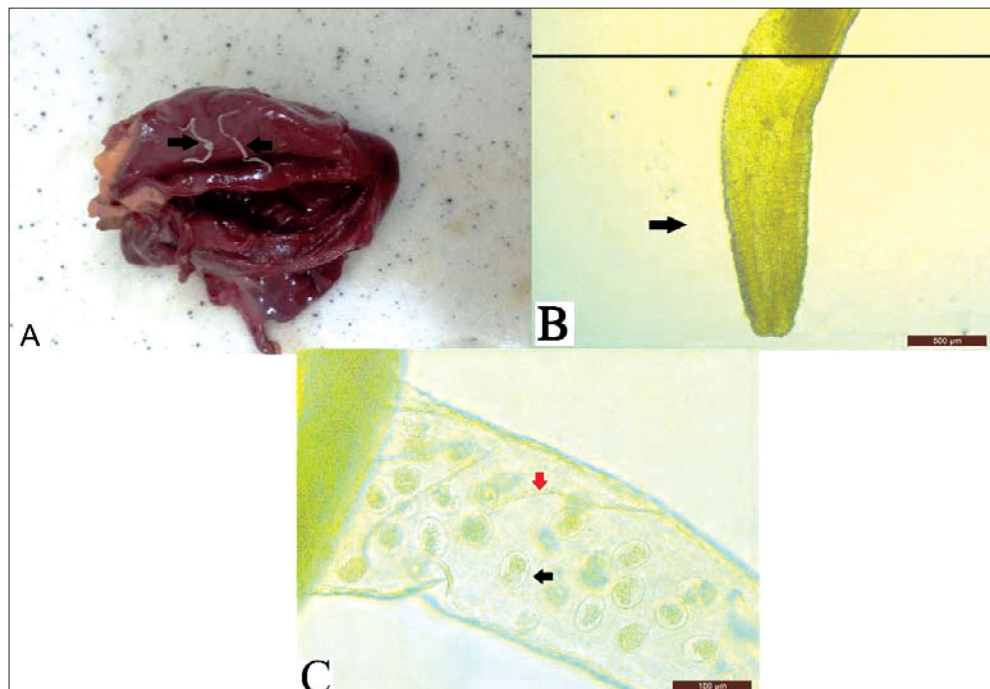


Table 1. Body size of *Trinoton anserinum* (mm) on various hosts according to different authors**Tablo 1.** Farklı araştırmacılara göre çeşitli konaklar üzerinde *Trinoton anserinum*'un (mm) vücut uzunlukları

Male n=2	References		Present Data n=2	Female n=3	References		Present Data n=3
	Cohen [15]	Castresana et al. [16]			Clay and Hopkins [13]	Castresana et al. [16]	
Length of head	0.91	-	0.80	Length of head	0.93	-	0.90
Width of head	1.54	-	1.38	Width of head	1.59	-	1.53
Width of thorax	-	-	0.60	Width of thorax	-	-	0.64
Length of thorax	-	-	2.9	Length of thorax	-	-	2.4
Length of abdomen	-	-	3.26	Length of abdomen	-	-	3.5
Width of abdomen	-	1.38	1.63	Width of abdomen	-	1.60	2.0
Total length of body	5.67	6.17	5.76	Total length of body	6.05	5.31-6.28	6.38

Table 2. Body size of females of *Sarconema eurycerca* (μ m) on various hosts according to different authors**Tablo 2.** Farklı araştırmacılara göre çeşitli konaklar üzerinde dişi *Sarconema eurycerca*'nın (μ m) vücut uzunlukları

Character	References		Present Data
	Cohen [15]	Seegar [14]	
Length of microfilariae	263-382	270-340	278-290
Width of microfilariae	-	4.5-6.5	6-7
Length of eggs	-	-	54-55
Width of eggs	-	-	33-34

DISCUSSION

Approximately 4.000 valid lice species have been reported on the birds worldwide [17]. In the studies done relevant to the chewing lice found on wild birds, approximately 100 lice species have been detected in the birds in Turkey, until today. This species have been reported from Greylag Goose (*Anser anser*) in Van [18] and Wild Swans in Samsun, Turkey [10]. *T. anserinum* was recorded from Whooper Swan (*Cygnus cygnus*) for the first time in this study, in Turkey. In this study, one lice species, *Trinoton anserinum* was found on the whooper swan (*Cygnus cygnus*).

Heartworm in swans and geese (birds of the order Anseriformes) is caused by *Sarconema eurycerca*, a filarial nematode of the superfamily filarioidea. *S. eurycerca* was recorded from whooper swan (*Cygnus cygnus*) for the first time in this study, in Turkey. This species has been previously reported from Mute Swan (*Cygnus olor*) in England [14], Mute Swan (*Cygnus olor*) in Netherlands [19], Whistling Swan (*Cygnus columbianus*) in Maryland [20] and Whooper Swan (*Cygnus cygnus*) in Korea [2].

Castresana et al. [16] compared species *T. querquedulae* and *T. anserinum* as morphologically and reported that while in the *T. anserinum*'s quetotaxia spines are shorter and mostly silky-like setae, the *T. querquedulae* species are longer and mostly spine-like setae. Additionally, they reported that 3rd femura has fewer and smaller sized brunch setae in *T. anserinum* compared to

T. querquedulae [16]. Therefore, these specimens were identified as *T. anserinum*.

Previous researchers reported that *T. anserinum* which was found in the host is seen in all species of the genus Anser [6,16,21,22]. It has also been cited that *S. eurycerca* whether causes to or being the primary cause of death of whistling swan and mute swan [3,20]. Three avian filarioids (*Pelecitus*, *Splendidofilaria* and *Sarconema*) may infect swan and geese of the Anatidae family. *Splendidofilaria* species induce lesions in various organs and tissues, such as the heart, aorta, pulmonary arteries, abdominal cavity, kidney, trachea, esophagus, eyes and skin. Various species of wild birds may be infected. *S. eurycerca* cause lesions only in the heart and only swans and geese were affected. Seegar [14] reported that the microfilariae of *S. eurycerca* was sheathed and measured 270-340 μ in length and 4.5-6.5 μ in width, and Cohen et al. [23] also reported the measurement 263-382 μ . In this study the microfilariae were measured between 278-290 μ x 6-7 μ .

In conclusion, *T. anserinum* and *S. eurycerca* are reported in whooper swan in Turkey for the first time.

REFERENCES

- Cole RA:** Heartworm of swans and geese. In, Friend M, Franson JC (Eds): Field Manual of Wildlife Diseases: General Field Procedures and Diseases of Birds Biological Resources Division, U.S. Geological Survey, Washington, DC, 233-234, 1999.
- Woo GH, Jean YH, Bak EJ, Kang S, Roh IS, Lee KH, Hwang EK, Lee OS:** Myocarditis by Nematodes infection, presumably *Sarconema eurycerca*, in

- a wild whooper swan (*Cygnus cygnus*) in Korea. *J Vet Med Sci*, 72, 1233-1235, 2010. DOI: 10.1292/JVMS.10-0075
- 3. Irwin JC:** Mortality factors in whistling swans at Lake St. Clair, Ontario. *J Wild Dis*, 11, 8-12, 1975.
- 4. Wehr E:** New genera and species of Filarioidea. III. *Sarconema eurycerca* n. gen. n. sp. *Proc Helminthol Soc Wash*, 6, 95-97, 1999.
- 5. Seegar WS:** Prevalence of the heartworm, *Sarconema eurycerca*, Wehr. 1939 (Nematoda), in whistling swan, *Cygnus columbianus columbianus*. *Can J Zool*, 57, 1500-1502, 1979. DOI: 10.1139/z79-194
- 6. Seegar WS, Schiller EL, Sladen WJ, Trpis M:** A mallophaga, *Trinoton anserinum*, as a cyclodevelopmental vector for a heartworm parasite of waterfowl. *Science*, 194, 739-741, 1976.
- 7. Clay T:** Some problems in the evolution of a group of ectoparasites. *Evolution*, 3, 279-299, 1949. DOI: 10.2307/2405715
- 8. Keirans JE:** The Mallophaga of New England birds. Agricultural Experiment Station University of New Hampshire Durham, New Hampshire. Station Bulletin, 492, 1967.
- 9. Fryderyk S:** *Trinoton querquedulae* (Linnaeus, 1758) (Phthiraptera: Amblycera, Menoponidae) a rare parasite of the Eider duck *Somateria mollissima* (Linnaeus, 1758). *Ann Parasitol*, 59, 21-23, 2013.
- 10. Açıcı M, Umur Ş, Gürsoy A:** Yabani bir kuğuda *Trinoton anserinum* olgusu. XIV. Ulusal Parazitoloji Kongresi, 18-25 Eylül, İzmir, pp.225-226, 2005.
- 11. Aksin N:** Chewing lice (Insecta: Phthiraptera) on Mallards (*Anas platyrhynchos*) in Turkey. *J Anim Vet Adv*, 10, 1656-1659, 2011. DOI: 10.3923/javaa.2011.1656.1659
- 12. Dik B, Uslu U:** Studies on chewing lice species found on some duck (Anseriformes: Anatidae) species at Lake Akşehir, Turkey. *Kafkas Univ Vet Fak Derg*, 18, 1055-1060, 2012. DOI: 10.9775/kvfd.2012.7020
- 13. Clay T, Hopkins GHE:** The early literature on Mallophaga (Part IV, 1787-1818). *Bull Br Mus (Nat Hist) Entomol*, 9, 1-61, 1960.
- 14. Seegar WS:** Prevalence of parasitic heartworms in swans in England. *Wildfowl*, 30, 147-150, 1979.
- 15. Cohen S:** *Sarconema eurycerca* (Wehr): The heartworm of swans and the role of *Trinoton anserinum* (F) as an intermediate host. A Doctoral Thesis. Submitted in partial fulfillment of the requirements for the award of Doctor of Philosophy of Loughborough University. 1988.
- 16. Castresana L, Notario A, Mateo PM:** Study of the ectoparasitic mallophaga of Anatidae (Insecta, Mallophaga) in the Iberian Peninsula. Identification, biometric characteristics and biological aspects. *Zool Baetica*, 10, 63-86, 1999.
- 17. Price RD, Hellenthal RA, Palma RL, Johnson KP, Clayton DH.** The Chewing Lice: World Checklist and Biological Overview. Illinois Natural History Survey Special Publication, 24, 2003.
- 18. Göz Y, Dik B, Kılıç ÖO, Aslan L:** Chewing lice (Phthiraptera: Amblycera, Ischnocera) on several species of wild birds around the Lake Van basin, Van, Eastern Turkey. *Kafkas Univ Vet Fak Derg*, 21, 333-338, 2015. DOI: 10.9775/kvfd.2014.12484
- 19. De Bruijn ND, Velkers FC, Gröne A:** Heartworm in a mute swan (*Cygnus olor*). *Tijdschr Diergeneeskd*, 134, 882-884, 2009.
- 20. Holden BL, Sladen, WJL:** Heartworm, *Sarconema eurycerca*, infection in whistling swans, *Cygnus columbianus*, in the Chesapeake Bay. *Bull Wildl Dis Assoc*, 4, 126-8, 1968. DOI: 10.7589/0090-3558-4.4.126
- 21. Pennycott TW:** Lead poisoning and parasitism in a flock of mute swans (*Cygnus olor*) in Scotland. *Vet Rec Jan*, 142, 13-17, 1998.
- 22. Acuna-Gonzales D, Lara J, Cicchino A:** New records of lice (Insecta: Phthiraptera) from domestic and ornamental birds from Chile. *Arc Med Vet*, 41, 181-184, 2009. DOI: 10.4067/S0301-732X2009000200013
- 23. Cohen S, Green Wood MT, Fowler JA:** The louse *Trinoton anserinum* (Amblycera: Phthiraptera), an intermediate host of *Sarconema eurycerca* (Filarioidea: Nematoda), a heartworm of swans. *Med Vet Entomol*, 5, 101-110, 1991.