

The Protective Effects of Osajin on Ischemia/Reperfusion Injury to Rat Ovaries: Biochemical and Histopathological Evaluation

Gülşen ÇİĞŞAR¹ Osman Nuri KELEŞ² Serpil CAN³ Mehmet KARACA⁴ İsmail CAN⁵
Hüseyin Serkan EROL⁶ Dilek SAĞIR⁷ Özlem Özgül ABUÇ² Ahmet ÇAKIR⁸
Zişan Gönül ŞAHİN⁹ Bünyami ÜNAL² Barış ANIL¹⁰ Mesut Bünyami HALICI⁶

¹ Kafkas University, School of Medicine, Department of Emergency Medicine, TR-36100 Kars - TÜRKİYE; ² Ataturk University, School of Medicine, Department of Histology and Embryology, TR-25240 Erzurum - TÜRKİYE; ³ Kafkas University, School of Medicine, Department of Physiology, TR-36100 Kars - TÜRKİYE; ⁴ Medstar Antalya Hospital, Clinic of Obstetrics and Gynecology, TR-07200 Antalya - TÜRKİYE; ⁵ Kafkas University, School of Medicine, Department of Histology and Embryology, TR-36100 Kars - TÜRKİYE; ⁶ Ataturk University, Faculty of Veterinary Medicine, Department of Biochemistry, TR-25240 Erzurum - TÜRKİYE; ⁷ Sinop University, School of Health Sciences, Department of Nursing, TR- 57000 Sinop - TÜRKİYE; ⁸ Kilis 7 Aralık University, Faculty of Science and Art, Department of Chemistry, TR-79000 Kilis - TÜRKİYE; ⁹ Kafkas University, School of Medicine, Department of Medical Biology, TR-36100 Kars - TÜRKİYE; ¹⁰ Ataturk University, Faculty of Science, Department of Chemistry, TR-25240 Erzurum - TÜRKİYE

Article Code: KVFD-2015-13387 Received: 18.03.2015 Accepted: 22.04.2015 Published Online: 24.04.2015

Abstract

Reactive oxygen species (ROS) and inflammation play important roles in the pathogenesis of ischemia/reperfusion (I/R) ovarian injury. The purpose of this in-vivo study is to evaluate the effect of osajin, a prenylated flavonoid with antioxidant and anti-inflammatory properties, on oxidative balance and ovarian damage induced by unilateral I/R. The study used 48 adult, female Wistar albino rats. In the controls (CN), only laparotomy was performed. In group CN^{Osajin}, 200 mg/kg osajin was administered. In group IR^{VEHICLE}, an ischemic period of 3 h was followed by reperfusion for 3 h; the bilateral ovaries were then removed. In groups IR^{Osajin100} and IR^{Osajin200}, after 3 h of ischemia, 100 and 200 mg/kg of osajin was given orally before reperfusion, respectively; after 3 h of reperfusion, the ovaries were removed. After the experiments, MPO, SOD and CAT enzyme activities and LPO levels was determined for the oxidative state and activities of PMNs. In addition, histopathological changes were examined in all rat ovarian tissues. Statistical analysis was performed using one-way ANOVA (with Duncan). According to biochemical and histopathological results, I/R increased LPO levels and MPO activities and infiltration of PMNs despite high-antioxidant SOD and CAT enzyme activity. Both dosage levels of osajin before I/R significantly decreased LPO level and MPO activity and PMN infiltration compared to those of the IR^{VEHICLE} group, with the higher dosage causing greater decreases. In addition, results showed that treatment with osajin against ameliorated development of irreversible ovarian damage induced by I/R. These results suggest that osajin provides protections against ovarian I/R injury. Its mechanisms could be related to mitigation of oxidative stress and activities and to PMN infiltration.

Keywords: *Osajin, Ischemia/Reperfusion, Oxidative stress, Ovary, Rat*

Sıçan Ovaryumlarında İskemi/Reperfüzyon Hasarı Üzerine Osajin'in Koruyucu Etkileri: Biyokimyasal ve Histopatolojik Değerlendirme

Özet

İnflamasyon ve Reaktif Oksijen Sınıfları (ROS) iskemik reperfüzyon (I/R) over hasarlarında çok önemli rol oynar. Bu in vivo çalışmanın amacı tek taraflı I/R ile oluşturulan over hasarı ve antiinflamatuvar ve antioksidant özellikli bir flavonoid olan osajinin oksidatif denge üzerine etkilerini incelemektir. Çalışmada 48 yetişkin dişi Wistar albino rat kullanıldı. Kontrol (CN) grubuna yalnızca laparotomi uygulandı. CN^{Osajin} grubunda, sadece 200 mg/kg dozda osajin verildi. IR^{VEHICLE} grubunda, 3 saatlik iskemik periyodu 3 saatlik reperfüzyon takip etti; daha sonra bilateral yumurtalıklar alındı. IR^{Osajin100} ve IR^{Osajin200} gruplarında 3 saatlik iskemiden sonra sırasıyla 100 ve 200 mg/kg osajin reperfüzyondan önce oral olarak verildi.; 3 saatlik reperfüzyondan sonra yumurtalıklar alındı. Deneylerden sonra, PMN'lerin aktiviteleri ve oksidatif durumları için MPO, SOD ve CAT enzim aktiviteleri ve LPO düzeyleri belirlendi. Ek olarak histopatolojik değişimler tüm rat ovaryum dokularında incelendi. İstatistiksel analizler one-way ANOVA kullanılarak yapıldı (Duncan ile). Biyokimyasal ve histopatolojik sonuçlara göre, yüksek antioksidan SOD ve CAT enzim aktivitesine rağmen, I/R PMN'lerin infiltrasyonunu, MPO aktivitelerini ve LPO düzeylerini artırdı. İskemik reperfüzyondan önce, osajinin her doz seviyesi büyük bir düşüşe sebep olan yüksek dozla birlikte IR^{VEHICLE} grubunda olanlarla karşılaştırıldığında LPO düzeyi, MPO aktivitesi ve PMN infiltrasyonunu önemli derecede düşürdü. Ek olarak sonuçlar dönüşümsüz ovaryum hasarının iyileştirmeden gelişmesine karşı osajin ile tedavi I/R tarafından uyarılmış olduğunu gösterdi. Bu sonuçlar osajinin ovaryan iskemik reperfüzyon hasarına karşı koruma sağladığını düşündürmektedir. Bunun mekanizmaları oksidatif stresi ve aktivitelerini ve PMN infiltrasyonunu azaltması ile ilgili olabilir.

Anahtar sözcükler: *Osajin, İskemi/Reperfüzyon, Oksidatif stress, Ovaryum, Rat*



İletişim (Correspondence)



+90 442 2311111/595



onkeles@atauni.edu.tr

INTRODUCTION

Ischemia/reperfusion (I/R) injury is one of the main causes of organ damage. It has been reported that certain organs, such as the kidneys, liver, ovaries, heart and brain are damaged by the I/R process [1]. I/R is a pathological situation characterized by restriction of blood flow to an organ followed by re-ensuring of perfusion and resupply of oxygen [2]. Ovarian torsion is the twisting of an ovary and/or tubular and supporting ligaments, an ischemic condition characterized by accompanying reduction or complete stoppage of blood flow [3]. Torsion of the adnexa is seen in women of all ages, however, 70-75% of patients are under the age of 30, and this condition is responsible for 2.7% of all emergency gynecological surgeries [4-6]. Signs and symptoms of ovarian torsion often resemble acute appendicitis and also are seen as abdominal and pelvic pain in young girls. Ovarian torsion often is misdiagnosed [7]. Laparoscopic ovarian-torsion surgery generally is used for ovarian detorsion and to restore blood flow to the ovary. Before surgery, painkillers usually are used for pain control [8]. In neglected or prolonged cases, necrosis develops in ovarian tissue to which blood flow has been cut for a long time. In these cases, surgical removal of the ovaries is required [9].

Ovarian detorsion may lead to increased reactive oxygen species (ROS), depending on the recovery of oxygen in the damaged ischemic tissue cells and oxidative tissue damage caused by reperfusion after ischemia [3,10]. ROS metabolites over the normal physiological levels damage cell structures, beginning with membranes (lipids) extending to proteins and DNA [11-14]. As a result of the appearance of various stimulants via I/R, activation of macrophages in tissue increases production of pro-inflammatory cytokines, such as TNF-alpha and IL-1, and chemokines [15]. These cytokines and chemokines may induce circulating neutrophils to adhere to endothelial cells and migrate to tissues [16]. Depending on neutrophil activation, increased ROS and inflammatory products mediated by respiratory bursts may cause more oxidative damage [17,18]. Previously, it has been reported that oxidative stress and its damage mechanisms may cause infertility and early menopause [19]. In addition, some antioxidant and anti-inflammatory drugs or agents have been determined as beneficial in mitigating detorsion (reperfusion) side effects, depending on their ability to reduce oxidative stress [18].

Flavonoids are a heterogeneous group of phenolic compounds that have a variety of biological effects, such as antioxidant, anti-inflammatory, anticancer, antiviral and anti-allergic [20]. Osajin is a main flavonoid compound as is obtained from ethyl acetate extract of fruits of the *Maclura pomifera* species of the mulberry family, Moraceae [21]. Vesel'á et al. [22] showed that osajin possesses low antioxidant effects compared to peroxy-nitrite-scavenging activity, inhibition of lipid peroxidation and

DPPH-scavenging activity. In addition, Tsao et al. [21] observed the antioxidant activities of osajin in FRAP and β -CLAMS tests. Interestingly, Diopan et al. [23] found that, although the antioxidant capacity of osajin was lower, it strongly decreased oxidative damage of the four bases (guanine, thymine, adenine and cytosine) in DNA exposed to oxygen radicals generated by Fenton's reaction. Recently, I/R in vivo (animal) studies in heart and kidney tissue produced strong evidence of the antioxidant activities of osajin, in spite of its showing less activity in *in-vitro* studies [24,25]. In addition to these effects of osajin, Hošek et al. showed that inhibition of I κ B-alpha degradation mediated anti-inflammatory effects of osajin in macrophage cell cultures [26]. Therefore, the present study used both biochemical and histopathological methods to investigate whether osajin could provide protective antioxidant and anti-inflammatory effects against I/R-induced ovarian damage.

MATERIAL and METHODS

Animals

The animals were housed in compliant facilities, and the experiment was conducted in accordance with international guidelines and were approved by the Institutional Animal Care and Use committee of Ataturk University. This study used 48 adult, female Wistar albino rats (210-230 g) from the Ataturk University Experimental Animal Laboratory (ATADEM-Approval No: 2013-03/96). The 48 rats were divided into eight groups of six rats each, and all rats were in the estrous phase when killed during the experiment.

Chemicals

Osajin used in this study was purified with chromatographic methods by PhD. Ahmet Çakır. Also, the chemical structure of Osajin was confirmed by spectroscopic methods in the UV-VIS, IR, ¹H-NMR, ¹³C-NMR, 1D and 2D NMR. Thiopental sodium (Pentothal sodium) was purchased from Abbott (Istanbul, Turkey). All the other chemicals for laboratory experimentation were purchased from Sigma-Aldrich (Germany).

Surgical Technique

All surgical procedures were performed under sterile conditions using thiopental sodium as an anesthetic. During the acclimatization period, the rats were fed a diet of standard commercial rat pellets. For this procedure, the animals were anesthetized with 25 mg/kg thiopental sodium, injected intraperitoneally. A longitudinal incision of 2.5 cm was made in the midline area of the lower abdomen. A small peritoneal incision was made, and the uterine horns and adnexae were located.

A sham operation (laparotomy only) was performed

on the six rats in the control group (CN; n = 6). In the second group, a sham operation was performed after administration of 200 mg/kg osajin (CN^{Osajin}; n = 6). In the third, fourth and fifth groups, bilateral ovarian ischemia was created by applying vascular clips below the ovaries and a 3-h period of ischemia was followed by 3 h of reperfusion. Then 2 h after induction of ischemia, groups 4 and 5 were administered 100 mg/kg (IR^{Osajin100}; n=6) and 200 mg/kg (IR^{Osajin200}; n = 6) doses of osajin, respectively, by oral gavage. Osajin was dissolved in a small volume of diluted, hot 0.9% NaCl to a final concentration of 1 ml. Group 3 was administered 1 ml/kg of saline solution (IR^{VEHICLE}; n = 6) by gavage. At the end of 3 h of reperfusion, ovaries were removed for histologic and biochemical examination.

Biochemical Analysis

Before the experiments, tissues were homogenated with liquid nitrogen in a mortar. These homogenates were stored at -80°C until the biochemical investigation, in which MPO, SOD and CAT enzyme activity and LPO levels were measured in the homogenates of rat ovary tissues, and 15 mg tissue from each group was weighed and treated with 1.5 ml of an appropriate buffer. This mixture was homogenized on ice in Eppendorf tubes with steel balls using a QIAGEN TissueLyser LT homogeniser for 15 min. Homogenates were filtered and centrifuged using a refrigerated centrifuge at 4°C. Supernatants were used to determine MPO, SOD and CAT enzyme activity and LPO amount. All assays were carried out at room temperature.

- **MPO Activity:** MPO activity was determined according to the modified method of Bradley et al.^[27]. The homogenised tissues mixture (1.500 g) was centrifuged for 10 min at 4°C. MPO activity of ovarian tissues was determined by adding 0.1 mL supernatant to 1.9 mL of 10 mmol/L phosphate buffer (pH 6.0) and 1 mL of 1.5 mmol/L o-dianisidine hydrochloride containing 0.0005% (wt/vol) hydrogen peroxide. Absorbances of MPO activity were measured on a UV-vis spectrophotometer at 460 nm. Ovarian MPO activity was expressed as $\mu\text{mol}/\text{min}/\text{mg}$ tissue.

- **LPO Determination:** LPO amounts were measured by estimating LPO using the thiobarbituric acid test^[28]. This was done by weighing 15 mg tissue homogenized in 1.5 mL of 100 g/L KCl and adding it to a solution containing 0.2 mL of 80 g/L sodium lauryl sulfate, 1.5 mL of 200 g/L acetic acid, 1.5 mL of 8 g/L 2-thiobarbiturate and 0.3 mL of distilled water in test tubes. Homogenized tissue was incubated at 98°C water for 1 h. After cooling, 5 mL of n-Butanol: pyridine (15:1) was added to the tubes, which were then vortexed for 1 min and centrifuged for 30 min at 1875 x g. Sample absorbances were determined at 532 nm. The standard curve was achieved by using 1,1,3,3-tetramethoxypropane, and recovery was greater than 95%. LPO levels were expressed as nanomol LPO per gram of tissue (nmol/g tissue).

- **SOD Activity:** Measurement of SOD activity was based on generation of superoxide radicals, which react with nitro blue tetrazolium to form formazan dye, which is produced by the xanthine and xanthine-oxidase system^[29]. SOD activity of ovarian tissues was determined by the degree of inhibition of this reaction at 560 nm. SOD activity was expressed as millimoles per minute per milligram (mmol/min/mg) of tissue.

- **CAT Activity:** The CAT catalysis decomposition of H₂O₂ was determined at 240 nm^[30]. CAT activity was described as the amount of catalase required to decompose 1 nanomole of H₂O₂ per minute at 25°C and pH 7.8. CAT activity of ovarian tissue was expressed as millimoles per minute per milligram (mmol/min/mg) of tissue.

Histopathological Analyses

Ovarian tissues were fixed in 10% formaldehyde, dehydrated in a graded alcohol series, embedded in paraffin wax and sectioned using a Leica RM2125RT microtome (Leica Microsystems, Wetzlar, Germany). For histopathological examination, 5 μm thick sections of paraffin block were obtained using a systematic randomized sampling method. Sections were stained with H&E. All ovaries were examined by light microscopy for histopathological evaluation of the following parameters: H&E staining for hemorrhage, vascular destruction, inflammatory cell infiltrates, reversible cell degeneration, necrotic cell death and apoptotic cell death.

Data Analyses

Statistical analysis was performed using one-way ANOVA with Duncan post hoc test for multiple comparisons. All data are expressed as mean \pm s.e, and are considered significant at a *p* level of 0.05 or less as mean. Calculations were performed using the IBM® SPSS software package, version 19.00 (SPSS, Chicago, IL, USA).

RESULTS

Biochemical Results

Fig. 1 shows the MPO enzyme activity, a significant marker of neutrophil infiltration, of the inflammatory enzyme secreted by activated neutrophils and macrophages in tissues for all treatments, I/R and control groups. Results show that administration of osajin alone did not affect ovarian MPO activity in the ovaries of sham-group rats ($P > 0.05$). IR^{Vehicle} ovarian tissues showed a significant increase in MPO activity compared to the control group ($P < 0.05$). Osajin treatments decreased high I/R-induced MPO activity ($P < 0.05$).

As *Fig. 2, 3, 4* and *5* show, for all treatments and groups, LPO levels and activity of endogenous antioxidants, including CAT and SOD, were measured to understand

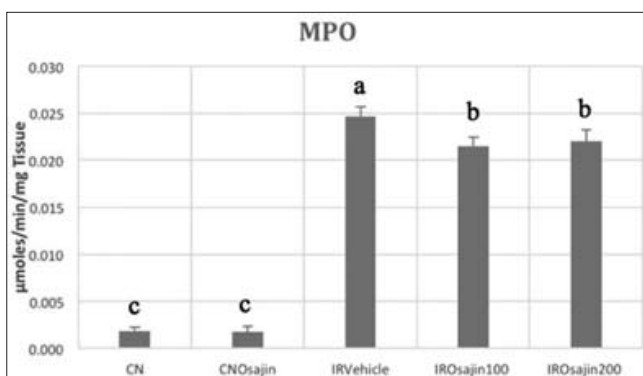


Fig 1. Effects of osajin treatments on MPO activity in I/R injury

Şekil 1. I/R hasarında MPO aktivitesi üzerine osajin tedavilerinin etkileri

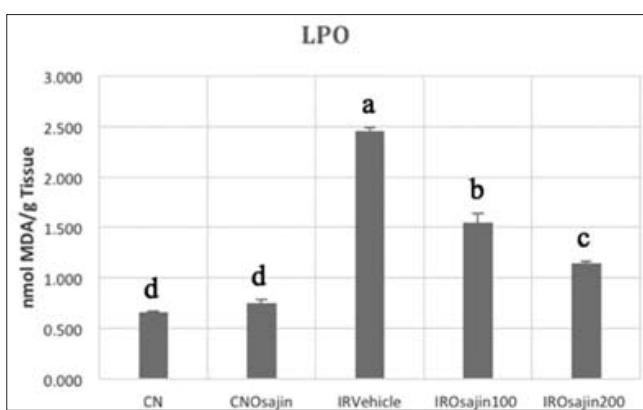


Fig 2. Effects of osajin treatments on LPO level changes in I/R injury

Şekil 2. I/R hasarında LPO seviyesindeki değişimler üzerine osajin tedavilerinin etkileri

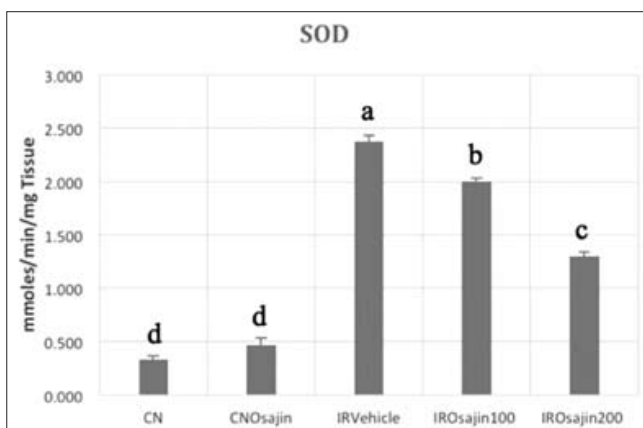


Fig 3. Effects of osajin treatments on SOD activity changes in I/R injury

Şekil 3. I/R hasarında SOD aktivitesi üzerine osajin tedavilerinin etkileri

oxidative damage and behaviours of antioxidant defense mechanisms. Ovaries in the CN and CNOsajin groups had LPO values at the physiological level, and there was no statistical difference in values of LPO between them ($P>0.05$). Ovarian LPO levels in the I/R group were significantly higher than in the control group ($P<0.05$). As Fig. 2 shows, administration of osajin significantly diminished LPO levels that had been increased in ovarian tissues by

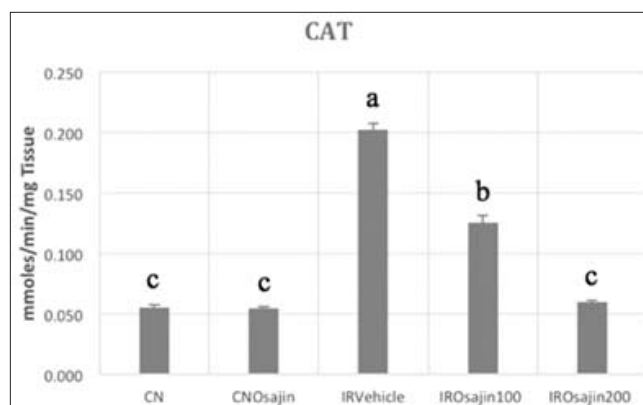


Fig 4. Effects of osajin treatments on CAT activity changes in I/R injury

Şekil 4. I/R hasarında CAT aktivitesi üzerine osajin tedavilerinin etkileri

I/R, both at the 100 mg/kg dose (36.7%) and the 200 mg/kg dose (53.4%) ($P<0.05$).

Compared to the control group and all other treatment groups, IRVehicle group ovarian CAT and SOD activities were significantly higher ($P<0.05$). As Fig. 3 and Fig. 4 show, ovarian SOD and CAT activities were decreased in a dose-dependent manner in the IROsajin100 and IROsajin200 groups ($P<0.05$).

Histopathological Investigations

As Fig. 5 shows, histopathological examination of ovaries in the CN and CNOsajin groups revealed that ovarian follicles, the stroma in between them, the tunica albuginea containing cortex and blood vessels and the loose connective tissue, including medulla, all appeared normal. As Fig. 6A and 6B show, ovarian tissues in the IRVehicle group showed reversible degenerative changes, including hypertrophy, especially accompanied with prominent vacuolization in follicular cells; necrotic tissue, generally in stromal and endothelial cells; apoptotic death, especially in follicular and luteal cells; destruction of venous blood vessels and capillaries by severe hemorrhage; and dense infiltrating polymorphonuclear leukocytes in the parenchyma and stroma. As Fig. 6C shows, ovarian tissues in the IROsajin100 group demonstrated significantly preserved vascular integrity and haemorrhagic areas in the stroma and the corpus luteum, and peripheries of the ovarian follicles were reduced significantly compared to I/R groups. As Fig. 6D shows, in this group, apoptotic cell death accompanied by neutrophil infiltration was observed only in the luteal cells, not in stromal and follicular cells. I/R-induced necrotic cell death and reversible cell damage were reduced significantly in the stromal and parenchymal cells, respectively. As Fig. 6E shows, some cortex areas in the IROsajin200 group showed small hemorrhagic areas, but in general vascular structures close to the CN. In this group, I/R-caused apoptotic cell death was not observed. In ovarian tissues in the IROsajin200 group, infiltration of polymorphonuclear leukocytes and hypertrophic cell degeneration were

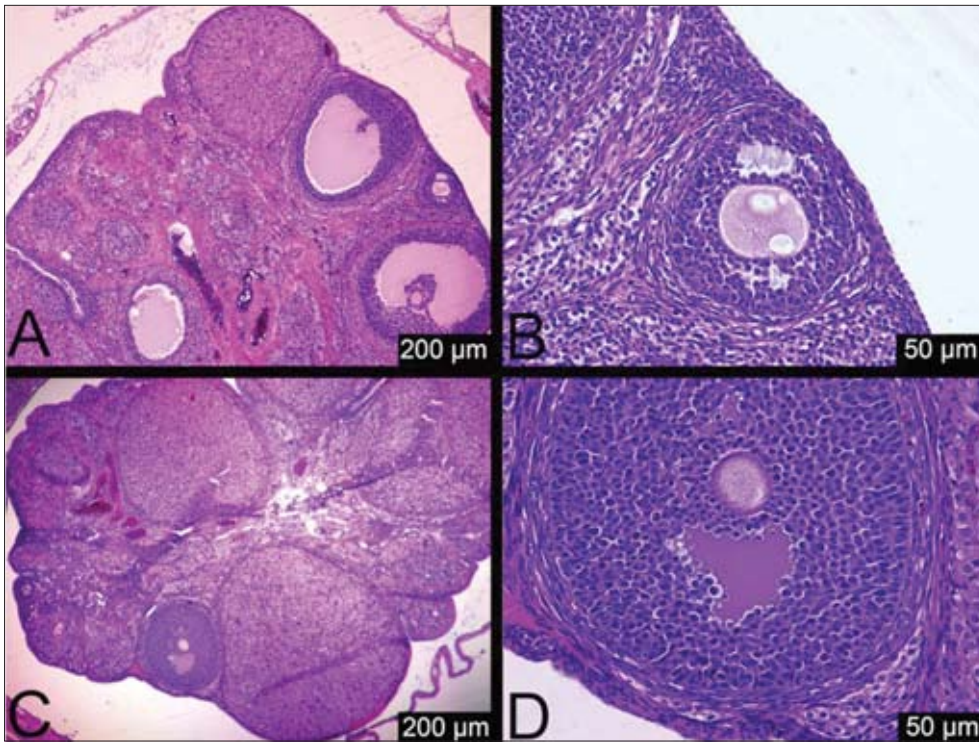


Fig 5. Histologic micrographs of ovaries of the CN (A, B) and CN^{Osajin} (C, D) groups. (A, C) Ovarian cortex and medulla, and (B, D) ovarian growing follicle and stroma on its periphery with normal appearance of ovaries in the CN and CN^{Osajin} groups

Şekil 5. CN (A, B) ve CN^{Osajin} (C, D) gruplarında overlerin histolojik mikroyrafları. CN ve CN^{Osajin} gruplarında ovaryum korteks ve medullası (A, C) ve büyüyen over foliküller ve onun etrafındaki stroması (B, D) ile normal görünümlü overler

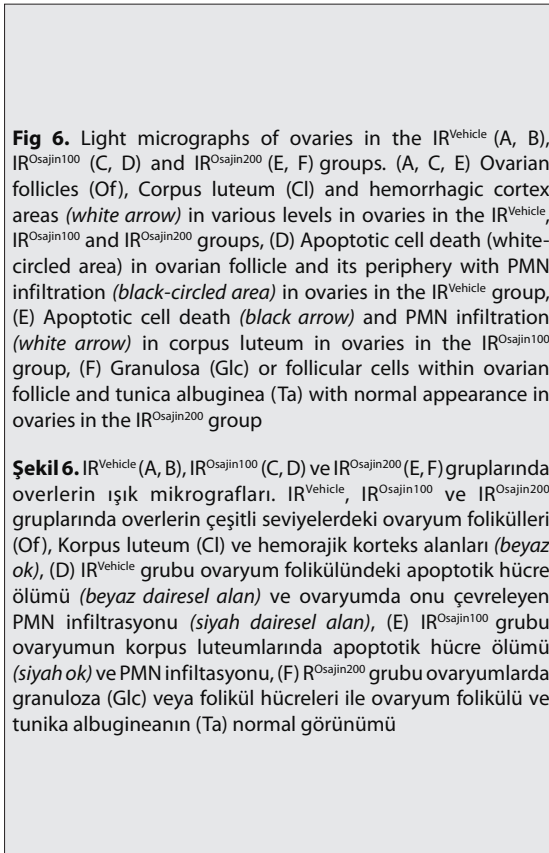
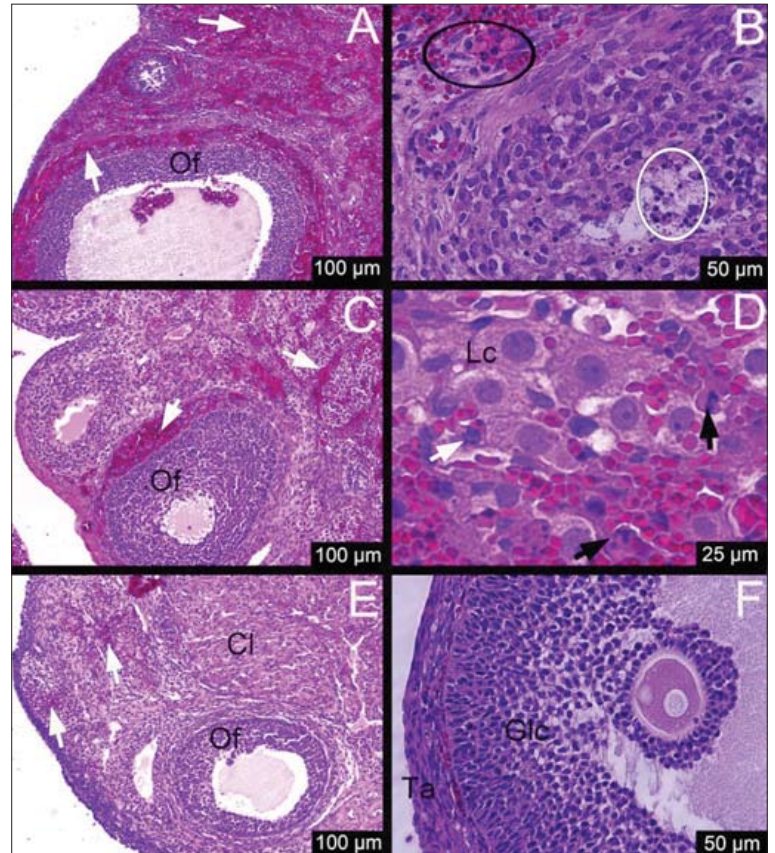


Fig 6. Light micrographs of ovaries in the IR^{Vehicle} (A, B), IR^{Osajin100} (C, D) and IR^{Osajin200} (E, F) groups. (A, C, E) Ovarian follicles (Of), Corpus luteum (Cl) and hemorrhagic cortex areas (white arrow) in various levels in ovaries in the IR^{Vehicle}, IR^{Osajin100} and IR^{Osajin200} groups, (D) Apoptotic cell death (white-circled area) in ovarian follicle and its periphery with PMN infiltration (black-circled area) in ovaries in the IR^{Vehicle} group, (E) Apoptotic cell death (black arrow) and PMN infiltration (white arrow) in corpus luteum in ovaries in the IR^{Osajin100} group, (F) Granulosa (Glc) or follicular cells within ovarian follicle and tunica albuginea (Ta) with normal appearance in ovaries in the IR^{Osajin200} group

Şekil 6. IR^{Vehicle} (A, B), IR^{Osajin100} (C, D) ve IR^{Osajin200} (E, F) gruplarında overlerin ışık mikroyrafları. IR^{Vehicle}, IR^{Osajin100} ve IR^{Osajin200} gruplarında overlerin çeşitli seviyelerdeki ovaryum folikülleri (Of), Korpus luteum (Cl) ve hemorajik korteks alanları (beyaz ok), (D) IR^{Vehicle} grubu ovaryum folikülündeki apoptotik hücre ölümü (beyaz dairesel alan) ve ovaryumda onu çevreleyen PMN infiltrasyonu (siyah dairesel alan), (E) IR^{Osajin100} grubu ovaryumun korpus luteumlarında apoptotik hücre ölümü (siyah ok) ve PMN infiltrasyonu, (F) IR^{Osajin200} grubu ovaryumlarda granuloza (Glc) veya folikül hücreleri ile ovaryum folikülü ve tunika albugineanın (Ta) normal görünümü



reduced significantly compared to the IR^{Vehicle} group. In addition, most parenchymal and stromal components were similar to those in the CN group, as Fig. 6E and 6F show.

DISCUSSION

Ischemia is described as failure to achieve the oxygen and other supplements required for tissue and the lack of

removal of cellular waste by blood circulation. For tissues to use oxygen effectively in situations of hypoxia, the cells make a series of transcriptional and enzyme modifications to ensure a number of factors, such as oxygen-independent ATP production, new vessel formation and ATP catabolism [31]. Transcriptionally, inhibition of prolyl hydroxylase (PHD) uses oxygen as a cofactor in hypoxia, and this inhibition induces increased hypoxia-inducible factor 1 to play a role in synthesis of the factors responsible for glycolysis enzymes of ATP synthesis in an oxygen-independent manner and neovascularization [32-34].

In addition, continued use of ATP and reduction in its production due to the growing influence of hypoxia causes a process for meeting energy needs by converting ATP to the purine metabolites xanthine and hypoxanthine [35-37]. In normal tissues, hypoxanthine is converted into uric acid. In ischemic tissue, hypoxanthine is not further metabolized and accumulates during hypoxia [38]. At the same time, in ischemia, a large portion of xanthine dehydrogenase turns into xanthine oxidase [39]. Xanthine oxidase induces oxidation of hypoxanthine to xanthine and can further trigger conversion from xanthine to uric acid with the onset of reperfusion [40]. During this period, due to increased enzyme activity of the xanthine oxidase, there is an increase in superoxide free radicals [41]. If these increased free radicals in the tissue are not diminished by the major endogenous antioxidants, excess amounts cause oxidative degradation of macromolecules by reacting with all cellular macromolecules. This growing rate of oxidative degradation of macromolecules plays an important role in cellular degeneration and death in I/R. Lipids are important cellular components that suffer from oxidative degradation, and the main end product of this degradation, malondialdehyde, is widely used to determine lipid peroxidation and oxidative tissue damage [42-44]. That is why the present study investigated LPO levels as an indicator of oxidative tissue damage, finding that I/R significantly increased LPO levels. First, at the beginning of I/R, this increase may be associated with increased activity of xanthine oxidase-induced elevated ROS. Cellular damage and the damage-associated molecular pattern molecules (DAMPs) induced by high ROS levels can initiate an immune response in the sterile inflammatory response, and then histamine release by activated mast cells, chemokines and proinflammatory cytokines released by stimulated macrophages trigger neutrophil migration into tissue [45-48]. In later stages of I/R, both oxidative burst response and inflammatory products, along with increased neutrophil migration, play roles in oxidative tissue damage [49,50]. In the present study, biochemical and histopathological findings show increased MPO activity and neutrophil infiltrations in ovarian tissues of the I/R group, showing that neutrophils engage in the pathophysiological process of I/R injury. Second, findings show that, in addition to xanthine oxidase-mediated ROS production, elevated LPO levels

in the I/R group may be associated with ROS production induced by increased neutrophil activity.

Cells protect themselves from oxidative stress by increasing activity of endogenous antioxidants in response to increasing ROS levels [51]. The present study determined that this was responsible for the increased activity in the major endogenous antioxidant enzymes SOD and CAT. The first step of the antioxidant team, involving both SOD and CAT enzymes, eliminated damage caused by superoxide radicals and derivatives. This provides information about levels of their substrates and indicates how the defense mechanism acts [52]. In light of this information, even though there is increased antioxidant enzyme activity, high LPO levels in the tissues can be related to sufficient conversion of superoxide to H₂O₂ by SOD or to inadequate H₂O₂ degradation via CAT. Many studies have shown that oxidative stress and excessive inflammatory products, depending on their densities in I/R injuries, cause either reversible cell damage or irreversible, lethal, cell damage, such as apoptosis and necrosis [53,54].

In histopathological examination of ovarian tissue, the present study observed reversible cell damage in both stromal and parenchymal cells. In addition, apoptotic and necrotic cell death were observed mainly in the stromal and parenchymal cells. In addition, the study observed dense neutrophil migration accompanied by hemorrhage. In addition to the biochemical data, these findings suggest oxidative stress and inflammatory response at these levels can lead to irreversible cell death.

Administration of 100 and 200 mg/kg doses of osajin diminished I/R-induced increases in ovarian LPO levels by 36.7% and 53.4%, respectively. Likewise, both SOD and CAT levels decreased dose-dependently. Increased activity of any enzyme could be linked to enhanced substrate production during metabolic processes [13]. Decreased antioxidant enzyme activities in the treatment groups could be explained by reduced ROS or substrate levels. Two previous studies of renal and myocardial I/R injuries found that SOD activity in tissues increased with 60 min reperfusion [24,25]. These findings suggest that there may be a decrease in ovarian LPO levels over time, given the elevated SOD activities at the beginning of the 3-h reperfusion in the present study, which may decrease the SOD activity according to the substrate reduction level at 3 h. Interestingly, Diopan et al. [23] found that, although the antioxidant capacity of osajin was less, osajin strongly decreased oxidative damage in DNA exposed to oxygen radicals independent of antioxidant capacity. This effect shows that, in I/R injury, osajin may decrease LPO levels through pathways other than SOD and CAT activity. We have found no information in the literature about metabolites of osajin and its in-vivo metabolism. In addition, high LPO levels may be decreased by the potentially powerful antioxidant effects of osajin metabolites that may occur in organs such as the liver and kidneys. In addition to the

antioxidant effects of osajin, the present study shows anti-inflammatory effects caused by lower MPO levels and neutrophil infiltration in tissues due to osajin treatment of ovarian I/R injury. Hošek et al.^[26] showed that inhibition of I κ B-alpha degradation mediates anti-inflammatory effects of osajin in macrophage cell cultures. NF- κ B (p65) is an essential transcription factor responsible for expression of many proinflammatory cytokines, such as TNF- α , IL-1 β , IL-6 and IL-8, in macrophages^[55]. I κ B α inhibits NF- κ B from cytoplasm to the cell nucleus via nuclear transport by binding nuclear localization signals of NF- κ B. If there is any increase I κ B-alpha degradation that is stimulant induced, NF- κ B is released to move from the cytoplasm to the nucleus and begins expression of proinflammatory cytokines by binding to DNA as a transcription factor^[56,57]. This indicates that the mitigating effects of osajin on neutrophil activities and infiltration found by the present study may be related to degradation-induced lessened release of proinflammatory cytokines from macrophages via its inhibitory effect on I κ B alpha. This anti-inflammatory effect may contribute to decreased LPO levels caused by neutrophil-derived ROS. In histopathological examination of ovarian tissues in the IR^{Osajin100} and IR^{Osajin200} groups, density of hemorrhagic areas, infiltration of polymorphonuclear leukocytes and reversible (vacuolated hypertrophic) and irreversible (apoptotic and necrotic) cell damage all were reduced compared to the I/R group in proportion to the osajin dose. In particular, ovarian tissues in the IR^{Osajin200} group generally showed parenchymal and stromal components similar to those in the CN group. Histopathological results of the present study demonstrated that osajin treatment dose-dependently promoted recovery from I/R tissue damage in torsion-detorsion models in rats.

Finally, on the basis of biochemical and histopathological findings observed for the first time in the present study, it can be said that early administration of osajin ameliorates the severity of ovarian-tissue damage induced by I/R. Therefore, osajin has been shown to be useful in preventing permanent ovarian damage caused by torsion-detorsion in women.

REFERENCES

- Bozkurt S, Arikian DC, Kurutas EB, Sayar H, Okumus M, Coskun A, Bakan V:** Selenium has a protective effect on ischemia/reperfusion injury in a rat ovary model: Biochemical and histopathologic evaluation. *J Pediatr Surg*, 47, 1735-1741, 2012. DOI: 10.1016/j.jpedsurg.2012.03.053
- Albayrak Y, Halici Z, Odabasoglu F, Unal D, Keles ON, Malkoc I, Oral A, Yayla M, Aydin O, Unal B:** The effects of testosterone on intestinal ischemia/reperfusion in rats. *J Invest Surg*, 24, 283-291, 2011. DOI: 10.3109/08941939.2011.591894
- Kumtepe Y, Odabasoglu F, Karaca M, Polat B, Halici MB, Keles ON, Altunkaynak Z, Gocer F:** Protective effects of telmisartan on ischemia/reperfusion injury of rat ovary: Biochemical and histopathologic evaluation. *Fertil Steril*, 93, 1299-1307, 2010. DOI: 10.1016/j.fertnstert.2008.12.016
- Hibbard LT:** Adnexal torsion. *Am J Obstet Gynecol*, 152 (4): 456-461, 1985.
- White M, Stella J:** Ovarian torsion: 10-year perspective. *Emerg Med Australas*, 17 (3): 231-237, 2005. DOI: 10.1111/j.1742-6723.2005.00728.x
- Oelsner G, Shashar D:** Adnexal torsion. *Clin Obstet Gynecol*, 49 (3): 459-463, 2006.
- Duigenan S, Oliva E, Lee SI:** Ovarian torsion: Diagnostic features on CT and MRI with pathologic correlation. *AJR Am J Roentgenol*, 198, W122-131, 2012. DOI: 10.2214/AJR.10.7293
- Fujishita A, Araki H, Yoshida S, Hamaguchi D, Nakayama D, Tsuda N, Khan KN:** Outcome of conservative laparoscopic surgery for adnexal torsion through one-stage or two-stage operation. *J Obstet Gynaecol Res*, 41, 411-417, 2015. DOI: 10.1111/jog.12534
- Kurtoglu E, Kokcu A, Danaci M:** Asynchronous bilateral ovarian torsion. A case report and mini review. *J Pediatr Adolesc Gynecol*, 27, 122-124, 2014. DOI: 10.1016/j.jpog.2013.06.016
- Sengul O, Ferah I, Polat B, Halici Z, Bayir Y, Yilmaz M, Kilic N, Keles ON:** Blockade of endothelin receptors with bosentan limits ischaemia/reperfusion-induced injury in rat ovaries. *Eur J Obstet Gynecol Reprod Biol*, 170, 458-463, 2013. DOI: 10.1016/j.ejogrb.2013.06.040
- Park ES, Kim J, Ha TU, Choi JS, Soo Hong K, Rho J:** TDAG51 deficiency promotes oxidative stress-induced apoptosis through the generation of reactive oxygen species in mouse embryonic fibroblasts. *Exp Mol Med*, 45: e35, 2013. DOI: 10.1038/emm.2013.67
- Unal D, Aksak S, Halici Z, Sengul O, Polat B, Unal B, Halici M:** Effects of diabetes mellitus on the rat liver during the postmenopausal period. *J Mol Histol*, 42, 273-287, 2011. DOI: 10.1007/s10735-011-9331-9
- Halici M, Imik H, Koc M, Gumus R:** Effects of α -lipoic acid, vitamins E and C upon the heat stress in Japanese quails. *J Anim Physiol Anim Nutr*, 96, 408-415, 2012. DOI: 10.1111/j.1439-0396.2011.01156.x
- Kaplan KA, Odabasoglu F, Halici Z, Halici M, Cadirci E, Atalay F, Aydin O, Cakir A:** Alpha-lipoic acid protects against indomethacin-induced gastric oxidative toxicity by modulating antioxidant system. *J Food Sci*, 77, H224-230, 2012. DOI: 10.1111/j.1750-3841.2012.02920.x
- Patouraux S, Rousseau D, Rubio A, Bonnafous S, Lavallard VJ, Lauron J, Saint-Paul MC, Bailly-Maitre B, Tran A, Crenesse D, Gual P:** Osteopontin deficiency aggravates hepatic injury induced by ischemia-reperfusion in mice. *Cell Death Dis*, 5, e1208, 2014. DOI: 10.1038/cddis.2014.174
- Kolaczowska E, Kubes P:** Neutrophil recruitment and function in health and inflammation. *Nat Rev Immunol*, 13, 159-175, 2013. DOI: 10.1038/nri3399
- Di A, Gao XP, Qian F, Kawamura T, Han J, Hecquet C, Ye RD, Vogel SM, Malik AB:** The redox-sensitive cation channel TRPM2 modulates phagocyte ROS production and inflammation. *Nat Immunol*, 13, 29-34, 2012. DOI: 10.1038/ni.2171
- Hausenloy DJ, Yellon DM:** Myocardial ischemia-reperfusion injury: a neglected therapeutic target. *J Clin Invest*, 123 (1): 92-100, 2013.
- Agarwal A, Gupta S, Sharma RK:** Role of oxidative stress in female reproduction. *Reprod Biol Endocrinol*, 3, 28, 2005. DOI: 10.1186/1477-7827-3-28
- Orhan I, Senol FS, Kartal M, Dvorska M, Zemlicka M, Smejkal K, Mokry P:** Cholinesterase inhibitory effects of the extracts and compounds of *Maclura pomifera* (Rafin.) Schneider. *Food Chem Toxicol*, 47, 1747-1751, 2009. DOI: 10.1016/j.fct.2009.04.023
- Tsao R, Yang R, Young JC:** Antioxidant isoflavones in *Osage orange*, *Maclura pomifera* (Raf.) Schneid. *J Agric Food Chem*, 51, 6445-6451, 2003. DOI: 10.1021/jf0342369
- Vesela D, Kubinova R, Muselik J, Zemlicka M, Suchy V:** Antioxidative and EROD activities of osajin and pomiferin. *Fitoterapia*, 75, 209-211, 2004. DOI: 10.1016/j.fitote.2003.12.005
- Diopan V, Babula P, Shestivska V, Adam V, Zemlicka M, Dvorska M, Hubalek J, Trnkova L, Havel L, Kizek R:** Electrochemical and spectrometric study of antioxidant activity of pomiferin, isopomiferin, osajin and catalposide. *J Pharm Biomed Anal*, 48, 127-133, 2008. DOI: 10.1016/j.jpba.2008.05.025
- Bartosikova L, Necas J, Suchy V, Janostikova E, Bartosik T, Jurica J, Florian T, Klusakova J, Frydrych M:** Protective effects of osajin in

ischemia-reperfusion of laboratory rat kidney. *Pharmazie*, 61 (6): 552-555, 2006.

- 25. Florian T, Necas J, Bartosikova L, Klusakova J, Suchy V, Naggara EB, Janostikova E, Bartosik T:** Effects of prenylated isoflavones osajin and pomiferin in premedication on heart ischemia-reperfusion. *Biomed Pap Med Fac Univ Palacky Olomouc Czech Repub*, 150 (1): 93-100, 2006.
- 26. Hosek J, Toniolo A, Neuwirth O, Bolego C:** Prenylated and geranylated flavonoids increase production of reactive oxygen species in mouse macrophages but inhibit the inflammatory response. *J Nat Prod*, 76, 1586-1591, 2013. DOI: 10.1021/np400242e
- 27. Bradley PP, Priebe DA, Christensen RD, Rothstein G:** Measurement of cutaneous inflammation: Estimation of neutrophil content with an enzyme marker. *J Invest Dermatol*, 78, 206-209, 1982. DOI: 10.1111/1523-1747.ep12506462
- 28. Ohkawa H, Ohishi N, Yagi K:** Assay for lipid peroxides in animal tissues by thiobarbituric acid reaction. *Anal Biochem*, 95 (2): 351-358, 1979. DOI: 10.1016/0003-2697(79)90738-3
- 29. Sun Y, Oberley LW, Li Y:** A simple method for clinical assay of superoxide dismutase. *Clin Chem*, 34 (3): 497-500, 1988.
- 30. Aebi H:** Catalase *in vitro*. *Methods Enzymol*, 105, 121-126, 1984.
- 31. Semenza GL:** Regulation of oxygen homeostasis by hypoxia-inducible factor 1. *Physiology (Bethesda)*, 24, 97-106, 2009. DOI: 10.1152/physiol.00045.2008
- 32. Lando D, Peet DJ, Gorman JJ, Whelan DA, Whitelaw ML, Bruick RK:** FIH-1 is an asparaginyl hydroxylase enzyme that regulates the transcriptional activity of hypoxia-inducible factor. *Genes Dev*, 16, 1466-1471, 2002. DOI: 10.1101/gad.991402
- 33. Kelly BD, Hackett SF, Hirota K, Oshima Y, Cai Z, Berg-Dixon S, Rowan A, Yan Z, Campochiaro PA, Semenza GL:** Cell type-specific regulation of angiogenic growth factor gene expression and induction of angiogenesis in nonischemic tissue by a constitutively active form of hypoxia-inducible factor 1. *Circ Res*, 93 (11): 1074-1081, 2003.
- 34. Semenza GL, Roth PH, Fang HM, Wang GL:** Transcriptional regulation of genes encoding glycolytic enzymes by hypoxia-inducible factor 1. *J Biol Chem*, 269 (38): 23757-23763, 1994.
- 35. Poulsen JP, Oyasaeter S, Saugstad OD:** Hypoxanthine, xanthine, and uric acid in newborn pigs during hypoxemia followed by resuscitation with room air or 100% oxygen. *Crit Care Med*, 21 (7): 1058-1065, 1993.
- 36. McCord JM:** Oxygen-derived free radicals in postischemic tissue injury. *N Engl J Med*, 312 (3): 159-163, 1985.
- 37. Zimmerman BJ, Granger DN:** Mechanisms of reperfusion injury. *Am J Med Sci*, 307 (4): 284-292, 1994.
- 38. McCord JM, Roy RS, Schaffer SW:** Free radicals and myocardial ischemia. The role of xanthine oxidase. *Adv Myocardiol*, 5: 183-189, 1985.
- 39. Parks DA, Williams TK, Beckman JS:** Conversion of xanthine dehydrogenase to oxidase in ischemic rat intestine: A reevaluation. *Am J Physiol*, 254 (5 Pt 1): G768-774, 1988.
- 40. Braunersreuther V, Jaquet V:** Reactive oxygen species in myocardial reperfusion injury: From physiopathology to therapeutic approaches. *Curr Pharm Biotechnol*, 13, 97-114, 2012. DOI: 10.2174/138920112798868782
- 41. Zweier JL, Talukder MA:** The role of oxidants and free radicals in reperfusion injury. *Cardiovasc Res*, 70, 181-190, 2006. DOI: 10.1016/j.cardiores.2006.02.025
- 42. Keleş ON, Can S, Çığsar G, Çolak S, Erol HS, Akaras N, Erdemci B, Bilgin BÇ, Can İ, Ünal B, Halıcı MB:** Hepatoprotective effects of B-1, 3-(D)-glucan on bortezomib-induced liver damage in rats. *Kafkas Univ Vet Fak Derg*, 20, 929-938, 2014. DOI: 10.9775/kvfd.2014.11413
- 43. Erdogan H, Fadillioğlu E, Yagmurca M, Ucar M, Irmak MK:** Protein oxidation and lipid peroxidation after renal ischemia-reperfusion injury: protective effects of erdosteine and N-acetylcysteine. *Urol Res*, 34, 41-46, 2006. DOI: 10.1007/s00240-005-0031-3
- 44. Paller MS, Hoidal JR, Ferris TF:** Oxygen free radicals in ischemic acute renal failure in the rat. *J Clin Invest*, 74, 1156-1164, 1984. DOI: 10.1172/JCI111524
- 45. Chen GY, Nunez G:** Sterile inflammation: Sensing and reacting to damage. *Nat Rev Immunol*, 10, 826-837, 2010. DOI: 10.1038/nri2873
- 46. van Golen RF, van Gulik TM, Heger M:** The sterile immune response during hepatic ischemia/reperfusion. *Cytokine Growth Factor Rev*, 23, 69-84, 2012. DOI: 10.1016/j.cytogfr.2012.04.006
- 47. Nathan C:** Neutrophils and immunity: Challenges and opportunities. *Nat Rev Immunol*, 6, 173-182, 2006. DOI: 10.1038/nri1785
- 48. Jaeschke H, Smith CW:** Mechanisms of neutrophil-induced parenchymal cell injury. *J Leukoc Biol*, 61 (6): 647-653, 1997.
- 49. Welbourn CR, Goldman G, Paterson IS, Valeri CR, Shepro D, Hechtman HB:** Pathophysiology of ischaemia reperfusion injury: Central role of the neutrophil. *Br J Surg*, 78, 651-655, 1991. DOI: 10.1002/bjs.1800780607
- 50. Duilio C, Ambrosio G, Kuppusamy P, DiPaula A, Becker LC, Zweier JL:** Neutrophils are primary source of O₂ radicals during reperfusion after prolonged myocardial ischemia. *Am J Physiol Heart Circ Physiol*, 280 (6): H2649-2657, 2001.
- 51. Çolak S, Geyikoğlu F, Turkez H, Bakir M, Husseinigouzdaganii M, Can S, Çığsar G, Aslan A:** The effects of lichens extracts in the healthy rats and the medical utility of these extracts in the prevention of diabetes-associated multiple organ failures. *Kafkas Univ Vet Fak Derg*, 21, 101-110, 2015. DOI: 10.9775/kvfd.2014.11913
- 52. Bhattacharya S:** Reactive Oxygen Species and Cellular Defense System. *Free Radicals in Human Health and Disease*, 17-29, Springer India; 2015. DOI: 10.1007/978-81-322-2035-0_2
- 53. Eefting F, Rensing B, Wigman J, Pannekoek WJ, Liu WM, Cramer MJ, Lips DJ, Doevendans PA:** Role of apoptosis in reperfusion injury. *Cardiovasc Res*, 61, 414-426, 2004. DOI: 10.1016/j.cardiores.2003.12.023
- 54. Linkermann A, Brasen JH, Darding M, Jin MK, Sanz AB, Heller JO, De Zen F, Weinlich R, Ortiz A, Walczak H, Weinberg JM, Green DR, Kunzendorf U, Krautwald S:** Two independent pathways of regulated necrosis mediate ischemia-reperfusion injury. *Proc Natl Acad Sci USA*, 110, 12024-12029, 2013. DOI: 10.1073/pnas.1305538110
- 55. Bonizzi G, Karin M:** The two NF-kappaB activation pathways and their role in innate and adaptive immunity. *Trends Immunol*, 25, 280-288, 2004. DOI: 10.1016/j.it.2004.03.008
- 56. Ashikawa K, Majumdar S, Banerjee S, Bharti AC, Shishodia S, Aggarwal BB:** Piceatannol inhibits TNF-induced NF-kappaB activation and NF-kappaB-mediated gene expression through suppression of IkkappaBalpha kinase and p65 phosphorylation. *J Immunol*, 169 (11): 6490-6497, 2002.
- 57. Shames BD, Selzman CH, Meldrum DR, Pulido EJ, Barton HA, Meng X, Harken AH, Jr McIntyre RC:** Interleukin-10 stabilizes inhibitory kappaB-alpha in human monocytes. *Shock*, 10 (6): 389-394, 1998.